Measurement of Bowel Wall Thickness by Transabdominal Ultrasonography Is Useful to Detect the Inflammation of Colon in Ulcerative Colitis Patients : A Retrospective Study

Masahiro Takahara (mtakahara@cc.okayama-u.ac.jp)
Department of Gastroenterology and Hepatology, Okayama University Graduate School of Medicine, Dentistry and Pharmaceutical Sciences,

Sakiko Hiraoka
Department of Gastroenterology and Hepatology, Okayama University Graduate School of Medicine, Dentistry and Pharmaceutical Sciences,

Masayasu Ohmori
Department of Gastroenterology and Hepatology, Okayama University Graduate School of Medicine, Dentistry and Pharmaceutical Sciences,

Kensuke Takei
Department of Gastroenterology and Hepatology, Okayama University Graduate School of Medicine, Dentistry and Pharmaceutical Sciences,

Eriko Yasutomi
Department of Gastroenterology and Hepatology, Okayama University Graduate School of Medicine, Dentistry and Pharmaceutical Sciences,

Shoko Igawa
Department of Gastroenterology and Hepatology, Okayama University Graduate School of Medicine, Dentistry and Pharmaceutical Sciences,

Shumpei Yamamoto
Department of Gastroenterology and Hepatology, Okayama University Graduate School of Medicine, Dentistry and Pharmaceutical Sciences,

Shohei Oka
Department of Gastroenterology and Hepatology, Okayama University Graduate School of Medicine, Dentistry and Pharmaceutical Sciences,

Mami Hirai
Department of Gastroenterology and Hepatology, Okayama University Graduate School of Medicine, Dentistry and Pharmaceutical Sciences,

Yasushi Yamasaki
Department of Gastroenterology and Hepatology, Okayama University Graduate School of Medicine, Dentistry and Pharmaceutical Sciences,

Toshihiro Inokuchi
Department of Gastroenterology and Hepatology, Okayama University Graduate School of Medicine, Dentistry and Pharmaceutical Sciences,
Hideaki Kinugasa
Department of Gastroenterology and Hepatology, Okayama University Graduate School of Medicine, Dentistry and Pharmaceutical Sciences,
Keita Harada
Department of Gastroenterology and Hepatology, Okayama University Graduate School of Medicine, Dentistry and Pharmaceutical Sciences,
Hideki Ohnishi
Department of Gastroenterology and Hepatology, Okayama University Graduate School of Medicine, Dentistry and Pharmaceutical Sciences,
Hiroyuki Okada
Department of Gastroenterology and Hepatology, Okayama University Graduate School of Medicine, Dentistry and Pharmaceutical Sciences,

---

Research Article

Keywords: Ulcerative colitis, Transabdominal ultrasonography, Bowel wall thickness, Mayo endoscopic score

Posted Date: December 11th, 2020

DOI: https://doi.org/10.21203/rs.3.rs-122414/v1

Abstract

Background: Transabdominal ultrasonography (TUS) is a non-invasive method that can be performed repeatedly. Although the usefulness of TUS in ulcerative colitis (UC) has been reported, no well-established data exist yet. This study aimed to determine the usefulness of TUS, compared with colonoscopy (CS), in detecting the presence of mucosal inflammation in each segment of the colon among patients with UC.

Methods: Eighty UC patients who underwent US within 14 days after CS were retrospectively registered. We divided the colon into five segments and measured the bowel wall thickness (BWT) using TUS. The results were then compared with the Mayo endoscopic subscore classification (MES) in order to determine their accuracy.

Result: We evaluated a total of 268 lesions for each segment among 80 UC patients. The proportion of BWT decreased with an increase in the MES of each segment ($p < 0.0001$, Cochran-Armitage trend test). The sensitivity, specificity, and accuracy of positive BMT (BWT >2 mm) for detecting mucosal inflammation (MES >0) of each segment were 0.85-1.00, 0.78-0.93, and 0.87-0.98, respectively.

Conclusion: This study concluded that TUS was a useful method for detecting the presence or absence of inflammation sites among UC patients due to its high accuracy when BMT >2 mm was considered as a positive finding. This non-invasive method may help control the disease activity of UC.

Background

Ulcerative colitis (UC) is characterized by chronic inflammation of the gastrointestinal tract and it affects the colon and the rectum, resulting in continuous inflammation.[1-3] Currently, there are no radical treatments for UC; therefore, patients require treatments throughout their lifetime.[4] Accurate assessment and proper treatment are crucial for monitoring UC patients. Endoscopy is the standard method for evaluating the activity of UC,[5] but frequent examination is difficult to conduct because of its highly invasive nature.[6] Moreover, endoscopic examination sometimes leads to the worsening of disease activity, especially for patients with severe conditions.[7,8] On the contrary, transabdominal ultrasonography (TUS) is a non-invasive method that can be performed repeatedly. According to necessity of continuous treatments, in this disease, TUS is also expected to be applied in a wide range of clinical assessments, such as in the judgment of treatment effects and in the evaluations of disease condition at the time of deterioration.[9-11]

Recently, the technological development of US devices has resulted in improved spatial resolution and depth sensitivity, allowing *detailed evaluations of the intestinal tract. Therefore, it is expected to be a useful tool for evaluating disease activity.*

Many reports of TUS for UC assessment are mainly based on disease severity.[12-14] However, UC is a refractory disease that has the possibility of worsening. Moreover, recently, the treatment goal has shifted

from clinical remission to endoscopic remission, which is associated with sustained clinical remission and reduced rates of hospitalization and surgical resection.[15,16] Therefore, the recognition of disease severity and the determination of the presence of mucosal inflammation are important factors in the selection of therapeutic agents, including local therapy.

The active lesions of UC in TUS are depicted as thickenings of the walls of the large intestine due to infiltration by inflammatory cells into the mucosa up to the submucosa. These lesions can therefore be evaluated by measuring the thickness of the large intestine wall.

In many previous reports, a colon wall thickness of 3-4 mm or more[9,12,13,17] indicated the presence of inflammation, but in autologous cases, mucosal inflammation was observed even in cases of a colon wall thickness of 3 mm or less. This 3-mm criterion has low sensitivity and may not be sufficient for detecting active lesions. Therefore, we were prompted to evaluate different conditions of colon wall thickness by TUS to reliably identify active lesions.

In this study, we compared TUS with colonoscopy findings and evaluated the usefulness of TUS in detecting mucosal inflammation in each segment of the colon among UC patients, with a change of 3-mm considered as a positive finding.

Methods

Patients

In this study, patients with UC visiting Okayama University Hospital were recruited from September 2016 to December 2019. Specifically, we included patients who underwent TUS within 14 days of colonoscopy (CS) for activity evaluation. We excluded patients who had aggravation or improvement of clinical status due to changes in treatment between CS and TUS, patients under 15 years of age, and patients with a proctitis phenotype. All patients had an established diagnosis of UC, according to endoscopic and histologic assessments, and had received medical therapy.

Clinical disease activity was scored using the Mayo endoscopic subscore classification (MES),[18] which is based on the four following criteria: stool frequency, rectal bleeding, endoscopic findings, and physician's global assessment (0, normal; 1, mild disease; 2, moderate disease; 3, severe disease). Clinical activity remission was defined as an MES stool frequency subscore of 0 or 1 and an MES rectal bleeding subscore of 0.

Transabdominal ultrasonography

TUS machines, AplioXG and Aplio 500, (Cannon Medical Systems Corp., Otawara, Japan) were utilized in this study. Two doctors, who had 3- and 6-year experiences with TUS of the digestive tract, performed TUS. TUS was performed after at least 5 hours of fasting. Neither preparation was used.

We first performed TUS by using a 3.5 MHz convex transducer for the purpose of whole abdominal screening. After which, a 7.5 MHz high-frequency linear-array transducer was used for more detailed evaluations. Each part of the colon was sequentially assessed, except for the rectum because it is difficult to assess.[19, 20] We divided the colon into five segments: ascending colon, right-sided and left-sided transverse colons, descending colon, and sigmoid colon. Using a 7.5 MHz high-frequency linear-array transducer, bowel wall thickness (BWT) was also then measured, which is defined as the distance from the central hyperechoic line of the lumen (i.e., lumens of digestive tract) to the outer hyperechoic margin of the wall (which refers to the serosa of the digestive tract) **(Figure 1-A, B)**.

Colonoscopy

On the day of the CS, patients received polyethylene glycol-based bowel preparations in accordance with the manufacturer's instructions. After the colonic lavage was completed, the patients then underwent CS. For patients with severe conditions, to avoid the risk of disease deterioration, a possible range was observed using enteroclysis for bowel perforation.

We compared the range of endoscopic observations with ultrasound findings. Patients were excluded if the colonoscopic examination was up to the rectum. Mucosal inflammation of each segment in UC was assessed using the MES.[18] Evaluation was performed at each portion of the colon, as mentioned above. Mucosal inflammation of each segment was defined as MES >0.

Statistical analysis

All statistical analyses were conducted using the JMP program (Version 13, SAS Institute, Cary, NC, USA). Spearman rank correlation was performed to determine the association between BWT and MES, while the trend between these two values was evaluated using the Cochran-Armitage trend test. Sensitivity, specificity, positive predictive value (PPV), negative predictive value (NPV), positive likelihood ratio, negative likelihood ratio, and area under the curve (AUC) with 95% confidence intervals for detecting mucosal inflammation by endoscopy were also determined, with the TUS findings as the basis. To estimate the appropriate cutoff values for BWT for detecting mucosal inflammation, receiver operating characteristic curve analysis was performed. All *p*-values were two-sided and were considered significant when $p < 0.05$.

Ethical considerations

The study protocol was approved by the institutional review board of Okayama University Graduate School of Medicine, Dentistry, and Pharmaceutical Sciences. Informed consent was obtained from each patient. All methods were performed in accordance with the Declaration of Helsink.

Results

Patients characteristics

A total of 80 UC patients who underwent US and CS were enrolled in this study. Their demographic and clinical characteristics are shown in **Table 1**. There were numerous (82.5%; n=66) male patients with a pancolitis phenotype. All patients underwent endoscopy for inflammation assessment. Only three patients were negative for inflammation in any part of the colorectum. To a greater or lesser degree, other patients had inflammation along their colorectum. Because there were some patients with severe conditions, we refrained from inserting the oral side colon to these patients, causing a decrease in the number of evaluations of the oral side colon. Rectal lesions were not assessed as these are difficult to evaluate[19]; therefore, we excluded patients with proctitis. The median interval between the TUS and colonoscopies was 14 days. Ten patients underwent changes in treatments during the examination, but clinically, no patient had a clear change in disease activity during this time.

Correlation between bowel wall thickness and colonoscopic findings of each part of colon

The correlations between BWT and CS findings are shown in **Figure 2-A, B, C, D, and E.** Spearman rank correlation coefficients and the corresponding *p-values* for the correlation are shown in each figures. BWT was positively correlated with endoscopic activity, but the correlation coefficient varied by segment (0.47-0.84, p <0.0001). Moreover, we assessed the presence of an association between mucosal inflammation and MES on each segment. The trend of the decrease in relation to the MES for each segment was statistically significant (p < 0.0001; each segment, Cochran-Armitage trend test).

In previous reports, a BWT >2 or 3 or 4 mm was evaluated as a positive finding. Among these values, BWT >3 or 4 mm was the commonly used criterion for a positive finding of inflammation.[9,12,13,20] However, from the receiver operating characteristic curve, the cut-off value of each segment was 2.0 - 2.4 mm **(Supplementary Table 1)**. Thus, 2 mm was considered optimal in this study. Furthermore, there is paucity of data detailing the usefulness of BMT > 2 mm as a positive finding. Therefore, in this study, we conducted inflammation assessment with BWT > 2 mm as a positive finding.

Sensitivity, specificity, and predictive values of bowel wall thickness for mucosal status

Table 2 shows the sensitivity, specificity, PPV, NPV, positive likelihood ratio, negative likelihood ratio, and accuracy of BWT >2 mm in relation to mucosal inflammation (MES >0) for each segment. The ratio of the MES was different for each segment, and each value of the inspection accuracy varied slightly; however, the result was almost enough to assess inflammation.[9,12] In addition, when a BWT >3 mm was used as the basis for a positive finding, the sensitivity dropped considerably; as a result, accuracy and area under curve were low (**Table 3**). In some reports, MES 1 was not defined as mucosal inflammation.[12,17] We also evaluated the sensitivity, specificity, PPV, NPV, positive likelihood ratio, negative likelihood ratio, and accuracy of BWT. When mucosal inflammation of each segment was defined as MES >1, specificity dropped considerably, and as a result, accuracy and area under curve were low (**Table 4**). We also evaluated the sensitivity, specificity, PPV, NPV, positive likelihood ratio, negative likelihood ratio, and accuracy per patient under similar conditions as per segment and the results were similar **(Supplementary Table 2)**.

These results showed that BWT >2 mm as a positive finding was useful for detecting mucosal inflammation in each segment of the colon.

Discussion

In this study, among outpatients and outpatients with UC, we compared BWT by TUS using CS findings in each segment of the colon, and showed that BWT reflected mucosal inflammation. In addition, a positive BWT of the colon accurately determined the presence of mucosal inflammation in UC. Therefore, TUS can be a useful and suitable method for detecting mucosal inflammation in UC for both inpatients and outpatients.

TUS has been a useful tool for evaluating the location of mucosal inflammation and assessing the disease activity of UC.[9,12,17,21,22] Among the various studies on UC, some have focused on assessing disease extent and location with a detailed consideration of mucosal inflammation.[9,12,17,21] These studies had a positive BWT of more than 3 mm or more, which may include areas with mild mucosal inflammation. Additionally, MES 1 was not classified as mucosal inflammation. There is a recent trend regarding MES 0 as mucosal healing, and there is a need for a stricter assessment of mucosal states.[14,15] The improvements of US machines have improved their spatial resolutions in comparison to past models, allowing the possibility of a more detailed observation of intestinal states. Therefore, we believe conventional intestinal evaluation with TUS was not sufficient to evaluate mucosal inflammation and consequently changed the evaluation method and analyzed it.

Our results indicated that BWT of UC patients tended to increase with increasing endoscopic severity, suggesting that measurement of BWT by TUS would be useful for the evaluation of mucosal inflammation. Regarding the correlation between BMT and MES, although there was a difference depending on the site, a high correlation was detected on the right colon side. Since it is difficult for patients with severe conditions to undergo a total CS examination, these results suggest that the degree of inflammation on the oral side might be evaluated noninvasively to some extent. On the other hand, in another report, the left colon was found to have a higher correlation for BMT and MES.[20] This may be due to differences in patient background, such as the intensity of inflammation and the number of patients analyzed as well as in the variations in the definition of BMT of the positive findings. It is recommended that further studies are necessary, including studies at other facilities, to increase the sample size and to clarify further the correlation between BMT and MES.

Regarding BMT, the optimal BWT varied slightly from segment to segment. However, our data suggest that BWT >2 mm as a positive finding might be appropriate for detecting mucosal inflammation. With this criterion, the calculated specificity of each site tended to have a lower value, but the results were almost comparable to those reported previously.[12,23,24] When the positive BWT was >3 mm, the specificity increased; however, the sensitivity decreased. As a result, BWT >2 mm as positive findings performed better overall. In our study, cases of mucosal inflammation of 2 mm or less and the opposite cases were only occasionally encountered. The reason may be that there are individual differences in wall thickening,

and that the evaluation was performed in a very narrow range of mm units, which may be prone to measurement errors by the performing physician. Therefore, evaluation by multiple physicians is necessary.

We also examined the presence of MES >1 as the basis of mucosal inflammation of each segment. Based on the results, the sensitivity was acceptable, but the specificity was extremely low. As such, there may be an increase in the possibility of overlooking the presence of inflammation. The data also suggested that our evaluation method could clearly detect mucosal inflammation. Since the evaluation of mucosal blood flow measurements in patients with UC using the color Doppler method has been reported,[12,20,25,26] evaluating this method, in combination with BWT, may also improve accuracy and stratify the degree of mucosal inflammation, so it may be an examination to be considered in the future.

This study has some limitations. One is that the number of cases at each site varies, and the oral intestinal tracts, such as the ascending and transverse colon, have numerous normal mucosa, and the number of inflammatory mucosa increases toward the anal sides. One of the causes of this imbalance could be that we mixed patients with different phenotypes (for example, 82% of patients had pancolitis and 96% of patients enrolled had an active state). This could have led to overestimation of the diagnostic accuracy. Moreover, this imbalance was also thought to be the cause of the dissociation between the accuracy rate and AUC, and the difference in correlation between BWT and endoscopic activity in each segment. To address this, the study targeted a wider patient population (from outpatients to inpatients with clinically severe cases, including those who are hospitalized or those who are in remission) to make the study more in line with real general practice. UC is characterized by its continuity, extending from the rectum to the mouth[1], and it is difficult to increase the number of evaluations of inflammatory mucosa, especially in severe states of the oral colon because in some cases, there is a risk of performing endoscopy itself. With regard to the distal side, it may be possible to solve this problem by increasing the number of examinations in patients in clinical remission states. Furthermore, blinding of tests is also necessary. On the other hand, considering the fact that patients with clinically severe states were also included, AUS images may be useful for assessing severity if other characteristics, such as blood flow, are considered, in addition to wall thickness. However, the range was limited to the observable distal colon on endoscopy.

Another limitation is that this study involved a retrospective analysis. Therefore, there were some various biases, which may be attributed to the possibility of additional treatment modification, incorrect examination period, non-blinding of tests, and the cases not being evaluated by multiple individuals.

Regarding the change in BWT related to the additional treatments and incorrect examination period, a recent report showed that BWT improved in two weeks after successful treatment.[27] Therefore, in cases where drugs with relatively immediate effects, such as infliximab or tacrolimus, were used, the effects of the drug might affect TUS findings if the examination period was prolonged. On the other hand because there was no contrast with endoscopic findings, it was unclear how much the two examinations would affect the results in about two weeks. In our cases, a few patients had an examination period of 14 days,

but the clinical findings, such as stool frequency and blood data, did not change significantly, so they were included in this study. In addition, there were no cases of endoscopic remission or TUS-negative findings due to the effects of treatment during the examination period, and no inflammation findings remained. Therefore, we believe that there would be no significant effect on the examination of the presence or absence of inflammation.

Conclusions

This study is the first to report the possibility of evaluating mucosal inflammation in UC patients by evaluating BWT. Results have shown that the detectability of endoscopic activity is adequate when the criterion for positive cases is set at BWT >2 mm. This minimally invasive and repeatable examination is expected to be useful for evaluating mucosal inflammation and controlling the disease activity of UC. Moreover, this method can provide fast results and can be helpful for treatment strategies in patients with UC. To make this data more accurate and reliable, multicenter prospective studies are necessary. In addition, it is also necessary to evaluate each degree of inflammatory mucosa (MES > 0) and clarify the characteristics by TUS.

Abbreviations

TUS: Transabdominal ultrasonography; UC: Ulcerative colitis; CS: Colonoscopy; BWT: Bowel wall thickness; MES: Mayo endoscopic subscore classification; PPV, positive predictive value; NPV, negative predictive value; US, ultrasonography; S/C, sigmoid colon; D/C, descending colon; T/C, transverse colon; A/C, ascending colon

Declarations

Acknowledgements

This study received no financial support. No potential conflicts of interest relevant to this article are reported.

Authors’ contributions

Conceived and designed the study, analyzed the data, and wrote the paper: MT. Helped design the study, and wrote the paper; SH. Helped design the study ; MO, KT,EY,SI,SY,SO,MH,YY,TI,HK,KH, and HO. Supervised the study: HO. All authors have read and approved the final manuscript.

Funding

This study did not receive any funding support.

Availability of data and materials

The datasets used and/or analyzed during the current study are available from the corresponding author upon reasonable request.

Ethics approval and consent to participate

The institutional review boards of Okayama University Graduate School of Medicine, Dentistry, and Pharmaceutical Sciences (approval number: 1804-030) approved the present study. Written informed consent was obtained from all participants and their parents or guardians.

Okayama University Graduate School of Medicine, Dentistry, and Pharmaceutical Sciences

Consent for publication

Not applicable.

Competing interests

The authors declare that they have no competing interests.

Author details

Department of Gastroenterology and Hepatology,

Okayama University Graduate School of Medicine, Dentistry and Pharmaceutical Sciences,

2-5-1 Shikata-cho, Kita-ku, Okayama 700-8558, Japan

References

1. Head KA, Jurenka JS. Inflammatory bowel disease Part 1: ulcerative colitis--pathophysiology and conventional and alternative treatment options. Altern Med Rev. 2003; 8: 247-283.
2. Ungaro R, Mehandru S, Allen PB, et al. Ulcerative colitis. Lancet. 2017; 389: 1756-1770.
3. Danese S, Fiocchi C. Ulcerative colitis. N Engl J Med. 2011; 365: 1713-1725.
4. Abraham C, Cho JH. Inflammatory bowel disease. N Engl J Med. 2009; 361: 2066-2078.
5. Dignass A, Lindsay JO, Sturm A, et al. Second European evidence-based consensus on the diagnosis and management of ulcerative colitis part 2: current management. J Crohns Colitis. 2012; 6: 991-1030.
6. Damore LJ, 2nd, Rantis PC, Vernava AM, 3rd, et al. Colonoscopic perforations. Etiology, diagnosis, and management. Dis Colon Rectum. 1996; 39: 1308-1314.
7. Levin TR, Conell C, Shapiro JA, et al. Complications of screening flexible sigmoidoscopy. Gastroenterology. 2002; 123: 1786-1792.
8. Menees S, Higgins P, Korsnes S, et al. Does colonoscopy cause increased ulcerative colitis symptoms?. Inflamm Bowel Dis. 2007; 13: 12-8.

9. Hata J, Haruma K, Suenaga K, et al. Ultrasonographic assessment of inflammatory bowel disease. Am J Gastroenterol. 1992; 87: 443-447.
10. Parente F, Greco S, Molteni M, et al. Imaging inflammatory bowel disease using bowel ultrasound. Eur J Gastroenterol Hepatol. 2005; 17: 283-291.
11. Novak KL, Jacob D, Kaplan GG, et al. Point of Care Ultrasound Accurately Distinguishes Inflammatory from Noninflammatory Disease in Patients Presenting with Abdominal Pain and Diarrhea. Can J Gastroenterol Hepatol. 2016; 2016: 4023065.
12. Allocca M, Fiorino G, Bonovas S, et al. Accuracy of Humanitas Ultrasound Criteria in Assessing Disease Activity and Severity in Ulcerative Colitis: A Prospective Study. J Crohns Colitis. 2018; 12: 1385-1391.
13. Bavil AS, Somi MH, Nemati M, et al. Ultrasonographic evaluation of bowel wall thickness and intramural blood flow in ulcerative colitis. ISRN Gastroenterol. 2012; 2012: 370495.
14. Haber HP, Busch A, Ziebach R, et al. Ultrasonographic findings correspond to clinical, endoscopic, and histologic findings in inflammatory bowel disease and other enterocolitides. J Ultrasound Med. 2002; 21: 375-382.
15. Ardizzone S, Cassinotti A, Duca P, et al. Mucosal healing predicts late outcomes after the first course of corticosteroids for newly diagnosed ulcerative colitis. Clin Gastroenterol Hepatol. 2011; 9: 483-489.e3.
16. Pineton de Chambrun G, Peyrin-Biroulet L, Lemann M, et al. Clinical implications of mucosal healing for the management of IBD. Nat Rev Gastroenterol Hepatol. 2010; 7: 15-29.
17. Kinoshita K, Katsurada T, Nishida M, et al. Usefulness of transabdominal ultrasonography for assessing ulcerative colitis: a prospective, multicenter study. J Gastroenterol. 2019; 54: 521-529.
18. Schroeder KW, Tremaine WJ, Ilstrup DM. Coated oral 5-aminosalicylic acid therapy for mildly to moderately active ulcerative colitis. A randomized study. N Engl J Med. 1987; 317: 1625-1629.
19. Parente F, Greco S, Molteni M, et al. Role of early ultrasound in detecting inflammatory intestinal disorders and identifying their anatomical location within the bowel. Aliment Pharmacol Ther. 2003; 18: 1009-1016.
20. Sagami S, Kobayashi T, Aihara K, et al. Transperineal ultrasound predicts endoscopic and histological healing in ulcerative colitis. Aliment Pharmacol Ther. 2020; 51: 1373-1383.
21. Antonelli E, Giuliano V, Casella G, et al. Ultrasonographic assessment of colonic wall in moderate-severe ulcerative colitis: comparison with endoscopic findings. Dig Liver Dis. 2011; 43: 703-706.
22. Dietrich CF. Significance of abdominal ultrasound in inflammatory bowel disease. Dig Dis. 2009; 27: 482-493.
23. Smith RL, Taylor KM, Friedman AB, et al. Systematic review: Clinical utility of gastrointestinal ultrasound in the diagnosis, assessment and management of patients with ulcerative colitis. J Crohns Colitis. 2019.

24. Arienti V, Campieri M, Boriani L, et al. Management of severe ulcerative colitis with the help of high resolution ultrasonography. Am J Gastroenterol. 1996; 91: 2163-2169.
25. Parente F, Molteni M, Marino B, et al. Bowel ultrasound and mucosal healing in ulcerative colitis. Dig Dis. 2009; 27: 285-290.
26. Parente F, Molteni M, Marino B, et al. Are colonoscopy and bowel ultrasound useful for assessing response to short-term therapy and predicting disease outcome of moderate-to-severe forms of ulcerative colitis?: a prospective study. Am J Gastroenterol. 2010; 105: 1150-1157.
27. Maaser C, Petersen F, Helwig U, et al. Intestinal ultrasound for monitoring therapeutic response in patients with ulcerative colitis: results from the TRUST&UC study. Gut. 2019.

Tables

Due to technical limitations, table 1,2,3,4 is only available as a download in the Supplemental Files section.

Figures

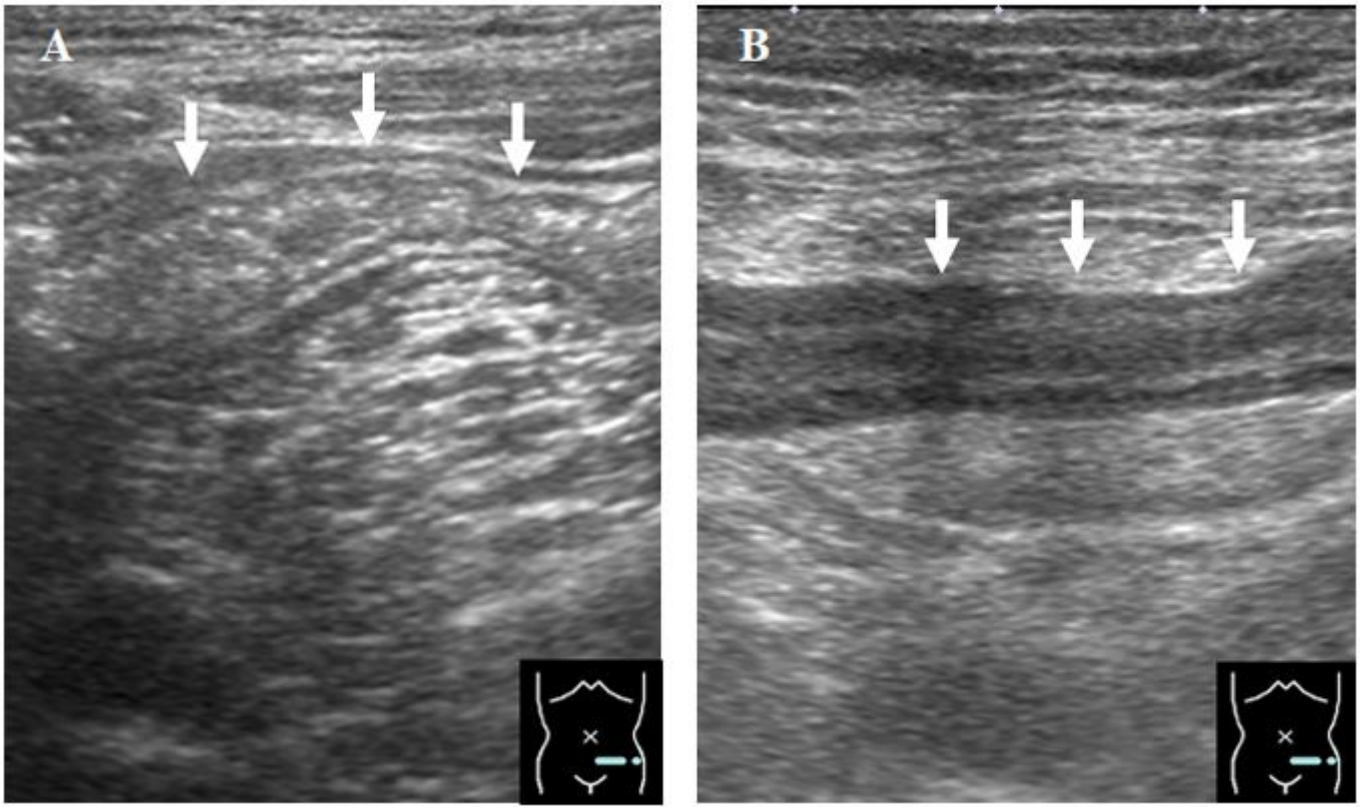

Figure 1

Ultrasonography (US) findings (Sigmoid colon) A: US findings of BMT 1.7 mm B: US findings of BMT 3.7 mm The white arrows indicate the sigmoid colon, while the red arrows indicate a representative measurement method of bowel wall thickness

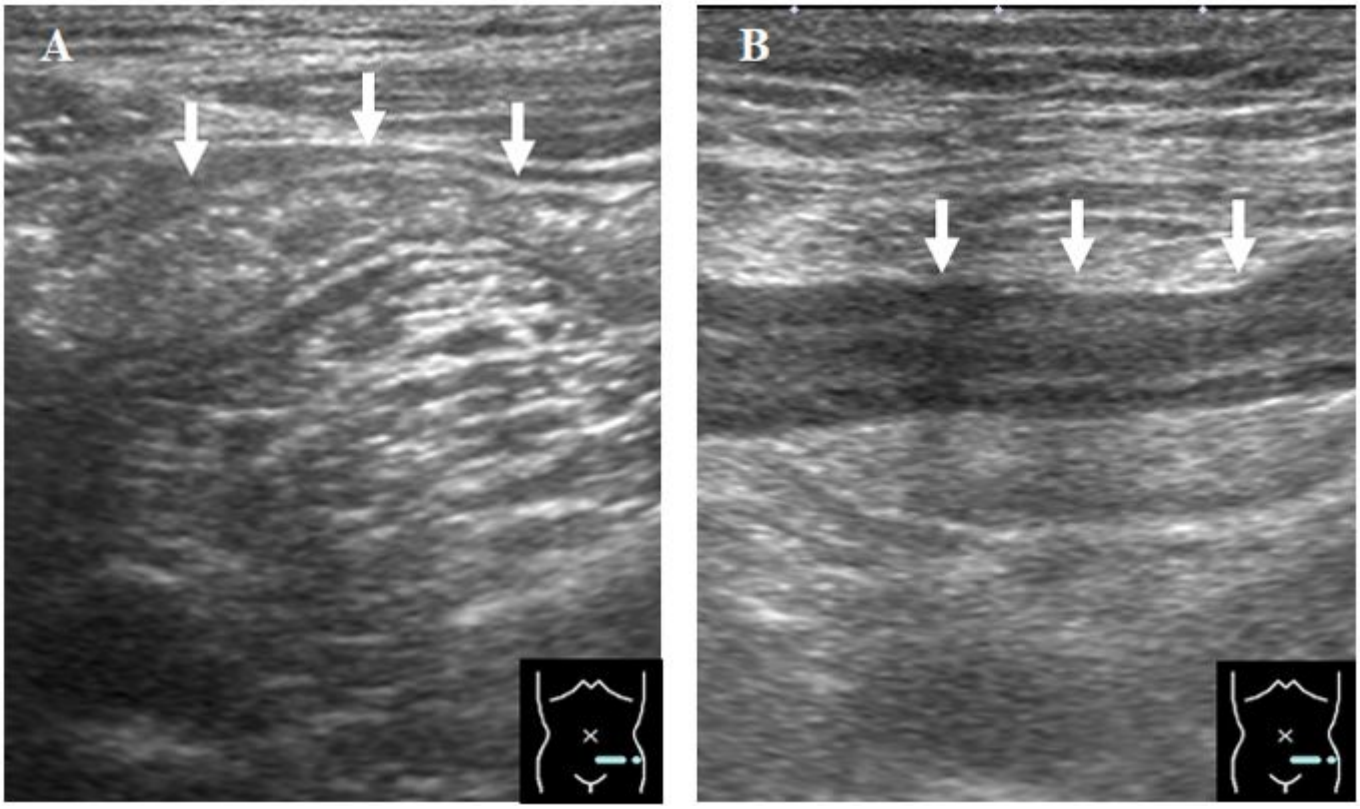

Figure 1

Ultrasonography (US) findings (Sigmoid colon) A: US findings of BMT 1.7 mm B: US findings of BMT 3.7 mm The white arrows indicate the sigmoid colon, while the red arrows indicate a representative measurement method of bowel wall thickness

Image not available with this version

Figure 2

Correlation between BWT and CS findings of each segment in colon BWT was positively correlated with endoscopic activity (Spearman rank correlation coefficient = 0.47-0.84, $p < 0.0001$). The trend of an increase in the proportion of positive results according to increases in MES was statistically significant ($p < 0 .0001$, Cochran-Armitage trend test). A: sigmoid colon (S/C), B: descending colon (D/C), C: left-sided transverse colon (T/C left), D: right-sided transverse colon (T/C right), E: ascending colon (A/C)

Image not available with this version

Figure 2

Correlation between BWT and CS findings of each segment in colon BWT was positively correlated with endoscopic activity (Spearman rank correlation coefficient = 0.47-0.84, $p < 0.0001$). The trend of an increase in the proportion of positive results according to increases in MES was statistically significant ($p < 0.0001$, Cochran-Armitage trend test). A: sigmoid colon (S/C), B: descending colon (D/C), C: left-sided transverse colon (T/C left), D: right-sided transverse colon (T/C right), E: ascending colon (A/C)

Supplementary Files

This is a list of supplementary files associated with this preprint. Click to download.

- UCAUSBMC.supplementary.docx.docx
- UCAUSBMC.supplementary.docx.docx
- UCAUStabel.BMC.docx.docx
- UCAUStabel.BMC.docx.docx