Long-term Outcomes of Cataract Surgery in Patients With Uveitis

Kristina Jevnikar
Department of Ophthalmology https://orcid.org/0000-0001-9688-0601
Saša Počkar
Manchester Royal Eye Hospital
Lan Umek
Faculty of administration, University of Ljubljana, Sovenia
Nataša Vidovic Valentincic (natasa.vidovic-valentincic@guest.arnes.si)
Department of ophthalmology, University medical centre Ljubljana

Research Article

Keywords: cataract, uveitis, phacoemulsification, CME, complications, outcome

Posted Date: March 7th, 2022

DOI: https://doi.org/10.21203/rs.3.rs-1229418/v1

Abstract

Purpose: The aim of this retrospective study was to evaluate the long-term visual outcomes of patients with various etiologies of uveitis, undergoing cataract surgery and to identify possible factors influencing the visual outcome and the rate of postoperative complications.

Methods: Patients who underwent cataract surgery between January 2015 and February 2020 were included.

Results: A total of 102 eyes of 78 patients were included in this study. There was a statistically significant difference in the postoperative BCVA between the groups based on anatomical localization as well as etiology. Standard procedure with phacoemulsification and lens implantation was associated with statistically significant better final BCVA than surgery with an additional iris procedure.

Conclusions: Visual outcome varies between the subtypes of uveitis. Post-operative BCVA correlates strongly with preoperative values; prolonged delay of surgery may not be indicated. Meticulous control of pre-operative inflammation, peri-operative treatment adjustment, and close postoperative follow-up is essential for a favorable outcome.

Introduction

A cataract is an important cause of reversible visual impairment in patients with uveitis. It develops due to a combination of prolonged inflammation and treatment with corticosteroids and affects 50-70% of patients [1–3]. As opposed to age-related cataracts, patients with uveitis tend to be younger, often exhibiting co-pathology such as cystoid macular edema (CME) and elevated intraocular pressure (IOP) [4–8]. Furthermore, the surgery is more challenging due to miotic pupil, posterior synechiae, iris atrophy, zonular weakness, and pupillary membrane [1, 4, 9, 10]. The most common postoperative complications include posterior capsule opacification, cystoid macular edema, recurrent or persistent inflammation, glaucoma, epiretinal membrane, and IOL dislocation 1, 4, 9-13. Since more intra, peri, and postoperative complications are seen, the prognosis is guarded; hence the decision to operate may be delayed [8, 11].

Nonetheless, it has been shown that delaying cataract surgery until best-corrected visual acuity (BCVA) significantly deteriorates may not be indicated, as the preoperative BCVA determines the post-operative BCVA [5]. Since the younger population is affected, an excellent post-operative outcome is very important to diminish the disease burden. It is known that careful management of patients and well-controlled inflammation that needs to be silent for at least three months before the surgery is essential for a desirable outcome [2, 3, 8, 9, 13, 14]. Nevertheless, postoperative outcomes may vary, and it has not yet been fully established why. This study aimed to evaluate the visual outcomes of patients with various etiologies of uveitis undergoing cataract surgery and identify possible factors affecting the visual outcome and the rate of postoperative complications.

Methods

Data collection

Adult patients with uveitis who underwent cataract surgery by a single surgeon at Eye Hospital, University medical center Ljubljana, Slovenia - a tertiary referral center between January 2015 and February 2020 were included in this retrospective observational study. The Slovenian medical ethics committee approved the study (0120-346/2021/3). Patients' medical records were reviewed, and the following data were retrieved: age, gender, pre-existing co-pathology, etiology, anatomical localization of uveitis according to Standardization of Uveitis Nomenclature diagnostic criteria [15], systemic medications prescribed, best-corrected visual acuity (BCVA) according to Snellen chart, intraocular pressure (IOP), type of surgery and postoperative complications.

Peri- and postoperative protocol

All patients received a topical corticosteroid - dexamethasone 0.1% (Dexamono®) and a nonsteroidal anti-inflammatory drug (NSAID) - nepafenac 0.1% (Nevanac®) 3 times daily three days before the surgery. Intravenous systemic corticosteroids were used preoperatively in patients with a complicated course of the disease and expected postoperative complications. Tropicamide was administered 30 minutes before the surgery to dilate the pupil. Standard cataract surgery, defined as phacoemulsification with lens implantation in topical anesthesia, was performed. A 2.2 mm main temporal clear corneal incision and one or more side-port corneal incisions were made. Small pupils and posterior synechiae were managed with synechiolysis, iris retractors, or mechanical devices (Malyugin ring®) as needed. Trypan blue (VisionBlue®) was used to stain the anterior capsule in white cataracts. A 5 mm anterior continuous curvilinear capsulorhexis was followed by hydro dissection, phacoemulsification, and IOL implantation. A hydrophobic intraocular lens was implanted. Dexamethasone implant (Ozurdex®) was used in eyes with a higher risk of developing postoperative cystoid macular edema (CME). Systemic corticosteroids (500 mg of Methylprednisolone daily, starting one day before surgery, three doses in total) were used preoperatively in 8 (7.8%) eyes; 5 of them had panuveitis (3 eyes sarcoidosis, two eyes Behçet's disease), three eyes had idiopathic intermediate uveitis. A single surgeon performed all the surgeries. Routine postoperative treatment consisted of 0.1% dexamethasone phosphate (Dexamono®) tapered slowly over three months and nepafenac 0.1% (Nevanac®) used for three months. Follow-up was performed at one day, one month, six months, one year, and three years postoperatively.

Statistical analysis

Descriptive statistics included mean ± standard deviation (SD) or median with the range as appropriate. Continuous parameters were analyzed using the Mann–Whitney U test and Kruskal-Wallis H test, whereas categorical parameters were analyzed using the chi-squared test. The Wilcoxon sign rank test was used for a change in BCVA after surgery. For prediction of final BCVA based on other analyzed parameters, linear regression was used. All arithmetic calculations on BCVA were performed after conversion to the logMAR scale. Values corresponding to counting fingers, hand movement, light perception, and no light

perception were substituted with 2.10, 2.40, 2.70, and 3.00 logMAR units. Kaplan Maier curve was used to estimate the time to the postoperative occurrence of CME. $P \leq 0.05$ was considered statistically significant. Python 3.8.5 was used.

Results

102 eyes of 78 patients (41 female, 37 male), who underwent cataract surgery by a single surgeon at Eye Hospital, University medical center Ljubljana, a tertiary referral center between January 2015 and February 2020, were included. Baseline demographics and clinical characteristics are presented in Table 1. Patients' mean ± SD (range) age was 58.8 ± 16.7 (20-84). The most common anatomical location of uveitis was intermediate, followed by anterior, posterior and panuveitis. Etiologically most eyes had idiopathic uveitis, followed by HLA-B27 associated uveitis, herpetic uveitis, ocular sarcoidosis, Fuchs' heterochromic iridocyclitis (FHI), juvenile idiopathic arthritis-associated uveitis (JIA), ocular Behçet's disease, toxoplasmosis and rheumatoid arthritis-associated uveitis (RA). Systemic immunosuppression in the form of disease-modifying anti-rheumatic drugs (DMARD) was used in 18 patients (26 eyes, 25.5%), biological drugs were used in 6 patients (6 eyes, 5.9%). Standard cataract surgery was performed in 25 (24.5%) eyes, 64 (62.7%) eyes required an additional iris procedure (iris ring, hooks, or synechioliysis). Ozurdex® was administered in 13 (12.7%) eyes. The mean (SD) of the follow-up was 19.9 (±13.7) months.

Table 1
Baseline characteristics

	No. of eyes	Frequency (%)
Total number of eyes	102	100
Total number of patients	78	
Gender		
Male	37	47.4
Female	41	52.6
Age		
Average (SD)	58.8 (17.2)	
Median (range)	59.5 (20-84)	
Anatomical localization		
Anterior	34	33.3
Inetrmediate	49	48.0
Posterior	9	8.8
Panuevitis	10	8.8
Etiology		
Idiopathic	61	59.8
HLA B27	12	11.8
Sarcoidosis	7	6.9
Herpetic	9	8.8
FHI	5	4.9
Toxoplasmosis	1	1.0
JIA	3	2.9
RA	1	1.0
Behcet	3	2.9
Systemic imunosupression		

FHI, Fuchs' heterochromic iridocyclitis; JIA, juvenile idiopathic arthritis-associated uveitis; RA, rheumatoid arthritis-associated uveitis; DMARD, disease-modifying anti-rheumatic drugs; Phe, phacoemulsification.

	No. of eyes	Frequency (%)
None	70	68.6
DMARD	26	25.5
Biologics	6	5.9
Systemic corticosteroids preoperatively	8	7.8
Type of surgery		
Phe + IOL	25	24.5
Phe + iris procedure	64	62.7
Phe + ozurdex	13	12.7
Follow up (months)		
Average (SD)	19.9 (13.7)	
Median	12	
Interquartile range	24	

FHI, Fuchs' heterochromic iridocyclitis; JIA, juvenile idiopathic arthritis-associated uveitis; RA, rheumatoid arthritis-associated uveitis; DMARD, disease-modifying anti-rheumatic drugs; Phe, phacoemulsification.

Visual acuity according to the anatomical localization and etiology

The worst preoperative BCVA was seen in patients with posterior uveitis, followed by panuveitis, intermediate uveitis, and anterior uveitis. Pre- and postoperative BCVA based on anatomical localization throughout the 3-year follow-up are shown in figure 1. Based on the etiology of uveitis RA was associated with the worst preoperative BCVA (2.3), followed by Behçet's disease (1.7±0.7), Juvenile idiopathic arthritis (JIA) (1.1±1.0), HLA-B27 associated uveitis (1.0±0.9), herpetic uveitis (1.0±0.6), idiopathic uveitis (1.0±0.7), sarcoidosis (0.6±0.4), FHI (0.6±0.5) and toxoplasmosis (0.3).

Postoperatively, the BCVA improved in 88% of patients, remained the same in 7%, and deteriorated in 5%. The median change in visual acuity was -0.4 logMAR (from -2.3 to 0.9) at four weeks postoperatively. The linear regression model has shown that better preoperative BCVA results in better postoperative BCVA ($p<0.05$). 73 (71.5%) eyes achieved BCVA of 0.5 (0.3 logMAR) or better. There were statistically significant differences in the postoperative BCVA between the groups based on anatomical localization ($p=0.00145$) as well as etiology ($p=0.0135$). The probabilities of the BCVA of 0.5 (0.3 logMAR) or better, 0.3 (0.5 logMAR) or worse, and worse than 0.05 (1.3 logMAR) according to the anatomical localization and etiology are presented in Tables 2 and 3. Best outcomes according to the anatomical localization were reported in anterior uveitis, where 91.2% of eyes achieved BCVA better than 0.5. Panuveitis was

associated with a worse prognosis, as 40% of eyes failed to reach BCVA higher than 0,05. Etiologically Behçet's disease and RA were associated with a worse outcome. Standard cataract surgery was associated with significantly better final BCVA than surgery with an additional iris procedure (p=0.007). There was no statistically significant difference in visual outcome between patients receiving DMARDs or biological drugs and patients without systemic therapy. There was no statistically significant difference in final BCVA between the genders.

Table 2
Visual outcomes according to the anatomical localization of uveitis.

Uveitis	BCVA >/= 0,5	BCVA </= 0,3	BCVA </=0,05	total
Anterior	31 (91.2%)	3 (8.8%)	1 (2.9%)	34
Intermediate	32 (65.3%)	15 (30.6%)	7 (14.3%)	49
Posterior	4 (44.4%)	5 (55.6%)	2 (22.2%)	9
Panuveitis	6 (60%)	4 (40%)	4 (40%)	10
BCVA, best corrected visual acuity.				

Table 3
Visual outcomes according to the etiology of uveitis.

Etiology	BCVA >/= 0,5	BCVA </= 0,3	BCVA </= 0,05	total
Herpetic	7 (77.8%)	2 (22.2%)	0	9
Sarcoidosis	6 (85.7%)	1 (14.3%)	1 (14.3%)	7
FHI	5 (100%)	0	0	5
Idiopathic	41 (67.2%)	18 (29.5%)	8 (13.1%)	61
JIA	3 (100%)	0	0	3
HLA B27	10 (83.3%)	2 (16.7%)	2 (16.7%)	12
Toxoplasmosis	1 (100%)	0	0	1
Behçet's disease	0	3 (100%)	2 (66.7%)	3
RA	0	1 (100%)	1 (100%)	1
BCVA, best corrected visual acuity; FHI, Fuchs' heterochromic iridocyclitis; JIA, juvenile idiopathic arthritis-associated uveitis; RA, rheumatoid arthritis-associated uveitis.				

Complications

CME was seen postoperatively in 20 (19.6%) eyes. Eyes with preoperative CME were excluded from this analysis. As for anatomical localization, it was seen in 4 (12.9%) eyes with anterior uveitis, 12 (32.2%) eyes with intermediate uveitis, 1 (14.2%) eye with posterior uveitis, and 3 (30.0%) eyes with panuveitis. Based on etiology, it was seen in 1 (100%) look with RA, 4 (57.1%) eyes with sarcoidosis, 1 (33.3%) eye with JIA, 12 (25.0%) eyes with idiopathic uveitis, 1 (12.5%) look with HLAB27 associated uveitis and 1 (11.1%) eye with herpetic uveitis. None of the patients with FHI, toxoplasmosis, or Behçet's developed CME postoperatively. There was no statistically significant difference between patients receiving preoperative systemic therapy and patients without it (p=0.64). The type of surgery was also assessed. CME was seen in 4 eyes after standard cataract surgery and 14 with an additional iris procedure. However, the difference was not statistically significant (p=0.36). Increased IOP within four weeks postoperatively was seen in 4 (3.9%) eyes, 2 of which required trabeculectomy due to secondary glaucoma. Posterior capsule rupture was seen in 2 (1.9%) cases.

Discussion

A cataract is an important source of reversible visual impairment in patients with uveitis [1–3]. Surgery can be technically challenging with more intra- and post-operative complications. Compared with age-related cataracts, the final BCVA tends to be worse, and the prognosis is generally guarded [5]. Uveitis is a heterogeneous condition that encompasses several anatomical locations and etiologies, affecting the final BCVA. In previous studies, idiopathic anterior uveitis and FHI were the most common subtypes 9. However, the most common anatomical subtype in our study was intermediate uveitis, possibly because we are the tertiary referral center. The final BCVA of 0.5 or higher was achieved in 71.5% of eyes which is comparable to previously reported data, where the final BCVA ranged from 47–87.3% [2–4, 9, 10, 12, 14, 16]. The highest percentage of eyes achieving BCVA 0.5 or better was seen in anterior uveitis, which is in line with previous reports [2, 4, 9, 10, 14, 16]. However, 65.3% of patients with intermediate uveitis achieved BCVA 0.5 or better, which is better than previously reported. As we are the tertiary referral center, all the patients with intermediate uveitis in the country needing surgery are seen at our clinic, so the timing of surgery is carefully chosen, and the treatment optimized. Hence, we believe the results reflect the meticulous pre-and post-operative care. The increased range of medications available to treat complicated cases, such as biological drugs, may also play a role. Only 44.4% of patients with posterior uveitis achieved BCVA better than 0.5, which can be explained by preexisting pathology affecting VA, as advanced serpiginous uveitis affecting the macula was present in four of those patients, and three patients had preexisting severe macular degeneration. Therefore, we believe these results do not reflect the effect of the cataract surgery on the visual outcome. Etiologically the best results were seen in FHI, herpetic uveitis, HLA B27, and toxoplasmosis. A similar distribution was seen in previous studies [4, 7, 9, 10, 14]. It is important to note that most cases with idiopathic uveitis also reached BCVA 0.5 or better. As previously reported, the worst outcome was seen in Behçet's disease and surprisingly also in RA. In those cases, the low preoperative BCVA could have a role, as our linear regression model shows, that preoperative BCVA strongly correlates with postoperative BCVA, which is in line with previously reported data [5]. Therefore, delaying the surgery until BCVA drops significantly may not be indicated. Post-

operative CME was observed in 19.6%, comparable to previously published data [4, 9, 10, 14]. Increased IOP was detected in 3.9% of cases, which is in line with previously published studies, where it was reported in 4,6-8,4% of cases [7, 9, 17]. Close monitoring of IOP and prompt intervention are essential in preventing secondary glaucoma. The impact of the type of surgery on the outcome has also been evaluated. Iris manipulation led to higher rates of CME and worse final BCVA, but the results were not statistically significant, possibly due to the small sample size. Oates et al. have noticed that iris hook insertion is related to more postoperative inflammation, which could explain these results [10]. One study has shown that perioperative systemic medications pose a risk for postoperative CME; however, in our study, the final BCVA or CME presence were not statistically significantly different between patients receiving preoperative systemic therapy and patients without it [1]. This probably reflects good preoperative management and optimal pre-and postoperative inflammation control.

Conclusion

Cataract surgery in patients with uveitis may be technically more challenging but is a safe, vision-improving procedure if appropriately planned. Considering post-operative BCVA correlates strongly with preoperative values, prolonged delay of surgery may not be indicated, especially considering that the younger population is predominantly affected. The visual outcome varies between the subtypes of uveitis. Meticulous control of pre-operative inflammation, peri-operative treatment adjustment, and close postoperative follow-up are essential for a favorable outcome.

Declarations

Compliance with Ethical Standards

The study received no funding.

Ethical approval: All procedures performed in studies involving human participants were in accordance with the ethical standards of the national research committee and with the 1964 Helsinki declaration and its later amendments or comparable ethical standards. The Slovenian medical ethics committee approved the study (0120-346/2021/3).

Informed consent: Informed consent was obtained from all individual participants included in the study.

None of the authors has any financial/conflicting interests to disclose.

Author contributions: All authors contributed to the study conception and design. Material preparation, data collection and analysis were performed by Kristina Jevnikar, Saša Počkar, Lan Umek and Nataša Vidovič Valentinčič. The first draft of the manuscript was written by Kristina Jevnikar and all authors commented on previous versions of the manuscript. All authors read and approved the final manuscript.

References

1. Zhang, Y.; Zhu, X.; He, W.; Jiang, Y.; Lu, Y., Efficacy of cataract surgery in patients with uveitis: A STROBE-compliant article. *Medicine (Baltimore)* **2017,** *96* (30), e7353.
2. Chan, N. S.-W.; Ti, S.-E.; Chee, S.-P., Decision-making and management of uveitic cataract. *Indian J Ophthalmol* **2017,** *65* (12), 1329-1339.
3. Sharief, L.; Lightman, S.; Baltinas, J.; Tomkins-Netzer, O., Long-term effect of cataract phacoemulsification on the inflammation control and clinical outcome in uveitis patients(). *Clin Exp Ophthalmol* **2018,** *46* (9), 1048-1054.
4. Balta, O.; Sungur, G.; Acar, M. A.; Kosker, M.; Yakin, M.; Ornek, F., Long-term results of cataract surgery in patients with anterior uveitis. *International Ophthalmology* **2018,** *38* (4), 1399-1407.
5. Chu, C. J.; Dick, A.D.; Johnston, R. L.; Yang, Y. C.; Denniston, A. K., Cataract surgery in uveitis: a multicentre database study. *Br J Ophthalmol* **2017,** *101* (8), 1132-1137.
6. Jones, N. P., The Manchester Uveitis Clinic: The first 3000 patients, 2: Uveitis Manifestations, Complications, Medical and Surgical Management. *Ocul Immunol Inflamm* **2015,** *23* (2), 127-34.
7. Mehta, S.; Linton, M. M.; Kempen, J. H., Outcomes of cataract surgery in patients with uveitis: a systematic review and meta-analysis. *Am J Ophthalmol* **2014,** *158* (4), 676-692.e7.
8. Moshirfar, M.; Somani, A. N.; Motlagh, M. N.; Ronquillo, Y. C., Management of cataract in the setting of uveitis: a review of the current literature. *Curr Opin Ophthalmol* **2020,** *31* (1), 3-9.
9. Pålsson, S.; Andersson Grönlund, M.; Skiljic, D.; Zetterberg, M., Phacoemulsification with primary implantation of an intraocular lens in patients with uveitis. *Clin Ophthalmol* **2017,** *11*, 1549-1555.
10. Ozates, S.; Berker, N.; Cakar Ozdal, P.; Ozdamar Erol, Y., Phacoemulsification in patients with uveitis: long-term outcomes. *BMC Ophthalmol* **2020,** *20* (1), 109.
11. Llop, S. M.; Papaliodis, G. N., Cataract Surgery Complications in Uveitis Patients: A Review Article. *Semin Ophthalmol* **2018,** *33* (1), 64-69.
12. Chiu, H.; Dang, H.; Cheung, C.; Khosla, D.; Arjmand, P.; Rabinovitch, T.; Derzko-Dzulynsky, L., Ten-year retrospective review of outcomes following phacoemulsification with intraocular lens implantation in patients with pre-existing uveitis. *Can J Ophthalmol* **2017,** *52* (2), 175-180.
13. Chen, J. L.; Bhat, P.; Lobo-Chan, A.-M., Perioperative Management of Uveitic Cataracts. *Adv Ophthalmol Optom* **2019,** *4*, 325-339.
14. AlBloushi, A. F.; Alfawaz, A. M.; Al-Dahmash, S. A.; Al Owaifeer, A. M.; AlEnezi, S. H.; Al-Fakhri, A. S.; Gikandi, P. W.; Abu El-Asrar, A. M., Incidence, Risk Factors and Surgical Outcomes of Cataract among Patients with Uveitis in a University Referral Hospital in Riyadh, Saudi Arabia. *Ocul Immunol Inflamm* **2019,** *27* (7), 1105-1113.
15. Jabs, D. A.; Nussenblatt, R. B.; Rosenbaum, J. T., Standardization of uveitis nomenclature for reporting clinical data. Results of the First International Workshop. *Am J Ophthalmol* **2005,** *140* (3), 509-16.
16. Cerqueira, P. M. G.; Silva, F.; Carricondo, P. C.; Olivalves, E.; Hirata, C. E.; Yamamoto, J. H., Outcomes of phacoemulsification in patients with uveitis at a tertiary center in São Paulo, Brazil: a review of cases

from 2007 to 2012. *Arq Bras Oftalmol* **2017,** *80* (2), 104-107.

17. Kawaguchi, T.; Mochizuki, M.; Miyata, K.; Miyata, N., Phacoemulsification cataract extraction and intraocular lens implantation in patients with uveitis. *J Cataract Refract Surg* **2007,** *33* (2), 305-9.

Figures

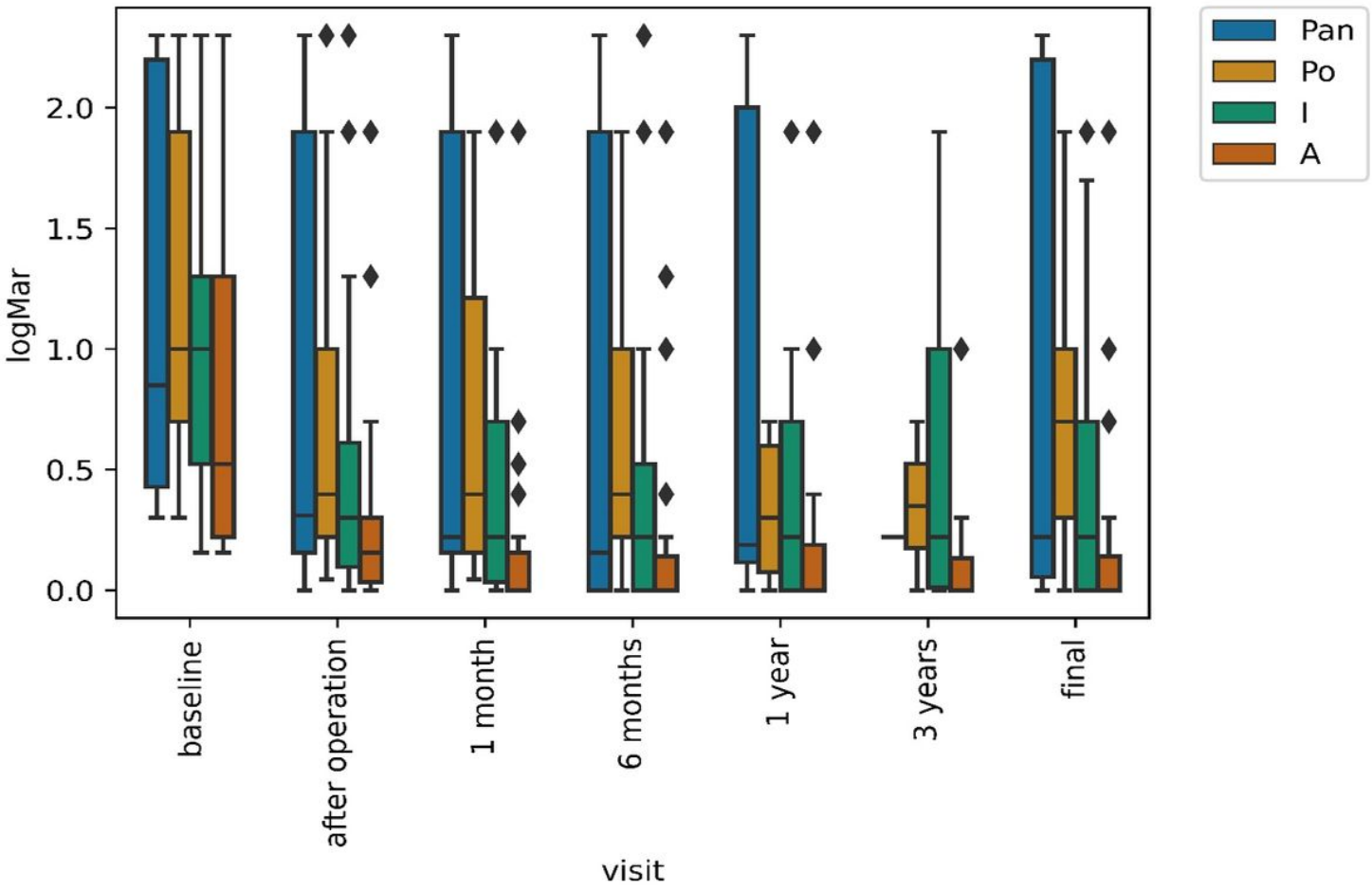

Figure 1

Pre- and postoperative best corrected visual acuity based on anatomical localization throughout the 3-year follow-up.