A Comparison of Cylindrical and Tapered Stem Designs in Femoral Revision Hip Arthroplasty

Yu Zhang
Xuzhou Medical College Affiliated Hospital
Ye Zhang
Xuzhou Medical College Affiliated Hospital
Jian-Ning Sun
Xuzhou Medical College Affiliated Hospital
Zi-Jian Hua
Hebei Medical University Third Affiliated Hospital
Xiang-Yang Chen (xzchenxiangyang@163.com)
https://orcid.org/0000-0001-7376-6179
Shuo Feng
Xuzhou Medical College Affiliated Hospital

Research article

Keywords: femoral revisions hip arthroplasty cylindrical stem tapered stem complications

Posted Date: January 23rd, 2020

DOI: https://doi.org/10.21203/rs.2.21732/v1

Version of Record: A version of this preprint was published on June 29th, 2020. See the published version at https://doi.org/10.1186/s12891-020-03461-5.

Abstract

Background Both cylindrical and tapered stems are commonly used in revision total hip arthroplasty, it is unclear whether the geometry of prosthesis stem has an effect on the patient's efficacy and prognosis. we assume the tapered stem is superior to the cylindrical stem for better clinical outcome. Methods A multicenter review of 120 femoral revisions with Paprosky I, II and III defects using cylindrical stem (54 hips) or tapered stem (66 hips) was performed with an average follow-up of 6 years. Demographic data was comparable between groups. Results There were no significant group differences were found in surgery time, bleeding volume and the postoperative Harris score, the level of overall satisfaction, 8-year cumulative survival. However, intraoperative fractures in the tapered group (4.5%) occurred significantly less than in the cylindrical group (14.8%), and stem subsidence was significantly less in the tapered group (2.17mm) than in the cylindrical group (4.17 mm). There was a higher ratio of bone repair and lower bone loss in the tapered group compared to the cylindrical group. The postoperative thigh pain rate was higher in the cylindrical group (12.9%) than in the tapered group (4.5%). Conclusion Both cylindrical stem and tapered stem can achieve satisfactory mid-term clinical results in revision THA; The tapered stem has better bone restoration of proximal femur, low incidence of intraoperative fracture, and low postoperative thigh pain rate compared with the cylindrical stem.

Introduction

Total hip arthroplasty (THA), as one of the most successful operations in the 20th century, can significantly reduce pain, improves function and corrects deformities, thereby improving patient quality of life. With the increase of primary total hip arthroplasty worldwide and the trend of younger, the number of cases requiring revision hip arthroplasty is increasing due to aseptic loosening, fracture and dislocation of prosthesis. The Swedish Hip Replacement Registry recently reported that the percentage of revisions has more than tripled since the 1990s[1]. Due to the loss of bone mass in the proximal femur, and depending on the quantity and quality of the remaining host bone, femoral stem revision can be challenging. Richard and other scholars believe that the four main objectives of femoral revision are to achieve long-term implantation and fixation, improve the quality of life of patients, reduce complications and maintain or restore the bone mass of proximal femur [2].

Cemented prostheses are mostly used in Europe in early femoral revision of total hip joint. However, due to severe bone defect and sclerosis of medullary cavity, the anchorage between cement and bone cortex decreases, which leads to higher early loosening rate and is gradually abandoned[3-5]. At present, more attention has been paid to the application of biological long-stem prosthesis in revision surgery. In North America, extensive coated cylindrical stem is widely used. The distal part of the prosthesis is cylindrical. And the prosthesis can cross the defective area of proximal femoral. With the help of the close compression between the prosthesis and the distal femoral medullary cavity, the initial rotation stability and axial stability of the prosthesis can be obtained, thus creating conditions for secondary bone growth. A large number of studies have shown that good clinical and imaging results can be obtained when

extensively coated cylindrical stem is used in revision THA[2, 6, 7].However, some scholars reported such prostheses with severe post-operative thigh pain (8% - 9%) and severe stress shielding of proximal femur (6% - 7.6%) [2]. In some patients with Paprosky III type femoral defects, the failure rate of these femoral stems is high[8].

Another widely used cementless prosthesis for femoral revision was first reported by Wagner. The distal stem is tapered geometric design. It has eight sharp lateral ridges on the surface and grooves formed by adjacent lateral ridges. It has been widely used in Europe and has been reported that the tapered stem can reduce the incidence of bone resorption caused by stress shielding in the proximal femur and has a good spontaneous bone regeneration in the proximal femur. Gutierrez et al.[9] suggested that spontaneous bone repair in proximal femur may be related to tapered design, titanium alloy material and good biocompatibility of rough surface. However, some scholars have reported that the tapered stem prosthesis has a high rate of subsidence and dislocation. The femoral prosthesis subsidence occurs in up to 35% [10]of patients.

Therefore, in the revision of hip femoral prosthesis, the effect of the geometry of the prosthesis on the long-term clinical outcome of patients is still unclear. At present, although there are many reports on the clinical efficacy of single stem, there are few studies on the mid-and long-term clinical results of two different geometric shapes of stem. This retrospectively study was to comparing the mid-and-long term clinical outcomes, imaging results postoperative complications and survivorship of cylindrical stem and tapered stem prosthesis for femoral revision to explore whether the tapered distal geometry of femoral prosthesis is superior to that of cylindrical stem.

Materials And Methods

2.1 Patient Selection

Patients who underwent revision THA with extensive coated cylindrical stem (Solution stem, DePuy, USA) and extensive coated tapered stem (Wagner SL, Zimmer, USA) in two institutions from January 2009 to June 2018 were reviewed. This retrospective study was approved by the Ethical Committee of our institution, and we confirm that all methods were performed in accordance with the relevant guidelines and regulations. Informed consent was obtained from all patients.

A total of 127 patients were initially identified. 7 patients (8 hips) were lost to follow-up and 5 patients (5 hips) died of causes unrelated to their operation. The remaining 120 hips (115 patients) were analyzed. According to the type of femoral prosthesis, the patients were divided into cylindrical group (54 hips) and tapered group (66 hips). The general data of the two groups were shown in Table 1. There was no significant difference in preoperative data between the two groups and the two groups were comparable.

2.2 Surgical methods

The two groups were treated with the same perioperative measures, including the use of antibiotics and the prevention of venous thrombosis. Preparation for skin test of antibiotics and intravenous drip half an hour before operation. All patients received general anesthesia and were incised through the original posterolateral approach and prolonged appropriately. When it is difficult to remove the femoral prosthesis, extended trochanteric osteotomy (ETO) is used. After operation, the affected limb maintained abduction neutral position, and the drainage tube was removed 24-48 hours after operation. The routine blood test, ESR, CPR and Postoperative double hip joint radiographs were reviewed. After awake anesthesia, patients were instructed to exercise quadriceps femoris isometric contraction and ankle flexion and extension. Under the guidance of physiotherapist on the second day after operation, partial weight-bearing was mobilized, and the whole body weight-bearing was allowed within 6 weeks. The patients who suffered from fracture during operation were treated with steel wire bandage or internal fixation plate. They were confined to bed for 6 weeks and delayed to go to the ground. According to the reexamination, the patients were delayed to go to the ground to bear weight. All patients were followed up regularly before operation, 6 weeks, 3 months, 6 months after operation, and every year thereafter to evaluate the pain, hip function and imaging results.

2.3 Clinical Assessment

Pain, range of motion, walking, stair climbing, limping and daily activity were assessed by hip Harris score before and during each follow-up. Visual Analogue Scale (VAS) was used to evaluate the degree of thigh pain before and after operation. Telephone and email investigations for patients who cannot go to the hospital after surgery. At each follow-up, patients' satisfaction with surgical results was subjectively divided into five levels[11]: very unsatisfactory, unsatisfactory but tolerable, neutral, satisfied and very satisfied. Data from the last follow-up were used in the analysis. The operation time, bleeding volume (intraoperative bleeding + postoperative drainage), blood transfusion volume, hospitalization time and complications (intraoperative fracture, periprosthetic fracture, dislocation, infection, ectopic ossification) were recorded.

2.4 Radiographic Assessment

The bone defect of femur was evaluated by Paprosky classification[12]. Comparing the initial X-ray with the final X-ray to evaluate the prosthesis subsidence, Callaghan et al.[13] measurement method was used to evaluate the prosthesis subsidence by measuring the vertical movement distance between the top of femoral prosthesis and the greater trochanter. The stability evaluation of femoral prosthesis is based on the standard assessment proposed by Engh et al[6]. It can be divided into bone ingrowth fixation, stable fibre fixation and unstable prosthesis. Changes in proximal femoral bone reserve were classified according to the criteria described by Bohm and Bischel[14]: A (increasing defects), B (constant defects) or C (osseous restoration). To evaluate the difference in the proximal femoral bone stock between the initial postoperative and most recent follow up radiographs. If a difference was noted, the dates of the radiographs were revealed to ascertain if this represented Type A or Type C. Stress shielding assessed by Engh and Bobyn methods[15]. (Degree I: the femoral calcar becomes round and blunt, the bone density

decreases, and the femoral calcar atrophy. Degree II: on the basis of Degree I, the reduction of bone mineral density involves the trochanter. Degree III: bone mineral density of the proximal isthmus decreased. Degree Ⅳ: the cortical bone density extending to isthmus decreased.)

The radiographic assessments were interpreted by one fellowship-trained academic musculoskeletal radiologist, who had 20 years of experience in interpreting hip X-Ray examinations. Engh and associates[16] reported on the reliability of radiographic evaluation for femoral bone loss and noted a J value of 0.58 for interobserver reliability and a J value of 0.74 for intraobserver reliability.

2.5 Statistical Analysis

The data and charts were analyzed and processed by IBMS PSS Statistical 19.0 statistical software. Continuous variables were analyzed using independent sample T test. Categorical variables were analyzed using the Pearson chi-square or Fisher exact tests. Kaplan-Meier survivorship analyses were used with the endpoint defined as any reoperation due to septic or aseptic complications. Test level was set at both sides α =0. 05, $P < 0.05$ was considered statistically significant.

Results

3.1. Basic conditions of surgery.

There was no significant difference between the two groups in operation time, hospitalization time, blood loss and blood transfusion. ($P > 0.05$). The comparison of intraoperative data between the two groups was shown in Table 2.

3.2. Clinical Results

120 patients were followed up with an average of 74.8 months(12-114months). At the last follow-up, the Harris hip score in the cylindrical group increased from 41.1±6.1 to 84.3±4.4 ($P < 0.05$), the tapered group increased from 40.1±6.6 to 85.5±3.8 ($P < 0.05$), the VAS score in the cylindrical group decreased from 7.6±1.6 to 2.0±0.4 ($P < 0.05$), and the tapered group decreased from7.5±1.2 to 1.8±0.2 ($P < 0.05$). At the last follow-up, there was no significant difference in Harris score ($P > 0.05$), but VAS score of cylindrical group was higher than that of tapered group. ($P=0.047$). (Figure. 1) There was no significant difference between cylindrical group (87.3%) and tapered group (90.1%) in the overall satisfaction of the recent follow-up results. (Table 3)

3.3. Radiographic Results

At the last follow-up, prosthesis subsidence in cylindrical group was 0-15 mm, with an average of (4.17 ± 4.20) mm, and in tapered group was 0-8 mm, with an average of (2.17 ± 1.49) mm (Figure. 2). There was significantly difference between cylindrical group and tapered group in prosthesis subsidence. All prosthesis subsidence stopped within 1 year after operation.

In the cylindrical group, 45 (84.1%) were fixed by bone growth, 7 (13.0%) were fixed by fibers and 1 (1.8%) was unstable. In the tapered group, 64 (98.4%) were fixed by bone growth, 1 (1.5%) was fixed by fibers and 1 (1.6%) was unstable. Compared with the tapered group, the failure rate of osseointegration (fibrous or unstable) in the cylindrical group was significantly higher ($P < 0.05$).

In the imaging changes of proximal femoral host bone, the proportion of bone repair type in the tapered group (39.4%) was significantly higher than that in the cylindrical group (7.4%) and the proportion of bone loss type in the tapered group (13.6%) was significantly lower than that in the cylindrical group (43.6%).Table 4

In the cylindrical group, 21 hips (38.9%) had stress-shielded bone resorption of degree I and degree II in the greater trochanter, which was manifested by femoral moment atrophy or cortical bone mineral density decreased from sharply blunt margin to trochanter level. However, in the tapered group, 9 hips (13.6%) had stress-shielded bone resorption of degree I and degree II in the greater trochanter.

3.4. Survivorship

The 8-year cumulative survival rate was defined as the end point of any reoperation due to septic or aseptic complications. The 8-year cumulative survivorship of the cylindrical stem was 94.43%, (95% confidence interval [CI], 86.13%-97.82%) and the 8-year cumulative survivorship of the tapered stem was 96.69% (95% confidence interval, 91.39%-98.75%). There was no significant difference between the two groups (Figure. 3).

3.5. Postoperative complications

In the cylindrical group, 8 cases (14.8%, Figure.4) had intraoperative fractures, while 3 cases (4.5%, Figure.5) in the tapered group. There was significantly difference between the two groups (P0.05). In the cylindrical group, 5 cases were femoral trochanteric fractures (with steel wire binding), 3 cases occurred in the femoral shaft (with steel wire binding), all fractures were healed. In the tapered group, 3 cases had femoral shaft fracture (with steel wire binding), and the fracture healed after operation.

There were 2 cases (3.7%) of periprosthetic fracture in cylindrical group and 1 case (1.5%) of periprosthetic fracture in tapered group ($P > 0.05$). Periprosthetic fractures were treated with open reduction and internal fixation.

There were 2 cases (3.7%) of hip dislocation in cylindrical group after operation. One patient underwent cup exchange with recurrent instability, while the other 1 was treated with closed reduction, regaining hip stability. Two cases (3.0%) of hip dislocation occurred in the tapered group ($P > 0.05$). One case of frequent dislocation after closed reduction was treated with replacement of lining and femoral head size.

One hip in cylindrical group was revised due to osteolysis around the cup at 9 years after surgery (Figure.6). The last follow-up radiography showed osteolysis around the cup and Cup revision arthroplasty carried out for an osteolytic lesion.

Postoperative thigh pain: 3 of 66 hips in tapered group had mild thigh pain (VAS score l-3), but most of the symptoms disappeared one year after operation; 7 of 54 hips in cylindrical group had mild thigh pain (VAS score 1-4), of which 2 developed persistent thigh pain.

Discussions

Total hip arthroplasty (THA) is a very successful surgery for relieving pain and restoring function in patients with advanced hip disease. However, complications, including prosthetic loosening, infection and fracture, may require revision surgery. Preoperative planning and appropriate implant selection are critical for successful and lasting outcomes of THA revision. Damaged femurs usually have very little support at the proximal metaphysis, but only limited support in the diaphysis. Severe femoral defects and changes in the shape of the femur pose challenges to adequate fixation in revision total hip arthroplasty.

During the revision of the non-cemented femoral prosthesis, there will be different degrees of prosthesis subsidence after the operation, and most of them occur in the first year after the operation. The main reason is the insufficient pressure between the prosthesis and the femoral medullary cavity during the operation, and the subsidence can occur when the weight is loaded after the operation. In this study, femoral prosthesis with cylindrical stem and femoral prosthesis with tapered stem also had different degrees of subsidence after operation. At the last follow-up, the average subsidence of the tapered group was 2.17 mm (0-8 mm), which was significantly improved compared with the cylindrical group 4.17 mm (0-15 mm). All prosthesis subsidence stopped within one year after operation. This may be in the process of the stem sinking, with the increase of the diameter of the proximal end of the tapered stem, the fixed strength of the tapered stem will be greater, and the tapered stem needs higher load than the cylindrical stem to produce settlement. Robert [17] reported that implantation of a 3 cm segmental bone model into the prosthetic stem produced a 150-micron displacement. The average load of the tapered stem was higher than that of the cylindrical stem (393N VS 221N). For tapered shank with 3cm segment, the average load of failure (>4mm settlement) is also higher (1574N VS 500N). The tapered shank requires a complete segment of at least 1.5-2.5 cm to obtain sufficient initial stability. In the case of severe bone loss, the reconstructed tapered stem has better initial fixation stability than the cylindrical stem. In the biomechanical comparison of tapered and cylindrical distal geometric structures in cadaveric models, the axial and rotational displacements of tapered designs are smaller when they are subjected to synchronous axial and torsional loads.

The stress shielding effect around prosthesis has attracted more and more attention in the widely coated cylindrical stem. In this study, stress-shielded bone resorption of degree I and degree II were also observed in 21 hips of the cylindrical group. Kang [7] reported the revision of 45 hips with widely coated cylindrical stem. The average follow-up period was 12 years. The incidence of bone resorption in proximal femur was 59.6% in 3 years, 65.4% in 5 years and 67.3% in 10 years. Engh [18]found that proximal femoral bone resorption occurred more frequently in women, patients with low cortical index and larger diameter femoral stem. Weeden [19]suggested that severe proximal femoral bone resorption was associated with preoperative osteoporosis and the use of large diameter femoral stem. The shape of prosthesis is an

important factor to determine the degree of stress shielding. Tapered design femoral stem can be wedged into femur to achieve stability. This kind of prosthesis can effectively reduce the stiffness of the prosthesis compared with the cylindrical stem fixed by the backbone rubbing. The degree of stress shielding is lighter and the stress distribution of the proximal femur is higher.

Spontaneous reconstruction of the proximal femur accompanied by early bone mass recovery in revision THA with taper stem has been reported in the mid-and long-term follow-up study[20]. In the imaging changes of proximal femoral host bone of this study, the proportion of bone repair type in tapered group (39.4%) was significantly higher than that in cylindrical group (7.4%) and the proportion of bone loss type in tapered group (13.6%) was significantly lower than that in cylindrical group (43.6%). Sandiford [21] reported 104 patients who underwent Wagner SL femoral stem revision were followed up for 2 years. Bone remodeling rate was 47%. Bone remodeling could be observed as early as 3 months after operation, and no bone resorption occurred in the proximal femur. Regis[20] reported 41 patients with Wagner SL femoral stem revision were followed up for an average of 13.9 years. 63.9% of the patients showed proximal femoral bone remodeling. And 94.4% of the cortical bone thickness did not decrease at the last follow-up compared with that immediately after surgery. Gutierrez [22] suggested that the spontaneous bone repair of proximal femur may be related to factors such as the tapered shape of Wagner SL prosthesis and the material of titanium alloy. According to Wolff's law, the growth of bone is affected by mechanical stimulation and its structure is changed. Stress shielding can lead to bone resorption and remodeling. A study [23]have shown that under the same degree of bone defect, the stress distribution of the tapered group is higher than that of the cylindrical group in the bone defect area, which may be conducive to bone reconstruction at the proximal femoral bone defect area. The stress of the widely coated cylindrical stem in the bone defect area is lower, which may lead to bone resorption in the bone defect area and aggravate bone loss in the proximal femur.

Another controversy over the cylindrical stem is thigh pain. In this study, 7 (12.9%) of the 54 hips in the cylindrical group developed mild thigh pain (VAS score 1-4) during walking down after surgery, and 2 of them developed persistent thigh pain. In the tapered group, 3 of 66 hips (4.5%) had mild thigh pain (VAS score l-3) while walking down after surgery, but most of the symptoms disappeared after one year. Kang[7] reported that 45 hip revision patients were followed up for an average of 12 years. The incidence of thigh pain was initially 15.6%. The pain disappeared 3 years after operation. Paprosky[24] reported that patients with osteoporosis and femoral bone deficiency were more likely to have thigh pain. Some scholars [7] believes that there are two main reasons for thigh pain: insufficient stability of prostheses and stiffness mismatch between bone prostheses. The former usually causes pain immediately after weight-bearing exercise. However, most of them will improve within 2 years, possibly due to internal fixation of stable fibers in the stem. The latter often manifests pain at the end of the prosthesis and is post-motion rather than initial. He speculates that this is due to a stiffness mismatch between the bone and the prosthesis. In material mechanics, the product of elastic modulus of material and geometric properties of corresponding cross-section is expressed as stiffness. In this study, the fibrous fixed in the cylindrical group (13.0%) was significantly higher than that in tapered group (1.5%). Not only that, in this study, the

cylindrical stem is cobalt-chromium alloy and the tapered stem is titanium alloy. The stiffness of cobalt-chromium alloy prosthesis (diameter < 15mm) is 3-5 times that of femoral shaft. Its elastic modulus is 2 times that of titanium alloy. Cobalt-chromium alloy prosthesis shows greater stiffness than titanium alloy prosthesis[25, 26]. Moreover, the stress distribution is related to material properties and geometric shape of the object. It can explain the reason why the cylindrical stem is more frequent than the tapered stem in the occurrence of post-operative persistent thigh pain.

We acknowledge some limitations of this study. First, this is a non-randomized retrospective study of patients treated by different surgeons in different institutions. I know the article usually prefers a minimum of 2 years follow up on all patients. We think 12 months is adequate to determine subsidence and outcomes. Second, the implants from two different manufacturers were used in this study. The cylindrical stem is cobalt-chromium alloy and the tapered stem is titanium alloy. And this study failed to control the materials confounding factor. The influence of material factors on the results cannot be excluded. The study should consider a multivariate analysis to control for bone loss classification, BMI, age, etc when reporting outcome metrics. Finally, the settlement measured by imaging markers may not be as accurate as other techniques.

We conclusion that both cylindrical stem and tapered stem can achieve satisfactory mid-term clinical results in revision THA; The tapered stem has better bone restoration of proximal femur, low incidence of intraoperative fracture, and low postoperative thigh pain rate compared with the cylindrical stem.

Abbreviations

THA Total hip arthroplasty ETO extended trochanteric osteotomy

VAS Visual Analogue Scale

Declarations

Ethics approval and consent to participate

This study was approved by the Ethics Committee of the Affiliated Hospital of Xuzhou Medical University and in accordance with the standards of the National Research Council. Written informed consent was obtained from all participants.

Consent for publication

Not applicable.

Availability of data and materials

We do not wish to share our data, because some of patient's data regarding individual privacy, and according to the policy of our hospital, the data could not be shared to others without permission.

Competing interests

The authors declare that they have no competing interests.

Funding

The author(s) received no financial support for the research, authorship, and/or publication of this article.

Authors' contributions

Yu Zhang did the study, analyzed the data, and wrote the manuscript. Ye Zhang, Jian-Ning Sun, Zi-Jian Hua, Shuo Feng, Xiang-Yang Chen were involved in the design, data management, and analysis of the study. Ye Zhang, Jian-Ning Sun, Zi-Jian Hua, Shuo Feng, Xiang-Yang Chen were involved in the study design, and data analysis. All authors read and approved the final manuscript.

Acknowledgements

We would like to acknowledge the helpful comments on this paper received from our reviewers.

References

1. Garellick G, Rogmark C, Rolfson O. The Swedish Hip Arthroplasty Register Annual Report 2011. 2013.
2. Richards CJ, Duncan CP, Masri BA, Garbuz DS. Femoral Revision Hip Arthroplasty: A Comparison of Two Stem Designs. Clinical Orthopaedics & Related Research. 2010;468(2):491.
3. Dohmae Y, Bechtold JE, Sherman RE, Puno RM, Gustilo RB. Reduction in cement-bone interface shear strength between primary and revision arthroplasty. Clinical Orthopaedics & Related Research. 1988;236(236):214.
4. Engelbrecht DJ, Weber FA, Sweet MB, Jakim I, . Long-term results of revision total hip arthroplasty. Journal of Bone & Joint Surgery British Volume. 1990;72(1):41.
5. Franzén H, ., Mj?Berg B, ., Onnerf?Lt R, . Early loosening of femoral components after cemented revision. A roentgen stereophotogrammetric study. J Bone Joint Surg. 1992;74(5):721.
6. Engh CA, Culpepper WJ, Engh CA. Long-term results of use of the anatomic medullary locking prosthesis in total hip arthroplasty. Journal of Bone & Joint Surgery American Volume. 1997;79(2):177.
7. Joon Soon K, Kyong Ho M, Seung Rim P, Seong Wook C. Long-term results of total hip arthroplasty with an extensively porous coated stem in patients younger than 45 years old. Yonsei Medical Journal. 2010;51(1):100-.
8. Paprosky WGSporer SM. Revision total hip arthroplasty: the limits of fully coated stems. Clinical Orthopaedics & Related Research. 2003;417(417):203-9.

9. José GDA, Eduardo GC, Vicente C, Enrique GG. Radiographic bone regeneration and clinical outcome with the Wagner SL revision stem: a 5-year to 12-year follow-up study. Journal of Arthroplasty. 2007;22(4):515-24.
10. Group RTHAS. A Comparison of Modular Tapered Versus Modular Cylindrical Stems for Complex Femoral Revisions. Journal of Arthroplasty. 2013;28(8):71-3.
11. Tang H, Du H, Tang Q, Yang D, Shao H, Zhou Y. Chinese Patients' Satisfaction With Total Hip Arthroplasty: What Is Important and Dissatisfactory? Journal of Arthroplasty. 2014;29(12):2245-50.
12. Della Valle CJ, Paprosky WG. The femur in revision total hip arthroplasty evaluation and classification. Clin Orthop Relat Res. 2004;420(420):55-62.
13. Callaghan JJ, Fulghum CS, Glisson RR, Stranne SK. The effect of femoral stem geometry on interface motion in uncemented porous-coated total hip prostheses. Comparison of straight-stem and curved-stem designs. Journal of Bone & Joint Surgery-american Volume. 1992;74(6):839-48.
14. Böhm P, Bischel O. Femoral revision with the Wagner SL revision stem : evaluation of one hundred and twenty-nine revisions followed for a mean of 4.8 years. Journal of Bone & Joint Surgery-american Volume. 2001;83(7):1023-31.
15. Banaszkiewicz PA. Porous-Coated Hip Replacement. The Factors Governing Bone Ingrowth, Stress Shielding, and Clinical Results. Journal of Bone & Joint Surgery-british Volume. 1987;69(1):45.
16. Engh CA, Mcauley JP, Sychterz CI, Sacco ME, Engh Sr. CA. The Accuracy and Reproducibility of Radiographic Assessment of Stress-Shielding. Journal of Bone & Joint Surgery American Volume. 2000;82(10):1414-20.
17. Russell RD, Pierce W, Huo MH. Tapered vs Cylindrical Stem Fixation in a Model of Femoral BoneDeficiencyinRevision Total Hip Arthroplasty. Journal of Arthroplasty. 2016;31(6):1352-5.
18. Jr EC, Jr HR, Sr EC. Distal ingrowth components. Clin Orthop Relat Res. 2004;420(420):135-41.
19. Weeden SH, Paprosky WG. Minimal 11-year follow-up of extensively porous-coated stems in femoral revision total hip arthroplasty. Journal of Arthroplasty. 2002;17(4):134-7.
20. Regis D, ., Sandri A, ., Bonetti I, ., Braggion M, ., Bartolozzi P, . Femoral revision with the Wagner tapered stem: a ten- to 15-year follow-up study. Journal of Bone & Joint Surgery British Volume. 2011;93(10):1320.
21. Sandiford NA, Garbuz DS, Masri BA, Duncan CP. Nonmodular Tapered Fluted Titanium Stems Osseointegrate Reliably at Short Term in Revision THAs. Clin Orthop Relat Res. 2016;475(1):1-7.
22. Alamo JGD, Garcia-Cimbrelo E, Castellanos V, Gil-Garay E. Radiographic Bone Regeneration and Clinical Outcome With the Wagner SL Revision Stem : A 5-Year to 12-Year Follow-Up Study. Journal of Arthroplasty. 2007;22(4):515-24.
23. Stefan K, Jan N, Thomsen MN, Christian H, Alexander J, Kretzer JP, et al. Fixation pattern of conical and cylindrical modular revision hip stems in different size bone defects. International Orthopaedics. 2015;39(9):1819-25.

24. Paprosky WG, Greidanus NV, Antoniou J. Minimum 10-year-results of extensively porous-coated stems in revision hip arthroplasty. Clin Orthop Relat Res. 1999;369(369):230-42.
25. Hazlehurst KB, Chang JW, Stanford M. A numerical investigation into the influence of the properties of cobalt chrome cellular structures on the load transfer to the periprosthetic femur following total hip arthroplasty. Medical Engineering & Physics. 2014;36(4):458-66.
26. Sumner DR. Long-term implant fixation and stress-shielding in total hip replacement. Journal of Biomechanics. 2015;48(5):797-800.

Tables

Table 1 Comparison of basic data between the two groups

classification	cylindrical group	tapered group	P value
Age (years)	68.3±7.0（49～81）	67.7±7.9（50～83）	0.481
Gender (female/male)	28/26	30/36	0.860
BMI（/）	26.1±3.0(19.00～32.00）	26.0±2.5(20.74～31.99）	0.860
Initial replacement to repair time （months）	11.5±4.8（1～21）	10.9±6.6（0.08～25）	0.370
reasons for revision（n）			0.583
Aseptic loosening	49	57	
Periprosthetic fractures	3	3	
Dislocation	2	6	
Paprosky femoral defect (n)			0.347
Ⅰ	10	12	
Ⅱ	27	36	
ⅢA	16	15	
ⅢB	1	3	
ASA classification（n）			0.168
Ⅰ	5	6	
Ⅱ	41	48	
Ⅲ	8	12	
Combined acetabular revision(n)	47	63	0.071
VAS score (score)	7.6±1.3（6～10）	7.5±1.1（6～10）	0.982
Harris score (score)	41.1±6.1（29～52）	40.1±6.6（27～52）	0.423

Table 2 Comparison of intraoperative data between the two groups

ssification	cylindrical group	tapered group	P value
rative time (minutes)	234.6±48.3 (120 ~ 330)	229.3±62.6 (120 ~ 385)	0.399
pital stay (days)	20.9±4.6 (12 ~ 34)	20.5±4.9 (10 ~ 40)	0.451
aoperative blood loss (ml)	1240.7±306.2 (500 ~2000)	1210.6±491.4 (300~2200)	0.441
operative drainage (ml)	536.2±88.0 (310 ~ 754)	520.8±115.6 (315 ~ 774)	0.203
l blood loss (ml)	1784.4±317.7 (984 ~2494)	1748.1±514.5(882 ~3525)	0.518
d transfusion volume (ml)	711.1±276.5 (400~ 1600)	709.1±320.0 (400 ~ 1600)	0.773
e binding (n)	24	24	
graft bone plate(n)	5	6	
(n)	10	9	

Table 3 Level of satisfaction at the most recent follow-up

level of overall satisfaction	Cylindrical group (N=54)	tapered group (N=66)
Very satisfied	29	43
Satisfied	18	17
Neutral	3	2
Dissatisfied	2	2
Very dissatisfied	2	2

Table 4 Radiographically evident changes to the proximal femur host bone stock

Changes to the proximal femur host bone stock	cylindrical group (N= 54)	tapered group (N=66)
Type A bone loss)	23	9
Type B (no change	27	31
Type C bone restoration	4	26

Figures

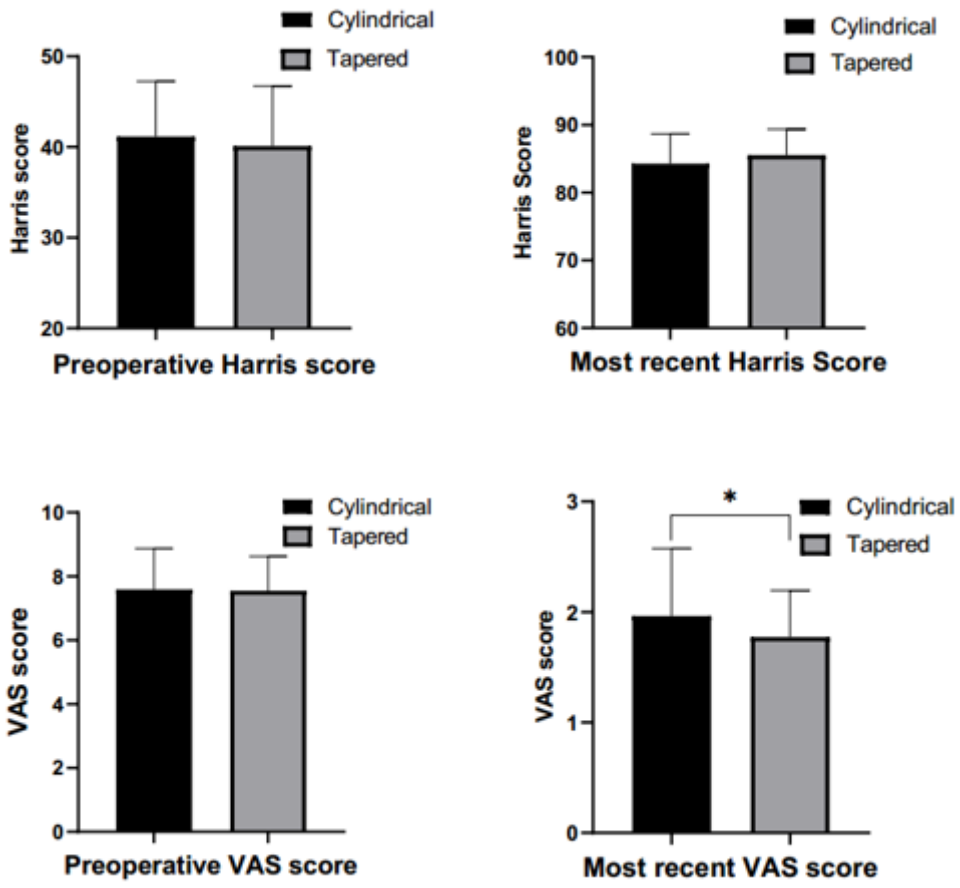

Figure 1

Comparison of the preoperative and postoperative Harris score and VAS score between the two groups

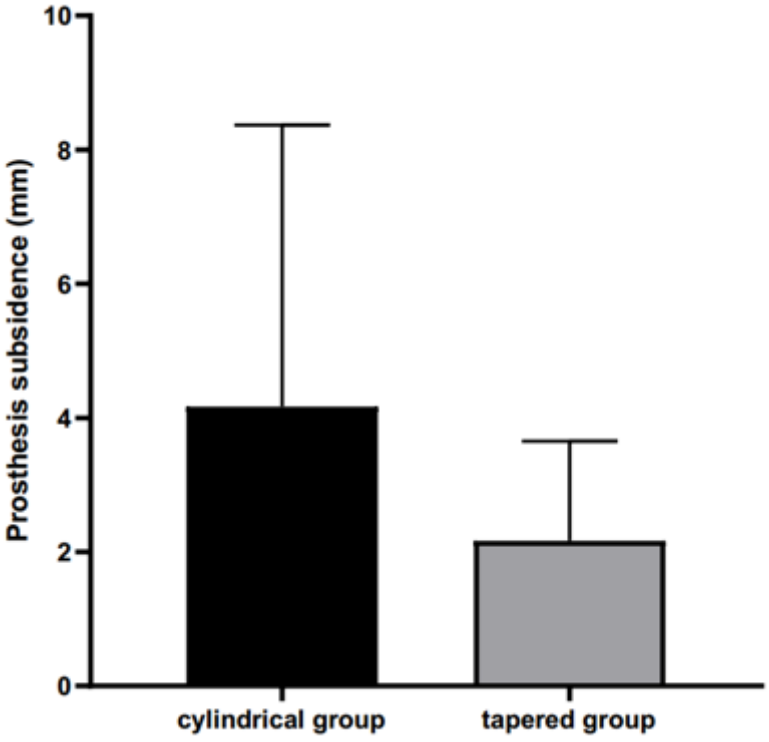

Figure 2

Comparison of the prosthesis subsidence between the two groups at the last follow-up (P<0.05)

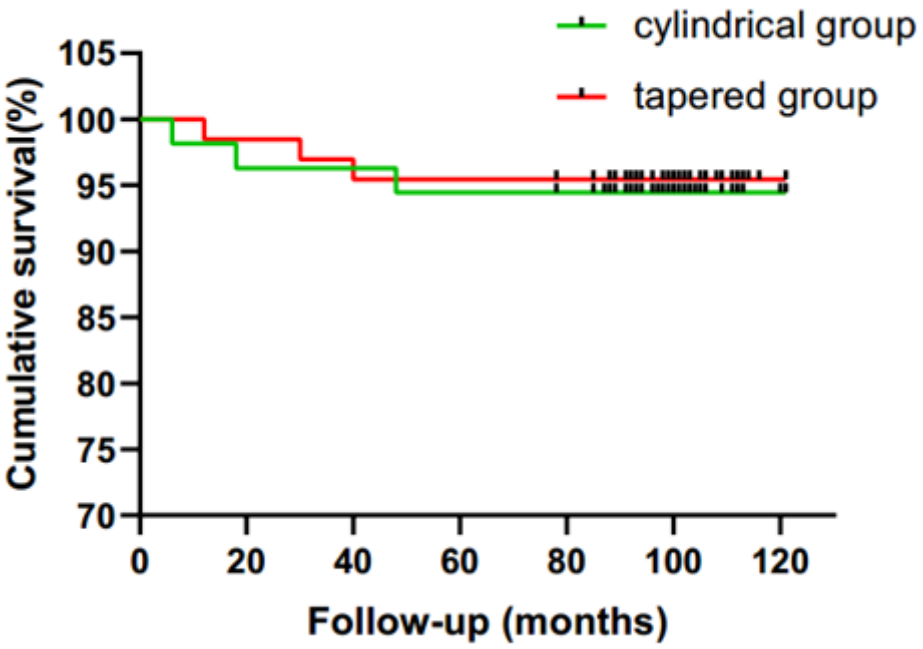

Figure 3

Kaplan-Meier survival analysis with the endpoint defined as any reoperation because of septic or aseptic complications

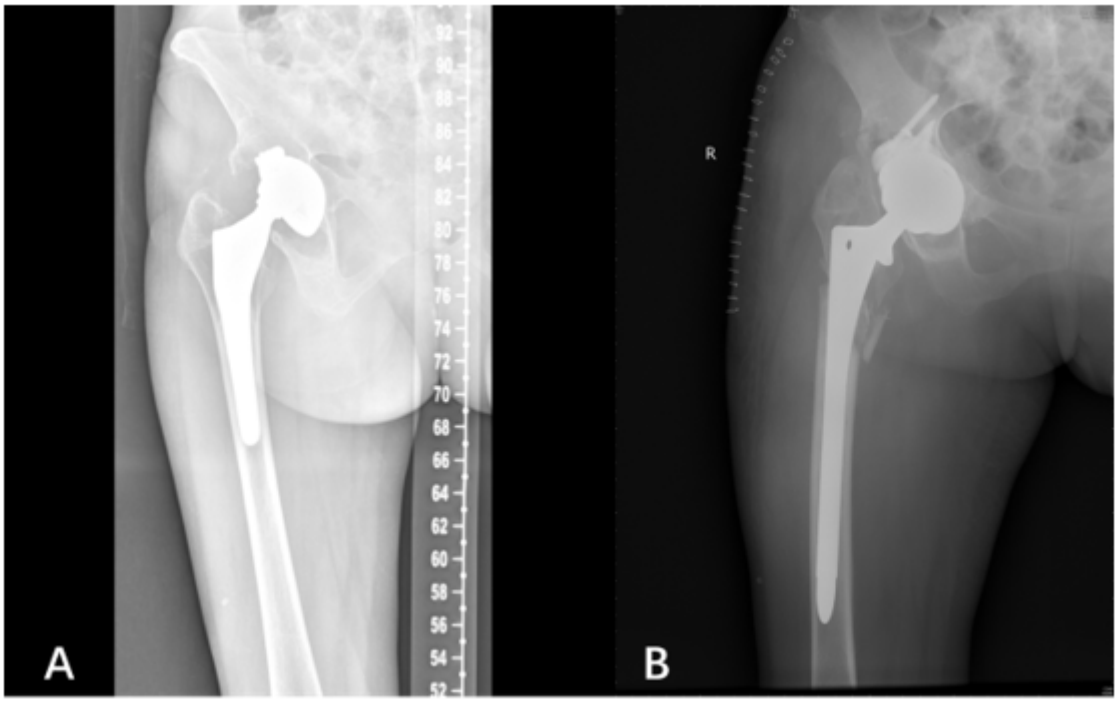

Figure 4

Preoperative and postoperative radiographs of cylindrical stem with intraoperative fractures.

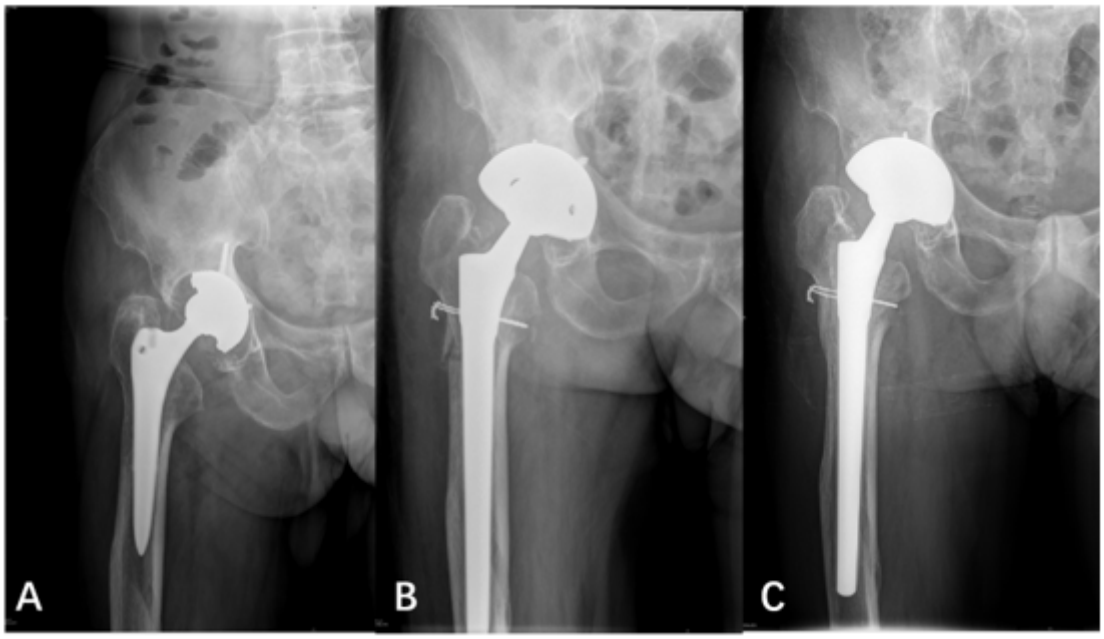

Figure 5

Preoperative and postoperative radiographs of tapered stem with intraoperative fractures.

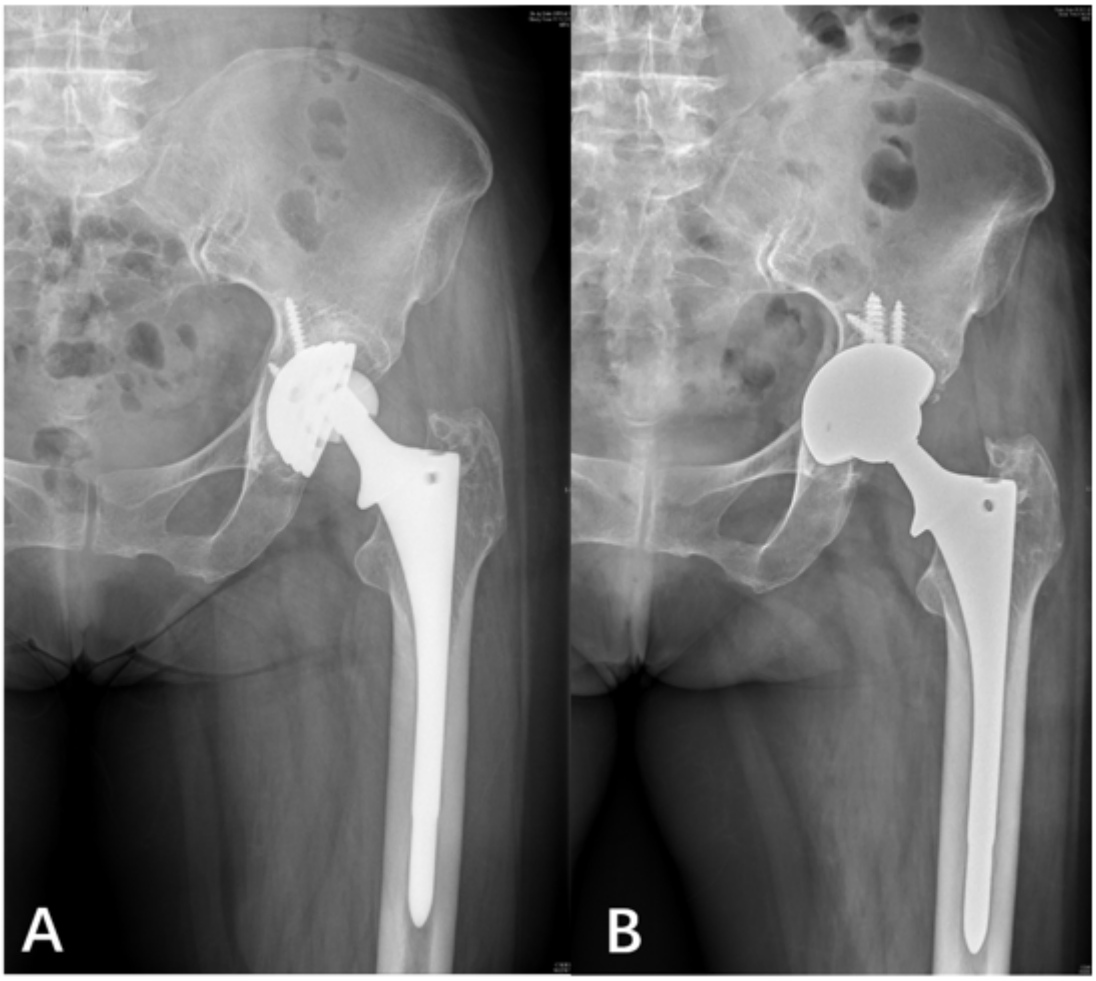

Figure 6

Postoperative radiographs of cylindrical stem with osteolysis around cup and re-revision with cup exchange.