Evaluation of Cardioprotective Potential of Hydroalcoholic Peel Extract of Citrullus Colocynthis

Ashira Manzoor
Muhammad Institute of Medical and Allied Sciences multan

Imran Ahmad Khan
Muhammad Institute of medical and allied sciences multan

Muhammad Omer Iqbal
Ocean University of China

Saba Kousar (sabakousar888@gmail.com)
Muhammad Institute of Medical and Allied sciences Multan https://orcid.org/0000-0003-1672-2334

shukat Hussain Munawar
Cholistan university of veterinary and animal sciences Bahawalpur

Zahid Manzoor
Cholistan university of veterinary and animal sciences Bahawalpur

Gul -e- mizgan
Muhammad institute of medical and allied sciences multan

Perwasha Perwasha
Allied Medical and Technical Institute: Fortis Institute - Wayne

---

Research

Keywords: Adrenaline, C.colocynthis, Cardioprotective

Posted Date: December 11th, 2020

DOI: https://doi.org/10.21203/rs.3.rs-124440/v1

Abstract

Background and objective: Myocardial infarction is the number one cause of death both in males and females in many developed countries. Citrullus colocynthis is a medicinal plant used for the treatment for asthma, constipation, cough. The current study evaluates the cardioprotective potential of hydroalcoholic peel extract of Citrullus colocynthis against adrenaline-induced myocardial infarction in rabbits.

Materials and Methods: Animals were divided into four major groups each group consisting of six rabbits. Group - 1 was given adrenaline 2mg/kg subcutaneously for two successive days. Considerably ($p<0.001$) accelerated the ALP, AST, ALT, Troponin, CK-MB, LDH, and CRP ($p<0.05$). Group 2, 3, 4 rabbits pre-treated with the peel extract of C. colocynthis 100mg/kg, 200mg/kg, 300mg/kg respectively orally for 14 successive days and on 14th and 15th-day adrenaline was inoculated considerably improve the impact of adrenaline through lowering the levels of CK-MB, LDH, Troponin, AST, CRP, ALT, and ALP.

Results: The myocardial tissues of adrenaline induced group have more necrotic lesions. A slight deteriorating modifications of myocardial tissues usually in cardiac cells structure were observed in the group treated with extract.

Conclusion: The out-turn showed the cardioprotective potential of hydroalcoholic peel extract of C. colocynthis in a dose-dependent manner.

Full Text

This preprint is available for download as a PDF.

Figures

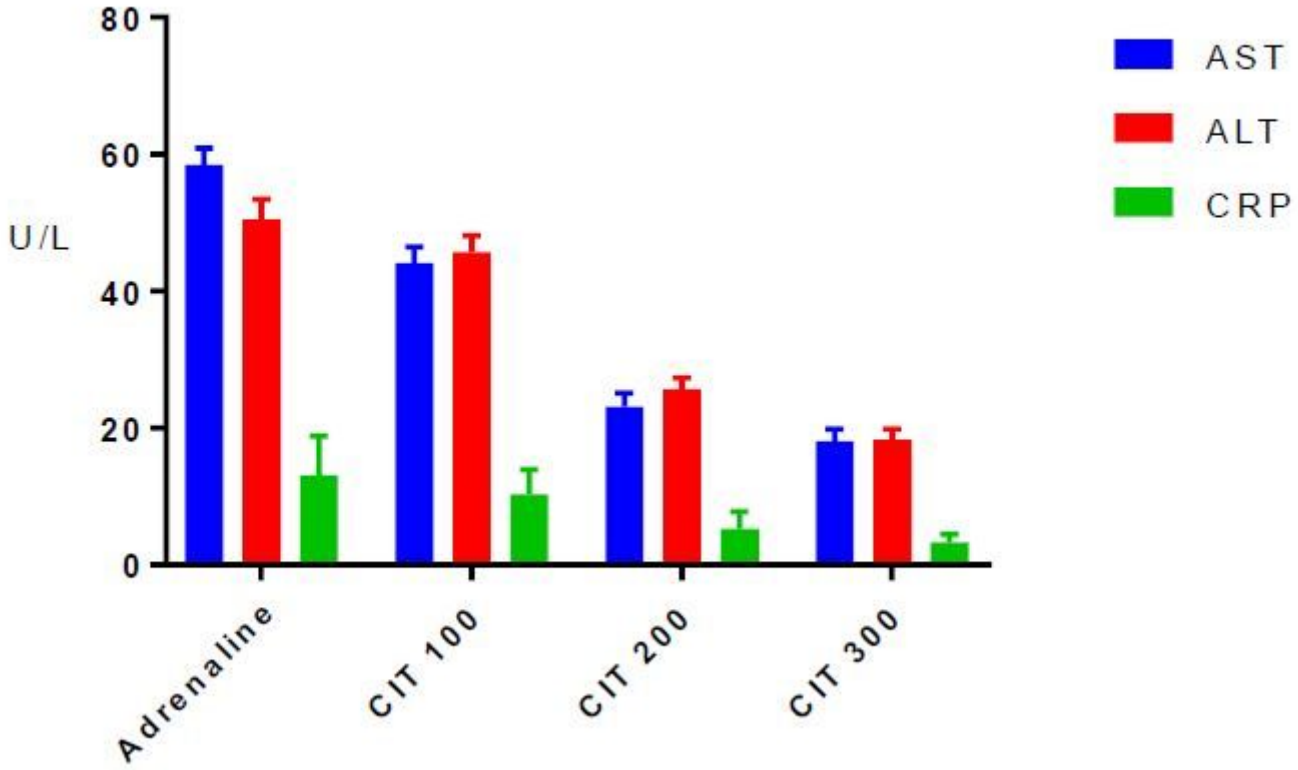

Figure 1

Treatment

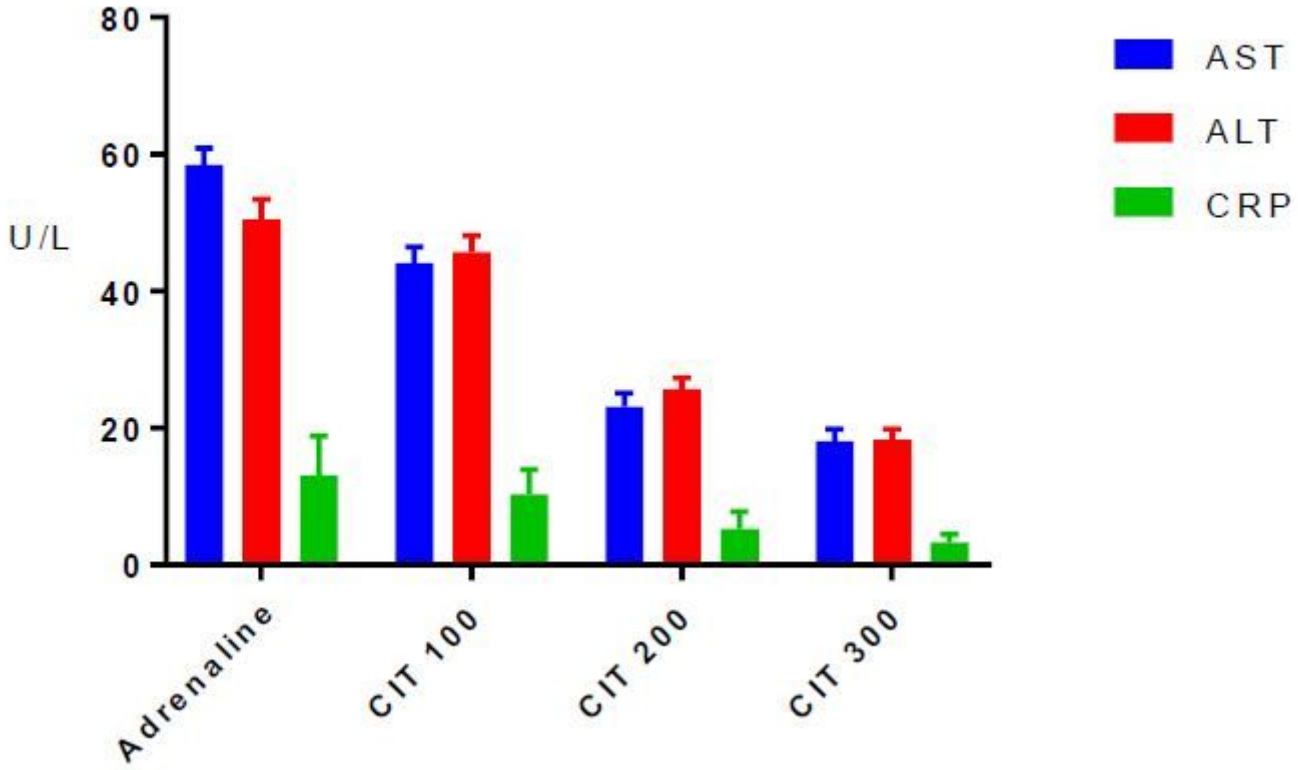

Figure 1

Treatment

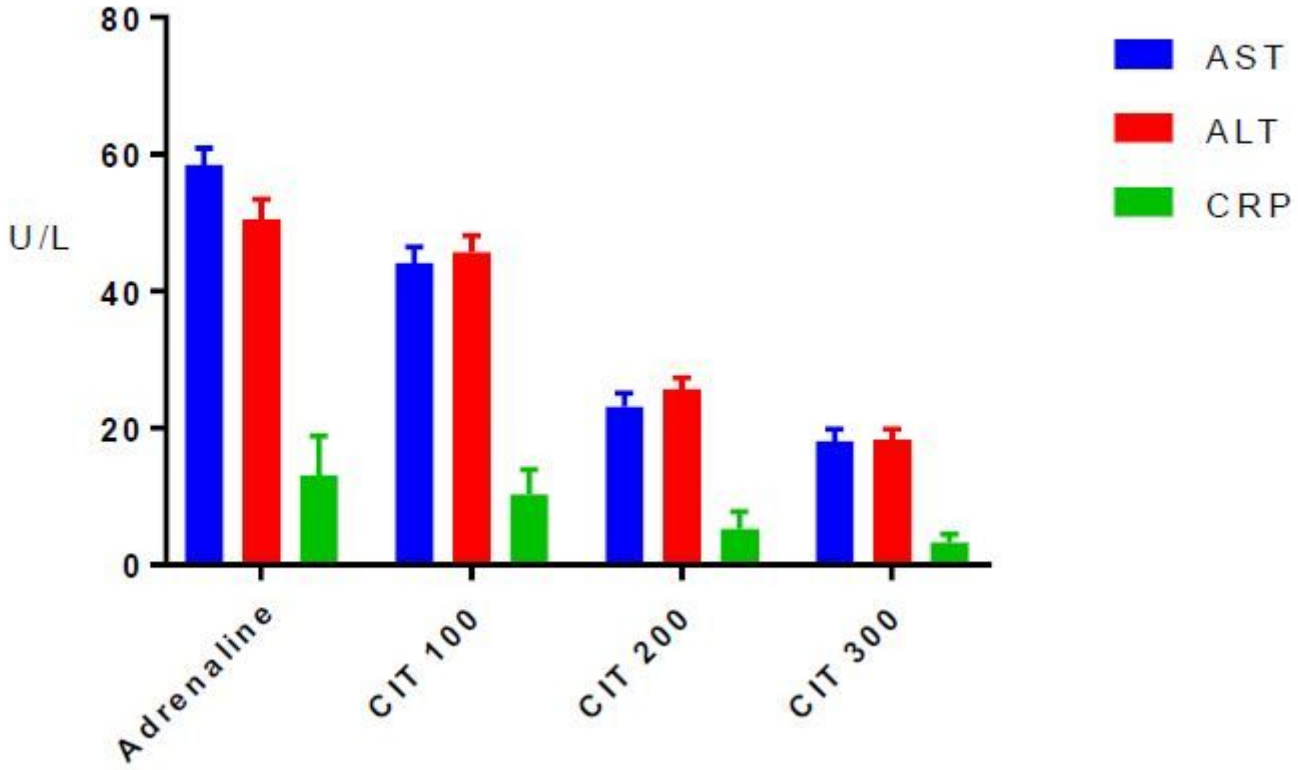

Figure 1

Treatment

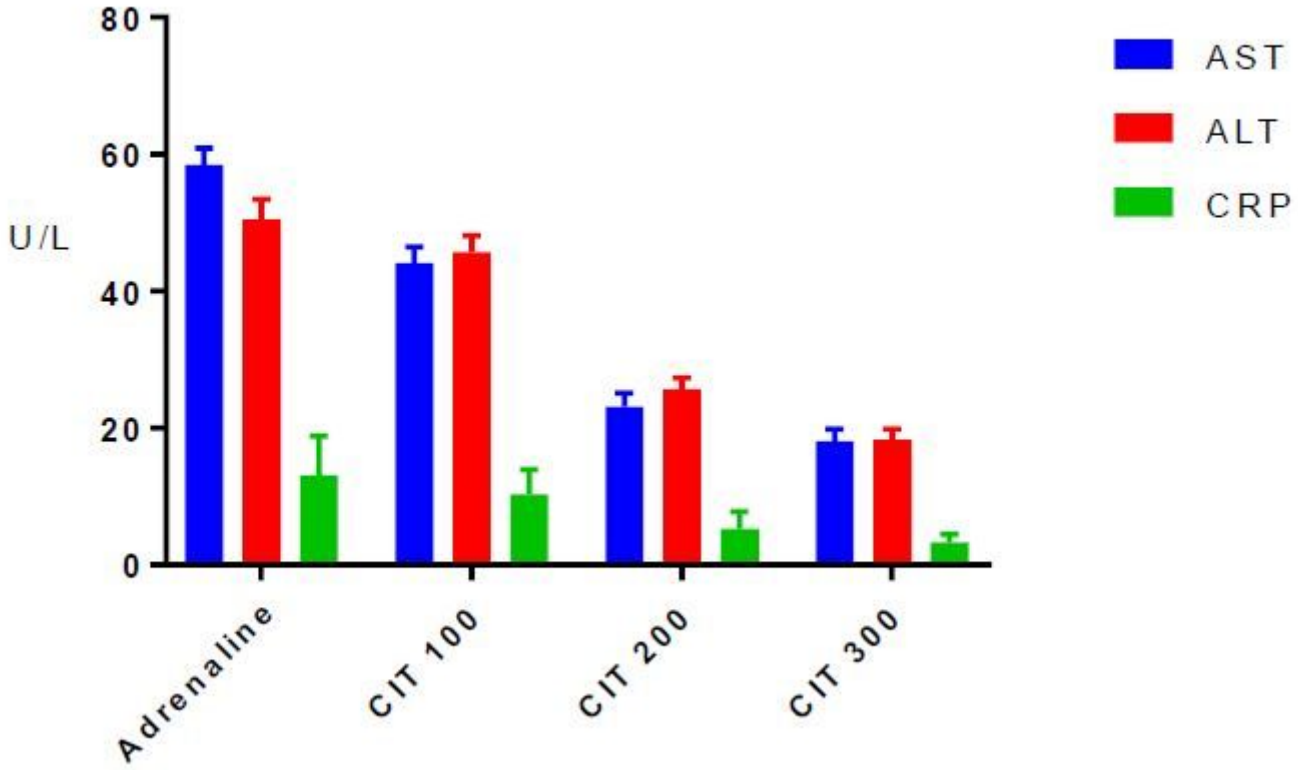

Figure 1

Treatment

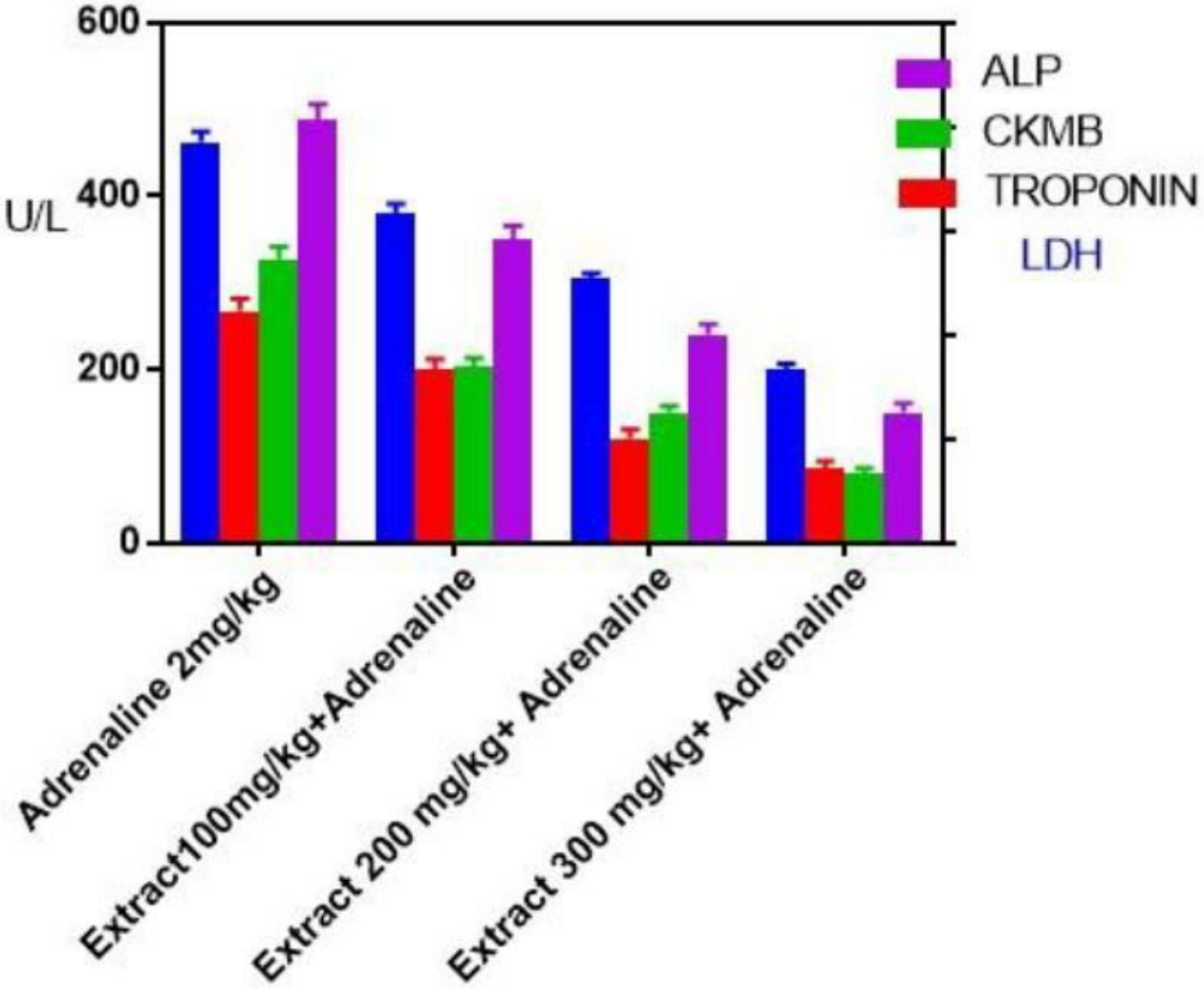

Figure 2

Treatment

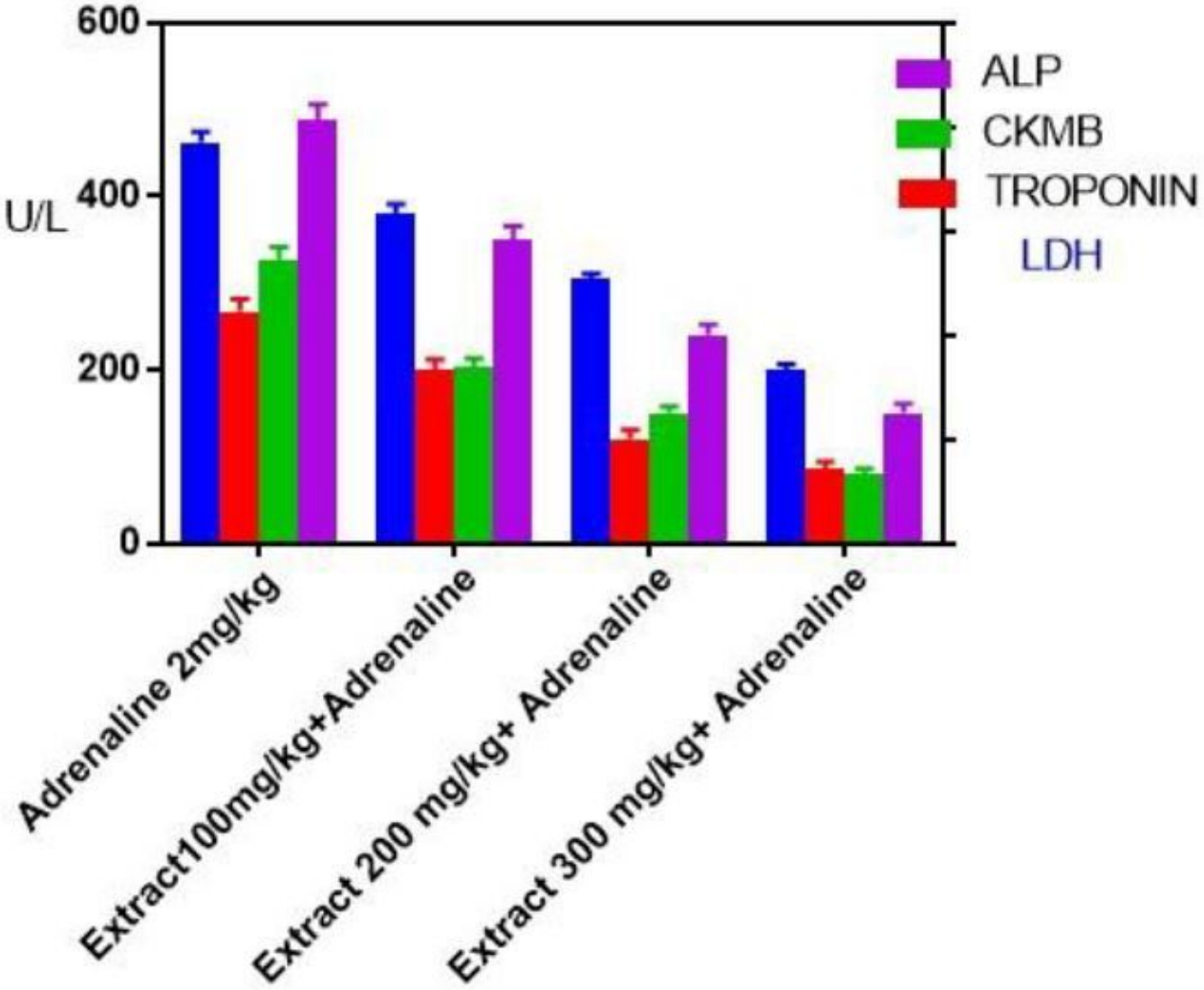

Figure 2

Treatment

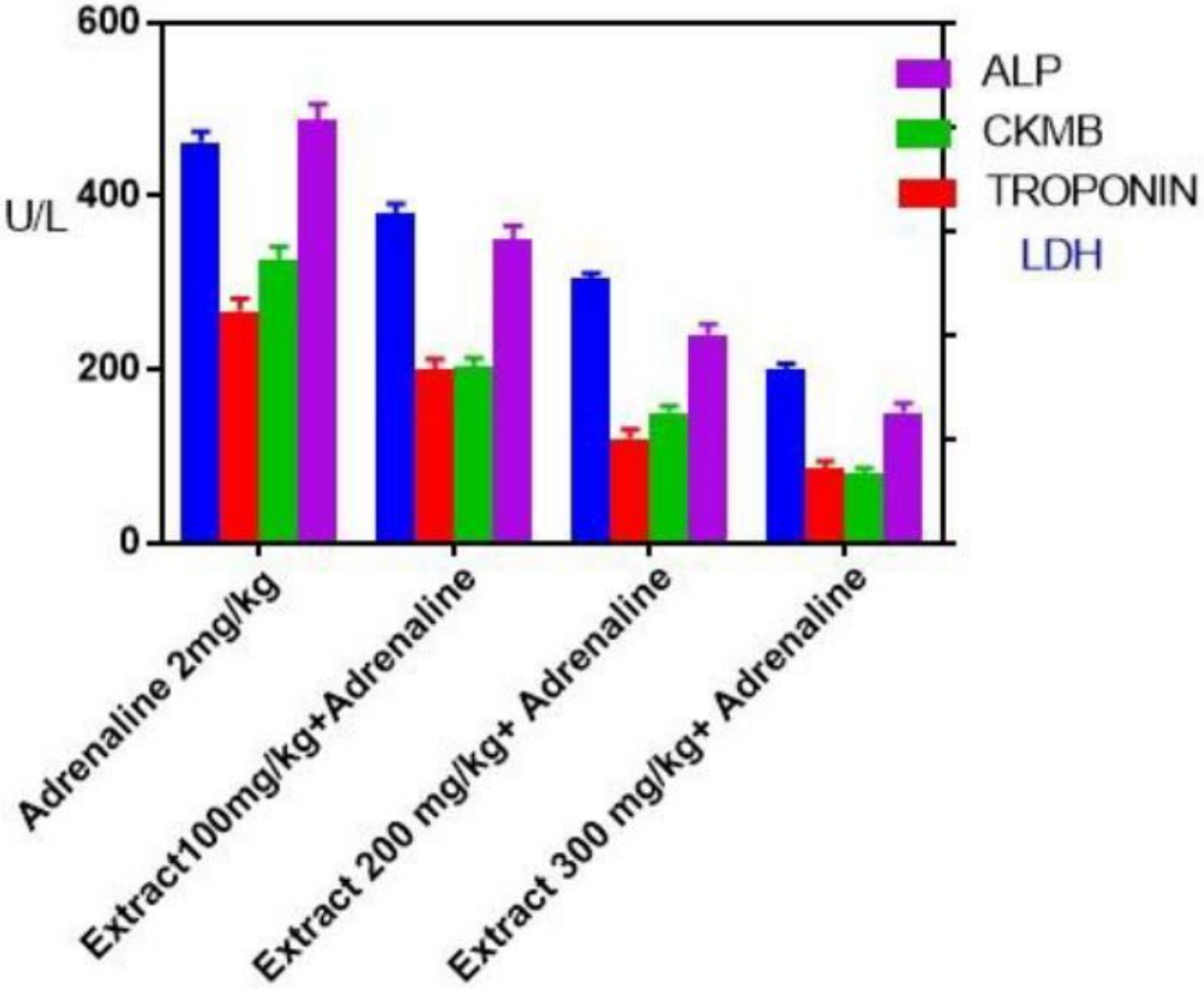

Figure 2

Treatment

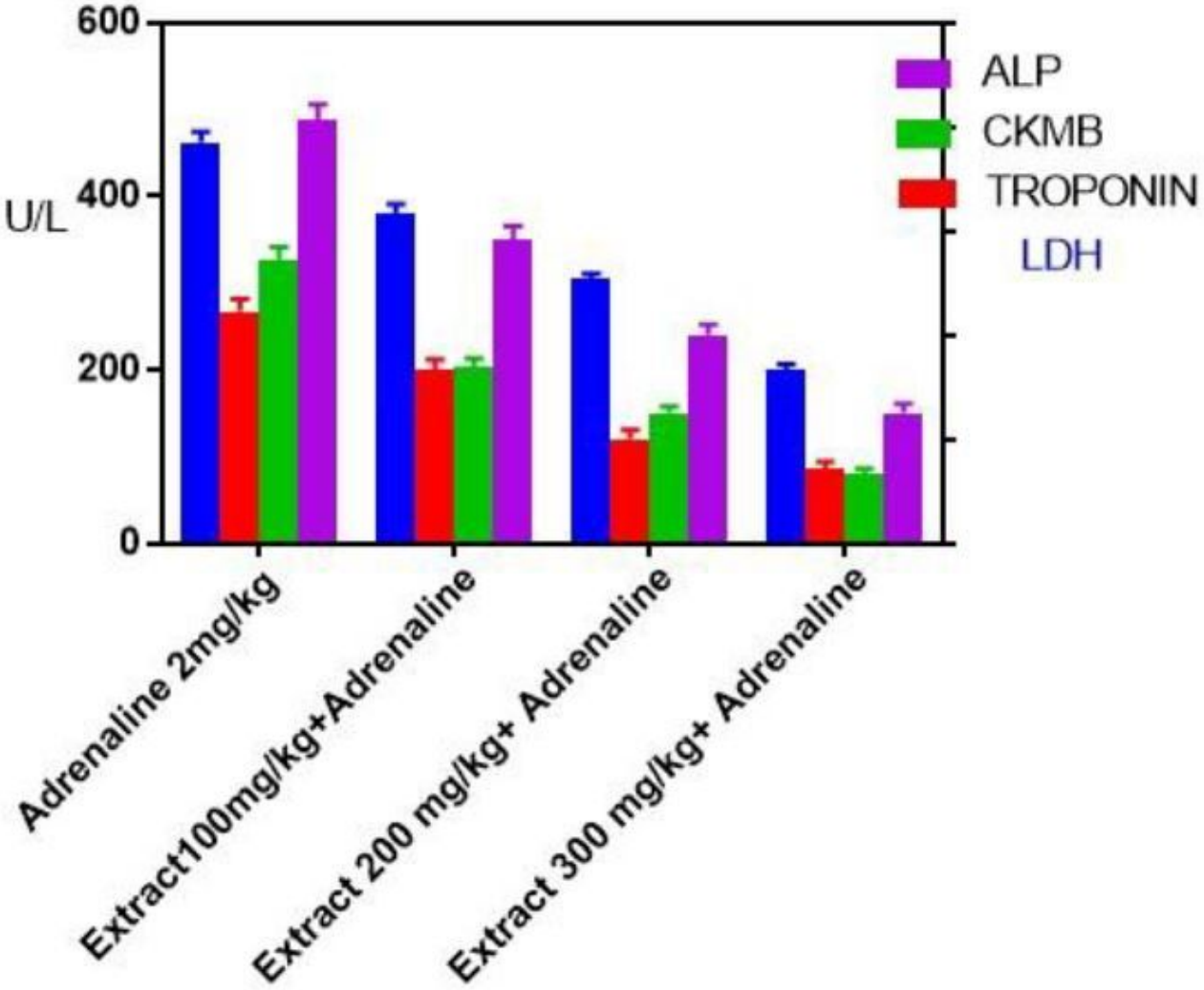

Figure 2

Treatment