Comparison of power-free-chop and phaco-chop techniques for moderate nucleus

Haiqing Bai
Department of ophthalmology,the affiliated hospital of Qingdao Univesity

Lin Yao (lynyao@126.com)
Qingdao Xinshijie Eye Hospital https://orcid.org/0000-0002-0082-3758

Research article

Keywords: power-free-chop, phaco-chop, phacoemulsification

Posted Date: January 27th, 2020

DOI: https://doi.org/10.21203/rs.2.21880/v1

Version of Record: A version of this preprint was published at BMC Ophthalmology on May 1st, 2020. See the published version at https://doi.org/10.1186/s12886-020-01455-4.

Abstract

Background: To compare intraoperative and postoperative effects of power-free-chop and phaco-chop techniques for moderate nucleus in phacoemulsification sugery. Methods: Sixty patients were evaluated in 2 groups prospectively. The power-free-chop technique was performed in Group 1 (30 eyes) and the phaco-chop technique in Group 2 (30 eyes). There were no significant differerces between these 2 groups. The cumulative dissipated energy (CDE), time to achieve maximum vision, corneal thickness variation, and time to return to the preoperative values were collected. All parameters were statistically compared in these 2 groups by using the chi-square test and the independent-sample t test. Results: The CDE was 5.53±1.92J in Group 1 and 7.02±1.77J in Group 2. After the operation, the mean time to recover to the maximum vision was 2.80±1.42 days in Group 1 and 3.80±1.92 days in Group 2 respectively. The mean postoperative corneal thickness increased 36.9±14.74μm in Group1 and 46.20±20.67μm in Group 2. And the mean time to return to preoperative pachymetry values were 3.73±1.70 days and 4.83±2.11 days, in Group 1 and Group 2 respectively. There were significant differences in these parameters between both groups. Conclusions: The power-free-chop technique had fewer negative effects on the corneal endothelium as less ultrasound power was used for moderate nucleus cases. This can accelerate the functional healing process and the return to preoperative physiologic values.

Background

Complete division of nucleus is crucial to accomplishing uneventful phacoemulsification. Several chop techniques have been introduced and modified with various advantages and disadvantages.[1–6] And the aims of all the techniques are to decrease the ultrasound power used during nucleus emulsification.[1]

Among these techniques, phaco-chop is one of the most popular techniques. Although phaco-chop technique is effective for moderate to hard nucleus, its use with soft nucleus is limited.[2,7] Therefore, in clinical applications, we invented the power-free-chop technique, which was derived from the modification of phaco-chop technique. Power-free-chop technique can be used to mechanically cleave soft to moderate nucleus into distinct fragments without ultrasound power participation.

As both power-free-chop and phaco-chop techniques can be used to cleave moderate nucleus. In this study, we compared the efficiency and safety for moderate nucleus cases by using these 2 techniques.

Methods

This study was comprised of 60 eyes (60 patients) with cataract. They were assigned to have phacoemulsification using the power-free-chop technique or the phaco-chop technique randomly. The criteria for these cases selection were 60–80 years old, 22.0–25.0 mm axial lengths, more than 2000 endothelial cells/mm^2, anterior depth beyond 2.5 mm, dilated pupil diameter beyond 6 mm, cataract nucleus grade 3 (according to Emery-Little classification[8]) and without other oculopathy.

All the surgeries were performed by the same surgeon (L. Y.), who was experienced in these 2 techniques, with Centurion® phacoemulsification unit (Alcon Laboratories, Inc.,).

In group 1 (power-free-chop), a standard 2.75 mm clear corneal incision was made at 11 o'clock and a side port create with a stab knife approximately 4 clock hours away. After continuous curvilinear capsulorhexis was made, hydrodissection and hydrodelineation were performed. The phaco tip inserted into the anterior chamber and removed the superficial cortex. And the phaco tip was erected and placed on the nucleus near the capsulorhexis edge at the 11 o'clock position, then leaned near the geometric center of the nucleus as deep as possible using irrigation/aspiration (I/A) gear without ultrasound power (Step 1, footpedal in position 2, Fig. 1A, 1B). The bevel face of the phaco tip was upwards. At this stage, occlusion was not necessary. The chopper was placed beyond the edge of the nucleus, and moved to the phaco tip horizontally. Then the nucleus was splitted into 2 hemispheres by the encountered chopper and phaco tip. Both of the hemispheres were turned 90 degrees around the horizontal axis using the chopper. Phaco tip was placed in the center of 2 hemispheres at irrigation status. The chopper was placed beyond the hemisphere which was opposite to the main corneal incision (Step 2, footpedal in position 1, Fig. 1C, 1D). And then the chopper moved to the phaco tip horizontally to split the hemisphere into 2 pieces. Each piece was aspirated and emulsified. And then repeated the same process. In the whole process, the position of the chopper was crucial. It must be placed beyond the edge of the nucleus and as deep as possible. I/A was used for clearing the remaining cortex. Sodium hyaluronate was injected into the anterior chamber and a foldable intraocular lens (IOL) was inserted into the capsular bag. The last step was clearing the sodium hyaluronate by I/A and the corneal incisions were closed by stromal hydration.

Compared with group 1, there were 2 differences of the operation in group 2 (phaco-chop). In step 1 and 2, the phaco tip was buried in the center of the nucleus with ultrasound power (Fig. 2A-D).

The cumulative dissipated energy (CDE), best corrected visual acuity (BCVA), time to achieve maximum vision, pachymetry, corneal thickness variation, and time to return to the preoperative values (± 20 μm according to the preoperative value) were recorded postoperatively. In the first week, all the patients were examined every, at an interval of 2 or 3 days in the first month, and then every month.

The chi-square test and the independent-samples t test were used to compare the groups for statistical significance. Data were analyzed using SPSS software (version 13.0, International Business Machines Corp,.). The level of significance was set to a P value of 0.05.

Results

Thirty patients in each group were evaluated. The characteristics of the patients in these 2 groups were shown in Table 1. There was no statistically significant difference between these 2 groups in any characteristic.

Table 1
Patients' characteristics.

Characteristic	Group 1 (Power-free-chop) (n = 30)	Group 2 (Phaco-chop) (n = 30)	P Value
Age (y)	70.26 ± 5.60	71.5 ± 5.59	0.396*
Sex (male/female)	12/18	14/16	0.602†
Right eye/ left eye	15/15	16/14	0.796†
Preoperative visual acuity (LogMar)	0.56 ± 0.21	0.61 ± 0.18	0.328*
Follow-up period (d)	63.50 ± 16.88	64.43 ± 15.26	0.823*
Preoperative corneal thickness (μm)	534.7 ± 38.37	543.5 ± 37.22	0.371*
Mean ± SD			
*Independent-samples t test			
†Chi-square test			

Between these 2 groups, differences in CDE, time to achieve maximum vision, pachymetry, corneal thickness variation, and time to return to the preoperative values were significant. However, there was no significantly difference in postoperative visual acuity between both groups (Table 2). The results showed that compared with the phaco-chop group, the postoperative healing period was shorter in the power-free-chop group.

Table 2
Intraoperative and postoperative parameters in the 2 groups.

Parameter	Group 1 (Power-free-chop) (n = 30)	Group 2 (Phaco-chop) (n = 30)	P Value*
Cumulative dissipated energy (CDE, J)	5.53 ± 1.92	7.02 ± 1.77	0.003
Postoperative visual acuity (LogMar)	0.067 ± 0.076	0.073 ± 0.074	0.732
Time to achieve BCVA (d)	2.80 ± 1.42	3.80 ± 1.92	0.026
Increase in CT (μm)	36.9 ± 14.74	46.20 ± 20.67	0.049
Time to return to preoperative CT (d)	3.73 ± 1.70	4.83 ± 2.11	0.031
Mean ± SD			
BCVA = best corrected visual acuity; CT = corneal thickness			
*Independent-samples t test			

Discussion

Chop procedure is the principal step for phacoemulsification. Many methods can be used to crack a nucleus such as phaco-chop, stop-and-chop, and divide-and-conquer.[4,9] But all of them involve occlusion, using high vacuum to stabilize the nucleus, and ultrasound power to create the initial groove or fracture.

Among these methods, phaco-chop technique is the most appropriated method for moderate to hard nuclei.[2,7] However, it is very difficult to achieve the occlusion and high vacuum required to cleave a soft nucleus. For soft nucleus even in occlusion, holding is difficult, because the phaco tip tends to aspirate the soft nuclear matter. Alternatively, flipping technique and phaco rolling technique have been described to remove soft nucleus. However both of them represent a certain risk to the endothelium, particularly in eyes with shallow anterior chambers.[10,11] Therefore, we invented the power-free-chop technique, which was a modified phaco-chop technique, can be used to mechanically cleave soft nucleus into distinct fragments without occlusion and ultrasound power participation. In clinical applications, we found power-free-chop technique is suitable for not only soft nucleus but also moderate nucleus.

As both power-free-chop and phaco-chop techniques could be used to cleave moderate nucleus. We compared 2 techniques for handling moderate nucleus in our study. The results showed that in the power-free-chop group CDE was significantly lower. In the postoperative follow-up period, compared with the phaco-chop group, corneal edema was significantly lower and the healing period was shorter in the power-free-chop group.

Compared with phaco-chop technique, occlusion and holding tightly are not necessary in the power-free-chop technique. In the chop procedure, the phaco tip just needs lean against the nucleus as deep as possible in I/A gear. Therefore, no ultrasound power is wasted in the chop procedure. As a contrast, phaco-chop technique requires ultrasound power to bury the phaco tip into the nucleus deeply. In the chop procedure, the using of the chopper is the same for these 2 techniques. The chopper needs to be placed beyond the edge of the nucleus and move to the phaco tip. Moreover, since without ultrasound power involved, the phaco tip will not penetrate the nucleus during the chopping process in the power-free-chop technique. Therefore, this also can protect the posterior capsule and avoid the occurrence of posterior capsule rupture (PCR).

Another significant benefit of the power-free-chop technique is that this technique do not need to build the occlusion in the nucleus with precise pedal control. This can eliminate the difficulty in the chopping procedure especially for the phaco beginners. Therefore, power-free-chop technique is easier to be learned and controlled compared with phaco-chop and other manual prechop techniques such as cystotome-assisted prechop technique.[12]

The power-free-chop technique also has disadvantage. It is effective for soft to moderate nucleus (Emery-Little classification, grade 1 to 3) only. We have tried to use this technique on hard nucleus, but it did not succeed. If encounter hard nucleus, power-free-chop technique can be easily switched to phaco-chop technique in the operation.

Conclusion

In summary, for moderate nucleus, power-free-chop technique is superior to the phaco-chop technique as it decreased the CDE and accelerated the functional healing process.

List Of Abbreviations

I/A, irrigation/aspiration; IOL, intraocular lens; CDE, cumulative dissipated energy); BCVA, best corrected visual acuity; PCR, posterior capsule rupture.

Declarations

Ethics and consent: This study was approved by Qingdao Xinshijie Eye Hospital ethics committee. Informed consent, obtained from all patients, was written.

Consent for publication: Written informed consent for publication was obtained.

Availability of data and materials: All data generated or analysed during this study are included in this published article.

Competing interests: The authors declare that they have no competing interests

Funding: The authors have no financial interest to disclose.This research was not supported by any funding.

Authors' contributions: HB and LY designed this study, collected and analysed the data. Both of them wrote the manuscript, read and approved the final manuscript.

Acknowledgements: Not applicable.

References

1. Linebarger EJ, Hardten DR, Shah GK, Lindstrom RL. Phacoemulsification and modern cataract surgery. Surv Ophthalmol 1999; 44:123-147
2. Buratto L. Techniques of phacoemulsification. In: Buratto L, ed, Phacoemulsification: Priciples and Techniques. Thorofare, NJ, Slack, 1998; 71-170
3. Vanathi M, Vajpayee RB, Tandon R, Titiyal JS, Gupta V. Crater-and-chop technique for phacoemulsification of hard cataracts. J Cataract Refract Surg 2001; 27:659-661
4. Koch PS, Katzen LE. Stop and chop phacoemulsification. J Cataract Refract Surg 1994; 20:566-570
5. Aslan BS, Müftüoglu O, Gayretli D. Crater-and-split technique for phacoemulsification modification of the crater-and-chop technique. J Cataract Refract Surg 2012; 38:1526-1530
6. Hwang HS, Kim EC, Kim MS. Drill-and-crack technique for nuclear disassembly of hard nucleus. J Cataract Refract Surg 2010; 36:1627-1630
7. Vasavada A, Singh R. Surgical techniques for difficult cataracts. Curr Opin Ophthalmol 1999; 10:46-52
8. Emery JM, Little JH. Patient selection. In: Emery JM, Little JH, eds, Phacoemulsification and Aspiration of Cataracts; Surgical Techniques, Complications, and Results. St. Louis, MO, CV Mosby, 1979; 45–48
9. Gimbel HV. Divide and conquer nucleofractis phacoemulsification: development and variations. J Cataract Refract Surg 1991; 17:281-291.
10. Fine IH. The chip and flip phacoemulsification technique. J Cataract Refract Surg 1991; 17:366-371.
11. Güell JL,Vázquez M,Lucena J,Velasco F,Manero F. Phaco rolling technique. J Cataract Refract Surg 2004; 30:2043-2045.
12. Chen X, Liu B, Xiao Y, Qi Y, Hao X, Shi L, Wu L. Cystotome-assisted prechop technique. J Cataract Refract Surg 2015; 41:9-13.

Figures

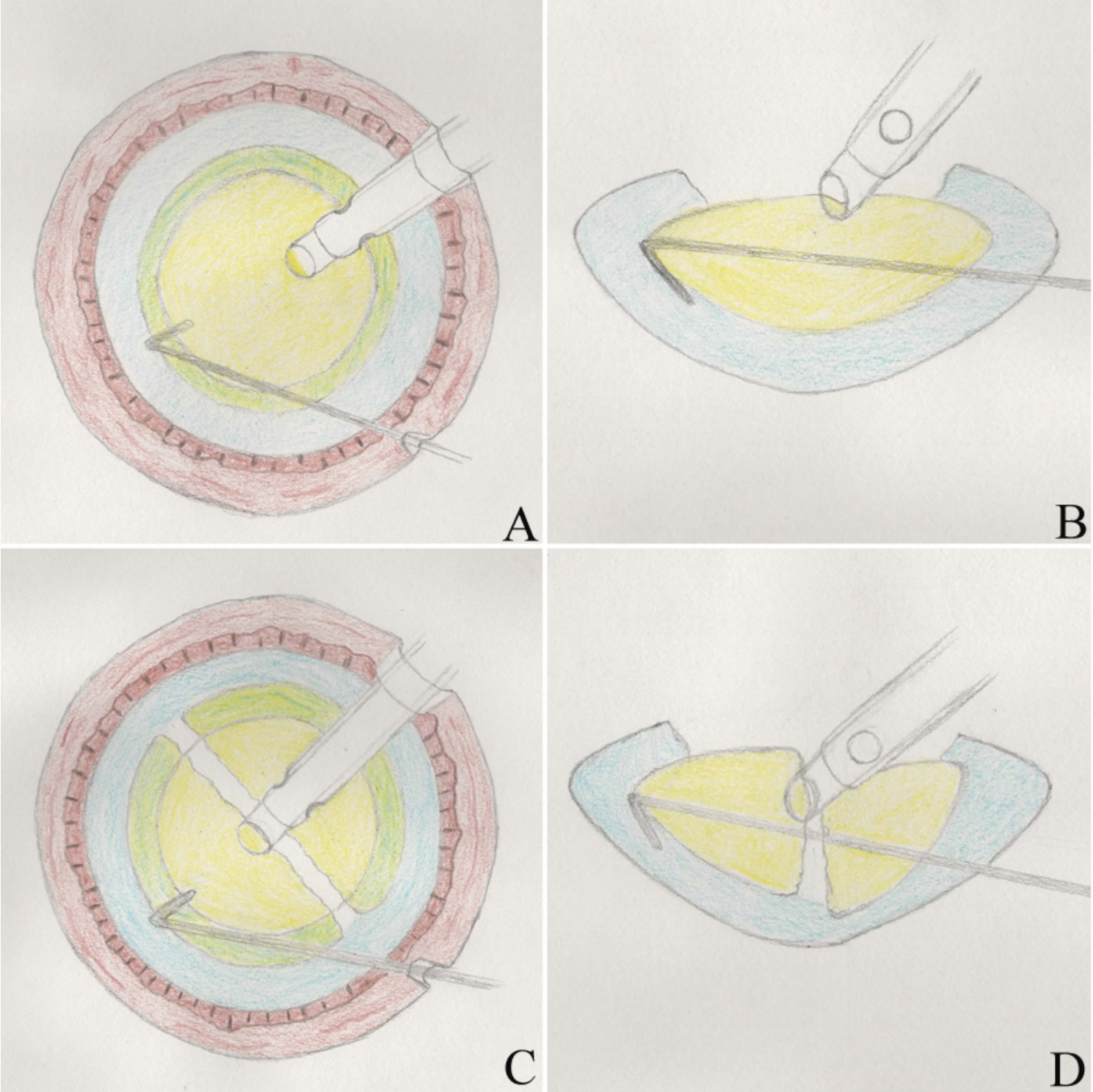

Figure 1

The procedure of power-free-chop technique.

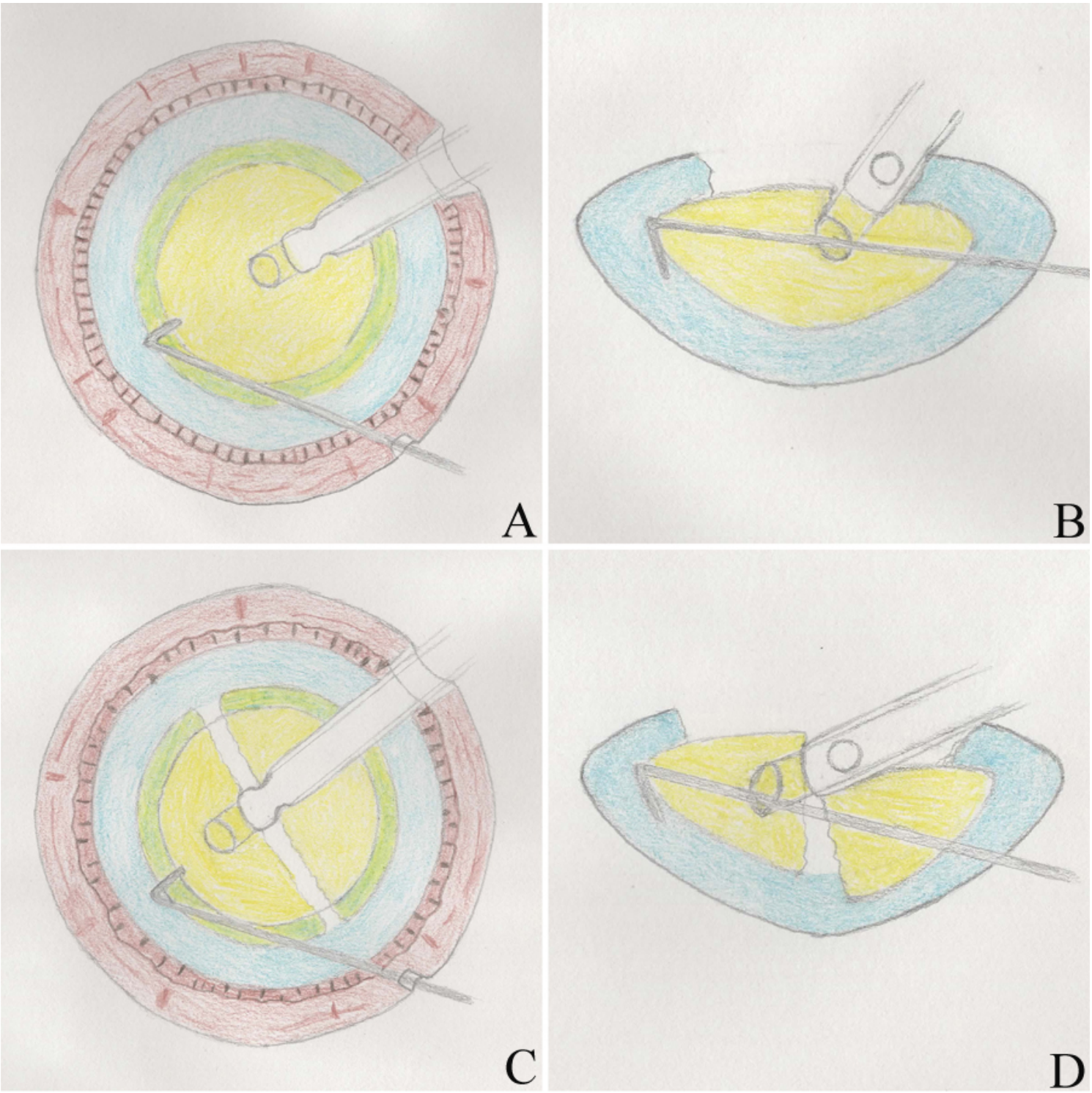

Figure 2

The procedure of phaco-chop technique.