Research Square

Preprints are preliminary reports that have not undergone peer review. They should not be considered conclusive, used to inform clinical practice, or referenced by the media as validated information.

The Effectiveness of Vitamin C on Quinalphos Ileal Toxicity: A Study of Histological, Ultrastructural, and Oxidative Stress Markers

Mohamed Samir Ahmed Zaki (mszaki1957@gmail.com)
King Khalid University College of Medicine https://orcid.org/0000-0003-0010-0506

Attalla F. El-kott F. El-kott
King Khalid University College of Science

Hussah I.M. AlGwaiz
Prince Sattam bin Abdulaziz University

Abulqasim M. Sideeg
King Khalid University College of Medicine

Mohamed Andarawi
King Khalid University College of Medicine

Refaat A. Eid
King Khalid University College of Medicine

Research Article

Keywords: Ileum, light microscopy, electron microscopy, Oxidative markers

Posted Date: January 24th, 2022

DOI: https://doi.org/10.21203/rs.3.rs-1247682/v1

License: This work is licensed under a Creative Commons Attribution 4.0 International License. Read Full License

Version of Record: A version of this preprint was published at Environmental Science and Pollution Research on March 31st, 2022. See the published version at https://doi.org/10.1007/s11356-022-19820-9.

Abstract

There is a significant hazard of human exposure to the organophosphates is a constant threat and they are responsible for numerous cases of poisoning and mammalian toxicity annually in non target wildlife. The antioxidants including the vitamin C (Vit C) have a protective effect on some organophosphorus compounds-induced organ damage. Quinalphos (QP) is one of these compounds. The investigation's objective is to see if there was any effect of QP on the rat ileum which could be rectified by using Vit C. Three groups of twenty-four animals were created. As a control, the first group was given pure water. Second group subjected to oral gavages of QPs. Third group rats were given oral gavages of Vit C plus QPs for 10 days. The reaction of ileal enterocytes to food-borne QPs was marked by poorly organized microvilli, numerous vacuoles within them, disrupted nuclei with chromatin margination, disoriented mitochondria, and an expanded intercellular space. The absorptive columnar cell illustrated many vacuoles inside with herniation of microvilli and normal goblet cells were also seen. Many Paneth cells towards the lumen of intestinal gland contained secretory granules of different sizes and shapes. The histological architecture of the ileal mucosa in the QP plus Vit C group was found to be close to those of healthy controls. The outcomes of this study suggest that administering Vit C to rats treated with QPs protects them from ileal dysfunction caused by QP.

Introduction

Organophosphates are a class of insecticides that are often used to keep pests out of agricultural fields and households. They are most widely used pesticides that constitute approximately 36% of the global pesticide consumption (Samare et al. 2020). They are the first choice as pesticides as a result of their effectiveness in promptly removing pests, high biodegradability and low bioaccumulation qualities (Rahman et al. 2004). Although they help in improving the crop yield by eliminating pests, they can cause serious health problems in nontarget living animals, including human beings (Chowdhary et al. 2014).

QPs (QP, O, O- diethyl-O-[2-quinoxalinyl phosphonothioate) are one of the most widely used organophosphorus insecticides worldwide (Hu et al. 2010). In developing countries, Because of its simple availability, regular usage in agriculture, and a misunderstanding about the negative consequences among farmers, the hazard of QP exposure to humans seems to be very high (Chowdhary et al. 2014). Further, considerable amount of QP was already identified in food indicating its possible risk to human exposure directly or through the food chain (Kumar et al. 2016).

Because of its large surface area and physiological features, the intestine is a significant organ of the digestive system and the principal site of nutrient/toxicant exposure. Pesticide residues in water and food are becoming more prevalent at levels exceeding permitted limits raises concerns about their role in intestinal problems (Moritoki &Ishida 1977). Paneth cells are secretory epithelial cells found in clusters at the base of the Lieberkühn crypts in mammals' small intestines that generate antimicrobial agents such as lysozyme and defensins, which are bundled in secretory cytoplasmic granules (Clevers &Bevins 2013).

Several studies have found that inhibiting the acetylcholinesterase enzyme has been associated to an increase in reactive oxygen compounds, not only in employees exposed to organophosphorus pesticides, but also in those subjected to bipyridyl herbicides like paraquat, demonstrating oxidative stress induction via a decline in antioxidant capacity and an elevation in lipid peroxidation (Ranjbar et al. 2002). Reactive oxygen species (ROS) accelerate oxidative processes within the cell and cause lipid peroxidation in cell membranes, as previously indicated (Castro et al. 2021). It has been suggested that there is a biological consequence as a probable action mechanism of pesticide-induced lipid peroxidation on blood cells via an electrophilic attack on particular cellular components, a method of producing ROSs (Vieira &Dos Reis Martinez 2018). Antioxidant enzymes, which including glutathione peroxidase (GPx), superoxide dismutase (SOD), catalase (CAT) and peroxiredoxins preserve essential macromolecules such as proteins and DNA from free radical oxidation. Vit C is a highly effective non-enzymatic antioxidant that removes free radicals from extracellular fluids and protecting biomembranes from peroxidative damage (He et al. 2019). Therefore as consequence, natural antioxidants in reducing oxidative damage as a factor in the histology, physiology and pathophysiology of a number of disorders has recently gotten more attention (He et al. 2019). Antioxidants Vit C and vitamin E are accessible as nutritional supplements and are essential for practically all biological functions. Vit C is a water-soluble chain-breaker antioxidant (Teng et al. 2018). However, as a consequence of this, it has grown to be among the most widely used and least expensive non-enzymatic antioxidant compounds for preventing oxidative damage (Teng et al. 2018). Fruits, vegetables, and protein sources (particularly liver and kidney) are the finest sources of Vit C (Znamirowska et al. 2021). It has been proven that vit C reduces biochemical and haematological alterations produced by organophosphate pesticides in people and animals. The application of organophosphorus insecticides has been encountered to induce ileal damage by inducing major alterations in the ileal tissues, such as disorganization and enlarged interstitial spaces between them (Eddleston &Chowdhury 2016).

This study looked at the negative consequences of organophosphate insecticide QP on the ileum of rats by analyzing changes in biochemical and histological parameters that occur in this tissue because of ROSs generation and can be alleviated by using Vit C.

Materials And Methods

Experimental Design

Twenty-four adult healthy, male albino rats of Sprague–Dawley strain weighing 200–250 gm were classified into three main groups on an equal basis, eight rats for each. The treatment schedule of each group was as follows.

Group I

Served as a control and the animals were kept in a rat cage and received distilled water orally each day at 8 a.m. for 10 days.

Group II

Animals were given 14 mg kg–1 QP [o, o-diethyl-o-(2-quinoalinyl phosphonothioate)] in 100 L pure water, which was acquired as 'Suquin' 25 percent EC from an origin (Sudarshan Chemical Industries Ltd, Pune). QP was administered via gavage every day at 8 am for 10 days.

Group III

Rats were preconditioned by giving them Vit C as pure crystals (Sigma, AX 1776-1 by E. Merck Science, a division of EM industries Inc., Darmstadt, West Germany) 4 hours after receiving a QP treatment of 14 mg kg^{-1} in 100 L pure water for 10 days at a dose of 20 mg/kg/day (i.e. 10 mg/kg bw/day (about double the human-approved therapeutic dosage)).

To rule out any diurnal variations in hormone and neurotransmitter levels, all of the animals were sacrificed between 10:00 and 12:00 h one day after their last treatment. To minimize interference with neurotransmitters, the quantity of ether inhaled was kept to a minimum.

Light Microscopy (LM) Specimen Preparation and Staining

Ileal specimens were excised and stored for 24 hours in 10% neutral formalin solution. After washing in a 0.1 M phosphate buffer solution, the specimen was dehydrated with alcohol in ascending grades and embedded in paraffin. Ileal sections (5 µm thick) were deparaffinized for 15 minutes with two xylene shifts before being rehydrated with progressively lower alcohol grades. To examine the general morphology, haematoxylin and eosin (Abcam, Boston, MA, USA) were used to stain the sections (Eddleston &Chowdhury 2016).

Tissue Preparation for Transmission Electron Microscopy (TEM)

Heart specimens were immediately preserved and fixed in a 2.5 per cent glutaraldehyde solution (Glutaraldehyde 50% CAS 111-30-8) in 0.1 M sodium cacodylate buffer, pH 7.2, trimmed and sliced into one cubic millimetre pieces, and stored at 4°C for two hours. They were post-fixed in a sodium cacodylate buffer (Shanghai Sunwise Chemical Co., Lt China) containing 1% osmium tetroxide, then dehydrated in an ascending series of ethyl alcohol and cleaned in propylene oxide. The specimens were immersed in Araldite 502 to create gelatin capsules. The capsules were heated to 60 degrees Celsius for polymerization. A JEOL ultramicrotome was used to create and pick up 100 nm sections on copper grids. After being doubly dyed with lead citrate and uranyl acetate. With the help of a TEM, sections were examined and imaged (JEM-1011, JEOL Co., Tokyo, Japan) (Eid et al. 2021).

Estimation and Processing of Parameters

Animals were sacrificed via cervical dislocation at the end of the investigation, and the ileum was extracted to analyze several oxidative stress indicators.

Ileum Homogenate's Antioxidant Situation

Ileal tissues were homogenized in a solution of 100 m M tris–HCl (pH 7.4) and stirred for 12 hours at 4°C at 12,000 g. Measuring ileum antioxidant properties such as GPx yielded the supernatant (Salameh et al. 2015) and CAT activity (Aebi technique) (Craig 2019). Colorimetric methods were used to measure CAT and GPx in the ileum. The assays for thiobarbituric acid precursor (TBARS Assay Kit, Item No. 10009055, Cayman Chemical Company, Ann Arbor, MI, USA) was being used to screen MDA spectrophotometrically (indicator for lipid peroxidation).

Estimation of blood Levels of TNF-α and Il-6

TNF-α (ELISA kit BIOTANG INC, Cat, No R6365, Lexington, MA, USA) and IL-6 (ELISA kit BIOTANG INC., Cat. No. R6365, Massachusetts, USA) serum levels were tested using ELISA kits (ELISA Kit, BIOTANG INC., Cat. No. R6365, Massachusetts, USA) following the manufacturer's instructions after the rats were sacrificed.

Statistical Analysis

For n = 8 experiments, the mean standard deviation of averages is displayed. At a $p<0.05$ level, statistical significance is determined, an ANOVA was performed to analyze the data. For repeated measurements, a post hoc Tukey HSD test with Bonferroni was used. The statistical analysis was performed using Systat for Windows, version 13 (Systat Inc., Evanston, IL, USA).

Results

Biochemical data analysis

To see how much Vit C interacted with the control of these markers, we looked at antioxidant levels in tissues from all rat groups (Figure 1A, 1B) and inflammation (Figure 2A, 2B). QP lowered the antioxidant biomarker GPx (Figure 1A) and Cat by a significant ($p<0.05$) degree (Figure 1B). When matched to the QP group, both antioxidant enzymes were significantly increased by Vit C. As shown in Figure 2A, B, QP significantly increased ileum tissue injury ($p< 0.05$) whereas both inflammatory biomarkers were decreased as compared to the QP group.

Light microscopy (LM) Results

The ileum's crypts were lined with epithelial columnar cells, goblet cells, and conspicuous Paneth cells with brilliant red cytoplasmic granules in the rat group that served as a control. QP-treated rats' crypt architecture was altered, besides a raise in secretory cells in the crypts, together with Paneth cell metaplasia and granule discharge inside the cryptal lumen. The enlarged cryptal lining epithelial columnar cells had pale vacuolated cytoplasm and pale coloured nuclei. The number of goblet cells had declined significantly, and they seemed to be mucus-depleted. In majority of the crypts, the QP+Vit C-treated rats had intact crypts that are completely covered with epithelial columnar cells, goblet cells, some

damaged goblet cells, and conspicuous Paneth cells with brilliant red cytoplasmic granules (Figure 1A,1B,1C &1D).

Transmission electron microscopy (TEM) Results

A TEM investigation of the epithelium covering the ileal crypts in control rats indicated that the epithelium was largely made up of columnar absorbing cells with fewer goblet cells. Microvilli were found on the luminal surface of the columnar absorbing cells, together with basal oval euchromatic nuclei with prominent nucleoli. Its cytoplasm was densely packed with mitochondria, rough endoplasmic reticulum cisternae, few lysosomes, and a healthy intercellular space. In clusters around the base of the intestinal crypts, paneth cells with cytoplasm filled with huge spherical granules surrounded by halos were observed. The majority of the granules had electron dense basal regions with euochromatic nuclei. The QP group's intestinal villi underwent TEM investigation, which demonstrated disrupted cell architecture and a significant enlargement of the intercellular space. Microvilli were partially lost in the columnar absorbing cells. Some cells showed pyknotic nuclei with heterochromatin margination. The columnar absorbing cells also had many cytoplasmic vacuolations of various diameters including significant lateral interdigitations. Increased lysosomes, dilated and vesiculated rough endoplasmic reticulum that might be degranulated to some extent and enlarged mitochondria, all of them have a few short disintegrating cristae in their cytoplasm. Mucous globules of variable electron density appeared to exist in goblet cells. Granules with non-uniform sizes and electron-lucent halos around the granule periphery, a dilated and vesiculated rough endoplasmic reticulum, massive lysosomes and enlarged degenerated mitochondria were exhibited in Paneth cells.

The QP+Vit C group's intestinal integrity was similarly in correlation to the control group. The luminal surface of the columnar absorbing cells was completely covered with intact microvilli with its cytoplasm contained intact organelles and the goblet cells seemed to be normal, being distended with homogeneous electron density mucous globules. Paneth cells were observed to have spherical shape granules. Interdigitations in the lateral cells seemed to be parallel to those seen in the control. (Figure 4A, 4B, 4C, 4D & 5A, 5B, 5C, 5D)

Discussion

Organophosphorus poisoning is a public health issue, with 3,000,000 instances of poisoning and 220,000 deaths reported each year around the world, with the vast majority of cases occurring in developing countries (Craig 2019).

In the QP group, the antioxidant enzymes, CAT and GPx were shown to be decreased, which was linked to an elevation in MDA (biomarker for peroxidation) that's being used to evaluate oxidative stress indicators (OxS). This is in accordance with previous findings that also revealed that an increase in ROS formation causes OxS to be generated & it's attributed to a reduction in antioxidant defense system and an

alteration in the cell's redox state. OxS is generated when the synthesis and scavenging of oxygen-free radicals are out of equilibrium (Moretti et al. 2018).

The antioxidant defense system involves enzymes like CAT and GPx. GPx is a lipid peroxidation detector as well as a free radical scavenger. The radical transformation of reactive oxygen is catalyzed by the catalytic enzyme CAT. As a consequence, any alteration in the antioxidant machinery's components will lead to the formation of ROS, leading to oxidative stress insult in cells (Singh et al. 2020). The cell's primary line of protection versus oxidation-induced tissue injury is the antioxidant enzymes. GPx and CAT activity have been lost in ileal tissues could be the mechanism whereby the QP enhances cellular disorders and oxidative stress, resulting in lipid peroxidation, degenerative alterations and the buildup ROS within the cell (Elwej et al. 2017).

OxS changes the structure and function of cellular macromolecules, as well as the cell membrane, as a result of difficulties produced by elevated levels of inflammatory biomarkers (Jakubczyk et al. 2020). When QP ileum was in comparison to ileum of the control group, IL-6 and TNF-α cytokines were observed to be elevated in the blood. According to the findings of our investigation, TNF-α and IL-6 may play a substantial role. The inflammatory process in the gut of patients with intestinal inflammation is characterized by elevated cytokine levels, resulting in mucosal damage (Joshi et al. 2015). TNF-α has previously been accustomed to enhance intestinal permeability in patients with inflammatory bowel disease by inducing the release of epithelial myosin light chain kinase (Gareb et al. 2020). IL-6 is a pro-inflammatory cytokine that offers a wide range of pro-inflammatory actions. It has been established that it has a significant impact on the intestinal epithelial barrier and that it modulates intestinal epithelial tight junctions via claudin-2 gene activation (Kuhn et al. 2018, Zhang et al. 2015).

The microscopic features of QP-induced cytotoxicity on the ileal mucosa were investigated in this study. The QP group's columnar cells had histopathological changes, according to LM analysis. The nuclei of the cryptal wall epithelial tissue were pale tained and had pale vacuolated cytoplasm. Flattened and vacuolated enterocytes were identified in prior studies of QP-induced mucositis. In the QP-treated group of our analysis, the proportion of goblet cells was diminished, and they seemed mucus-depleted. Cryptal goblet cells decreased significantly in the rat’s small intestine after QP injection (Gillois et al. 2018).

In the present research, secretory cells in the crypts continued to increase, also Paneth cell metaplasia and granule release into the crypt lumen were seen. These granules are easily identified in histological sections due to their intense eosin staining. Paneth cells produce such granules apically through the overlying crypt lumen after proper stimulation, where they help remove any pathogenic microbes (Clevers &Bevins 2013). The QP group's ileum was examined using TEM, which demonstrated significant ultrastructural alterations. The cell configuration of crypts was disrupted, with broadened intercellular spaces observed. Previously, similar findings in the small intestine were reported (Abe et al. 2015).

Columnar cells in the QP group showed areas of substantial loss of microvilli, cytoplasmic vacuolations, and ultrastructural degenerative changes incorporating cell organoids. Paneth cells exhibited degenerative alterations, cytoplasmic vacuolations, and autophagic vacuoles. Among the changes were

patchy disruption and dissolution of the microvilli, enlarged mitochondria, some pyknotic nuclei, cytoplasmic vacuolations and endoplasmic reticulum dilatation. The accumulation of lipid peroxidation products caused by an increase in ROS level was essential for mitochondrial expansion and degradation; the same process could explain the mitochondrial damage seen in epithelial cells in our study (Chen et al. 2017).

Electron microscopy revealed cytoplasmic vacuolations in the ileal epithelial cells of the QP group, which might be caused by dilated organelles (rough endoplasmic reticulum and mitochondria), autophagic vacuoles, or hydropic degeneration. On a microscopic level, the injured cells have vacuoles in the cytoplasm with no apparent borders (Moriarty 1969).

Atypical Paneth cells with non-uniform granule diameters and electron-lucent halos at the granule periphery were identified in the QP-treated group. In the small intestine, Paneth cells are important for microbial growth regulation because they produce a variety of chemicals, such as the Wnt protein, that help to maintain the surrounding intestinal stem cell compartment, modulate stem cell proliferation, and build crypt architecture (Mei et al. 2020). Antimicrobial-containing granules discharged into the crypt lumen penetrate the mucus layer and extend outward towards the lumen, protecting the crypts from potentially hazardous microbes. Antimicrobials produced by Paneth cells have been shown to have a significant impact on the bacterial community in the small intestine, lowering total microbial numbers and altering bacterial composition (Wehkamp &Stange 2020, Yokoi et al. 2019).

The histological structure of the ileal mucosa was virtually entirely recovered in the QP and Vit C-treated group. The presence of intact microvilli with a consistent and well-defined brush border, as well as goblet cells packed with mucous granules, was confirmed by TEM analysis. The enzyme paraoxonase, which is concerned in the detoxification of organophosphorus insecticides, has been reported to enhance Vit C activity (Robea et al. 2020). Other minor antioxidant molecules, such as glutathione, urate, and beta-carotene, can be produced from their respective radical species (Medithi et al. 2021). Vit C is a water-soluble antioxidant that has been demonstrated to lower oxidative stress and neutralize ROSs by donating a hydrogen atom to make an ascorbyl-free radical that is adequately stable (Arruda et al. 2013).

In conclusion, this research's findings indicate that in QP-treated rats, Vit C co-administration protects against ileal dysfunction. Furthermore, Vit C mitigates the oxidative damage caused by QP. Vit C may play a role in ileal free radical generation by regulating it.

Declarations

Funding:

This research at King Khalid University in Abha, Saudi Arabia, was totally financed by the Deanship of Scientific Research (Grant No. G.R.P. 01-21-42).

Data Availability Statement

The data supporting the study's findings are available upon request.

Ethics statement

All animal studies followed King Khalid University's College of Medicine's rules for using animals in scientific research. These recommendations are based on international guidelines created by the National Institutes of Health for the care and use of laboratory animals (NIH Publications No. 8023, revised 1978).

Author Contributions:

Mohamed Samir Ahmed Zaki conceived and designed the study, and they rigorously revised the manuscript. Mohamed Samir Ahmed Zaki performed most of the experiments and analyzed the results and drafted the manuscript. Hussah I.M. AlGwaiz, Abulqasim M. Sideeg and Mohamed Andarawi helped collect samples and participated in the study preperation. Attalla F. El-kott and Refaat A. Eid participated in the experiment and analyzed the results. Attalla F. El-kott participated in result analysis of biochemical indicators. All authors read and approved the final manuscript.

Consent to participate

Informed consent was obtained from all individual participants included in the study.

Consent for publication

Consent was obtained from participants about publishing their data.

Competing interests

The authors have no relevant financial or non-financial interests to disclose.

References

1. Abe R, Toyota K, Miyakawa H, Watanabe H, Oka T, Miyagawa S, Nishide H, Uchiyama I, Tollefsen KE, Iguchi T, Tatarazako N (2015): Diofenolan induces male offspring production through binding to the juvenile hormone receptor in Daphnia magna. Aquatic toxicology (Amsterdam, Netherlands) 159, 44-51
2. Arruda MM, Mecabo G, Rodrigues CA, Matsuda SS, Rabelo IB, Figueiredo MS (2013): Antioxidant vitamins C and E supplementation increases markers of haemolysis in sickle cell anaemia patients: a randomized, double-blind, placebo-controlled trial. British journal of haematology 160, 688-700
3. Castro VMR, da Mota Silva M, Prudêncio de Souza ER, Guerra AF, Riger CJ, Laureano-Melo R, Luchese RH (2021): Role of milk and honey in the tolerance of lactobacilli to oxidative stress. Brazilian journal of microbiology : [publication of the Brazilian Society for Microbiology] 52, 883-893
4. Chen T, Tan J, Wan Z, Zou Y, Afewerky HK, Zhang Z, Zhang T (2017): Effects of Commonly Used Pesticides in China on the Mitochondria and Ubiquitin-Proteasome System in Parkinson's Disease.

International journal of molecular sciences 18

5. Chowdhary S, Bhattacharyya R, Banerjee D (2014): Acute organophosphorus poisoning. Clinica chimica acta; international journal of clinical chemistry 431, 66-76
6. Clevers HC, Bevins CL (2013): Paneth cells: maestros of the small intestinal crypts. Annual review of physiology 75, 289-311
7. Craig K (2019): A Review of the Chemistry, Pesticide Use, and Environmental Fate of Sulfur Dioxide, as Used in California. Reviews of environmental contamination and toxicology 246, 33-64
8. Eddleston M, Chowdhury FR (2016): Pharmacological treatment of organophosphorus insecticide poisoning: the old and the (possible) new. British journal of clinical pharmacology 81, 462-70
9. Eid RA, Zaki MSA, Al-Shraim M, Eldeen MA, Haidara MA (2021): Grape seed extract protects against amiodarone - induced nephrotoxicity and ultrastructural alterations associated with the inhibition of biomarkers of inflammation and oxidative stress in rats. Ultrastructural pathology 45, 49-58
10. Elwej A, Ghorbel I, Chaabane M, Soudani N, Marrekchi R, Jamoussi K, Mnif H, Boudawara T, Zeghal N, Sefi M (2017): Protective effects of dietary selenium and vitamin C in barium-induced cardiotoxicity. Human & experimental toxicology 36, 1146-1157
11. Gareb B, Otten AT, Frijlink HW, Dijkstra G, Kosterink JGW (2020): Review: Local Tumor Necrosis Factor-α Inhibition in Inflammatory Bowel Disease. Pharmaceutics 12
12. Gillois K, Lévêque M, Théodorou V, Robert H, Mercier-Bonin M (2018): Mucus: An Underestimated Gut Target for Environmental Pollutants and Food Additives. Microorganisms 6
13. He Y, Li Z, Tan F, Liu H, Zhu M, Yang H, Bi G, Wan H, Wang J, Xu R, Wen W, Zeng Y, Xu J, Guo W, Xue S, Cheng Y, Deng X (2019): Fatty acid metabolic flux and lipid peroxidation homeostasis maintain the biomembrane stability to improve citrus fruit storage performance. Food chemistry 292, 314-324
14. Hu H, Liu X, Jiang F, Yao X, Cui X (2010): A novel chemiluminescence assay of organophosphorous pesticide quinalphos residue in vegetable with luminol detection. Chemistry Central journal 4, 13
15. Jakubczyk K, Dec K, Kałduńska J, Kawczuga D, Kochman J, Janda K (2020): Reactive oxygen species - sources, functions, oxidative damage. Polski merkuriusz lekarski : organ Polskiego Towarzystwa Lekarskiego 48, 124-127
16. Joshi L, Ponnana M, Sivangala R, Chelluri LK, Nallari P, Penmetsa S, Valluri V, Gaddam S (2015): Evaluation of TNF-α, IL-10 and IL-6 Cytokine Production and Their Correlation with Genotype Variants amongst Tuberculosis Patients and Their Household Contacts. PloS one 10, e0137727
17. Khazaie S, Jafari M, Heydari J, Asgari A, Tahmasebi K, Salehi M, Abedini MS (2019): Modulatory effects of vitamin C on biochemical and oxidative changes induced by acute exposure to diazinon in rat various tissues: Prophylactic and therapeutic roles. Journal of animal physiology and animal nutrition 103, 1619-1628
18. Kuhn KA, Schulz HM, Regner EH, Severs EL, Hendrickson JD, Mehta G, Whitney AK, Ir D, Ohri N, Robertson CE, Frank DN, Campbell EL, Colgan SP (2018): Bacteroidales recruit IL-6-producing intraepithelial lymphocytes in the colon to promote barrier integrity. Mucosal immunology 11, 357-368

19. Kumar S, Kaushik G, Villarreal-Chiu JF (2016): Scenario of organophosphate pollution and toxicity in India: A review. Environmental science and pollution research international 23, 9480-91
20. Medithi S, Jonnalagadda PR, Jee B (2021): Predominant role of antioxidants in ameliorating the oxidative stress induced by pesticides. Archives of environmental & occupational health 76, 61-74
21. Mei X, Gu M, Li M (2020): Plasticity of Paneth cells and their ability to regulate intestinal stem cells. Stem cell research & therapy 11, 349
22. Moretti S, Mrakic-Sposta S, Roncoroni L, Vezzoli A, Dellanoce C, Monguzzi E, Branchi F, Ferretti F, Lombardo V, Doneda L, Scricciolo A, Elli L (2018): Oxidative stress as a biomarker for monitoring treated celiac disease. Clinical and translational gastroenterology 9, 157
23. Moriarty F (1969): The sublethal effects of synthetic insecticides on insects. Biological reviews of the Cambridge Philosophical Society 44, 321-57
24. Moritoki H, Ishida Y (1977): Aspects of the spasmogenic effects of acetate esters on ileal smooth muscle. European journal of pharmacology 42, 347-54
25. Rahman MF, Mahboob M, Grover P (2004): In vitro acetylcholinesterase inhibition by novel OP compounds in various tissues of the fish Channa punctatus. Bulletin of environmental contamination and toxicology 72, 38-44
26. Ranjbar A, Pasalar P, Abdollahi M (2002): Induction of oxidative stress and acetylcholinesterase inhibition in organophosphorous pesticide manufacturing workers. Human & experimental toxicology 21, 179-82
27. Robea MA, Jijie R, Nicoara M, Plavan G, Ciobica AS, Solcan C, Audira G, Hsiao CD, Strungaru SA (2020): Vitamin C Attenuates Oxidative Stress and Behavioral Abnormalities Triggered by Fipronil and Pyriproxyfen Insecticide Chronic Exposure on Zebrafish Juvenile. Antioxidants (Basel, Switzerland) 9
28. Salameh A, Halling M, Seidel T, Dhein S (2015): Effects of minocycline on parameters of cardiovascular recovery after cardioplegic arrest in a rabbit Langendorff heart model. Clinical and experimental pharmacology & physiology 42, 1258-65
29. Samare M, Samareh AN, Safari S, Zaree R, Moghadam D, Azhdarpoor A, Badeenezhad A, Rostami S (2020): A survey of the secondary exposure to organophosphate and organochlorine pesticides and the impact of preventive factors in female villagers. Chemosphere 240, 124887
30. Singh P, Verma PK, Raina R, Sood S, Sharma P (2020): Maximum contaminant level of arsenic in drinking water potentiates quinalphos-induced renal damage on co-administration of both arsenic and quinalphos in Wistar rats. Environmental science and pollution research international 27, 21331-21340
31. Teng J, Pourmand A, Mazer-Amirshahi M (2018): Vitamin C: The next step in sepsis management? Journal of critical care 43, 230-234
32. Vieira CED, Dos Reis Martinez CB (2018): The pyrethroid λ-cyhalothrin induces biochemical, genotoxic, and physiological alterations in the teleost Prochilodus lineatus. Chemosphere 210, 958-967

33. Wehkamp J, Stange EF (2020): An Update Review on the Paneth Cell as Key to Ileal Crohn's Disease. Frontiers in immunology 11, 646
34. Yokoi Y, Nakamura K, Yoneda T, Kikuchi M, Sugimoto R, Shimizu Y, Ayabe T (2019): Paneth cell granule dynamics on secretory responses to bacterial stimuli in enteroids. Scientific reports 9, 2710
35. Zhang YG, Wu S, Lu R, Zhou D, Zhou J, Carmeliet G, Petrof E, Claud EC, Sun J (2015): Tight junction CLDN2 gene is a direct target of the vitamin D receptor. Scientific reports 5, 10642
36. Znamirowska A, Szajnar K, Pawlos M (2021): Effect of Vitamin C Source on Its Stability during Storage and the Properties of Milk Fermented by Lactobacillus rhamnosus. Molecules (Basel, Switzerland) 26

Figures

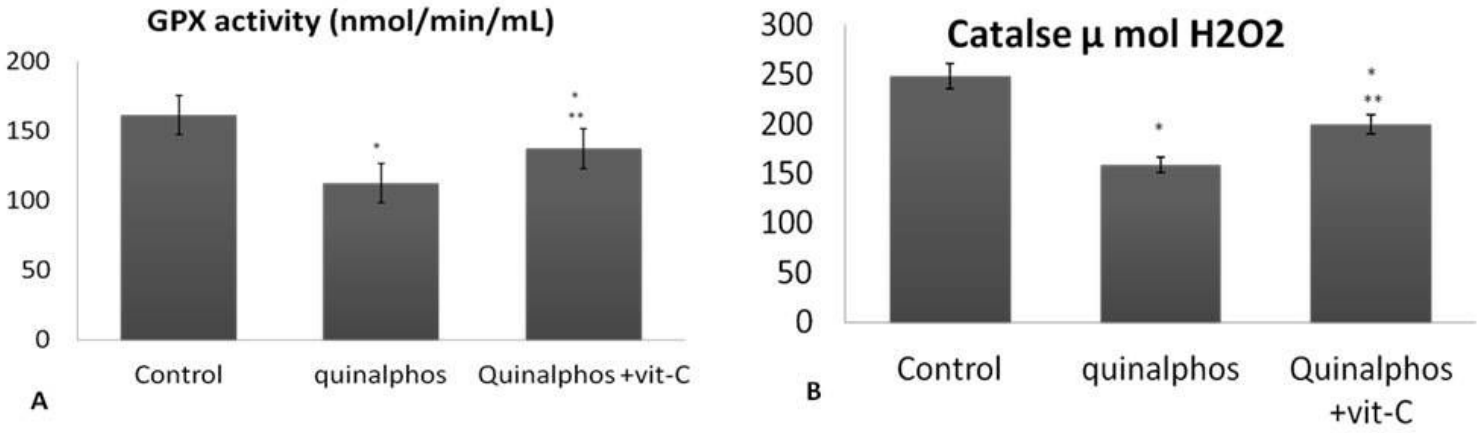

Figure 1

Vit C protects rats from QP-induced oxidative stress and decreases antioxidant biomarkers. At the end of the study, the values of GPx (A), Cat (B), and MDA (C) in ileum homogenates were assessed in the three groups of rats included in this study: control, QP, and QP + Vit C. The findings are the mean (±SD) f; n = 6. Experiments were carried out in triplicate. * $p < 0.05$ in comparison to control group, *** $p < 0.05$ in contrast to QP group.

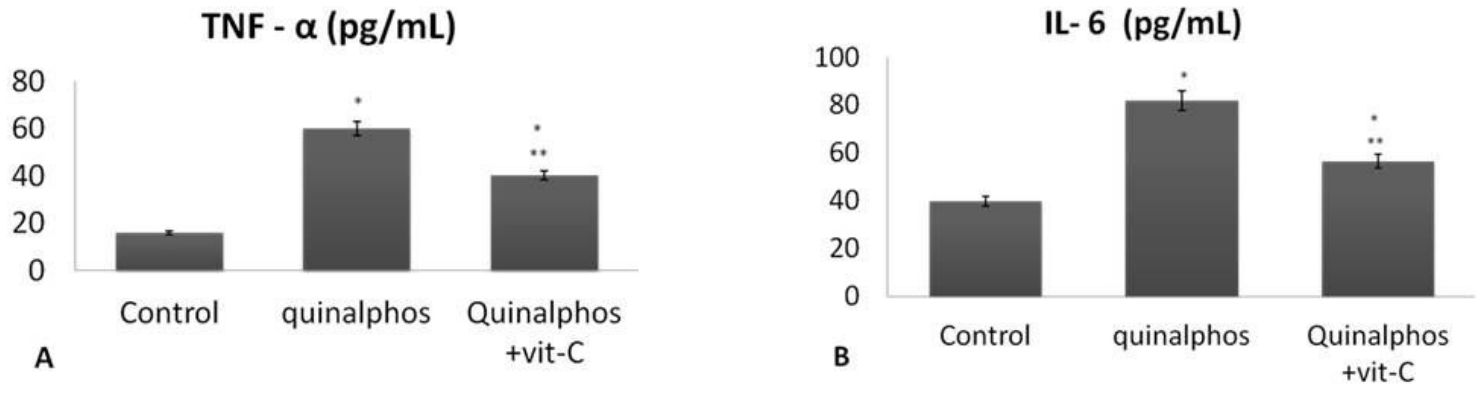

Figure 2

In rats, Vit C suppresses QP-induced inflammatory indicators. The levels of TNF-α (A) and IL-6 (B) in the blood of three groups of rats were measured at the end of the experiment: control, QP, and QP + Vit C. The findings are the mean (SD) for each group; n = 6. Experiments were carried out in triplicate. * $p < 0.05$ in comparison to control, *** $p < 0.05$ in comparison to QP group.

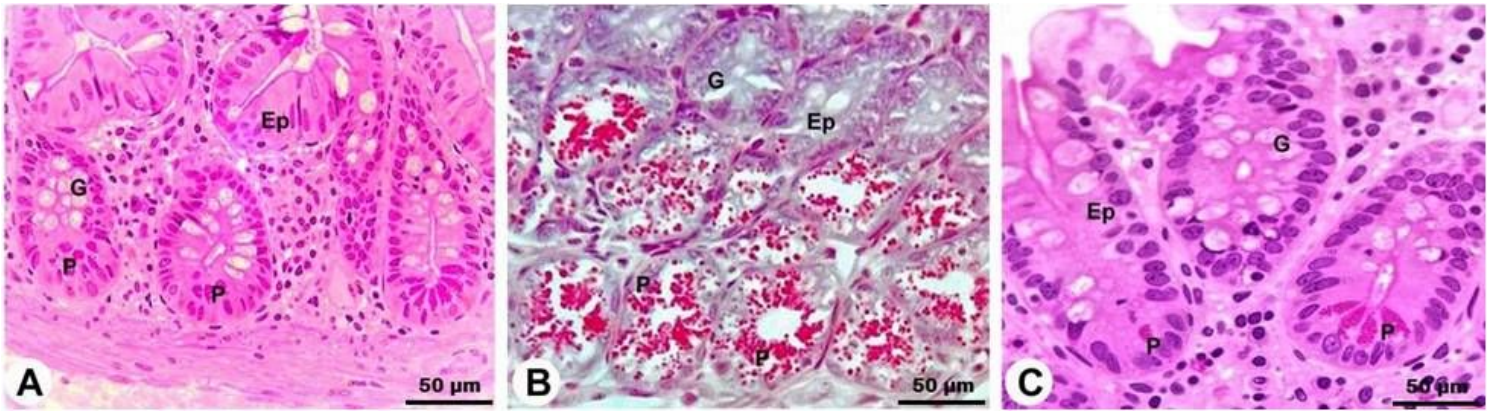

Figure 3

Light micrographs of the rat atrial muscles have been utilized from all groups. (X400; H&E)

A. Control rat's group displaying crypts of the ileum consisting of crypts are lined with epithelial columnar cells (Ep), goblet cells (G) and prominent Paneth cells (P) with bright red cytoplasmic granules.

B. QP-treated rat's group exhibiting disturbed crypt architecture with an increase in secretory cells in the crypts with differentiation of Paneth cell (P) metaplasia and granule release into the crypt lumen. The crypt lining epithelial columnar cells (Ep) are enlarged with pale vacuolated cytoplasm and pale stained nuclei. The goblet cells (G) are markedly decreased in number appear depleted of mucus.

C. QP+VIT C treated rat's group exhibiting intact crypts that are completely covered with epithelial columnar cells (Ep), goblet cells (G) and prominent Paneth cells (P) with bright red cytoplasmic granules in most of the crypts. Some disrupted goblet cells are seen.

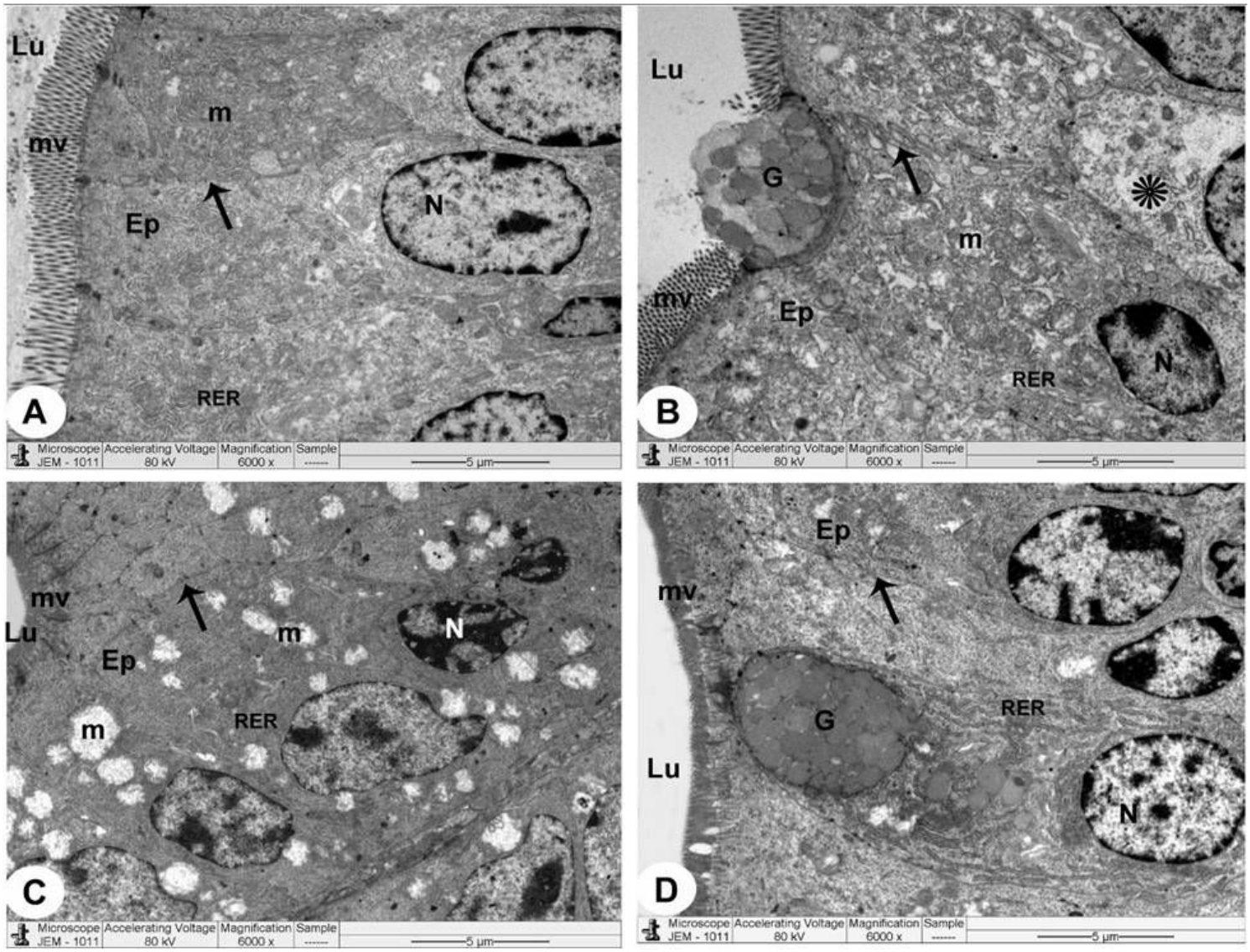

Figure 4

The ileum is imaged using TEM in all groups of rats. (x6000)

A. **Control rat group** showing intestinal epithelial cells (Ep) lining of the crypts of the ileum. The columnar absorbing cells have apical microvilli (mv) which are of uniform length and size that constitutes the brush border towards the lumen (Lu), intact mitochondria (M) and normal rough endoplasmic reticulum (RER) are seen within the epithelial cells. Intact intercellular spaces (arrow) and basal active euochromatic nuclei (N) are also seen.

B. **QP-treated rat's group** exhibiting intestinal epithelial cells (Ep) lining of the crypts of the ileum with disturbed cell architecture. The intercellular Spaces (arrow) between the cryptal cells are widened but the cells are still bound to each other by cytoplasmic extensions. Areas of partial loss of microvilli (mv) are observed in the columnar absorbing cells. The Mitochondria (M) show disintegrated cristae and disrupted rough endoplasmic reticulum (RER). Goblet cells (G) are distended with variable electron density mucous

globules, pyknotic shrunken nuclei (N) with margination of heterochromatin and large vacuoles (*) area also seen intracellular.

C. **QP-treated rat's group** exhibiting widened intercellular spaces (arrow) in between two adjacent columnar absorbing cells. Vesiculated RER are observed and some are partly degranulated. The Mitochondria (M) show complete dissuasion with disintegrated cristae.

D. **QP+VIT C treated rat's group** revealing the absorbing cells are more or less similar to the control group and contain, more or less, intact organelles. The luminal surface (Lu) is completely covered with regular long microvilli (MV) and the lateral interdigitations (arrow) present between adjacent cells are similar to those of the control. Goblet cells (G) are distended with homogenous mucous globules.

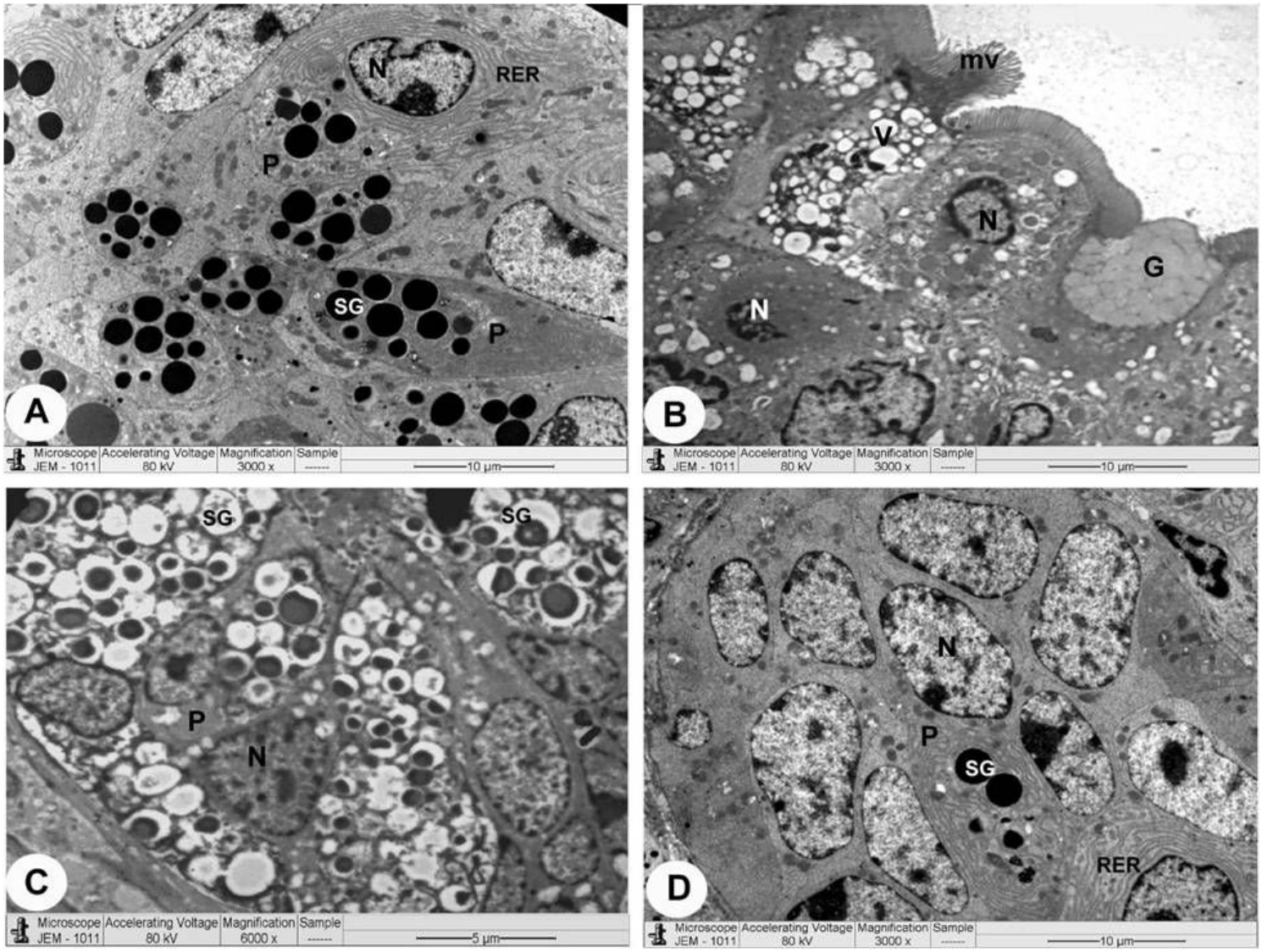

Figure 5

The ileum is imaged using TEM in all groups of rats.

A. Control rat's group displaying the Paneth cells (P) of the small intestine showing basal nuclei (N) with prominent nucleolus and large secretory granules (SG) with a protein core surrounded by a halo of polysaccharide-rich material. Paneth cells displayed orderly, stacked rough endoplasmic reticulum (RER) cisternae around nuclei. (x 3000).

B. QP-treated rat's group exhibiting intestinal epithelial cells (Ep) with many lipid vacuoles (V) inside, herniation of microvilli (Mv) and a goblet (Go) cells. Also, atrophic pyknotic nuclei (N) are seen. (x 3000)

C. QP-treated rat's group exhibiting abnormal Paneth cells (P) that contain granules of non-uniform size with electron-lucent halos in the granule periphery. (x 6000)

E. QP+Vit C treated rat's group demonstrating Paneth cells (P) of the ileum with nuclei (N) and prominent nucleolus and large secretory granules (SG) are more or less similar to the control and contain, more or less, intact organelles. (x 3000)