Solo Surgery in Single Incision Laparoscopic Myomectomy

Do Young Chung (jsgp@naver.com)

Original Article

Keywords: Solo surgery, Myomectomy, Single incision laparoscopic surgery, Camera holder, Uterine manipulation

Posted Date: December 22nd, 2020

DOI: https://doi.org/10.21203/rs.3.rs-124916/v1

Abstract

Background

The intracorporeal suture during single incision laparoscopic surgery is challengeable. Since laparoscopic myomectomy requires not only one assistant to hold a camera but also other to hold the uterine manipulator, it is difficult to perform solo surgery in single port laparoscopic myomectomy through intracorporeal suture.

Results

The three patients underwent single incision laparoscopic myomectomy. The size of the largest myoma was 4.8-5.6cm. The operation was performed by the surgeon alone without assistants. The passive camera holder was positioned near the patient's body. Without using uterine manipulator, the uterus was hung from the abdominal wall using a thread. The uterine myoma was enucleated, which was removed from the outside with the umbilicus incision site. The uterine wound was double sutured to avoid any uterine defects. The outer suture of wound was sutured by a method such as simple continuous suture, Lembert suture, or baseball suture. The operation time was 95-105 minutes.There were no specific complications associated with the surgery. The patients were discharged on the second day after surgery.

Conclusions

Solo surgery in single incision laparoscopic myomectomy using camera holder was successfully performed without using a uterine manipulator.

Background

Not only the surgeon but also the assistants participate in laparoscopic myomectomy. The assistants play an important role in securing enough space for surgery, removing uterine myoma and suturing the surgical site. Typically, one assistant holds the camera to illuminate the surgical site and the other moves the uterus to an appropriate position using the uterine manipulator. In single incision laparoscopic surgery, if several laparoscopic instruments enter into one narrow space of a single hole, they may bump into each other or the angle required for the operation of each instrument may not come out. Since the intracorporeal suture during single incision laparoscopic surgery is difficult, new attempts to solve them have been sought(1).

Recently, single incision laparoscopic surgery has been reported in which the surgeon performs the operation alone without the help of an assistant(2). For solo approach of single incision laparoscopic surgery, various camera holders are being developed(3). Most of the solo surgery was performed in the department of general surgery, and ovarian cystectomy or oophorectomy were rarely performed in the department of obstetrics and gynecology(4). Since laparoscopic myomectomy requires not only one

assistant to hold a camera but also other to hold the uterine manipulator, it is difficult to perform solo surgery in single port laparoscopic myomectomy through intracorporeal suture.

In this paper, a single incision laparoscopic myomectomy using camera holder was successfully performed using the technique of hanging the uterus to the abdominal wall without using a uterine manipulator. As the surgical procedure is shared, it is intended to be a cornerstone for the clinical application of solo surgery in single incision laparoscopic myomectomy(Solo-SILM).

Materials And Methods

Case 1

A 49-year-old woman came to the hospital due to menorrhagia and dysmenorrhea. The menstruation was periodic, but the amount of menstruation was high. After the hospital visit, hemoglobin level was confirmed to be 8.1 g/dL, and an iron injection was prescribed several times. Ultrasonography revealed a 4.1 cm-sized submucosal type of uterine myoma that pressed the endometrium. Serum CA-125 levels were slightly elevated to 52.7 u/ml. The body mass index was 23.4 kg/m^2. I had obtained informed consent from the patient for this case. The uterus observed in the operating field has a thickened posterior wall. There were no specific abnormalities in both adnexa. The intestine and omentum were adhered to the left low abdominal wall, but did not interfere with the operation. A 10 mm, 30 degree camera(AESCULAP, Tullingen, Germany) was used for the surgical procedure. When the myoma was visible, the myoma were captured using a 5 mm screw. The incision in the uterus was double sutured using V-loc™(Covidien, Mansfield, MA, USA) after the uterus was removed. The inner and outer sutures of uterine wound were simple continuous sutures.(Fig. 1) There were no special complications during and after the surgery. The patient were discharged from the hospital on the second day after surgery.

Case 2

A 58-year-old woman came to the hospital for a general gynecological examination. The patient became menopause at the age 51. Several myomas were found on ultrasound. I had obtained informed consent from the patient for this case. The size of the intramural type myomas was 5.5 cm at posterior part, 1.6 cm, 1.5 cm, and 1.2 cm at the anterior part. The patient was worried about the presence of the uterine myomas and wanted to be removed surgically. The body mass index was 22.0 kg/m^2. Four myomas were observed in the uterus as a finding of the operating field. There were no specific abnormalities in both adnexa. 5 mm, 0 degree camera(AESCULAP, Tullingen, Germany) and 10 mm screw were used for the surgical procedure. The uterine wound was double-sutured with 1.0 vicryl((Ethicon,. Sommerville, USA). The inner suture of wound was made with simple continuous suture and the outer suture was made with Lembert suture(Fig. 2). There were no special complications during and after the surgery. The patient were discharged from the hospital on the second day after surgery.

Case 3

A 48-year-old woman with dysmenorrhea visited the hospital for gynecological management. Intramural type myomas of 4.9 cm, 1.9 cm, 1.3 cm, 1.2 cm and 1.1 cm size were detected by ultrasound. The body mass index was 23.9 kg/m^2. I had obtained informed consent from the patient for this case. The largest myoma was located in the left posterior part of the uterus. There were no specific abnormalities in both adnexa. 10 mm, 30 degree camera(AESCULAP, Tullingen, Germany) and 10 mm screw were used for the surgical procedure. The wound on the uterus was double-sutured with V-loc™(Covidien, Mansfield, MA, USA). The inner suture of wound was made with simple continuous suture and the outer suture was made with baseball suture(Fig. 3). There were no special complications during and after the surgery. The patient were discharged from the hospital on the second day after surgery.

Surgical technique

The patient was placed in a lithotripsy position under general anesthesia. The surgeon was placed on the left side of the patient after the patient's left arm was adducted. The diathermy pedal is placed near the surgeon’s left foot. The monitor was located below the patient’s right leg. The skin at the umbilicus was incised 2.0 cm longitudinally. A glove port with four channels (Nelis, Bucheon-si, Gyeonggi-do, Republic of Korea) was inserted into the incision. The abdomen was insufflated with CO2 to a pressure of 12 mmHg. The passive camera holder (Endoworld®LAP53 Holding Systems, Karl Storz, Tullingen, Germany) was installed close to the body on the right side of the patient. (Fig. 4) A 10 mm, 30 degree or 5 mm, 0 degree camera(AESCULAP, Tullingen, Germany) was used for the surgical procedure. A needle of 1.0 vicryl((Ethicon, Sommerville, USA) was inserted into the abdominal cavity from the lower part of the abdomen to the outside of the body. The needle that came out of the abdominal cavity was pulled with a needle holder. Suture was made to avoid myoma. In other words, case 1 was sutured in the fundus and case 2 or case 3 was sutured in the uterine anterior body. After suturing, the needle with a thread was pulled out of the skin. The uterus was lifted against the abdominal wall by pulling the two threads that came out of the body(Fig. 5). The two threads with the uterus remaining were fixed over the skin with kelly. The method of lifting the uterus was introduced as the hitch technology(5). 20 ml of vasopressin at a concentration of 10 IU/100 ml of saline solution was infiltrated up to at several points at the base of myoma before the incision. The uterus was incised longitudinally using a molopolar scissors. When the myoma was visible, the myoma were captured using a screw. The outer periphery of the uterine myoma was enucleated using an energy device (Caiman®; Aesculap AG, Tuttlingen, Germany). There was hemostasis with bipolar forcep while checking for bleeding in the incision site of the uterus. The incision in the uterus was double sutured using V-loc™(Covidien, Mansfield, MA, USA) or 1.0 vicryl((Ethicon, Sommerville, USA). The outer suture of wound was sutured by a method such as simple continuous suture, Lembert suture, or baseball suture. On the outside of the body, kelly was released and the thread was removed. The bleeding points of the uterus were hemostated with a bipolor forcep. Drainage was inserted to remove blood accumulated in the pelvic cavity and saline that had been irrigated. The uterine myoma was removed from the outside with the umbilicus incision site. After interrupted suturing the fascia and skin of the umbilicus, the operation was completed.

Discussion

The intracorporeal suture during single incision laparoscopic surgery is very difficult because various instruments must be properly triangulated in the narrow single space(1). Since the uterine wound should be closed in double or triple after myoma are removed, the cooperation between the surgeon and the assistant is more important in single incision laparoscopic myomectomy. Recently, various camera holder for solo surgery has been developed, and some cases of solo single incision laparoscopy have been reported in obstetrics and gynecology, but the scope of application is still limited(4). These cases were the first trial of solo surgery of single incision laparoscopic myomectomy without using a uterine manipulator.

Unlike the case where the operation was accompanied by an assistant, there were several things to consider when performing the operation alone as in these cases. The first is related to the camera manipulation. When the surgeon's arm and camera holder collided during the suturing process in which both hands must be used freely, the suture was difficult. In this sense, the camera holder needed to be installed close to the patient's body. The camera holder used in these cases has the advantage that the position does not change once the position is fixed, but it has the disadvantage of having to move manually using two hands. In this respect, it was difficult to proceed with the surgery when the camera location had to be changed frequently. Fixing the camera as far away from the surgical site in the abdominal cavity as possible was helpful because it would not change its position often. Various types of camera holders have been produced. Some can be operated with one hand even if the position is slightly changed (6–9). Although the speed is somewhat slow and it is difficult to select a position, there are some that are operated by foot, voice or head motion instead of hands (10–13). Therefore, it is believed that a suitable camera holder should be selected in surgery where the camera position is frequently changed. Using a 5 mm camera provided more space for surgery in case 2, but the 10 mm camera had a clearer field of view, which was useful during surgery in case 1 and case 3. The 10 mm screw had good gripping power for the myoma in case 2 and case 3, but the space utilization was lower than the 5 mm screw in case 1. When used with a camera, the best combination was considered a 10 mm, 30 degree camera and a 10 mm screw in case 1. When uterus was hung on the abdominal wall using a thread, the 30 degree camera was more useful than 0 degree when holding the needle or suturing the uterus. Solo surgery was difficult when the camera field of view was blurred. The use of energy devices created gases and blured the camera's view. If a assistant participated in the surgery, the camera would have been removed from the body and wiped. In solo surgery, the operator first inserted a suction and irrigation device to remove the gas, then sprayed water on the uterus, and then wiped the camera lens to eliminate the clouding of the camera's vision. Second, it is related to myoma enucleation and suture technique. When the uterus was incised longitudinally rather than transversely, it became easier to close the wound. The reason was that suturing was possible only when the surgical instruments were kept parallel without crossing the abdominal cavity. To reduce the incidence of bleeding during surgery, vasopressin was applied before uterine incision. When enucleating myoma, the use of an energy device was useful because hemostasis and resection were performed at the same time. Even without clamping the uterine artery, the myoma could be enucleated only with the above two methods. Since myoma was

removed, a double suture was performed to suture the outer side after suturing the inner side to prevent defects in the uterus. Barbed suture was useful as it prevented the thread from loosening in case 1 and case 3. Lembert suture or baseball suture was used to compensate for intrauterine defects in case 2 and case 3. A rigid conventional instruments in these cases were used for solo surgery. Although the these instruments were not bent, there were no particular problems with the suture process.

There are several limitations that make it difficult to widely apply solo surgery to clinical applications in the future. First, it is an emergency situation where excessive bleeding occurs. In order to stop bleeding, suction and irrigation devices may additionally be used to check the bleeding area as well as the grasping forcep and bipolar forcep. The surgeon may encounter difficulties because he must use three types of instruments with both hands. When active bleeding occurs, blood may run on the camera lens, making it difficult to secure the camera's field of view. To clean the camera lens in the abdominal cavity without removing the blood-stained camera outside, the surgeon may need to use four types of instruments with both hands. There is a limit to controlling the bleeding quickly by the surgeon alone. Secondly, there is severe adhesion in the abdominal cavity. Depending on the area and degree of adhesion, the position of the camera cannot be fixed and needs to be changed frequently. When the adhesion site is excised after electrocautery, gas is generated and the camera field of view becomes cloudy. In this situation, it is difficult to perform the operation by the surgeon alone without an assistant helping to manipulate the camera. Third is the participation of assistant who lack experience in laparoscopic surgery. If solo surgery is performed frequently, the assistant's skills cannot be improved. It is difficult to receive great help from less-trained assistant when the solo surgery is stopped and assistants participate in emergency situations. The fourth is related to uterine myoma. Depending on the location, size, and number of myoma, solo surgery can be difficult during the suture process. If myoma is in the anterior portion of the uterus or the number of myoma is large, the location of the threads should be selected so that the thread that lifts the uterus and the thread that sutures do not overlap.

Conclusions

Solo incision laparoscopic surgery has the advantage of avoiding collision with an assistant during surgery, and allowing surgeon to set the camera direction as desired. And by using the seat where an assistant was, the surgeon can use both hands more widely. In these cases, solo single incision laparoscopic myomectomy was successfully performed without using a uterine manipulator.

Abbreviations

Solo-SILM : solo surgery in single incision laparoscopic myomectomy

Declarations

Availability of data and materials

All cases have been done at our hospital. All data including photos have beeb available in clinical charts at our department.

Acknowledgements

Not applicable

Disclosure statement

All authors disclose that this data has not been published or presented elsewhere, and the manuscript is not under review at any other journal. We declare no conflict of interest.

Funding

There are no external funds

Author information

Affiliations

Department of obstetrics and gynecology, Mediplex Sejong hospital, Incheon, Republic of Korea

Do Young Chung

Contributions

SA conceived the idea, performed the operation, analyzed the material, and wrote the paper. The author read and approved the final manuscript.

Ethics declarations

Ethics approval and consent to participate

Each patient gave detailed written informed consent for the procedure as well as for the publication text and accompanying images.

Competing interests

The author declares that they have no competing interests. Authors' interpretation of data or presentation of information is not influenced by any personal or financial relationship with other people or organizations.

Additional information

Publisher's Note

Springer Nature remains neutral with regard to jurisdictional claims in published maps and institutional affiliations.

Rights and permissions

References

1. D.Y. Chung. The intracorporeal knot tying using rigid instruments in single-incision laparoscopic surgery. Surg Laparosc Endosc Percutan Tech.2013;23(3):e90-2.

2. S.J. Kim, B.J. Choi, S.C. Lee. Novel approach of single-port laparoscopic appendectomy as a solo surgery: A prospective cohort study. Int J Surg. 2015;21:1-7

3. S.J. Kim, S.C. Lee. Technical and instrumental prerequisites for single-port laparoscopic solo surgery: state of art. World J Gastroenterol. 2015;21(15):4440-4446

4. Y.S. Yang, S.H. Kim, C.H. Jin, K.Y. Oh, M.H. Hur, S.Y. Kim, H.S. Yim. Solo surgeon single-port laparoscopic surgery with a homemade laparoscope-anchored instrument system in benign gynecologic diseases. J Minim Invasive Gynecol. 2014;21(4):695-701.

5. S.P. Puntambekar, A.M. Patil, N.V. Rayate, S.S. Puntambekar, R.M. Sathe, M.A. Kulkarni. A novel technique of uterine manipulation in laparoscopic pelvic oncosurgical procedures: "the uterine hitch

technique". Minim Invasive Surg. 2010;2010:836027

6. Melzer A, Buess G, Cuschieri A. Instrument for endoscopic surgery. In: Cuschieri A, editors. Operative manual of Endoscopic Surgery 1992; 14-36
7. Lee YS, Jeon HG, Lee SR, Jeong WJ, Yang SC, Han WK. The feasibility of solo-surgeon living donor nephrectomy: initial experience using video-assisted minilaparotomy surgery. Surg Endosc. 2010; 24: 2755-2759
8. Arezzo A, Schurr MO, Braun A, Buess GF. Experimental assessment of a new mechanical endoscopic solosurgery system: Endofreeze. Surg Endosc. 2005; 19: 581-588
9. Laparostat. 2014, December 11. Available from: URL: https://www.yumpu.com/no/document/view/20462143/laparostattm-kitcivco-medical-solutions
10. Arezzo A, Ulmer F, Weiss O, Schurr MO, Hamad M, Buess GF. Experimental trial on solo surgery for minimally invasive therapy: comparison of different systems in a phantom model. Surg Endosc. 2000; 14: 955-959
11. Gillen S, Pletzer B, Heiligensetzer A, Wolf P, Kleeff J, Feussner H, Fürst A. Solo-surgical laparoscopic cholecystectomy with a joystick-guided camera device: a case-control study. Surg Endosc. 2014; 28: 164-170
12. Kalteis M, Pistrich R, Schimetta W, Pölz W. Laparoscopic cholecystectomy as solo surgery with the aid of a robotic camera holder: a case-control study. Surg Laparosc Endosc Percutan Tech. 2007; 17: 277-282
13. Yavuz Y, Ystgaard B, Skogvoll E, Mårvik R. A comparative experimental study evaluating the performance of surgical robots aesop and endosista. Surg Laparosc Endosc Percutan Tech. 2000; 10: 163-167

Figures

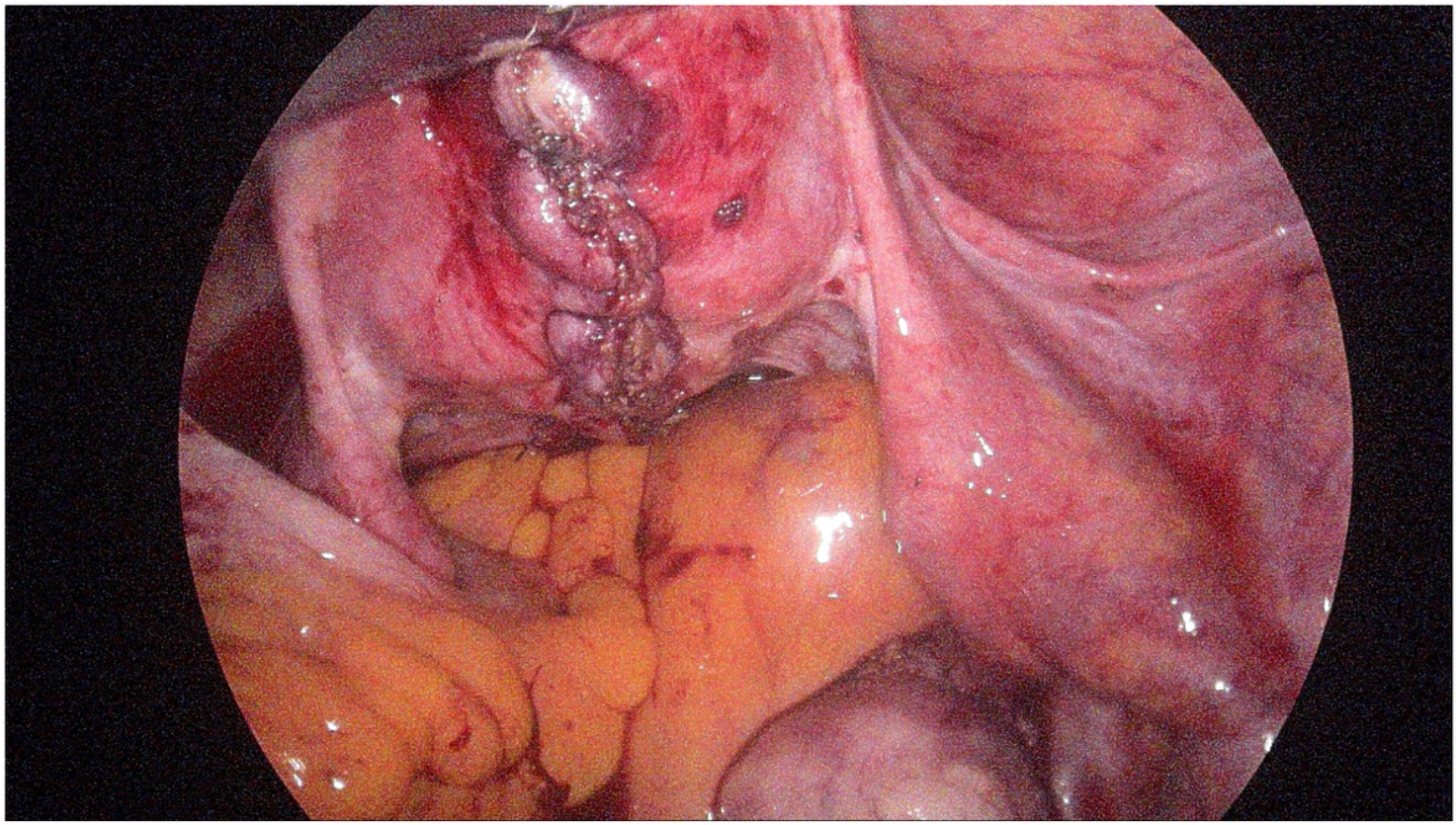

Figure 1

Suture of the uterine wound in case 1. The wound was double sutured simple continuous suture with a barbed thread.

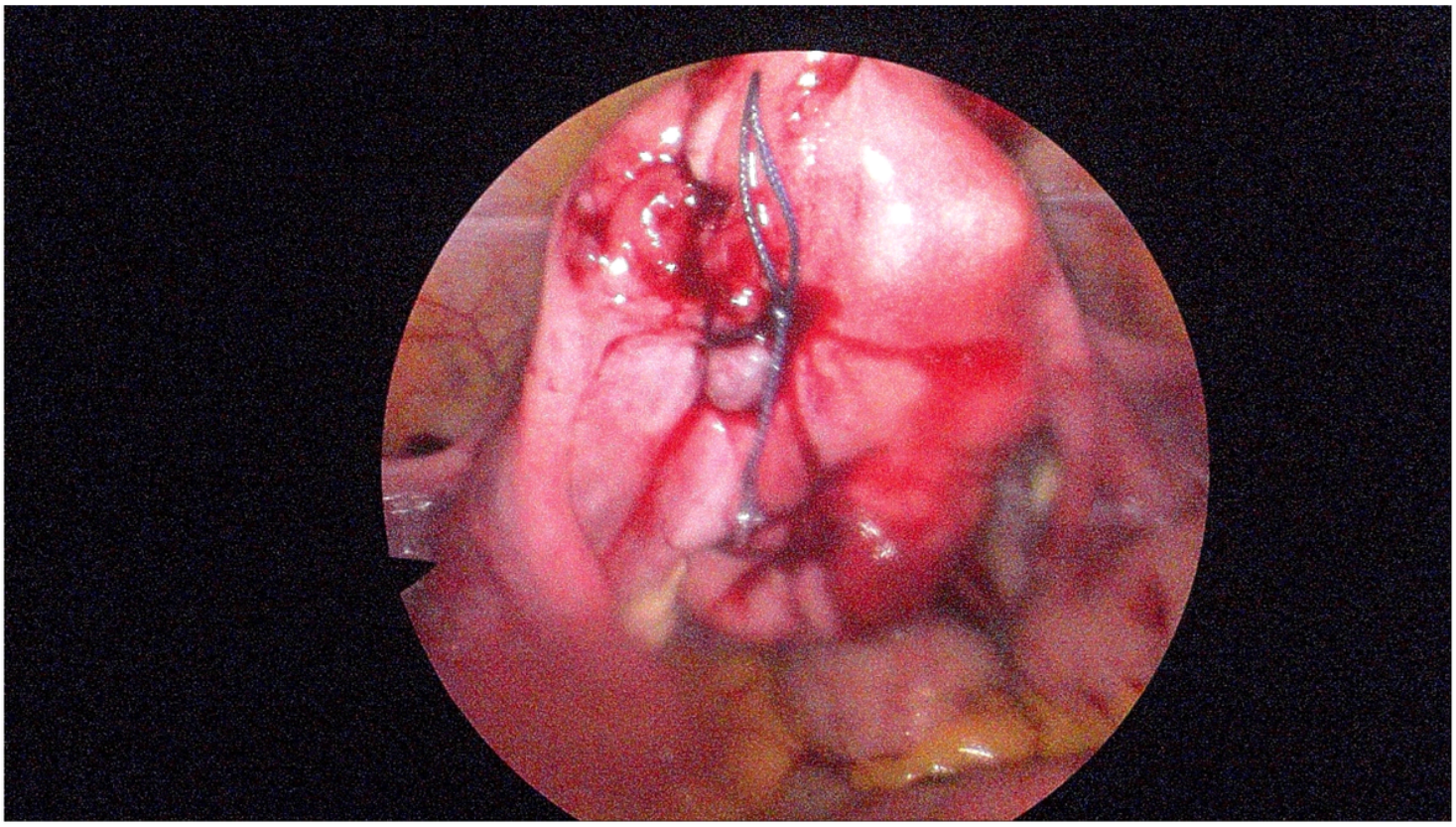

Figure 2

Suture of the uterine wound in case 2. The inner suture of wound was made with simple continuous suture and the outer suture was made with Lembert suture by 1.0 vicryl.

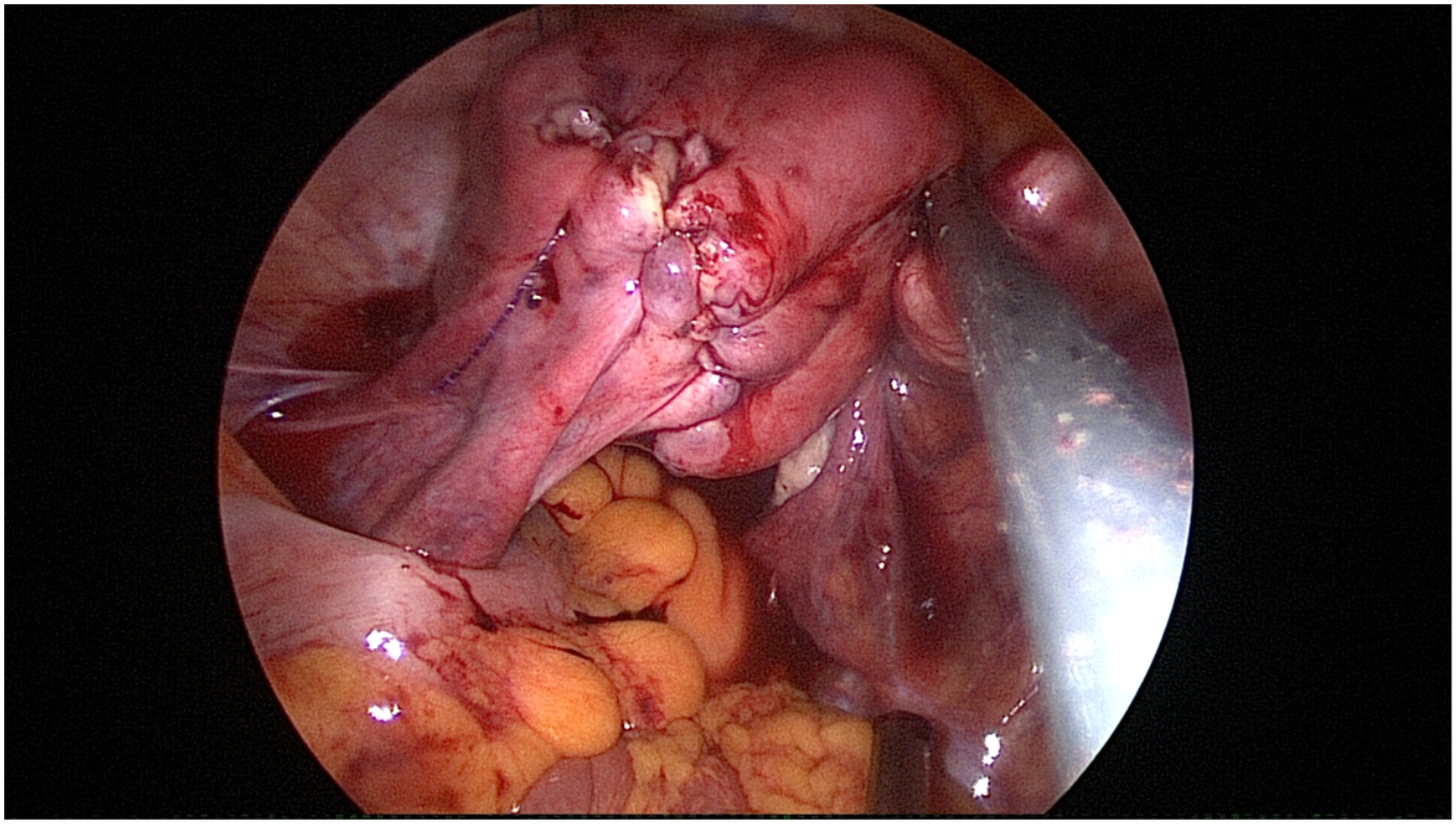

Figure 3

Suture of the uterine wound in case 3. The inner suture of wound was made with simple continuous suture and the outer suture was made with baseball suture by barbed thread.

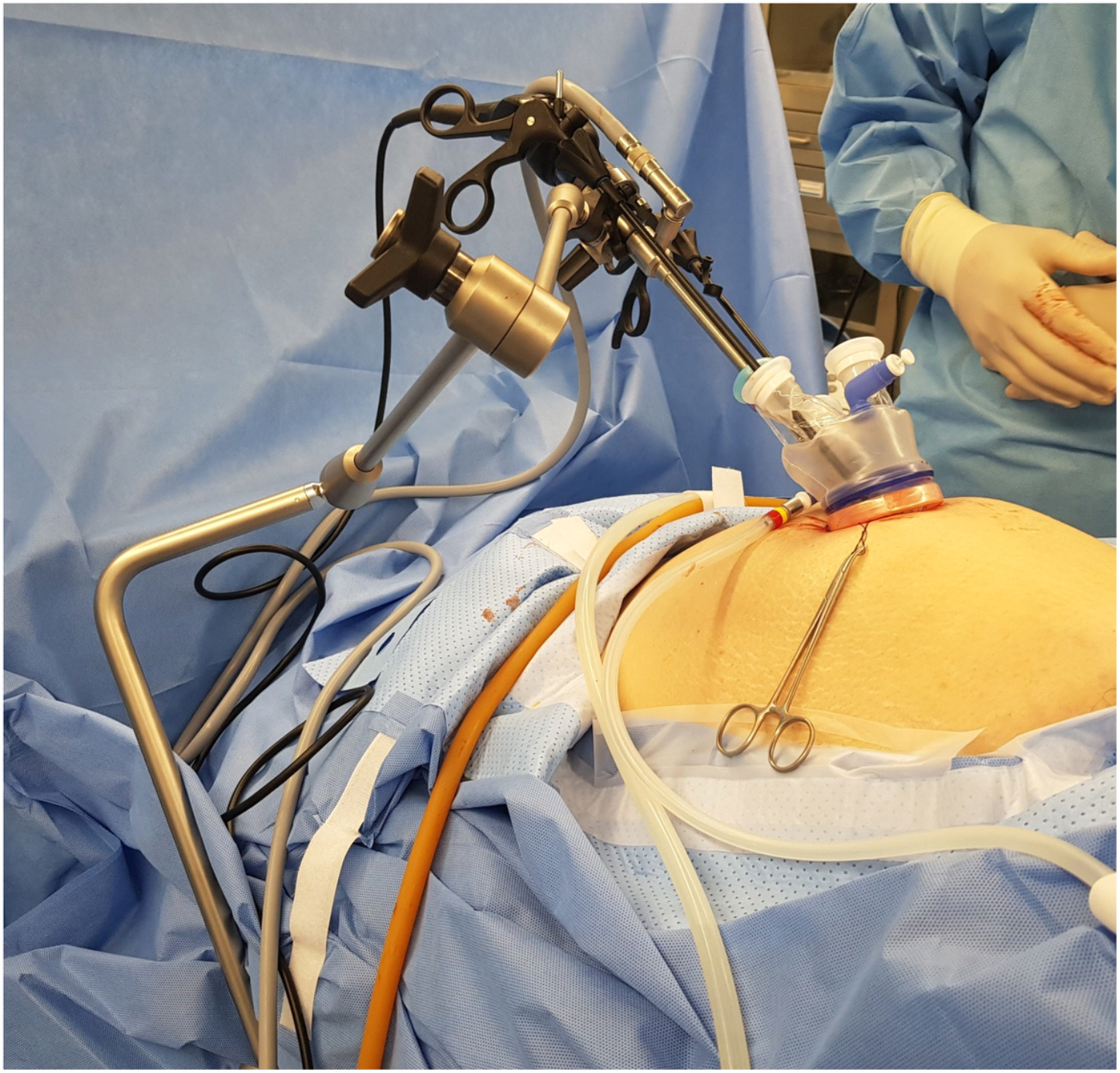

Figure 4

Basic installation of operative tools. The surgeon was placed on the left side of the patient. A glove port was inserted into the umbilical incision site. The passive camera holder was installed from patient's head to the body.

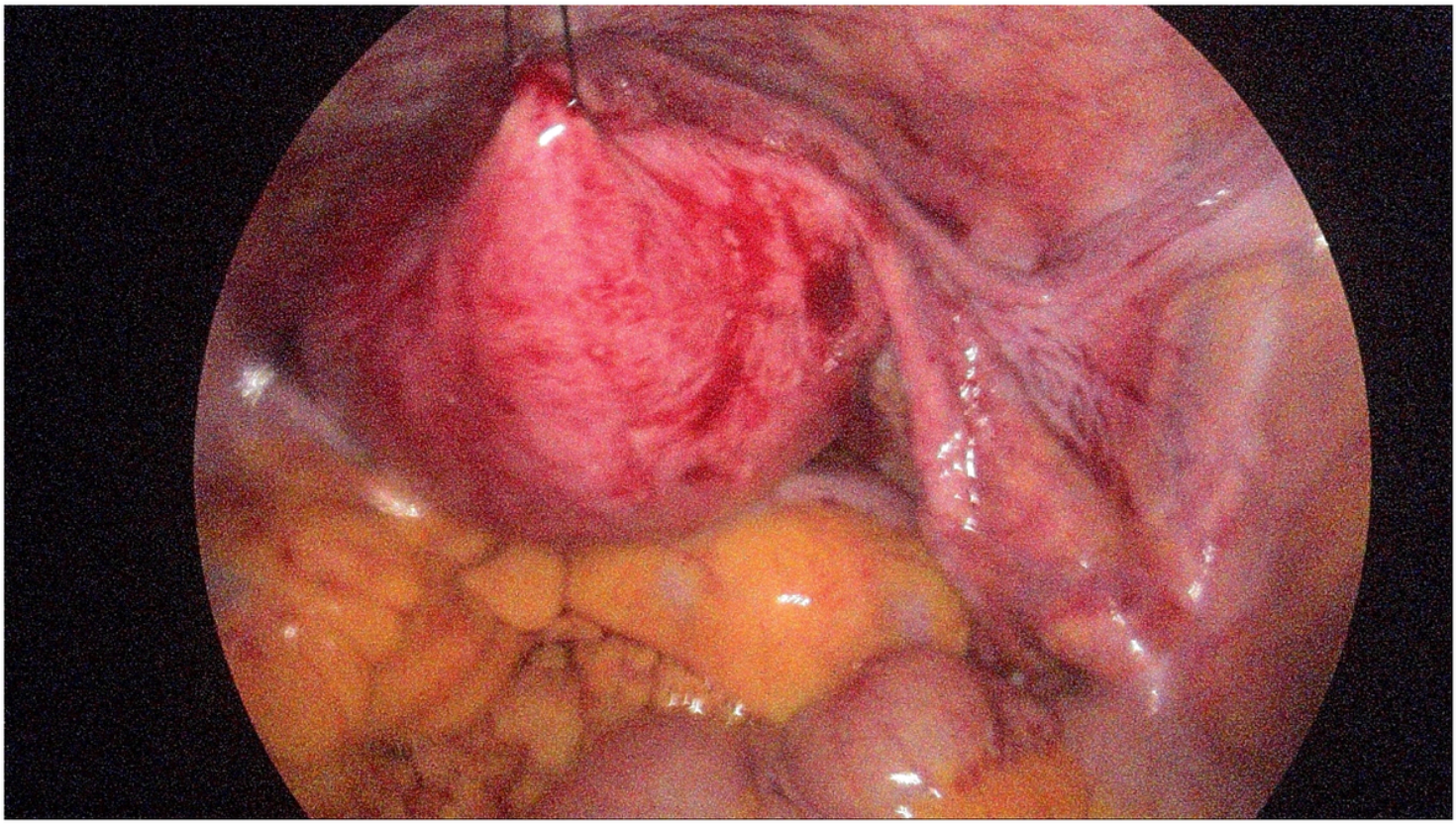

Figure 5

Uterus fixed near the abdominal wall. The suture was applied to the uterine fundus. The uterus was lifted against the abdominal wall by pulling the two threads that came out of the body.