Subacromial Erosion after Hook Plate Fixation in Acute Acromioclavicular Joint Dislocation

Jung Youn Kim
Kangnam Sacred Heart Hospital
Yong Girl Rhee
Myongji Hospital
Young Wan Ko
Kyung Hee University
Sung Min Rhee (starsmstar@hanmail.net)
Kyung Hee University

Research Article

Keywords: Acromioclavicular joint injury, Locking Hook plate, Subacromial erosion, shoulder

Posted Date: December 29th, 2020

DOI: https://doi.org/10.21203/rs.3.rs-125960/v1

Version of Record: A version of this preprint was published at Journal of Orthopaedic Trauma on October 8th, 2021. See the published version at https://doi.org/10.1097/BOT.0000000000002282.

Subacromial Erosion after Hook Plate Fixation in Acute Acromioclavicular Joint Dislocation

Jung Youn Kim[1], M.D. , Ph.D., Yong Girl Rhee[2], M.D.,Ph.D., Young Wan Ko[3], M.D, Sung Min Rhee[3]* ,M.D. , Ph.D.

Department of Orthopaedic Surgery, Kangnam Sacred Heart Hospital,

Hallym University College of Medicine, Seoul, Republic of Korea[1.],

Shoulder & Elbow Clinic, Department of Orthopaedic Surgery, Myongji Hospital, Goyang-si, Korea.[2]

Shoulder & Elbow Clinic, Department of Orthopaedic Surgery, College of Medicine,

Kyung Hee University, Seoul, Republic of Korea[2]

Jung Youn Kim; E-mail: kimjungyounn@hanmail.net

Yong Girl Rhee; shoulderrhee@hanmail.net

Young Wan Ko; koyw2000@hanmail.net

Sung Min Rhee; Starsmstar@hanmail.net

* Reprint requests to

Sung Min Rhee, MD

Department of Orthopaedic Surgery, College of Medicine, Kyung Hee University

1 Hoegi-dong, Dongdaemun-gu, Seoul 130-702, Korea

Tel : +82-2-958-8370, Fax : +82-2-964-3865

E-mail: starsmstar@hanmail.net

ABSTRACT

Background: This study was to analyze the clinical results of locking hook plate fixation for acute acromioclavicular joint (ACJ) injury and to find out the incidence of subacromial erosion, carry out quantitative analysis and identify risk factors.

Methods: The study was conducted on 35 patients who underwent the locking hook plate fixation for acute ACJ joint injury. The clinical outcomes were evaluated measuring the visual analog scale (VAS) for pain, and the University of California at Los Angeles (UCLA) score. The computed tomography (CT) was conducted to measure the subacromial erosion. The acromioclavicular slope (AC slope) of the unaffected side, the acromion-hook angle (AH angle), the acromioclavicular anteroposterior distance (AC-AP distance), and the preoperative acromioclavicular interval (ACI) of the affected side were analyzed to identify the risk factors of subacromial erosion.

Results: The mean preoperative VAS score was 7.6 points, which improved by a significant level of 0.3 at the final follow-up ($P < 0.001$). The UCLA score at the last follow-up was 32.3 points, which was higher than the preoperative average of 15.2 points ($P = 0.003$). According to the computed tomography (CT) findings, subacromial erosion was found in all cases, and the mean value was 5.0mm, which is 53% of the entire acromion thickness. The AC slope ($B=-0.159$, $P<0.001$) and AC-AP distance ($B=0.233$, $P=0.004$) were found to have a significant influence on postoperative subacromial erosion. The AC slope showed a negative correlation with the amount of erosion, while the AC-AP distance showed a positive correlation with erosion.

Conclusion: The study was able to obtain satisfactory clinical and radiological results after locking hook plate fixation for acute ACJ injury. The CT findings revealed that subacromial erosion occurred in all cases, and the mean erosion depth was about 50% of the acromial thickness. If the preoperative AC slope of the unaffected side was more acute and the AC-AP distance was larger, the incidence of subacromial erosion was higher.

Level of evidence: Therapeutic Level IV

Keywords: Acromioclavicular joint injury; Locking Hook plate; Subacromial erosion; shoulder

Retrospectively registered study: This study was retrospective in nature, and final approval of informed consent exemption by the institutional review board was obtained (KHUH IRB 2019-04-079)

Background

The acromioclavicular joint (ACJ) injury is a common injury that accounts for about 9% of the total shoulder girdle injuries. About half of the ACJ injuries occur in young people in their 20s, and the incidence among males is 5 times higher than among females.[1] The most common injury mechanism of the ACJ injury is considered as an external force applied directly from above the acromion process, which usually occurs when falling with the upper limb in an adducted position.[2] Among ACJ injuries, incomplete injuries which belong to Rockwood type I to II have been reported to show good results with non-surgical treatment. In contrast, there is still much controversy over optimal treatments for higher grader injuries which belong to Rockwood type III~VI.[3-5] Recent biomechanical studies have suggested that restoring acromioclavicular distance as closely as possible to an preinjury state is important for maintaining the superoinferior and anteroposterior stability of ACJ.[2]

A variety of surgical treatments for ACJ injuries have been reported to date. Of these surgical treatments, the locking hook plate, which is a technique to promote the natural healing of the injured ligament through ACJ fixation, has been used widely as an surgical treatment for acute ACJ injuries because of a simple surgical technique, a short operation time and satisfactory clinical results.[6, 7] The locking hook plate forms a non-rigid fixation between the distal clavicle and the acromion to allow the rotation of the ACJ and a more free motion of the shoulder joint when compared with the conventional rigid fixation, which in turn extends the implant retention and provides sufficient time for ligament healing.[8] On the other hand, subacromial erosion is a typical complication of the hook plate which can occur due to its characteristics of forming non-rigid fixation, which may lead to acromial fracture.[9-12] It has been reported that 16-26% of those patients who underwent hook plate fixation had subacromial erosion.[13, 14] However, since the studies up to now determined the presence of erosion only by with visible radiolucency around the hook on the plain X-ray images, the incidence rate must have been underestimated because it was difficult to discover modest erosion.

The purpose of this study was to evaluate the clinical and radiological outcomes after locking hook plate fixation for acute ACJ injury and to conduct quantitative analysis of the true incidence and erosion of subacromial erosion through the CT evaluation. In addition, the study also tried to identify the preoperative and postoperative risk factors of erosion. The authors of the study hypothesized that the non-rigid fixation characteristics of the hook plate might cause a much higher incidence of subacromial erosion than reported in the previous literatures.

MATERIALS AND METHODS

Ethics approval and consent to participate

This study was retrospective in nature, and final approval of informed consent exemption by the institutional review board was obtained ((KHUH IRB 2019-04-079)

Patient Selection

This study retrospectively examined those patients who underwent hook plate fixation for acute ACJ injury at our hospital from January 2011 to October 2015. The inclusion criteria were as follows: 1) ACJ injury of Rookwood type III or higher, 2) operation within 2 weeks from the date of injury, and 3) follow-up of more than 1 year after surgery. 4) CT scan before implant removal. A total of 35 patients were selected for the study based on these criteria.

Operative Technique and Rehabilitation

All surgeries were performed by one senior author. The operation was done in a beach-chair position under general anesthesia; a longitudinal incision was performed along the long axis of the clavicle centered on the ACJ, and then the upper part of the dislocated joint was exposed. After inserting a locking hook plate (Synthes, Solothurn, Switzerland) into the proper position, we checked whether ACJ was reduced in C-arm or not and then fixed the hook plate. Hook depth was determined based on the restoration of the position of distal clavicle as closely as possible to the unaffected side.

Patients put on shoulder slings and were immobilized for up to 2 weeks after operation. After that, they started with passive motion and the range of motion (ROM) was gradually increased. Patients were instructed to refrain from engaging in excessive physical activities other than ordinary daily activities until implant removal, and the ROM was exercised to a tolerable level, and extreme motion was avoided.

Preoperative and Postoperative Evaluations

Clinical evaluation was performed before surgery and in each follow-up examination. Pain was measured using the Visual Analogue Scale (VAS) scores. The range of motion of the shoulder joint was assessed by measuring forward flexion, external rotation at side, internal rotation to posterior, and abduction. The study measured changes in shoulder function using the University of California at Los Angeles (UCLA) score as a comprehensive clinical evaluation.

Radiologic Evaluations

Anteroposterior radiographs of the affected and contralateral unaffected ACJ in neutral rotation were obtained with patients in a standing position immediately after operation and in each follow-up examination including the last one. To evaluate the postoperative reduction quality, the following radiologic factors were measured. (Figure 1):1. Acromioclavicular interval (ACI), 2. Coracoclavicular distance (CCD), 3. Acromioclavicular distance (ACD)

ACI was defined as the perpendicular distance between clavicle distal end and acromion; CCD was defined as the perpendicular distance between the upper border of the coracoid process and the inferior cortex of the clavicle; ACD was defined as the perpendicular distance between the line passing the upper border of acromion and the line parallel to the upper border of the lateral part of clavicle. All radiographs were analyzed by two authors who reached a consensus. Reduction loss was decided by comparing ACI, CCD, and ACD in the immediately postoperative and the last follow-up radiographs. Radiologic results of contralateral unaffected side and affected

side at the last follow-up examination were compared in order to determine whether anatomical reduction was appropriate.[3]

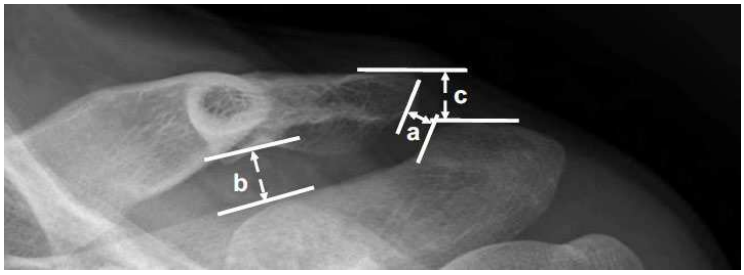

Figure. 1 Radiologic analysis on the plain anteroposterior radiograph for the assessment of postoperative reduction quality. a: acromioclavicular distance, b: coracoclavicular distance, c: acromioclavicular interval.

The CT scan was performed just before implant removal for quantitative analysis of subacromial erosion. and the length of a vertical line drawn from the undersurface of acromion to the upper end of the erosion was taken as the depth of erosion and measured in a sagittal and coronal view, respectively. The largest erosion depth measured in each view was recorded as the final erosion depth.

The following radiologic factors on plain anteroposterior radiographs or CT images were additionally measured to determine the risk factors of subacromial erosion occurring after hook plate fixation (Figure 2):1. Acromioclavicular slope (AC slope) of unaffected side, 2. Acromion-hook angle (AH angle) of affected side 3. Acromioclavicular anteroposterior distance (AC-AP distance) of affected side 4. Preoperative acromioclavicular interval (ACI) of affected side

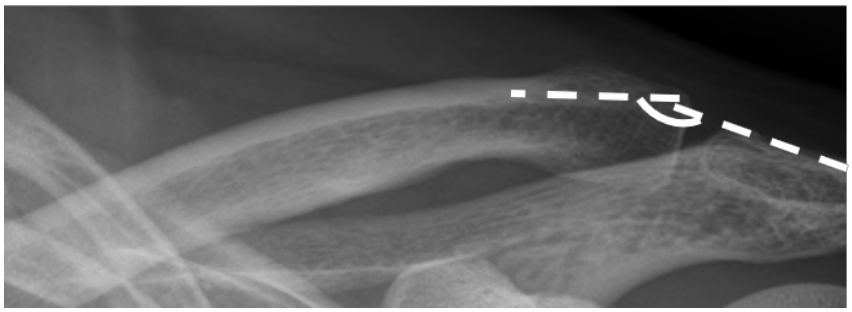

Figure 2.1)

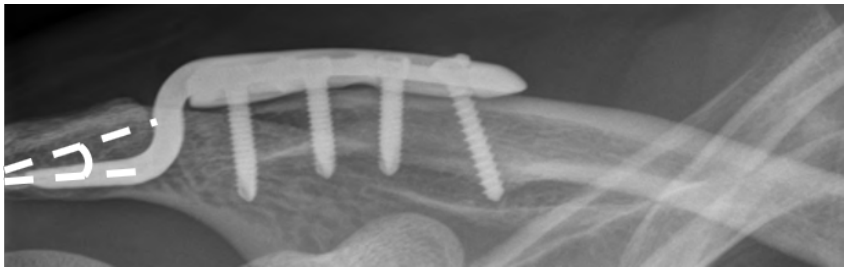

Figure 2.2)

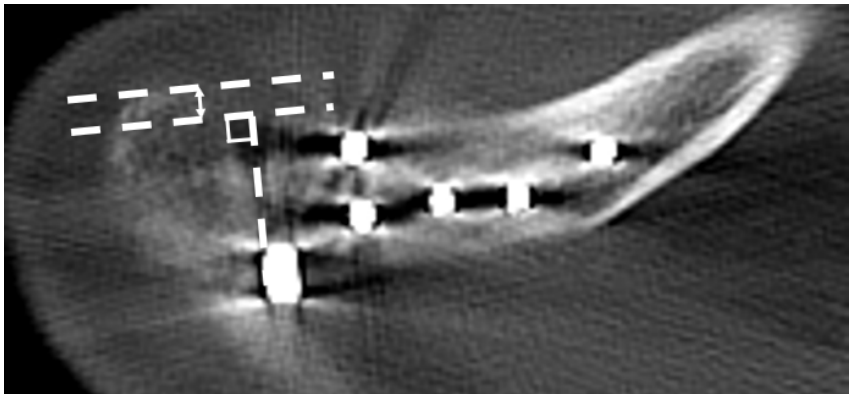

Figure 2.3)

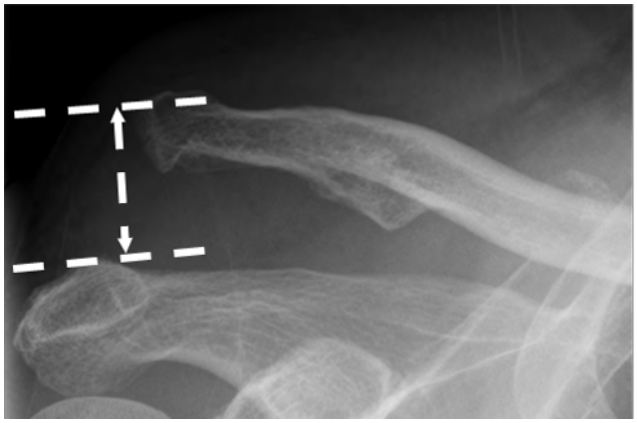

Figure 2.4)

Figure 2. Risk factor analysis for the subacromial erosion. 1) Acromioclavicular slope (AC slope), 2) Acromion-hook angle (AH angle), C) Acromioclavicular AP distance (AC-AP distance) D) Acromioclavicular interval (ACI)

The AC slope was defined as the angle formed between the upper surface of the acromial process and the upper surface of the distal clavicle on the plain anteroposterior radiograph. The AH angle was defined as the angle formed between the upper surface of the acromial process and the hook of the locking hook plate on a plain anteroposterior radiograph. The AC-AP distance, which was measured in the axial view of the CT, was defined as the distance between the two lines tangent to the anterior margin of the acromial process and the anterior margin of the distal clavicle. In addition, the pre-operative ACI of the affected side was included as a risk factor and measured together with the above three items.

Statistical Analysis

The paired t-test was performed to assess the difference between the preoperative and postoperative results. Comparisons between the 2 groups were performed using the χ-square test for comparing proportions between groups and the independent t-test for mean difference between groups. The regression analysis was used to identify the risk factors for the subacromial erosion. Statistical analyses were conducted using IBM SPSS Statistics, version 20.0 (SPSS, Chicago, IL), and $P < 0.05$ was considered statistically significant.

RESULTS

Patients demographics

The mean age of the patients was 40.0 years old (range: 20~82) and all of them were male. The mean follow-up period was 45.6 months and the mean duration from hook plate fixation to implant removal was 3.2 months. According to Rockwood classification, there were 5 cases of type III (14%), 2 cases of type IV (6%), and 28 cases of type V (80%).

Clinical Outcomes

According to the VAS scores, the mean pain level before operation was measured at 7.6 points, which improved significantly by 0.9 points right after hook plate removal and by 0.8 points at the last follow-up examination ($P < 0.001$). The range of motion (ROM) of the affected side showed a slight limitation when compared with the unaffected side. Statically significant differences were seen only in the forward flexion and the internal rotation posterior but the differences were not so large ($P = 0.004$ and 0.005) (Table 1). The mean UCLA score at the last follow-up examination was 32.3 points, which is a significant improvement when compared to the mean UCLA score before operation. ($P = 0.003$)

Table 1. Comparison of range of motion between the affected and unaffected shoulder at the last follow-up.

	Affected	Unaffected	Significance
Forward flexion	147.4	158.7	0.004
External rotation at side	58.0	64.1	0.175
Internal rotation to posterior	T10.0	T7.6	0.005
Abduction	126.9	137.4	0.221

Radiologic Outcomes

In terms of reduction quality, three factors showed that the affected side was well restored right after surgery without any significant difference from the unaffected side. At the final follow-up examination after the removal of the hook plate, all three factors showed a significant reduction loss compared to the uninjured side, but the difference was as modest as 1.6 ~ 2mm (Table 2).

Subacromial erosion was found in all case in the CT images. Erosion depth was 4.7 mm in the coronal view and 4.7 mm in the sagittal view, which corresponded to 47% and 53% of the total acromion thickness, respectively. The mean value calculated by taking higher measurement values between the coronal and sagittal views was 5.0 mm (53%). 17 cases or 49% of the entire patient group showed erosion with a size of more than 50% of the total acromion thicknesses.

Risk factor analysis for the subacromial erosion

According to the results of correlation analysis of four radiologic factors measured to identify risk factors of subacromial erosion, all of them showed significant correlations with postoperative erosion. A negative correlation was found in AC slope (r = -0.491, P = 0.003), while positive correlations were found in AH slope (r=0.579, P<0.001), AC-AP distance (r=-0.436, P=0.009), and preoperative ACI (r=0.341, P=0.045). were all positively correlated. In the final multivariate regression analysis of these three factors, two factors such as AC slope (B=-0.159, P<0.001) and AC slope (B=0.233, P=0.004) were found to have significant influence on postoperative subacromial erosion.

(mm)	Affected	Unaffected	Significance
Immediate postoperative			
ACD	3.5	3.0	0.101
CCD	7.8	8.0	0.758
ACI	2.6	3.4	0.157
Last follow-up			
ACD	5.0	3.0	0.006
CCD	9.9	8.0	<0.001
ACI	5.0	3.4	<0.001

Complications

The most common postoperative complication was subacromial erosion which was found in all patients on CT scan. Among them, 4 cases (11%) showed that only a thin cortical shell remained as a bone above the hook, and 2 cases (6%) had acromial fracture. Amount of erosion were not significantly related to clinical outcomes such as VAS scores and UCLA scores(P=0.218, P=0.342,respectively).

Table 2. Quality of reduction in immediate postoperative period and last follow-up compared with the unaffected side

* Acromioclavicular distance; ACD, Coracoclavicular distance; CCD, Acromioclavicular interval; ACI

DISCUSSION

In the past, trans articular fixation using Kirschner's wire or Steinmann pin was widely performed and showed satisfactory clinical results. However, as complications such as wire breakage or migration have been reported recently, it is rarely performed now.[15, 16] Hook plate has been actively used as an ACJ fixation device recently to obtain good clinical and radiological results. Koukakis et al.[17] reported an excellent functional outcome after hook plate fixation in patients with ACJ injury. Especially, as it does not require a high level of surgical skill, it can be performed successfully by a relatively less experienced surgeon without any difficulty. Unlike the previously used Wolter plate, hook plate fixation does not require drilling into acromion, which makes the operation easy to perform. However, complications have been reported to occur due to the use of mobile hook.

The subacromial erosion described in this study is a typical complication caused by mobile hook, and extra care and precaution need to be taken, as it may lead to pathologic acromial fracture in a severe case.

The most notable finding in this study was that subacromial erosion was found in all cases of hook plate in the CT images. The previous hook plate studies reported that subacromial erosion occurred as a postoperative complication, but because they used a plain radiograph, they reported a considerably lower incidence rate (16-26%) than what the authors of this study have found out.[13, 14] In the analysis of acromial morphology in case of hook plate fixation, Yoon et al.[18] reported that there was a wide individual variation in the posterior acromial process when the hook was being fixed, which made it difficult to represent it as an average model. It means that it is not easy to judge subacromial erosion on plain radiograph. Therefore, the authors used the CT to determine the occurrence of erosion before hook plate removal and found that subacromial erosion occurred in all cases. This incidence rate was higher than the ones reported by the previous studies using plain radiographs, so the clinician should pay more attention to complications. The quantitative analysis of erosion showed the mean erosion depth of 5.0 mm, which was equivalent to 53% of the total acromial thickness, and it was found that the erosion of a size of more than 50% of the acromial thickness occurred in about half of all patients. In addition, it was found that six cases or 17% of the entire patient group, which was considered to be a significantly high percentage, had acromial fracture or impending fracture where erosion was severe to the extent that only the acromion cortical shell remained. Many previous studies recommended that the retention after hook plate fixation should lasted for 3 to 6 months before it was removed.[8, 12, 19] However, the implant retention lasted for 3.2 months in average in this study before it was removed, but only 17% of the patients had severe subacromial erosion or fracture, which means that if the implant retention period lasts longer for the better healing of ligament, it can increase the incidence rate of acromial fracture.

The authors tried to identify risk factors for subacromial erosion among various preoperative and postoperative radiologic factors. Finally, both the preoperative AC slope of the unaffected side and the postoperative AC-AP distance of the affected side were found to be significant risk factors. The AC slope was negatively correlated with the amount of erosion, which means that the amount of erosion was increased as the slope was decreased to form a sharp angle. If the AC slope becomes smaller, the hook located on the acromial undersurface will have a more pointed contact, which leads to a greater stress on the tip of the hook, resulting in more erosion. The AC-AP distance was positively correlated with the amount of erosion, meaning that more distal erosion may occur if the distal clavicle is reduced more in backward than acromion. As this is related to anteroposterior stability after fixation of the hook plate, it is thought that the displacement of a hook plate in the superoinferior direction is controllable but the displacement in the anteroposterior direction is difficult to control. In other words, if the anteroposterior instability is in a serious condition due to a severe soft tissue and ligament damage around the ACJ, the hook plate alone is not sufficient to restore the affected side to the original anatomy, and the resulting erosion may be more serious.

The limitations of this study are as follows; first, since most of the patients had hook plate removed after a similar implant retention period, it was impossible to analyze changes in erosion amount depending on different retention periods from the initial operation. Therefore, it is difficult to present a proper hook plate removal time to prevent serious erosion based on the data of this study.

CONCLUSIONS

The locking hook plate fixation for acute ACJ injury showed satisfactory clinical and radiological outcomes after operation. The CT scan images showed that subacromial erosion occurred in all cases and about half of the patient group had erosion of more than 50% of the total acromial thickness. It was found that if the preoperative AC slope of the unaffected side became more acute, and if the postoperative AC-AP distance was larger, there was more subacromial erosion. Therefore, considering these risk factors, it is considered necessary to determine a patient's rehabilitation protocols and hook plate removal time.

List of abbreviations

acromioclavicular joint (ACJ)

visual analog scale (VAS)

University of California at Los Angeles (UCLA)

computed tomography (CT)

acromioclavicular(AC)

acromion-hook (AH)

acromioclavicular interval (ACI)

acromioclavicular distance (ACD)

range of motion (ROM)

Declarations

Ethics approval and consent to participate

All methods were performed in accordance with relevant guidelines and regulations. All experimental protocols were approved by Kyung-hee university hospital institutional review board. This study was retrospective in nature, and final approval of informed consent exemption by the institutional review board was obtained ((KHUH IRB 2019-04-079)

Consent for publication

Not applicable

Availability of data and materials

The datasets used and/or analysed during the current study are available from the corresponding author on reasonable request

Competing interests

The authors declare that they have no competing interests

Funding

This research received no specific grant from any funding agency in the public, commercial, or not-for-profit sectors

Authors' contributions

JY, YW and YG analyzed and interpreted the patient data. SM was a major contributor in writing the manuscript. All authors read and approved the final manuscript.

Acknowledgements

Not applicable

REFERENCES

1. Mazzocca AD, Arciero RA, Bicos J: **Evaluation and treatment of acromioclavicular joint injuries**. *Am J Sports Med* 2007, **35**(2):316-329.
2. Mazzocca AD, Santangelo SA, Johnson ST, Rios CG, Dumonski ML, Arciero RA: **A biomechanical evaluation of an anatomical coracoclavicular ligament reconstruction**. *Am J Sports Med* 2006, **34**(2):236-246.
3. Eschler A, Gradl G, Gierer P, Mittlmeier T, Beck M: **Hook plate fixation for acromioclavicular joint separations restores coracoclavicular distance more accurately than PDS augmentation, however presents with a high rate of acromial osteolysis**. *Arch Orthop Trauma Surg* 2012, **132**(1):33-39.
4. Dias JJ, Steingold RF, Richardson RA, Tesfayohannes B, Gregg PJ: **The conservative treatment of acromioclavicular dislocation. Review after five years**. *J Bone Joint Surg Br* 1987, **69**(5):719-722.
5. Galpin RD, Hawkins RJ, Grainger RW: **A comparative analysis of operative versus nonoperative treatment of grade III acromioclavicular separations**. *Clin Orthop Relat Res* 1985(193):150-155.
6. Di Francesco A, Zoccali C, Colafarina O, Pizzoferrato R, Flamini S: **The use of hook plate in type III and V acromio-clavicular Rockwood dislocations: clinical and radiological midterm results and MRI evaluation in 42 patients**. *Injury* 2012, **43**(2):147-152.
7. von Heideken J, Bostrom Windhamre H, Une-Larsson V, Ekelund A: **Acute surgical treatment of acromioclavicular dislocation type V with a hook plate: superiority to late reconstruction**. *J Shoulder Elbow Surg* 2013, **22**(1):9-17.
8. Gstettner C, Tauber M, Hitzl W, Resch H: **Rockwood type III acromioclavicular dislocation: surgical versus conservative treatment**. *J Shoulder Elbow Surg* 2008, **17**(2):220-225.
9. Ding M, Ni J, Hu J, Song D: **Rare complication of clavicular hook plate: clavicle fracture at the medial end of the plate**. *J Shoulder Elbow Surg* 2011, **20**(7):e18-20.
10. Hoffler CE, Karas SG: **Transacromial erosion of a locked subacromial hook plate: case report and review of literature**. *J Shoulder Elbow Surg* 2010, **19**(3):e12-15.
11. Chiang CL, Yang SW, Tsai MY, Kuen-Huang Chen C: **Acromion osteolysis and fracture after hook plate fixation for acromioclavicular joint dislocation: a case report**. *J Shoulder Elbow Surg* 2010, **19**(4):e13-15.
12. Nadarajah R, Mahaluxmivala J, Amin A, Goodier DW: **Clavicular hook-plate: complications of retaining the implant**. *Injury* 2005, **36**(5):681-683.
13. Meda PV, Machani B, Sinopidis C, Braithwaite I, Brownson P, Frostick SP: **Clavicular hook plate for lateral end fractures:- a prospective study**. *Injury* 2006, **37**(3):277-283.
14. Muramatsu K, Shigetomi M, Matsunaga T, Murata Y, Taguchi T: **Use of the AO hook-plate for treatment of unstable fractures of the distal clavicle**. *Arch Orthop Trauma Surg* 2007, **127**(3):191-194.

15. Lyons FA, Rockwood CA, Jr.: **Migration of pins used in operations on the shoulder**. *J Bone Joint Surg Am* 1990, **72**(8):1262-1267.
16. Larsen E, Bjerg-Nielsen A, Christensen P: **Conservative or surgical treatment of acromioclavicular dislocation. A prospective, controlled, randomized study**. *J Bone Joint Surg Am* 1986, **68**(4):552-555.
17. Koukakis A, Manouras A, Apostolou CD, Lagoudianakis E, Papadima A, Triantafillou C, Korres D, Allen PW, Amini A: **Results using the AO hook plate for dislocations of the acromioclavicular joint**. *Expert Rev Med Devices* 2008, **5**(5):567-572.
18. Yoon JP, Lee YS, Song GS, Oh JH: **Morphological analysis of acromion and hook plate for the fixation of acromioclavicular joint dislocation**. *Knee Surg Sports Traumatol Arthrosc* 2017, **25**(3):980-986.
19. Kashii M, Inui H, Yamamoto K: **Surgical treatment of distal clavicle fractures using the clavicular hook plate**. *Clin Orthop Relat Res* 2006, **447**:158-164.

FIGURE LEGENDS

Figure. 1 Radiologic analysis on the plain anteroposterior radiograph for the assessment of postoperative reduction quality. a: acromioclavicular distance, b: coracoclavicular distance, c: acromioclavicular interval.

Figure 2. Risk factor analysis for the subacromial erosion. A) Acromioclavicular slope (AC slope), B) Acromion-hook angle (AH angle), C) Acromioclavicular AP distance (AC-AP distance) D) Acromioclavicular interval (ACI)

Figures

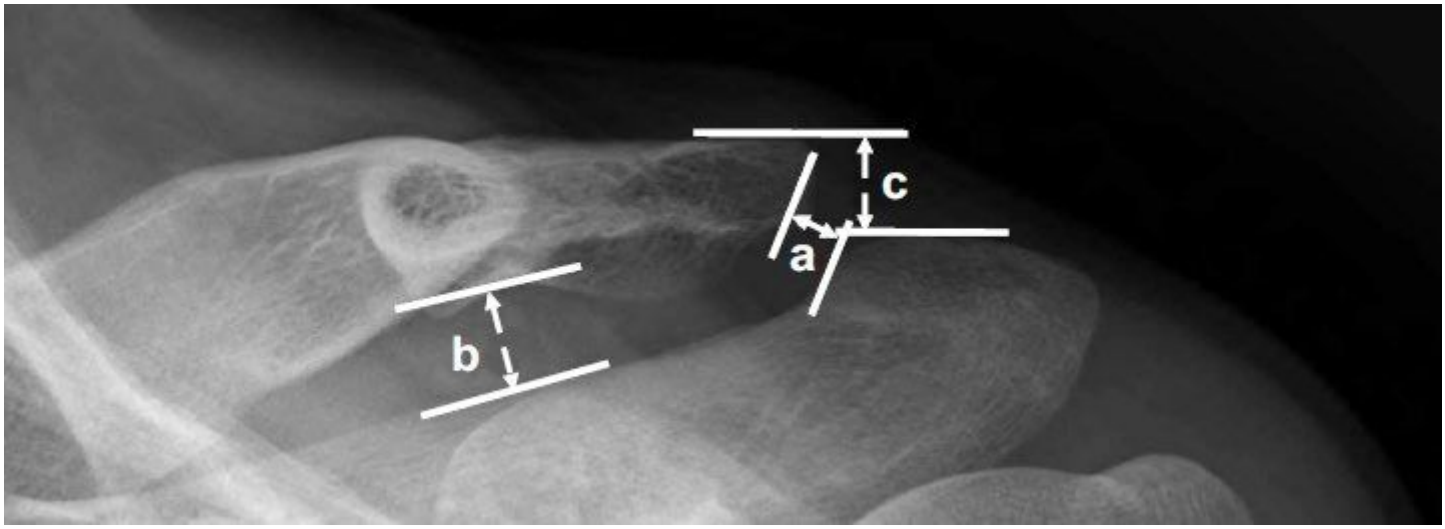

Figure 1

Radiologic analysis on the plain anteroposterior radiograph for the assessment of postoperative reduction quality. a: acromioclavicular distance, b: coracoclavicular distance, c: acromioclavicular interval.

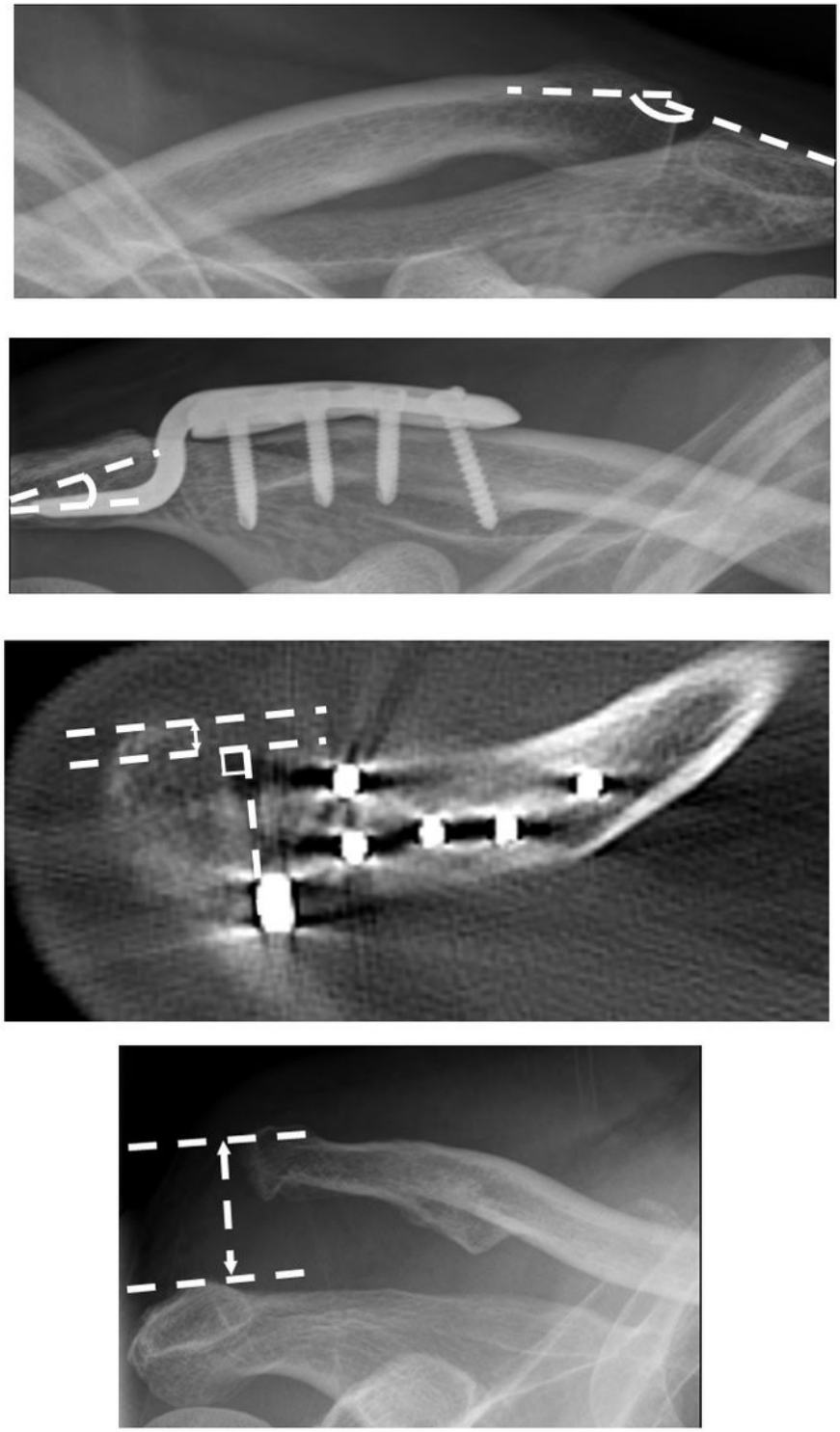

Figure 2

Risk factor analysis for the subacromial erosion. 1) Acromioclavicular slope (AC slope), 2) Acromion-117 hook angle (AH angle), C) Acromioclavicular AP distance (AC-AP distance) D) Acromioclavicular interval (ACI)