Can Descending Necrotizing Mediastinitis be treated without surgical intervention? – A case report.

Feras Lami
Tripoli Children's Hospital
Abdulfattah Bengheshir
Tripoli Children's Hospital
Mohamed Hadi Mohamed Abdelhamid (Mohamed.abdelhamid@btc.org.ly)
Biotechnology Research Center https://orcid.org/0000-0002-6544-9410

Research Article

Keywords: DNM, Ludwig's angina, dental focal infection, abscess, pleural effusion

Posted Date: January 26th, 2022

DOI: https://doi.org/10.21203/rs.3.rs-1273820/v1

Abstract

Background

Descending necrotizing mediastinitis (DNM) is a relatively uncommon complication of deep neck infections. We present a case of DNM that has been managed due to early diagnosis and adequate medical treatment, a rare and often lethal complication of odontogenic infections.

Case presentation

A 17-year-old female patient with a history of swelling in the neck, tongue and lips for two weeks was admitted to the Paediatric Intensive Care Unit of the Cartage Clinic, Tripoli, Libya at the end of December 2019. The predominant underlying oropharyngeal infection was of odontogenic origin, specifically, infection involving the mandibular 3rd molar. The most common option for empiric therapy were broad-spectrum intravenous antibiotics combined with metronidazole or clindamycin. The patient has been discharged from the hospital after four weeks, since being in good health.

Conclusion

In view of our experience, we believe that only through aggressive combined medical management by antibiotics directed at both aerobic and anaerobic organisms and drainage at all pus collection sites can reverse the effect of DNM the highly morbid.

Background

Descending necrotizing mediastinitis (DNM) occurs as a complication of odontogenic infection due to spreading of the deep neck infections such as Ludwig’s angina, peritonsillar abscess, or post-traumatic neck abscess. In the first modern series of patients with DNM published in 1938, Pearse reported that 49% of patients died during their treatment [1]. Moreover, this infection is usually self-limiting and did not spread to other sites, especially with the use of antibiotics, steroids, and non-steroidal anti-inflammatory drugs which can mask the symptoms of such infections. However, if these infections remained untreated, may rapidly spread down into the mediastinum, pleural cavities, or even to the pericardium[2].

As the infection spreads along deep cervical fascial planes into the mediastinum, widespread cellulitis, necrosis, abscess formation, and sepsis may occur. In addition, the delayed diagnoses and inappropriate drainage of the mediastinum are the main causes of the high mortality of those cases (40-60%)[3–5].

A previous study by Rizzo et al. reported that deep neck infections are more common in male (51.9%) than in female (48.1%), and there is no set age for this type of infection [6].

We report a case with DNM that has been successfully diagnosed and treated with appropriate medical approaches. However, the optimal form of the mediastinal drainage model is still controversial and varies widely. I.e. thoracotomy, median sternotomy, clamshell incision, a subxiphoid approach, a transcervical

approach, Video-assisted thoracoscopic surgery (VATS), mediastinoscopy, and percutaneous catheter drainage [7, 8].

The diagnosis of DNM was suggested by the laboratory finding, clinical examination and confirmation using Computed Tomography (CT). And/or collection of pus from the neck to the mediastinum was the main evidence of DNM. CT scans of the chest provide important information regarding the extent of mediastinal involvement [8].

In a case report, we present a case of descending necrotizing mediastinitis that has been successfully treated due to early diagnosis and adequate medical treatment. Moreover, in our experience, we believe that only through aggressive combined medical management can reversing the effect of descending necrotizing mediastinitis the highly morbid.

Case Presentation

We report a case of Ludwig Angina with DNM observed at the end of December 2019. A healthy 17-year-old female was admitted to the paediatric intensive care unit at Cartage Clinic, Tripoli, Libya, with a history of swelling in neck, tongue and lips for two weeks (Fig.1).

On the initial examination, the patient was leaning forward, had shortness of breath and complaining of dysphagia, aphonia, and regurgitation even with water through the nose. The patient couldn't lie on the bed, slept on upright position with orthopnea. She was febrile over 38 ℃ and recorded a heart rate of 95-110 b/m, blood pressure of 124/70 mm Hg, respiratory rate of 35-38 b/m, and an oxygen saturation of 89-92%. Examination revealed the anterior fullness of the neck, with a deep purplish discoloration of her skin.

There was significant swelling, and induration in the submandibular and submental regions extending down towards the base of the neck, with marked decrease in air entry on the right side of the lung, other physical examination was unremarkable.

The ethics statement, After the family is informed of the treatment options (surgical and medical), they accepted tooth extraction and aspiration of the collected fluid in submandibular and plural areas besides the medical treatment.

The study was approved by the Ethics Committee (Bioethics committee at Biotechnology Research Center N°: BTC-BTRC 24_2021). An informed consent was obtained for the family patient; and the study was carried out according to Helsinki declaration.

Laboratory test and imaging

The diagnosis was DNM arising from Ludwig’s Angina with a dental infection source. Clinical features and presentations, supported by the laboratory and radiology exams are requested for diagnostic

assistance such as; complete blood count (CBC), renal function test, tuberculin skin test (TST), Immunoassay and tumor markers (Table 1).

We did an ultrasound, computed tomography (CT) scans of the neck, chest x-ray, chest, and abdomen. We collected samples from both submandibular and plural areas for biochemistry, culture, and sensitivity (C/S) analysis (Table 2,3).

The laboratory report of the fine needle aspiration samples submandibular swelling shows that cytological features are consistent with acute purulent inflammation. In the details we can say that the samples show mixed inflammatory cells composed of many neutrophils, small lymphocytes, and many foamy macrophages, in the background of fibrin, cellular debris, and red blood cells. Multiple scattered mature squamous epithelial cells are seen. No multinucleated giant cells are seen. No atypical or malignant cells are seen in both samples of pleural and submandibular swelling (Table 2,3).

Furthermore, laboratory data was significant for a leukocyte count of 19.1 n x 103 cells/µl, C-reactive protein of 96 mg/dL. And noted that the HIV screen was negative.

Chest x-ray showing massive right pleural effusion and blunting of the costophrenic angle (Fig.2). An ultrasound scan of the submandibular area and neck swelling showed right parotid gland hypertrophy with intraparotid massive abscess with submandibular turbid collection and multiple inflammatory lymphadenopathy.

The first CT scan of the neck and chest was 1st week of admission show a large well-defined lobulated collection involved bilateral parapharyngeal spaces, prevertebral cervical space, tracking down beneath platysma muscle bilateral submandibular region of the anterior and posterior mediastinum associated with right-side pleural effusion.

On 2nd CT SCAN of the neck and chest with contrast which was at the 4th week of admission (Fig. 3 A) showing in comparison with previous CT scan of the 1st week of admission. The comparison shows that there is a newly developed small collection socket on the right side of the nasopharynx 2.0 cm and 1.6 cm posteriorly to the upper trachea. The unchanged collection is just below the level of the thyroid gland in the anterior lower neck soft tissue.

A newly developed small socket collection in the posterior mediastinum 3.3 cm in the axial diameter and unchanged collection in the anterior mediastinum 7.3 x 2.7 cm with some new post interventional air inside.

Post removal of the right-side chest tube with newly developed mild right-side pleural effusion, no evidence of suspected Pneumothorax, Nasopharynx, oropharynx, and larynx appear normal. However, Normal appearance of the bilateral thyroid gland lobes. Normal scanned the rest of the bilateral lung parenchyma. Trachea and main bronchi are normal in caliber.

The 3rd CT SCAN at 6th week of admission (Fig. 3 B) in comparison with previous CT scan in 4th week of admission shows dramatic regression of the previously seen multiple peripherally rim enhancing collections seen at upper and lower neck soft, and no more neck softly tissue collection can be detected.

Further, regression of the previously seen collection in the anterior mediastinum and right-side pleural effusion, there is just a minimal collection seen in the anterior mediastinum and small encysted pleural effusions are seen on the right side.

Management

Once DNM was suspected, an experimental broad-spectrum intravenous antibiotic, including meropenem, vancomycin, metronidazole, and ampicillin as the first line of treatment was started for two weeks .

Our view is that administration of empirical antibiotics should cover aerobes and anaerobes for possible mixed infection. We then performed another CT scan as an assessment procedure, as CT of the Cervical thorax is the ideal image to evaluate the area of DNM involved. Especially, the aspiration of the collection in the submandibular region and right pleural effusion were performed under the complete aseptic technique at the 1st week of admission. The collection from the submandibular area with 500 ml of pus aspirated, sent to a laboratory for c/s (Fig.5).

The Pleurocentesis Chest tube guided by ultrasound was inserted and draining of 1250 ml of pleural fluid and sent to a laboratory for Analysis and c/s. Unfortunately, the second CT scan which was performed at the 4th week (after the aspiration) showed a new collection in the posterior mediastinum and newly developed mild right-side pleural effusion. We changed the antibiotic to Imipenem/ Cilastatin, Ceftriaxone, clindamycin, and Piperacillin/tazobactam this decision was made not according to any culture because it was aseptic collections (Table 2-3). However, extraction of the 3rd right molar tooth which has the dental caries was done, which was the source of infection, on the 10th day of admission.

The CT scan of the chest and neck was repeated in the 6th week, showing dramatic regression of the previously seen multiple peripherally rim enhancing collection at upper and lower neck. At the same time, no more neck soft tissue collection can be detected compared to the previous CT scan. The collection was completely resolved, and the patient completed 3 weeks of antibiotics after one month of discharge.

Results

Clinical Data

The main clinical symptoms included swelling and pain in bilateral cervical areas, dysphagia, associated with fever. However, trismus and dyspnea before hospital admission, the patient has been receiving oral antibiotics before being admitted to our clinic, which had proven inadequate in preventing

progression of the odontogenic or tonsillar infection. Notably, the length of time between the onset of symptoms and hospital admission was 7 days.

Diagnostic Investigations and Radiographic

After clinical evaluation, the diagnosis was made by CT, which showed swelling and infiltration of the cervical soft tissues, with signs of mediastinal infection (encapsulated fluid collections)

Post-aspiration CT show regression of the previously seen fluid collections.

Inflammatory markers range started to change after starting antibiotic and after aspiration of the collected fluid in the neck and plural cavities , as CRP in the 2st week of admission reach 96 mg/dL after aspiration and proper antibiotics reach in 4rth week 12 mg/dL and also leukocyte count from 19.1 n x 10^3 cells/μL in 1st week reach 7.4 n x 10^3 cells/μL in 4rth week , however there was no changes in renal , heart or liver functions during the admission , also Blood and Urine Cultures results with no growth of any organisms .

Therapy and Recovery

Antibiotic therapy was begun empirically on admission and was later altered according to the microbiological examinations and antibiograms only if the cultured organisms revealed resistance towards the begun therapy or if the patient situation deteriorated. Sources of contamination and recurrent or new nosocomial infections were considered before altering the antimicrobial agent regimen. Common choices for the empiric therapy were broad-spectrum intravenous antibiotics combined with metronidazole or clindamycin.

The patient treated at the intensive care unit (ICU), Surgical intervention as an emergency procedure was considered if the condition of the patient deteriorated as the family refused any surgical intervention only if there is an emergency, the medical treatment was supported with some point as the patient is female, young age, and the general condition was good as she didn't need intensive respiratory support, there wasn't any sign of organ failure, and the patient doesn't have any sign of septic shock.

Recovery items including good follow-up and psychological support of the patient are very important, especially for her condition.

Discussion And Conclusions

In this case report we describe a rare case of DNM due to Gram-negative and Gram-positive multidrug-resistant bacteria. We obtained the resolution of DNM by compiling conventional medical therapy and very strict management, even though there was no recommendation for this strategy in this case and there was a lack of literature.

In 1836, W.F.V Ludwig described a Ludwig's angina, as a rapidly and frequently fatal gangrenous progressive cellulitis and oedema of the soft tissues of the neck and floor of the mouth [9]. In addition, the most common cause of Ludwig's angina (proximally 46.9%) is dental infection. Interestingly, the submandibular space was the primary site of infection in 84.0% of patients with Ludwig's angina. However, 16.0% can be involved secondary to an infection of the lateral pharyngeal and parotid spaces. An unsuspecting physician may underestimate an initially localized infection, which could shortly present as airway collapse or descending mediastinitis [4, 6].

Moreover, the inappropriate use of antibiotics, steroids, and nonsteroidal anti-inflammatory drugs may mask signs of infection and change the clinical presentation, making it more elusive, and also lead to a slow course of disease, delayed recovery, and the development of complications [10].

The diagnosis of Ludwig's angina could be mistaken by sub-mental abscess, cellulitis of the sub-maxillary gland, cervical adenitis. That's why the diagnosis should depend on anatomical and clinical criteria. By anatomically, there must be inflammatory involvement of the sublingual and sub-maxillary spaces and the tongue which may be edematous in some cases this involvement depending on the duration of the disease. On the other hand, clinically the patient has rounded, tense, brawny, tender swelling may be unilateral or may be bilateral. However, the patient well has edema, induration, tenderness, and elevation of the floor of the mouth this well leads to difficulty with speech, and in extreme cases may be unable to talk, difficulty with breathing is the last complaint. It's a sign of chronicity[11].

Appropriate radiological tools help for identification of spread between fascial spaces that may not be clinically apparent, clinical examination alone is not enough as it may underestimate the presence of disease in 70% of cases [12, 13].

The cervical fascial layers are divided into a superficial and a deep layer, the deep layer itself consists of three layers (superficial, middle, and deep), which generate the different deep neck spaces, the dorsal part of the submandibular space offers access to the sublingual compartment and the parapharyngeal space, which is connected with the retropharyngeal space, and by this anatomical communicated route, spreading of inflammations, infectious processes may reach into the posterior visceral space and cause for example a Descending Necrotizing Mediastinitis[14–16]. Pharyngeal spaces communicated with the mediastinum leading to complication as pericardial and plural effusion as in our case [14, 15].

In literature between 1970 and 1999 about 102 patients with DNM were also identified from 49 reports published. Their mean age range from 11 months to 71 years, most of these patients had mixed aerobic and anaerobic infections but 4% exceptions there pathogen was β-hemolytic Streptococcus. The origin of the infectious process producing DNM was predominantly Odontogenic. All of these patients were also treated with intravenous antibiotics [4].

Ludwig's angina can lead to multiple complications, including descending necrotizing mediastinitis which is devastating complication, in addition to the even rarer treat it with no major surgical intervention. a differential diagnosis for complications arising from infection in this space include cranial nerve nine to

twelve palsies, Horner's syndrome, carotid artery rupture or sheath abscess and jugular vein suppurative thrombophlebitis (Lemierre's syndrome), infection can spread to the retropharyngeal and danger spaces, located between the posterior border of the pharynx or esophagus, and the anterior border of the spine. These spaces communicate with the mediastinum, leading to complications such as pleural or pericardial effusions, as well as descending necrotizing mediastinitis[13, 14].

DNM is a very rare complication and diagnosis especially for this time and after the era of antibiotics. And management of this type of cases is challenging as the physicians are not very familiar with these uncommon infections. the anatomic communication between these spaces can make a simple untreated infection become a life-threatening condition and the extension beyond the original site of infection makes it difficult for them sometimes to see what the main site of infection[2, 13, 15].

Therapeutic needle aspiration of the abscess was considered an alternative to conventional open surgery, intraoperative findings confirmed the CECT diagnosis in 68-88% of cases [6].

5 years of published data in Japan Yuka Sumi Department of Emergency and Critical Care Medicine, Juntendo University, Urayasu Hospital, Chiba, Japan, comprehensive review of the data regarded about DNM in Japan Twenty-one patients were treated with video-assisted thoracic surgical drainage and 15 cases by percutaneous catheter drainage, whereas transcervical approach was applied in 25 patients and thoracotomy was carried out in 21 patients. The overall mortality was 5.6%. Many authors advocated that the most effective management tool is a high degree of clinical suspicion followed by prompt and adequate drainage with intensive care including hemodynamic and nutritional support and repeat computer tomographic monitoring [7].

The mortality rate of Ludwig's angina is less than 10% but it can increase to reach more than 30% when complicated by descending necrotizing mediastinitis, so we can say that Ludwig's angina is a potentially life-threatening condition when it doesn't treated well [6, 14].

Moreover, management of this condition primarily start with the surgical choice because the mortality rate increased by the high risk of septic shock in delayed managed patent. In other hand, the appropriate medical management and aspiration of the collected abscess leads to a good result especially the good general condition and the absents of risk factors for septic shock, this position is supported by Ungkanont et al., who successfully treated 37% of the DNIs in a series of 117 children exclusively by antibiotics[17].

Notably, the complication of surgery such as high-cost procedures, risk of mortality during surgery reach, recollect of the drained abscess, risk of anesthetic-related nausea and vomiting, wound infection, scares, bad cosmetic appearance, In addition to the impact of surgery on psychiatric patients, all these complications can be avoided by appropriate medical treatment [18, 19]. In our opinion, even if nonsurgical treatment is tempting, more data are needed before abolishment of surgical intervention.

In summary, DNM is an uncommon entity with an often-nonspecific clinical presentation. So far, the medical treatment did not seem to increase complications of deep neck infections and does not increase the length of hospitalization and is not associated with more morbidity or mortality. In view of our experience, the DNM case of descending necrotizing mediastinitis had been successfully treated due to early diagnosis and adequate medical treatment, also, we believe that only through aggressive combined medical management by antibiotics directed at both aerobic and anaerobic organisms and drainage at all pus collection sites can reversible the effect of DNM the highly morbid.

Declarations

Acknowledgements

The authors wish to thank all nurses in Cartage healthcare Unit and technician who were involved in this study, and Hamza El-thelb for editing the text.

Conflicts of interest:

The authors have declared that no competing interests exist.

Contributors:

(I)Manuscript writing: All authors; (II) Final approval of manuscript: All authors.

References

1. Suppuration C, Pearse HE. Mediastinitis following. Infection.:588–611.
2. Freeman RK, Vallières E, Verrier ED, Karmy-Jones R, Wood DE. Descending necrotizing mediastinitis: An analysis of the effects of serial surgical debridement on patient mortality. J Thorac Cardiovasc Surg. 2000;119:260–7.
3. Sarna T, Sengupta T, Miloro M, Kolokythas A. Cervical necrotizing fasciitis with descending mediastinitis: Literature review and case report. J Oral Maxillofac Surg. 2012;70:1342–50.
4. Marty-Ane CH, Alauzen M, Alric P, Serres-Cousine O, Mary H. Descending necrotizing mediastinitis: Advantage of mediastinal drainage with thoracotomy. J Thorac Cardiovasc Surg. 1994;107:55–61.
5. Huang SM, Wu RC. Rare Type of Deep Neck Infection: Two Cases of Descending Necrotizing Mediastinitis. Tzu Chi Med J [Internet]. Buddhist Compassion Relief Tzu Chi Foundation; 2009;21:348–51. Available from: http://dx.doi.org/10.1016/S1016-3190(09)60070-7.
6. Boscolo-rizzo P, Cristina M, Mosto D. Submandibular space infection: a potentially lethal infection. 2009.
7. Sumi Y. Descending necrotizing mediastinitis: 5 years of published data in Japan. Acute Med Surg. 2015;2:1–12.

8. Foroulis CN, Sileli MN. Descending Necrotizing Mediastinitis: Review of the Literature and Controversies in Management. 2011;12–8.
9. Reports C. Periorbital swelling: the important distinction between allergy and infection. 2004;240–65.
10. Boscolo-Rizzo P, Marchiori C, Montolli F, Vaglia A, Da Mosto MC. Deep neck infections: A constant challenge. Orl. 2006;68:259–65.
11. Ashbel C, Williams, Guralnick W. The Diagnosis and Treatment of Ludwig's Angina: A Report of Twenty Cases. N Engl J Med. 1943;228.
12. Nubiato Crespo A, Takahiro Chone C, Santana Fonseca A, Montenegro MC, Pereira R, Altemani Milani J. Clinical versus computed tomography evaluation in the diagnosis and management of deep neck infection. Sao Paulo Med J. 2004;122:259–63.
13. Reynolds SC, Chow AW. Life-Threatening Infections of the Peripharyngeal and Deep Fascial Spaces of the Head and Neck. 2007;21:557–76.
14. Tejura N, Kapila R, Dever L. Ludwig's Angina Complicated by Descending Necrotizing Mediastinitis and Superimposed Candida mediastinitis: Case Report and Literature Review. J Dent Maxillofac Surg. 2018;1:33–6.
15. Kinzer S, Pfeiffer J, Becker S, Ridder GJ. Severe deep neck space infections and mediastinitis of odontogenic origin: Clinical relevance and implications for diagnosis and treatment. Acta Otolaryngol. 2009;129:62–70.
16. Marra S, Hotaling AJ. Current Reviews Deep Neck Infections. 1996;17:287–98.
17. Ungkanont K, Yellon RF, Weissman JL, Casselbrant ML. Head and neck space infections in infants and children. 1995.
18. Van Der Brempt X, Derue G, Severin F, Colin L, Gilbeau JP, Heller F. Ludwig's angina and mediastinitis due to Streptococcus milleri: Usefulness of computed tomography. Eur Respir J. 1990;3:728–31.
19. Jayasekera BAP, Dale OT, Corbridge RC. Descending Necrotising Mediastinitis: A Case Report Illustrating a Trend in Conservative Management. Case Rep Otolaryngol. 2012;2012:1–4.

Tables

Table 1. Laboratory Values Throughout Hospitalization

	Reference Range	Patient Result at time of admission	Patient Result during 2nd/W of admission	Patient Result in 4rth/W of admission (Predischarge)
	4-15 n x 10^3 cells/ µL	19.1	14.1	7.4
globin	9-11g/dl	8.7	9.6	9.1
et	150-450 10^3/µL	574	436	368
m **e**	70-120 mg/dL	127	85	116
nine	0.6-1.4 mg/dL	0.6	0.7	0.6
	10-50 mg/dL	17	30	29
	135-155 mmol/L	125	133	135.3
	3.5-5.5 mmol/L	3.63	4	3.59
	98-107 mmol/L	105	106	100.8
3	Up to 25 U/L	17.4		
ONIN-	Up to 0.30 ng/mL	<0.01		
	0-0.5mg/dL	24	96	12
and	No growth			

Table 2. Laboratory Values of Fine Needle Aspiration samples from sub-mandibular swelling which done in 1st week of admission

BACTERIOLOGY	
Body Fluid Differential Cell Count	
Sample origin	Pus (Neck)
Result	
Lymphocytes	20%
Neutrophil	80%
PUS C/S	
PHYSICAL EXAMINATION	
Sample origin	Pus (Neck)
Color & Appearance	Yellowish brown / Turbid
MICROSCOPIC EXAMINATION	
white blood cells	Moderate
Yeast	Nil
CULTURE AND IDENTIFICATION	
Culture	No growth after 48 hours of incubation
GRAM STAIN	
Sample origin	Pus (Neck)
Bacteria	No bacteria seen
Yeast	Nil

Table 3. Laboratory Values of Pleural fluid sample which done in 1st week of admission

BIOCHEMISTRY	
Body Fluid LDH	1008 U/L
Body Fluid Analysis	
Specimen	Pleural Fluid
Appearance and color	Slightly turbid/Dark yellow
Specific Gravity	1.005
Total protein	47.9 g/L
Glucose	46.2 mg/dL
Red blood cells	13000 /mm^3
white blood cells	500 / mm^3
Lymphocytes	30 %
Neutrophil	70 %

BACTERIOLOGY	
Body Fluid c/s	
Sample origin	Pleural Fluid
Color & Appearance	Slightly turbid/Dark yellow
Culture	No growth after 48 hours of incubation
GRAM STAIN	
Sample origin	Pleural Fluid
Bacteria	No bacteria seen
Yeast	Nil

Figures

Figure 1

Clinical appearance evidencing submandibular, submental and sublingual extensive swelling.

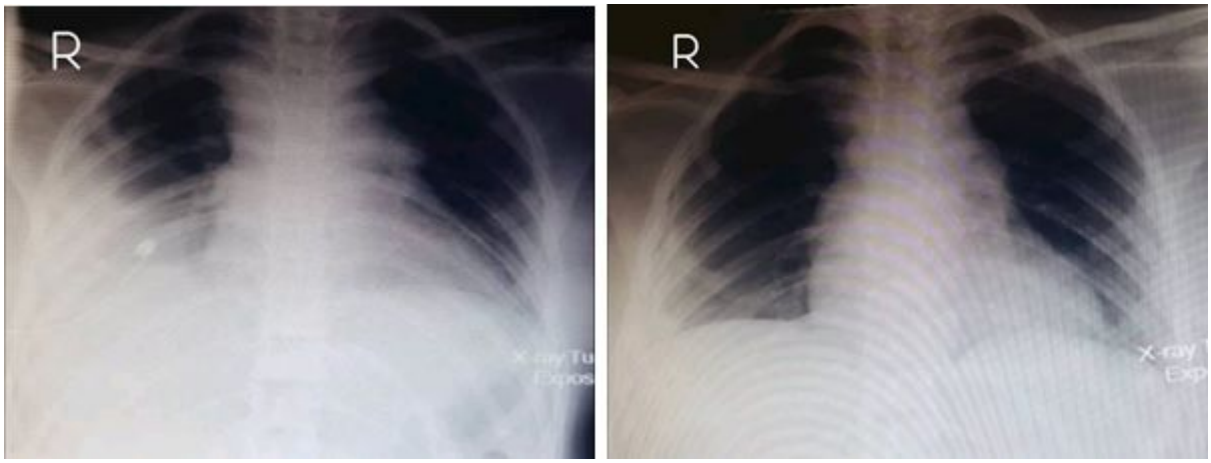

Figure 2

Chest x-ray showing massive right costophrenic angle obliteration. (A) at time of admission, (b) before discharge.

Figure 3

A. The 2nd Computed tomography (CT) SCAN at 11.01.2020. **B.** The 3rd Computed tomography (CT) SCAN at 11.2.2020.

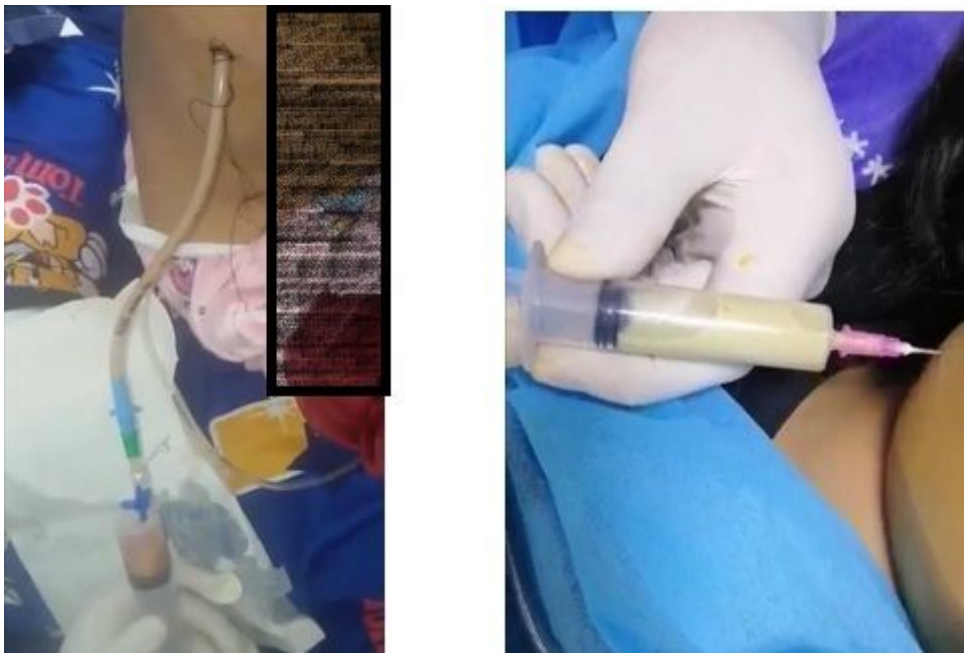

Figure 4

pictures showing the puss aspirated from right lower lobe of the chest. (A) and right submandibular (B) area.