Comparison of Different Parathyroid Autograft Project after Total Parathyroidectomy in Patients with Secondary Hyperparathyroidism

mengjia FEI
Shanghai Jiao Tong University School of Medicine Affiliated Renji Hospital
dong XU
Shanghai Jiao Tong University School of Medicine Affiliated Renji Hospital
yi LAI
Shanghai Jiao Tong University School of Medicine Affiliated Renji Hospital
yanan XU
Shanghai Jiao Tong University School of Medicine Affiliated Renji Hospital
jingwen ZHANG
Shanghai Jiao Tong University Medical School Affiliated Ruijin Hospital
jiadong WANG (drjiadongw@126.com)
Shanghai Jiao Tong University School of Medicine Affiliated Renji Hospital

Research

Keywords: Secondary hyperparathyroidism, Parathyroidectomy, Transplantation of parathyroid autograft, Comparison of different project

Posted Date: December 15th, 2020

DOI: https://doi.org/10.21203/rs.3.rs-127808/v1

Abstract

Objective To evaluate the feasibility and efficacy of total parathyroidectomy followed by modified needle-quantified injection of parathyroid autograft compared with classic incision and transplantation.

Methods We conducted a retrospective study of 171 patients with secondary hyperparathyroidism treated by hemodialysis or peritoneal dialysis. These patients were included in our study from April 2006 to December 2016,who had undergone total parathyroidectomies with autotransplantation . Patients were divided into classic incision for transplantation of parathyroid autograft group and modified needle-quantified injection group. Clinical and biochemical characteristics, including preoperative and postoperative intact parathyroid hormone levels were recorded and compared between two group patients.

Results To compare the techniques of modified needle-quantified injection and classic incision and transplantation, pre- and postoperative biochemistry and length of operation was recorded and analyzed. Preoperative biochemistry was similarly in both groups. However, autograft function achieved was significantly faster in the group with modified needle-quantified injection compared with classic incision and transplantation (P = 0.03). Median time to parathyroid function regain was 3 months for injection compared with 7 months for classic incision. There was no remarkable difference in the recurrence rates between the two groups.

Conclusion The modified needle-quantified injection of parathyroid tissue is a feasible and simple alternative to the more commonly used method of classic incision and transplantation.

1. Background

Secondary hyperparathyroidism (SHPT) is one of the most common clinical problems faced by chronic kidney disease (CKD) patients with long-term dialysis. This disease may even lead to a significant increase in all-cause death and cardiovascular death in patients, which seriously affects their quality of life[1]. Statistics data show that nearly 10–30% of CKD patients with a history of hemodialysis over 10 years will progress to severe SHPT, and 75% of CKD patients have persistent SHPT, which leads to the formation of proliferative lesions or tumors of parathyroid cells[2,3]. Calcium, phosphorus, and parathyroid hormone (PTH) metabolic disorders are typical laboratory findings in patients with SHPT. Low calcium and hyperphosphatemia are considered to be important factors in the occurrence and development of SHPT.

The medical treatment for early phase of SHPT includes active vitamin D analogues, calcium-sensitive receptor agonists, etc. In recent years, with the standardized application of drug treatment, the amount of parathyroid surgery in the world has shown a certain downward trend[4]. However, as increase of patients age, calcium and phosphorus metabolism disorders, patients with poor response to drug and general treatment often progress to refractory SHPT. Thus, these patients eventually need to undergo parathyroid surgery. At present, there are three main types of SHPT surgery: subtotal parathyroidectomy (SPTX), total

parathyroidectomy (TPTX), total parathyroidectomy with autotransplantation (TPTX + AT). SPTX is designed to avoid severe post-operative hypocalcemia and permanent hypoparathyroidism. However, the disadvantage of this surgical approach is that the amount of tissue retained cannot be precisely controlled for individual differences in the patient. It is true that most patients have a good long-term prognosis[5], but SPTX has also been mentioned in some literatures with a high recurrence rate, and the potential risk of secondary surgery has caused patient suffering[6,7]. Based on the above considerations, more and more surgeons tend to detect and remove all of enlarged parathyroid glands and normal glands (usually 4). Refractory hypocalcemia is relatively prone to be occurred in TPTX, which need long-term calcium and calcitriol supplementation and also have a risk of low turnover bone disease. Therefore, the parathyroid autograft was performed on the non-dialysis fistula side forearm during the operation. The classic Wells' method was used to select the parathyroid gland for transplantation, which should be the smallest volume, relatively normal appearance or simply diffuse hyperplasia with pathological evidence[4,8,9]. Apparently, the choice of TPTX + AT also has problems such as prolongation of operation time, new scar on the forearm, and increased risk of local infection and bleeding. For decades, we have also made many attempts and explorations in forearm transplantation of parathyroid. Currently, we are routinely using the modified 1 ml-syringe quantitative injection method to transplant the parathyroid glands. The purpose of this retrospective study was also to analyze the feasibility and effectiveness of this innovative approach of parathyroid transplantation.

2. Materials And Methods

2.1 Patients

After obtaining approval from the Research Ethics Committee of Renji Hospital, the clinical data of 171 patients with secondary hyperparathyroidism were admitted to this retrospectively study. All patients underwent the operation between April 2006 to December 2016 at head and neck surgery of Renji Hospital affiliated to Shanghai Jiaotong University School of Medicine. Written informed approval was obtained from each participant’s legal guardian and is available for verification through the medical records department of our hospital. The selection of operation and preoperative preparation were determined through multidisciplinary discussions. The indications for surgery were based on the Kidney Disease: Improving Global Outcomes (KDIGO) Guide[3]: Patients with chronic renal disease stage III and above, who followed one or more criterias (1) PTH persistently higher than 800 pg/ml (at least twice casual examinations), (2) persistent hypercalcemia and/or hyperphosphatemia with drug therapy ineffective, (3) image examination including ultrasonography and or parathyroid isotope scan with at least one parathyroid enlargement and a diameter greater than 1 cm, (4) combined with ostealgia, skeletal deformities and even fractures, skin itch and calcific uremic arteriolopathy. Accordingly, all patients diagnosed with primary hyperparathyroidism and those with a history of thyroid/parathyroid surgery were not included in the study.

2.2 Operation method

All patients in this study underwent total parathyroidectomy with autograft, and there were two projects for autotransplantation: group one for the classic forearm incision into brachioradialis and the other group for modified 1 ml-syringe forearm quantitative injection method for transplantation of parathyroid glands. For each patient, the transplantation method is mainly determined by the patient's medical team. It is worth mentioning that the surgeons gradually accepted and preferred to use the modified 1 ml-syringe quantitative injection method during the study, which led to a quantity variance between patients of the two groups. Until the later stage of the study, the effect of modified 1 ml-syringe forearm quantitative injection had been confirmed by all the surgeons. Two autotransplantation methods are described and compared in following aspects. Intraoperative rapid PTH testing was not widely used in this study. The intraoperative search for parathyroid glands relied mainly on anatomical localization, and some cases were supplemented with 99mTc-methoxyisobutyl isonitrile(99mTc-MIBI) and nano-carbon suspension,who indicates the position of the parathyroid gland. All the resected specimens were strictly compared with the preoperative imaging examination. The fast frozen pathology was performed during the operation, by which the parathyroid gland should be comfirmed as benign hyperplasia lesion. The patients in this study did not routinely underwent thymectomy.

In the group of patients with classic forearm incision into brachioradialis, approximately 60 mg autograft tissue selected from the smallest or non-nodular parathyroid gland, which was diced using a fresh scalpel to < 1 mm^2 fragments and divided into 4 portions. Then, a 2–3 cm incision was made in the non-hemodialysis side forearm, and four capsular pockets were separated in the brachioradialis, and 1 portion of parathyroid tissue placed in each pocket, and then each pocket closed with a silk suture; In the modified 1 ml syringe quantitative injection group, the same amount of parathyroid tissue was minced using a fresh scalpel. The graft was processed into 1 ml syringe, which generally added to 0.2 ml scale. As shown in Fig. A, the method to improve the syringe is to cut off all the front-end of the barrel, so as to completely expose the inner plunger of the it. At the time of transplantation, a small mouth of about 5 mm was cut in the forearm, and the vascular clamp was gently separated through the incision to assist in formatting a skin-subcutaneous-muscle passage. When to the process of transplantation, the modified 1 ml syringe is placed vertically along the incision. In view of the special structure of the plunger of 1 ml syringe, the front-end of the plunger naturally forms a "guide rod", which can smoothly guide the syringe to the superficial muscle layer. After the syringe enters the forearm muscle during the transplantation process, there is a certain sense of breakthrough, and then all the grafts are quickly delivered and sutured.

Figure 1A material preparation before transplantation B parathyroid gland prepared has been put into the syringe C forearm transplantation process

2.3 Follow-up

The postoperative serum PTH (reference range 12–72 pg/L), corrected serum calcium, and serum phosphorus levels on day 1 and day 3 were recorded. The symptoms of low calcium such as numbness of the hands and feet, hypocalcemic tetany were observed, which were routine treated by 10% calcium gluconate 10 ml (6–8 g / day) intravenous fluid therapy; Long-term calcium tablet and activity Vitamin D

treatment had been applied ,when patients had symptom of persistent mild hypocalcemia. The follow-up of all patients after discharge from the hospital was recorded by the nephrology and Head and Neck Surgery. This study identified the success of the operation as postoperative PTH level < 72 ng / L(the upper limit of the reference range); postoperative persistent parathyroid gland hyperactivity was defined as PTH level still three-fold higher than the upper limit of the reference value on the third postoperative day[10,11]. For patients match the criterion of successful operation,it is necessary to follow-up the trend of PTH level : the monthly postoperative PTH level should be recorded for patients had lower normal value when discharge from hospital. Until the PTH level reach the normal reference range, the follow-up interval could extend to every 3–6 months. If the random PTH > 400 ng/L during follow-up, the possibility of disease recurrence caused by prosthetic graft hyperplasia should be considered[10]. Beyond that, if the clinical observation and imaging evidence suggest that the forearm graft hyperplasia is significant, the forearm graft should be removed. The operation for removal of the graft is likely to be performed under local anesthesia. If new lesion postoperative with PTH secretion function is found in the neck or mediastinum, the residual parathyroid gland + graft removal under general anesthesia is performed.

2.4 Statistical analysis

Statistical analysis was performed using SAS version 9.3 software. The continuity variables were expressed as $\bar{\chi} \pm s$, and categorical variables were expressed as rates. The t-test was used to compare the mean between the groups; the non-parametric rank sum test was used for the non-conformity distribution, and the chi-square test was used to compare the relevant factors. The time taken to normalization of PTH after parathyroidectomy was calculated using the Kaplan–Meier method.

3. Result

From April 2006 to December 2016, a total of 171 patients with renal secondary hyperparathyroidism included in the analysis of this study, who underwent total parathyroidectomy and forearm transplantation in our hospital(Table 1). Among the patients who underwent surgery, 118 (69.9%) underwent syringe injection method; 53 (30.1%) underwent a classical forearm incision to transplant the parathyroid gland. It should be noted that this method of forearm incision to transplant the parathyroid gland was used concentrated in the first five years of the study. With postoperative PTH value, 11 patients (6.4%) had persistent hyperparathyroidism, and 3 patients (1.8%) had low levels of parathyroid function for more than 12 months (2.56 pg/ml, 3.70 pg /ml, 3.87 pg/ml) combined with hypocalcemia, which is considered as postoperative persistent hypoparathyroidism.

Table 1
Clinical characteristics of patients (n = 171) who had undergone operation between April 2006 and December 2016

Characteristics	Total parathyroidectomies
Age (y)	
Median	55
Range	34—76
Sex	
Male	77(45%)
Female	94(55%)
Dialysis	
Hemodialysis	135(78.9%)
Peritoneal dialysis	32(18.7%)
Neither	4(2.3%)
No. of glands removed	
2*	1(0.6%)
3	12(7.0%)
4	151(88.3%)
5	7(4.1%)
*One patient only 2 parathyroid glands were found, so that an additional hemithyroidectomy on the suspected side and no AT was performed.	

Considering that the main purpose of this study is to compare the two different transplantation techniques, we have selected a total of 160 patients who met the criteria for successful clinical operation among all the patients mentioned above with long-term follow-up data. There are 111 patients with modified syringe forearm quantitative injection method, 49 patients with classic forearm incision method to transplant the parathyroid gland. There were no statistically significant differences between the two groups in clinical characteristics and laboratory results (Table 2). In order to compare the recovery of parathyroid function with two different transplantation methods, the whole course PTH level of patients was completely recorded. The process of PTH from the postoperative low state to the normal range was especially concerned: A Kaplan–Meier plot was generated to compare the restoration of parathyroid function of the parathyroid glands as defined in months by a return of PTH levels from sub- normal to normal levels (Fig. 2). According to the statistical results, patients who took the syringe forearm quantitative injection method had a shorter recovery time of postoperative PTH level than the forearm incision intramuscular transplantation (P = 0.03). In the syringe quantitative injection group, the mean

parathyroid function recovery time was about 3 months; on the other hand, the data was 7 months in the forearm incision muscle transplantation group. In addition, 3 patients were defined as persistent hypoparathyroidism after surgery: there was 1 patient in the syringe injection transplantation group, whose PTH level returned to the normal range at the 41st month after surgery; there were 2 patients in the forearm incision intramuscular transplantation group, whose PTH level was still lower than the normal lower limit until end of the follow-up. The follow-up time for these two patients was 46 months and 63 months after operation.

Figure 2 Kaplan–Meier curves showing time to normalization of parathyroid hormone (PTH) levels in patients with successful total parathyroidectomy, comparing modified syringe injection and classic forearm incision (P = 0.03).

A comparison of postoperative recurrences between the two groups of different transplantation methods showed that either 'recurrence' was defined as requiring reoperation due to graft hyperplasia (P = 0.629) or only PTH > 400 pmol/L as recurrence definition(P = 0.277), which were statistically considered to have no significant differences. During the period of the study, there were three patients in each group requiring reoperation for the forearm graft. Among them, there were 2.5% (3/111) patients in the group of the syringe forearm quantitative injection (1 case within 12 months after surgery, 1 case within 12–24 months, 1 case within 24–36 months) and 6.1% (3/49) patients in the group of forearm incision muscle transplantation (1 case within 12 months after surgery,2 cases within 24–36 months). The median corrected calcium level before reoperation was 2.54 mmol/L (2.47–2.85) in the patients with syringe forearm quantitative injection method, and 2.32 mmol/L (2.02–2.60) in the patients with forearm incision muscle transplantation group. There was no statistical difference between the two groups. The average time for removal of forearm graft was 18 minutes with the modified syringe injection method, which is statistically considered to be superior to the traditional forearm incision graft method with an average length of about 29 minutes (reduce surgery time by nearly 30%,P = 0.02). During this study, in addition to the graft recurrence mentioned above, there were another 4 patients had the gradually rising PTH and reached three-fold higher than the upper normal reference limit. Two patients were scheduled for reoperation within the first year after initial surgery and cured after resection of the missing gland that was found in the mediastinum. Other two patients refused reoperation, were treated with calcimimetics with consecutive reduction of PTH below the three-fold of the upper normal value within 2 years after surgery.

Table 2 Comparisons of the two group of patients with different parathyroid

gland transplantation methods (n=160)

Patient Characteristics &laboratory examination	Syringe quantitative injection	Classic forearm incision	P value
All patients, N = 160	111	49	
Age（y）			0.294
Median	58	57	
Range	34-73	39-76	
Sex			0.35
Male	51（45.9%）	20（40.8%）	
Female	60（54.1%）	29（59.2%）	
Dialysis method			0.462
Hemodialysis	97	41	
Peritoneal dialysis	13	8	
Unclear	1	/	
Duration of dialysis（y）			0.433
Median	8	7	
Range	1-23	2-30	
Operating time（min）			0.356
Median	109	117	
Range	60-253	60-241	
Preoperative PTH（pg/ml）			0.243
Median	1324	1204	
Range	347-2500	390-2500	
Postoperative PTH（pg/mL）			0.406
<12	78（70.3%）	31（63.3%）	
12-72	27（24.3%）	14（28.5%）	
72-216*	6（5.4%）	4（8.2%）	
PTH on POD3（pg/mL）			0.371
<12	69（62.2%）	28（57.2%）	
12-72	33（29.7%）	15（30.6%）	
	9（8.1%）	6（12.2%）	

72-216*			
Preoperative corrected Ca□mmol/L□			0.593
Median	2.75	2.76	
Range	2.23-3.76	2.44-3.33	
Postoperative corrected Ca□mmol/L□			0.201
Median	2.48	2.44	
Range	2.08-2.81	1.95-2.96	
Dose of calcium carbonate on discharge (g)			0.378
Median	8	9	
Range	6-26	6-25	

* This table shows a total of 160 patients who meet the criteria for successful surgery, the maximum PTH range selected is three times 72pg/mL.

4. Discussion

With the standardized treatment of kidney-related diseases, the number of patients requiring long-term dialysis is on the rise. Thus, the incidence of secondary hyperparathyroidism is increasing year by year. In the 1960s, Stanbury [4] first reported two cases of subtotal parathyroidectomy for the treatment of secondary hyperparathyroidism. In view of the lack of consensus that can be widely recognized, the choice of surgical procedure and the way the parathyroid gland is transplanted depends largely on the surgeon's experience. At present, most surgeons tend to choose total parathyroidectomy with forearm autotransplantation, and the positon of the transplanted gland is constantly optimized. In the process, most surgeons chose non-neck incision transplantation: the reason is that when choosing a cervical incision transplant, such as intrasternal sternocleidomastoid, which face a greater risk of complications during the second surgery. Nevertheless, the technique of parathyroid autotransplantation has also been evolving.

There is a certain amount of reports on how to perform autologous transplantation of parathyroid glands, but there are not many involved transplanting parathyroid glands into the forearm or deltoid muscle by injection, and most of them are still in the exploration stage[4,10,12]. In this study, we retrospectively analyzed perioperative management of patients with secondary hyperparathyroidism. Specifically, we

focused on comparing the efficacy of the modified syringe injection for parathyroid gland transplantation with that of conventional incision for parathyroid gland transplantation in forearm muscles.

With the modified syringe transplantation, the average recovery time of parathyroid hormone was about 3 months. This data is much better than the average recovery time of the traditional muscle incision transplantation method for about 7 months. According to the analysis of the existing results, the transplantation of the parathyroid gland by syringe injection has achieved a relatively better clinical effect. The reason for this could be that the injection requires that the transplanted parathyroid tissue be as close to the homogenized state as possible, and that the transplanted tissue is made more 'fine' after the injection in a thinner diameter syringe. The greater surface area allows for better imbibition of the graft and possibly a better uptake as a result. On the other hand, for the two different transplantation methods: the proportion of 'recurrence' of hyperparathyroidism due to grafts, there was no statistically significant difference in this study. Although there were only 49 patients in our intramuscular group with conventional incisions, the cumulative frequency of intramuscular autograftectomy was similar to the results of Tominaga's study[13], which included 2,660 intramuscular autotransplantation patients. At 5 years, the cumulative frequency of intramuscular autograftectomy was 7.5% in Tominaga's study and is 6.1% in the present study. However, there are several studies consider that intramuscular multi-point transplantation with conventional incisions has a higher recurrence rate than other transplantation methods like subcutaneous autotransplantation[10,14].In our study, there are similar situations that the cumulative frequency of autograftectomy in syringe injection group is 2.7%,which is much better than conventional incisions group.In summary, these data suggest that the method of modified syringe injection is a feasible alternative with a comparable, if not greater, efficacy than implantation of conventional incision. Moreover, in response to the possible secondary removal after modified syringe injection, the reoperation could in a relatively shorter time($P = 0.02$), simpler operation and less trauma under local anesthesia. On the contrary, for patients with intra-brachioradialis muscle transplantation, the reoperation need to find and remove the graft placed in muscle pockets, and face prolonged operation time and even higher risk of bleeding.

The research process also considers the possible impact of some system factors. First of all, as a retrospective study involving four different surgeons with their own personal preferences with regard to the 2 different techniques. When doctors perform two different types of transplanting parathyroid surgery, there is no denying that there will be minor differences in personal surgical habits. Interestingly, after experiencing the advantages of the syringe injection of the parathyroid gland, all four surgeons gave up the traditional muscle incision transplantation method at some stage of the study. In addition, the medical environment in China is rather unusual in that the proportion of hemodialysis patients is much higher than that of patients with peritoneal dialysis. It has been also documented [15,16] that secondary hyperparathyroidism tends to be more severe in patients undergoing hemodialysis compared with patients on peritoneal dialysis. Thus, this reason explains our high patient quantity undergoing total parathyroidectomy, and the reported recurrence rate may be also affected.

5. Conclusion

Overall, we have innovated the use of a modified 1 ml syringe forearm for quantitative injection of the transplanted parathyroid method. As an innovative improvement of forearm transplantation, modified 1 ml syringe quantitative injection has its own advantages: firstly, it is technically simpler, faster, with high repeatability and less obvious postoperative scar; secondly, the selected parathyroid tissue will be cut into small pieces, which can generate functional as soon as possible. Third, the transplanted area is relatively concentrated, and if there is a need for secondary surgical removal, the operation is relatively simple. Therefore, for patients with persistent and drug-refractory secondary hyperparathyroidism, this modified innovative transplantation method is a very effective option when performing forearm transplantation after total parathyroidectomy.

6. Abbreviations

SHPT Secondary hyperparathyroidism

CKD Chronic kidney disease

PTH Parathyroid hormone

SPTX Subtotal parathyroidectomy

TPTX Total parathyroidectomy

TPTX + AT Total parathyroidectomy with autotransplantation

POD3 The third day after the operation

Declarations

Ethics approval and consent to participate

This study was approved by the Ethics Committee of Renji Hospital Affiliated to Shanghai Jiaotong University School of Medicine and written informed consent was obtained from patients.

Consent for publication

Not applicable

Availability of data and materials

The datasets used and analyzed during the current study are available from the corresponding author on reasonable request.

Competing interests

The authors declare that they have no competing interests.

Authors' contributions

FMJ,XD,ZJW : designed the study, collated the information, analyzed and interpreted the data, did statistical evaluation, wrote the paper . WJD approved the final version of the manuscript, designed the study. LY: did statistical evaluation, searched the literature. XYN: helped in literature search and preparing the manuscript , did follow up work.

All authors read and approved the final version of the manuscript.

Acknowledgements

Anyone who contributed towards the article meets the criteria for authorship. Therefore, there are no further acknowledgements to state.

Funding

This research did not receive any specific grant from funding agencies in the public, commercial, or non-profit sectors.

References

1. Tentori F, Wang M, Bieber BA, et al. Recent changes in therapeutic approaches and association with outcomes among patients with secondary hyperparathyroidism on chronic hemodialysis: the DOPPS study. Clin J Am Soc Nephrol. 2015;10(1):98–109.
2. Bilezikian JP, Bandeira L, Khan A, et al. Hyperparathyroidism Lancet. 2018;391(10116):168–78.
3. Uhlig K, Berns JS, Kestenbaum B, et al. KDOQI US commentary on the 2009 KDIGO Clinical Practice Guideline for the Diagnosis, Evaluation, and Treatment of CKD-Mineral and Bone Disorder (CKD-MBD). American journal of kidney diseases: the official journal of the National Kidney Foundation. 2010;55(5):773–99.
4. Ng JC, Wang W, Chua MJ, et al. Subcutaneous injection is a simple and reproducible option to restore parathyroid function after total parathyroidectomy in patients with secondary hyperparathyroidism. Surgery. 2014;155(4):682–8.
5. Anderson K Jr, Ruel E, Adam MA, et al. Subtotal vs. total parathyroidectomy with autotransplantation for patients with renal hyperparathyroidism have similar outcomes. American journal of surgery. 2017;214(5):914–9.
6. Lorenz K, Bartsch DK, Sancho JJ, et al. Surgical management of secondary hyperparathyroidism in chronic kidney disease–a consensus report of the European Society of Endocrine Surgeons. Langenbeck's archives of surgery. 2015;400(8):907–27.

7. Madorin C, Owen RP, Fraser WD, et al. The surgical management of renal hyperparathyroidism. Eur Arch Otorhinolaryngol. 2012;269(6):1565–76.
8. Schlosser K, Bartsch DK, Diener MK, et al. Total Parathyroidectomy With Routine Thymectomy and Autotransplantation Versus Total Parathyroidectomy Alone for Secondary Hyperparathyroidism: Results of a Nonconfirmatory Multicenter Prospective Randomized Controlled Pilot Trial. Annals of surgery. 2016;264(5):745–53.
9. Filho WA, van der Plas WY, Brescia MDG, et al. Quality of life after surgery in secondary hyperparathyroidism, comparing subtotal parathyroidectomy with total parathyroidectomy with immediate parathyroid autograft: Prospective randomized trial. Surgery. 2018;164(5):978–85.
10. Hsu YC, Hung CJ. Intramuscular and subcutaneous forearm parathyroid autograft hyperplasia in renal dialysis patients: A retrospective cohort study. Surgery. 2015;158(5):1331–8.
11. Sakman G, Parsak CK, Balal M, et al. Outcomes of Total Parathyroidectomy with Autotransplantation versus Subtotal Parathyroidectomy with Routine Addition of Thymectomy to both Groups: Single Center Experience of Secondary Hyperparathyroidism. Balkan Med J. 2014;31(1):77–82.
12. Gopalakrishna Iyer N, Shaha AR. Complications of thyroid surgery: prevention and management. Minerva chirurgica. 2010;65(1):71–82.
13. Tominaga Y, Matsuoka S, Uno N, et al. Removal of autografted parathyroid tissue for recurrent renal hyperparathyroidism in hemodialysis patients. World J Surg. 2010;34(6):1312–7.
14. Agha A, Loss M, Schlitt HJ, et al (2012) Recurrence of secondary hyperparathyroidism in patients after total parathyroidectomy with autotransplantation: technical and therapeutic aspects. European Archives of Oto-Rhino-Laryngology. 269 (5):1519–1525.
15. Messa P, Castelnovo C, Scalamogna A. Calcimimetics in peritoneal dialysis patients. Contributions to nephrology. 2012;178:143–9.
16. Tominaga Y, Matsuoka S, Uno N, et al. Removal of Autografted Parathyroid Tissue for Recurrent Renal Hyperparathyroidism in Hemodialysis Patients. World J Surg. 2010;34(6):1312–7.

Figures

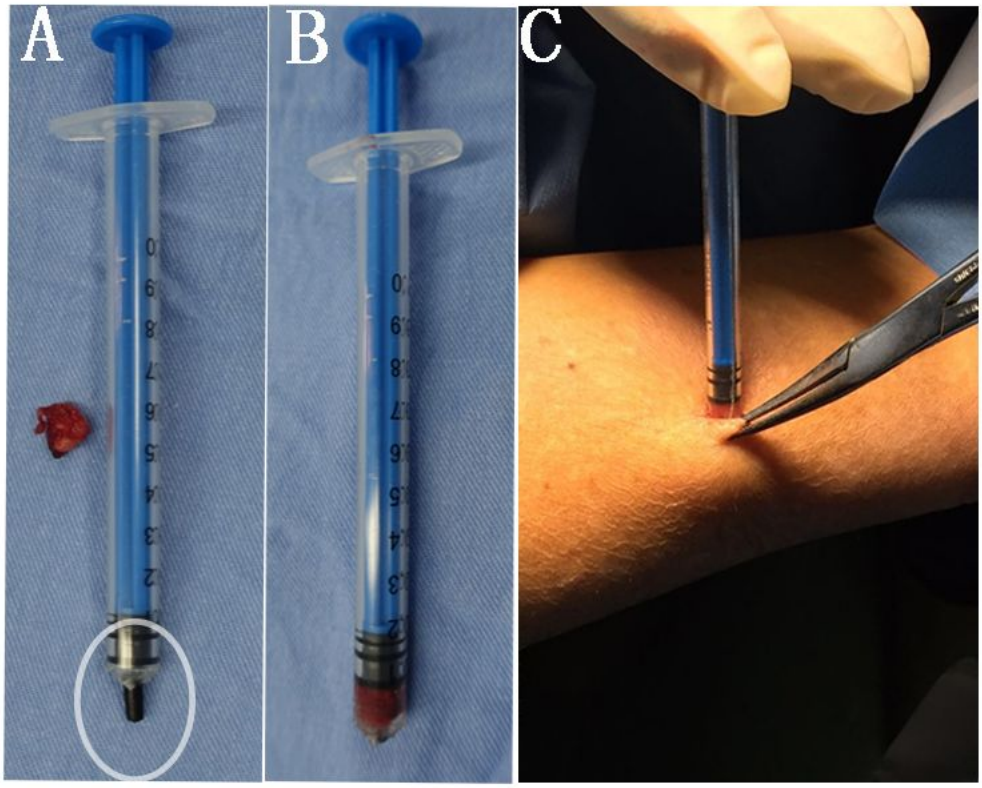

Figure 1

A material preparation before transplantation B parathyroid gland prepared has been put into the syringe C forearm transplantation process

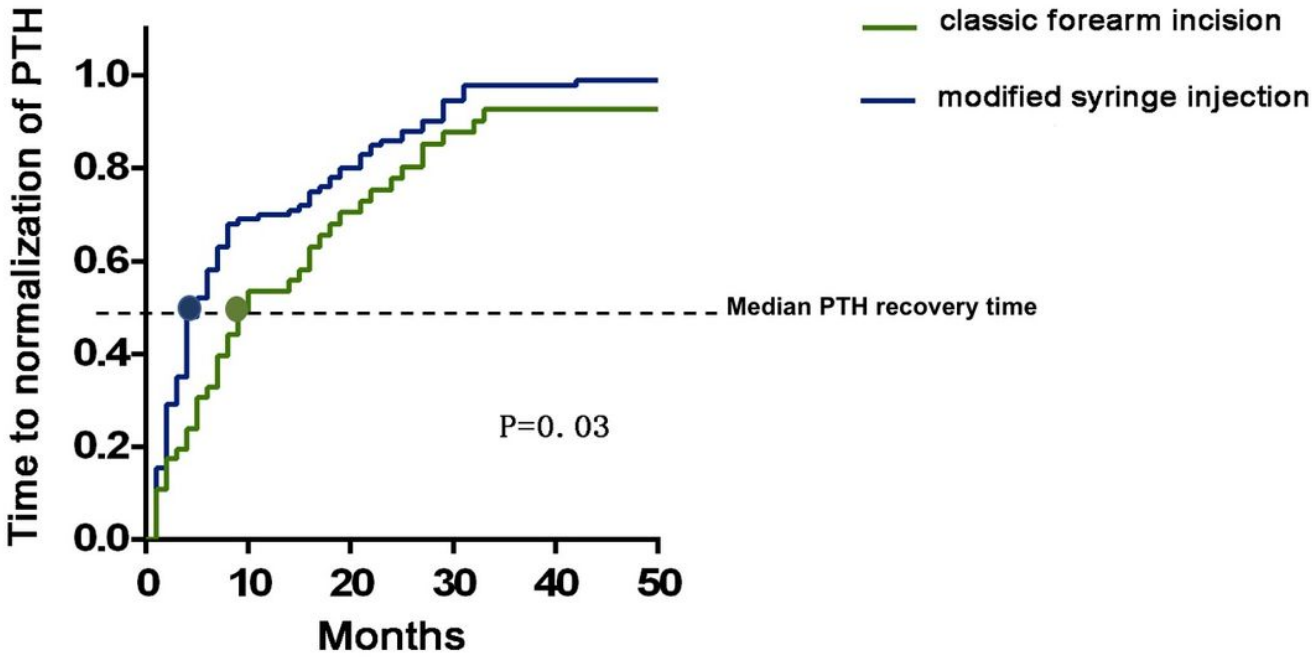

Figure 2

Kaplan–Meier curves showing time to normalization of parathyroid hormone (PTH) levels in patients with successful total parathyroidectomy, comparing modified syringe injection and classic forearm incision (P =0.03).