Value of Echocardiography Combined with Lung Ultrasound in The Diagnosis and Treatment of Coronavirus Disease 2019 (COVID-19) Pneumonia

Jing Han
Ultrasound and Functional Center, Capital Medical University Youan Hospital
Xi Yang
Wuhan University of Science and Technology
Wei Xu
Department of Hepato-Pancreato-Biliary Surgery, Peking University Cancer Hospital institute
Ronghua Jin
Beijing You An Hospital, Capital Medical University
Weiyuan Liu
Capital Medical University Youan Hospital
Sha Meng
Capital Medical University Youan Hospital
Jin Li
Capital Medical University Youan Hospital
Ying Zheng
Beijing You An Hospital, Capital Medical University
Haowen Li
Ultrasonography, China Aerospace Science and Technology Corporation 731 Hospital
Fankun Meng (mengfankun@ccmu.edu.cn)
Ultrasound and Functional Diagnosis Center, Beijing You An Hospital, Capital Medical University

---

Research

Keywords: echocardiography, LUS, COVID-19, pulmonary arterial pressure

Posted Date: December 17th, 2020

DOI: https://doi.org/10.21203/rs.3.rs-129388/v1

Abstract

Purpose: To investigate relationships between echocardiography results and lung ultrasound score (LUS) in COVID-19 pneumonia patients, and the value of their combined application for evaluating COVID-19 pneumonia in diagnosis and treatment.

Methods: Hospitalized patients underwent lung ultrasound and echocardiography daily. Patients with tricuspid regurgitation within 3 days after admission were collected, and the correlations and differences between pulmonary artery pressures and LUS on days 3, 8, and 13 were compared. The inner diameter of the pulmonary artery root and the sizes of the atria and ventricles were observed.

Results: Pulmonary artery pressure within 3 days was positively correlated with LUS ($r = 0.448$, $p = 0.003$; $r = 0.738$, $p = 0.000$; $r = 0.325$, $p = 0.036$). On day 8 the values of both were higher than the corresponding values on days 3 and 13 ($p < 0.01$). On day 8 the positive rate for increased pulmonary artery pressure was 92.9%(39/42), the positive rate for increased LUS was 90.5%(38/42), and the combined positive rate for the two was 97.6%(41/42). On day 8 the inner diameters of the right atrium, right ventricle, and pulmonary artery differed significantly from the corresponding values on days 3 and 13 ($p < 0.05$).

Conclusions: Pulmonary arterial pressure is positively correlated with LUS. The two should be combined for more informative assessment of the status of recovery from COVID-19 pneumonia.

1. Introduction

On February 11, 2020, the disease caused by the severe acute respiratory syndrome coronavirus 2 which broke out in Wuhan, Hubei, China, was named coronavirus disease (COVID-19) by the World Health Organization (WHO)[1] With the rapid worldwide spread of COVID-19[2, 3], real-time reverse transcriptase polymerase chain reaction (RT-PCR) and high-resolution chest CT have been increasingly unable to meet the demands of diagnosis. Many countries and regions have gradually adopted ultrasonography as a basic examination method[4–6], especially Italy[7]. Improvements in the diagnostic value of ultrasound for COVID-19 pneumonia are required. To date there have been no reports describing the combined evaluation of changes in pulmonary arterial pressure and LUS when assessing the progression of COVID-19 pneumonia. The aim of the present study was to provide useful information in this regard for the diagnosis and treatment of COVID-19 pneumonia.

2. Materials And Methods

2.1. Study design

This work was supported by the ministry of science and technology of the people's republic of china (grant number 2020YFC0844900). The study was approved by the Ethics Committee of Beijing You An Hospital affiliated to the Capital Medical University ([2020]020). The consents were signed by all patients. In the current study 42 hospitalized COVID-19 pneumonia patients (the diagnosis was confirmed by RT-

PCR and CT) underwent dynamic echocardiographic and lung ultrasound observation. The combined use of the two modalities for evaluating lung lesions was assessed, and correlations between the two were calculated. All patients underwent dynamic lung ultrasound and echocardiographic observation upon admission to the hospital. The proportion with tricuspid valve regurgitation was increased by day 3 after admission, therefore we selected patients in whom tricuspid regurgitation was evident within 3 days as study subjects, and thereafter LUS and echocardiographic examinations were conducted daily. The mean hospital stay length was 15 days, Literature studies and our own previous research suggest that the length of time between the appearance of symptoms and the most severe stage of disease is approximately 10 days[8, 9], and that the length of time between the appearance of symptoms and hospitalization is approximately 2 days. Accordingly, days 3, 8, and 13 were selected for comparisons of LUS, pulmonary arterial pressures, and atrial and ventricular diameters. General symptoms including fever, cough, dyspnea, and history of underlying heart and lung disease were recorded.

2.2. Lung Ultrasound

Rouby[10] proposed to divide a unilateral lung into six zones for examination. With the anterior and posterior axillary lines as the boundaries, the lung was divided into three zones, namely anterior, lateral, and posterior (Fig. 1). Each zone was further divided into upper and lower parts. The worst sign of each zone in the examination was considered as the final judgment sign of the zone, and the results were recorded as the following four basic types (Fig. 2): type N: the ultrasonographic features were A line sign or ≤ 2 independent B lines, indicating good lung inflation; type B1: the ultrasonographic features were multiple B lines, with an interval of about 7 mm between the B lines (B7 lines); type B2: the ultrasonographic features were multiple B lines, and the interval between B lines was ≤ 3 mm, (B3 lines); and type C: the ultrasonographic features were hepatization or fragment sign of the lung tissue, with dynamic bronchial inflation sign, with or without a small amount of pleural effusion, indicating consolidation of the lung. The scoring of lung ultrasonography was based on the above four types as: N = 0, B1 = 1, B2 = 2, and C = 3. All patients underwent lung ultrasonographic examination, and the sum of scores of the 12 zones was recorded. All lung ultrasound images were performed by two experienced sonologists.

2.3. Echocardiography

All patients underwent echocardiographic examination daily. Routine parasternal, apical, and other cardiac section scans were performed. Spectral Doppler was used to record the peak velocity of tricuspid regurgitation. The transvalvular pressure difference was calculated. Right atrial pressure plus the transvalvular pressure difference was calculated as the right ventricular pressure. The right ventricular pressure is approximately equal to the pulmonary artery systolic pressure[11]. When the right atrium was mildly, moderately, or severely enlarged, the respective pressures therein were 5 mm Hg, 10 mm Hg, and 15 mm Hg, where 1 mm Hg = 0.133 kPa[12].

2.4. Statistical analysis

SPSS 26.0 statistical software was used for data analysis. Continuous data were expressed as means ± the standard deviation. Non-parametric tests were used to assess data that were not normally distributed. The Mann-Whitney U test was used for comparisons of two independent samples. The Kruskal-Wallis test was used for testing multiple independent samples. Pearson's correlational analysis was used to assess correlations between LUS and pulmonary artery pressures. $p < 0.05$ was deemed to indicate statistical significance.

3. Results

Forty-two patients were included in the cohort, 24 were males and 18 were females, with an average age of 47.8 ± 10.8 years. All patients had no history of heart disease or chronic respiratory disease. Their general characteristics, clinical features, and related medical history are shown in Table 1.

Table 1
General characteristics, symptoms, and relevant medical histories of the 42 patients.

Characteristics	Patients (42 cases)
Sex(M/F)	24(18)
Age(y)	47.8±10.8
Fever	36(85.7%)
Cough	34(80.9%)
Dyspnea	36(85.7%)
Myalgia	37(88.1%)
Diarrhea	16(38.1%)
Heart disease history	0
Chronic lung disease history	0

LUS and pulmonary arterial pressures in the 42 COVID-19 pneumonia patients on days 3, 8, and 13 differed significantly as the disease progressed. The two parameters were positively correlated within 3 days, and the correlation was higher in patients with more severe disease($r = 0.448$, $p = 0.003$; $r = 0.738$, $p = 0.000$; $r = 0.325$,$p = 0.036$), Fig. 1(a,b,c).

LUS directly reflected the degree of lung disease, whereas pulmonary arterial pressure was an indirect indicator of lung disease. Increased pulmonary arterial pressure can directly cause dilation of the pulmonary artery trunk with corresponding enlargement of the right ventricle and right atrium, and lead to exacerbation of tricuspid regurgitation. One such patient is shown in Fig. 2 (a,b,c), which illustrates the

relationships between pulmonary artery changes and tricuspid regurgitation on days 3, 8, and 13. There were significant differences in the LUS of the 42 COVID-19 pneumonia patients within 3 days. Differences in the inner diameters of the atria, ventricles, and pulmonary artery are shown in Tables 2 and 3.

Tables 2

The overall difference of LUS, pulmonary arterial pressure and atrial diameter in 42 patients on day 3, 8 and 13.

Category	On day 3	On day 8	On day 13	p
LUS	6.1 ± 1.0	11. 1 ± 1.4	7.6 ± 2.1	0.000
PAP(mm Hg)	26.5 ± 5.7	42.6 ± 8.2	31.3 ± 6.4	0.000
IDPAR(mm)	22.8 ± 1.6	24.6 ± 1.2	23.5 ± 1.4	0.000
Right atrium(mm)	33.4 ± 3.1	35.5 ± 2.5	33.3 ± 2.7	0.001
Right ventricle(mm)	36.7 ± 2.2	39.0 ± 2.2	36.0 ± 1.7	0.000
Left atrium(mm)	33.2 ± 2.9	33.2 ± 2.5	32.9 ± 2.5	0.759
Left ventricle(mm)	46.7 ± 2.6	46.9 ± 2.9	46.4 ± 3.4	0.881

Note -Pulmonary artery pressure: PAP; The inner diameter of the pulmonary artery root: IDPAR.

Tables 3

The differences of LUS, pulmonary artery pressure and atrial diameter in 42 patients on day 3, 8 and 13.

Day	LUS	PAP	IDPAR	right atrium	right ventricle	left atrium	Left ventricle
	Z	Z	Z	Z	Z	Z	Z
	P	P	p	p	p	p	p
3/8	-7.822	-7.494	-4.906	-2.936	-4.303	-0.144	-0.356
	0.000	0.000	0.000	0.003	0.000	0.885	0.722
3/13	-4.109	-3.360	-1.943	-0.383	-1.446	-0.680	-0.131
	0.000	0.001	0.052	0.702	0.148	0.497	0.896
8/13	-6.752	-6.350	-3.286	-3.611	-6.184	-0.587	-0.486
	0.000	0.000	0.001	0.000	0.000	0.577	0.627

Note -Pulmonary artery pressure: PAP; The inner diameter of the pulmonary artery root: IDPAR.

The 42 patients exhibited overall increases in both pulmonary arterial pressure and LUS on day 8, but at that timepoint there were 4 patients without significant increases in pulmonary arterial pressure and 3 without significant increases in LUS. Comparisons of computed tomography (CT) findings on day 8 revealed increased severity compared to day 3 in 6 patients, suggesting that these 6 patients were false negatives. Only one(1/7) patient there was no substantial difference between CT findings acquired on day 3 and those acquired on day 8, indicating a negative result in the case. There were 41□42 cases in which the two in combination were positive (Table 4).

Table 4
List of positive rates of LUS and pulmonary arterial pressure used alone or in combination.

	PAP	LUS	PAP□LUS
Positive	39(92.9%)	38(90.5%)	41(97.6%)
Negative	3(7.1%)	4(9.5%)	1(2.4%)
Total	42	42	42

Note -Positive: the pulmonary arterial pressure was greater than 30 mm Hg in three days; LUS greater than 1.

4. Discussion

In the present study LUS was positively correlated with pulmonary arterial pressure, and the correlation was stronger with increased disease severity. There are many reasons for increased pulmonary arterial pressure[12–14]. Patients with a history of underlying cardiopulmonary disease were excluded from the present study, and the observed changes in pulmonary arterial pressure were believed to be related to lung disease. During lung inflammation, inflammatory infiltration and alveolar exudate reduce the alveolar surface area available for diffusion, and diffusion time is prolonged. Hypoxic acidosis can cause swelling of pulmonary endothelial cells and pulmonary vasospasm, leading to pulmonary hypertension[12, 15].

The COVID-19 pneumonia outbreak and the 2003 severe acute respiratory syndrome outbreak were both caused by members of the coronavirus family. Angiotensin-converting enzyme-2 is a component of the renin-angiotensin system that protects blood vessels, and it is thought to be a functional receptor for coronaviruses on epithelial cells[16–18]. Another component of the renin-angiotensin system is angiotensin II, which causes alveolar epithelium inflammation and damage. The lung injury associated with coronavirus disease 2019 may be due to upregulation of angiotensin II and reduced angiotensin-converting enzyme-2 levels resulting in increased pulmonary vasoconstriction. The results of the present study suggest that these factors are associated with higher LUS and higher pulmonary arterial pressure.

Many studies[12–14] have investigated pulmonary arterial hypertension caused by pneumonia, but there are no reports of the use of pulmonary arterial pressure to predict LUS. In the present study LUS were dynamically evaluated, and echocardiography was performed simultaneously. LUS increased with

worsening condition, and decreased with improving condition. Echocardiography indicated that the amount of tricuspid regurgitation increased with worsening condition, and pulmonary arterial pressure and the inner diameters of the pulmonary artery, right ventricle, and right atrium also increased. All of these parameters exhibited statistically significant changes, and all of them decreased with improving condition (Tables 2 and 3). These results suggest that changes in LUS and pulmonary arterial pressure can reflect lung lesions.

Hemodynamic characteristics indicate that increased pulmonary arterial pressure leads to increased right ventricular ejection resistance, which results in increased inner diameter of the right atrium, right ventricle, and pulmonary artery. Dynamic echocardiography can be used to monitor changes in pulmonary arterial pressure and the size of each chamber of the heart in real time, such that disease development can be assessed in a timely manner. The positive correlation between pulmonary arterial pressure and LUS in the current study also indicates a tendency in LUS. There were no significant changes in left heart size during the entire course of disease, indicating a low probability of left heart involvement, which is consistent with previous studies.

In the present study the rate of positivity for increased pulmonary arterial pressure in the 42 patients on day 8 was 92.9%. 3(3/42) patient was stable, which may be related to compensation by pulmonary blood vessels[12, 15]. The rate of positivity for LUS on day 8 was 90.5%, and the scores of 4 patients did not increase with worsening condition. In conjunction with CT findings this suggests that the region of lesion exacerbation did not involve the edge of the lung, which is outside the detection range of ultrasound and is consistent with the principles of lung ultrasound. The positivity rate for the combination of the two was 97.6%, which constitutes an improvement in the accuracy of disease progression evaluation. To date there have been no comparable previous reports.

The current study had some limitations. Some patients could not undergo oxygen therapy due to dyspnea. Compared with patients who did not undergo oxygen therapy, the estimation of pulmonary arterial pressure may be biased. Because the frequency of CT examination was not as high as that of ultrasound, not all patients have corresponding CT data at the three study timepoints utilized, and there is a lack of a basis for comparison. Fortunately, corresponding CT data were available for 7 negative patients, which provided a strong basis for diagnosis.

5. Conclusions

In conclusion, in COVID-19 pneumonia patients pulmonary arterial pressure and LUS positively correlated. The combination of the two can improve the rate of diagnosis of lung disease progression, and has an important guiding role with respect to monitoring disease progression, as making treatment decisions.

Abbreviations

coronavirus disease 2019 COVID-19

lung ultrasound score LUS

Declarations

Ethical Approval and Consent to participate:

The study was approved by the Ethics Committee of Beijing You An Hospital affiliated to the Capital Medical University ([2020]020). The consents were signed by all patients.

Consent for publication:

Agree.

Availability of data and materials:

We confirm the data and material availability in our manuscript.

Competing interests:

Not applicable.

Funding:

This work was supported by the ministry of science and technology of the people’s republic of china (grant number 2020YFC0844900).

Authors' contributions:

JH: collect data, analyze and write article; XY: collect data, analyze and write article; WX: write article; RJ: write article; WL: collect data, statistical analysis; SM: statistical analysis; JL: collect data; YZ: collect data; HL: collect data; FM: analyze and write article.

Acknowledgements:

We would like to thank Editage (www.editage.cn) for English language editing.

References

1. WHO. WHO Director-General's remarks at the media briefing on 2019-nCoV on 11 Feb 2020. 2020.

2. Han Y, Yang H. The transmission and diagnosis of 2019 novel coronavirus infection disease (COVID-19): A Chinese perspective. J Med Virol. 2020; 92(6):639-644
3. China. NHCotPsRo. Update on pneumonia of novel coronavirus infections as of 24:00 on April 09, 2020.; 2020.
4. Soldati G, Smargiassi A, Inchingolo R, Buonsenso D, Perrone T, Briganti DF, et al. Proposal for International Standardization of the Use of Lung Ultrasound for Patients With COVID-19 A Simple, Quantitative, Reproducible Method. J Ultras Med. 2020; 39(7):1413-1419
5. Soldati G, Smargiassi A, Inchingolo R, Buonsenso D, Perrone T, Briganti DF, et al. Is There a Role for Lung Ultrasound During the COVID-19 Pandemic? J Ultras Med. 2020; 39(7):1459-1462
6. Kalafat E, Yaprak E, Cinar G, Varli B, Ozisik S, Uzun C, et al. Lung ultrasound and computed tomographic findings in pregnant woman with COVID-19. Ultrasound Obst Gyn. 2020; 55(6):835-837
7. Vetrugno L, Bove T, Orso D, Barbariol F, Bassi F, Boero E, et al. Our Italian experience using lung ultrasound for identification, grading and serial follow-up of severity of lung involvement for management of patients with COVID-19. Echocardiogr-J Card. 2020; 37: 625-627.
8. Zu ZY, Jiang MD, Xu PP, Chen W, Ni QQ, Lu GM, et al. Coronavirus Disease 2019 (COVID-19): A Perspective from China. Radiology. 2020; 296(2):E15-E25
9. Zhou S, Wang Y, Zhu T, Xia L. CT Features of Coronavirus Disease 2019 (COVID-19) Pneumonia in 62 Patients in Wuhan, China. AJR Am J Roentgenol. 2020; 214: 1287-1294.
10. Caltabeloti FP, Rouby JJ. Lung ultrasound: a useful tool in the weaning process? Rev Bras Ter Intensiva. 2016; 28: 5-7.
11. Galie N, Humbert M, Vachiery JL, Gibbs S, Lang I, Torbicki A, et al. [2015 ESC/ERS Guidelines for the diagnosis and treatment of pulmonary hypertension]. Kardiol Pol. 2016; 69(2):177
12. Galie N, Hoeper MM, Humbert M, Torbicki A, Vachiery JL, Barbera JA, et al. Guidelines for the diagnosis and treatment of pulmonary hypertension: the Task Force for the Diagnosis and Treatment of Pulmonary Hypertension of the European Society of Cardiology (ESC) and the European Respiratory Society (ERS), endorsed by the International Society of Heart and Lung Transplantation (ISHLT). Eur Heart J. 2009; 30: 2493-537.
13. Parasuraman S, Walker S, Loudon BL, Gollop ND, Wilson AM, Lowery C, et al. Assessment of pulmonary artery pressure by echocardiography-A comprehensive review. Int J Cardiol Heart Vasc. 2016; 12: 45-51.
14. Dunham-Snary KJ, Wu D, Sykes EA, Thakrar A, Parlow LRG, Mewburn JD, et al. Hypoxic Pulmonary Vasoconstriction: From Molecular Mechanisms to Medicine. Chest. 2017; 151: 181-92.
15. Tuder RM, Archer SL, Dorfmuller P, Erzurum SC, Guignabert C, Michelakis E, et al. Relevant issues in the pathology and pathobiology of pulmonary hypertension. J Am Coll Cardiol. 2013; 62: D4-12.
16. Li W, Moore MJ, Vasilieva N, Sui J, Wong SK, Berne MA, et al. Angiotensin-converting enzyme 2 is a functional receptor for the SARS coronavirus. Nature. 2003; 426: 450-454.

17. Jia H. Pulmonary Angiotensin-Converting Enzyme 2 (ACE2) and Inflammatory Lung Disease. Shock. 2016; 46: 239-248.
18. Zhang J, Dong J, Martin M, He M, Gongol B, Marin TL, et al. AMP-activated Protein Kinase Phosphorylation of Angiotensin-Converting Enzyme 2 in Endothelium Mitigates Pulmonary Hypertension. Am J Respir Crit Care Med. 2018; 198: 509-520.

Figures

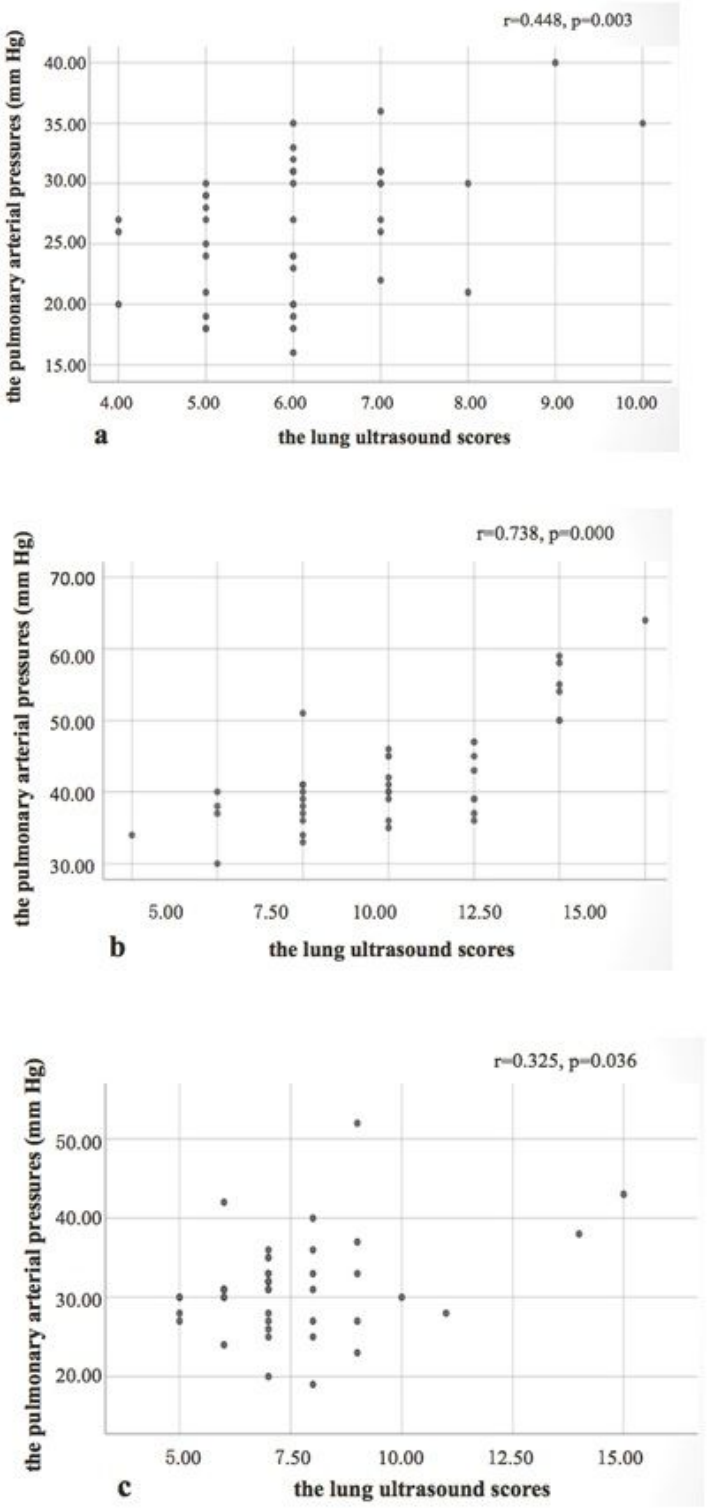

Figure 1

a, Correlation between LUS and pulmonary arterial pressure in 42 patients with covid-19 pneumonia on day 3. b, Correlation between LUS and pulmonary arterial pressure in 42 patients with covid-19 pneumonia on day 8. c, Correlation between LUS and pulmonary arterial pressure in 42 patients with covid-19 pneumonia on day 13.

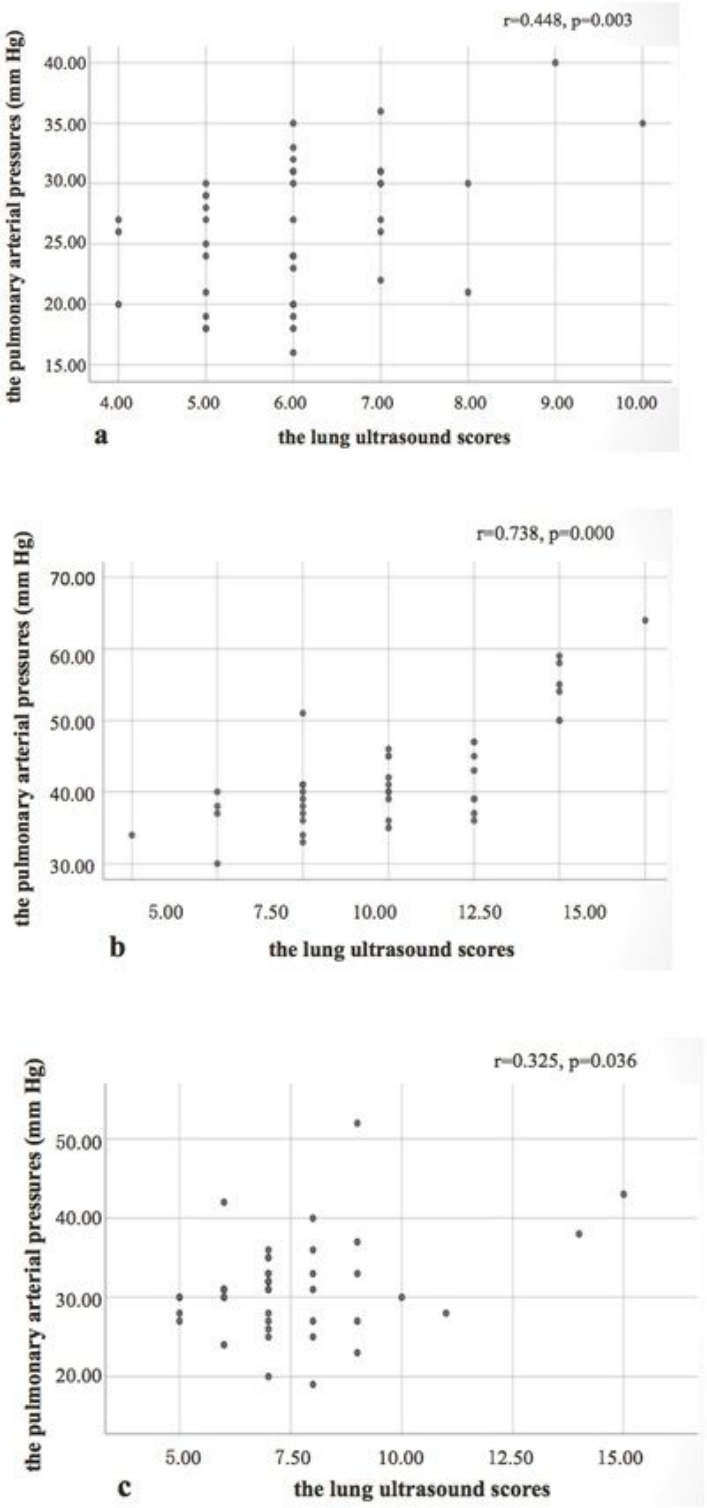

Figure 1

a, Correlation between LUS and pulmonary arterial pressure in 42 patients with covid-19 pneumonia on day 3. b, Correlation between LUS and pulmonary arterial pressure in 42 patients with covid-19 pneumonia on day 8. c, Correlation between LUS and pulmonary arterial pressure in 42 patients with covid-19 pneumonia on day 13.

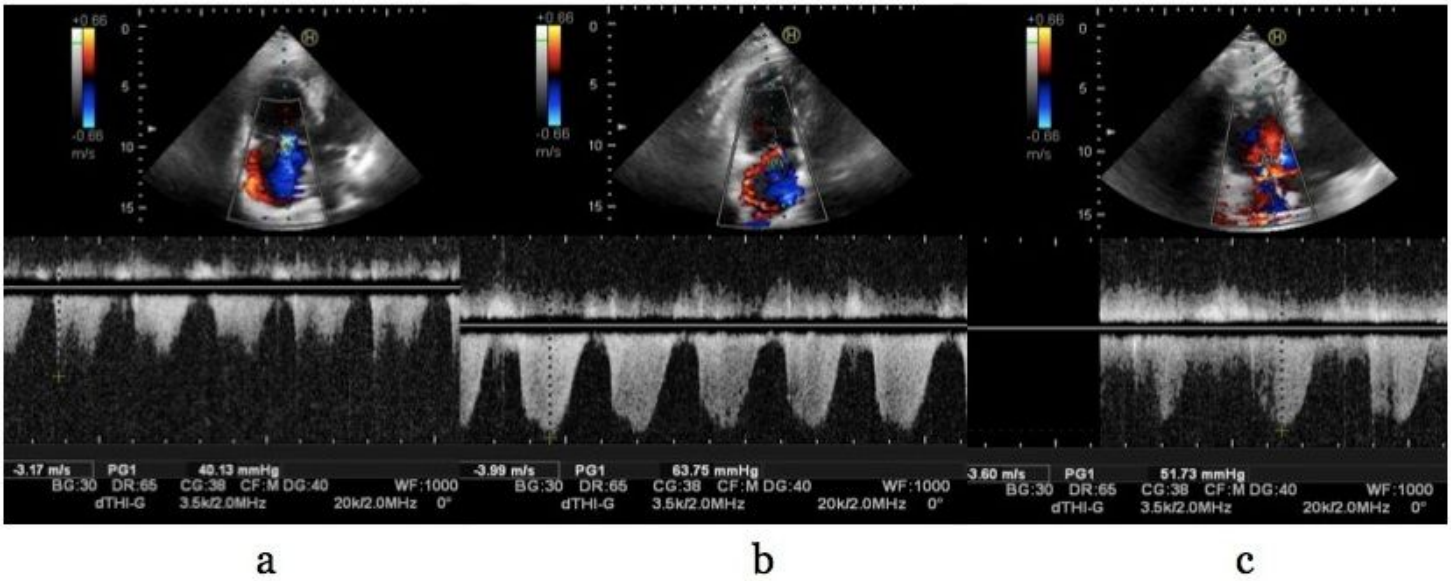

Figure 2

A 60-year-old male patient with pulmonary hypertension was presented with tricuspid regurgitation by color Doppler echocardiography, and pulmonary systolic pressure was estimated on days 3(a), 8(b), and 13 (c)by the gradient of tricuspid regurgitation pressure.

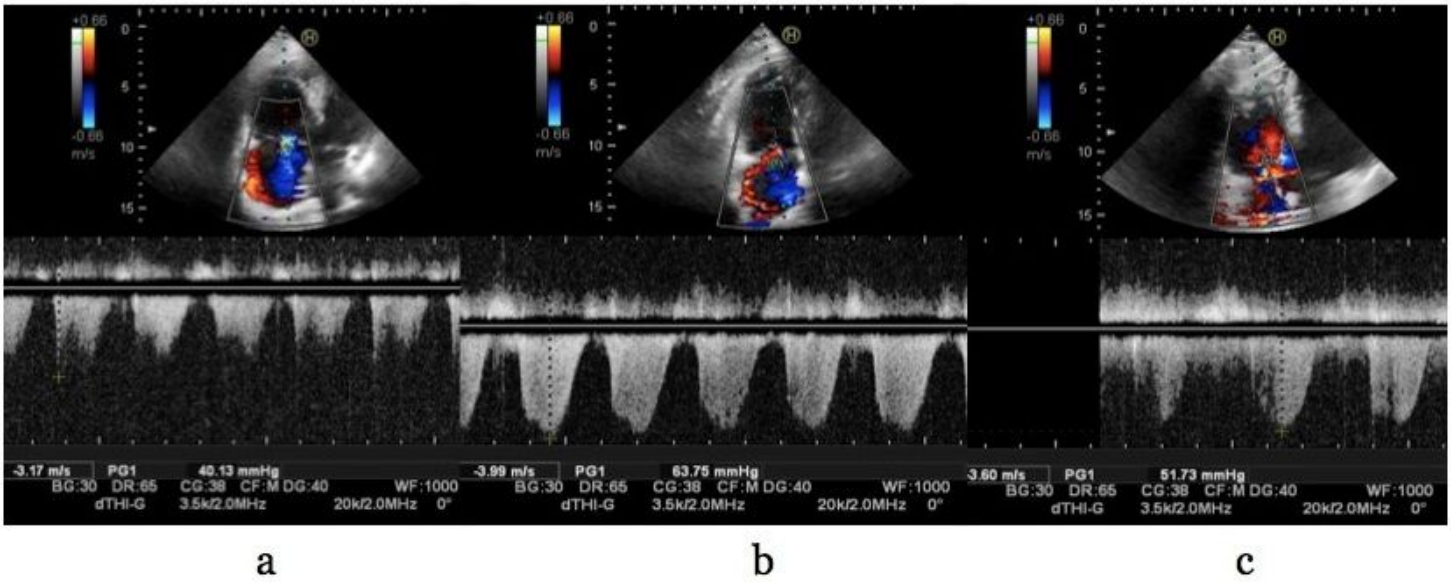

Figure 2

A 60-year-old male patient with pulmonary hypertension was presented with tricuspid regurgitation by color Doppler echocardiography, and pulmonary systolic pressure was estimated on days 3(a), 8(b), and 13 (c)by the gradient of tricuspid regurgitation pressure.

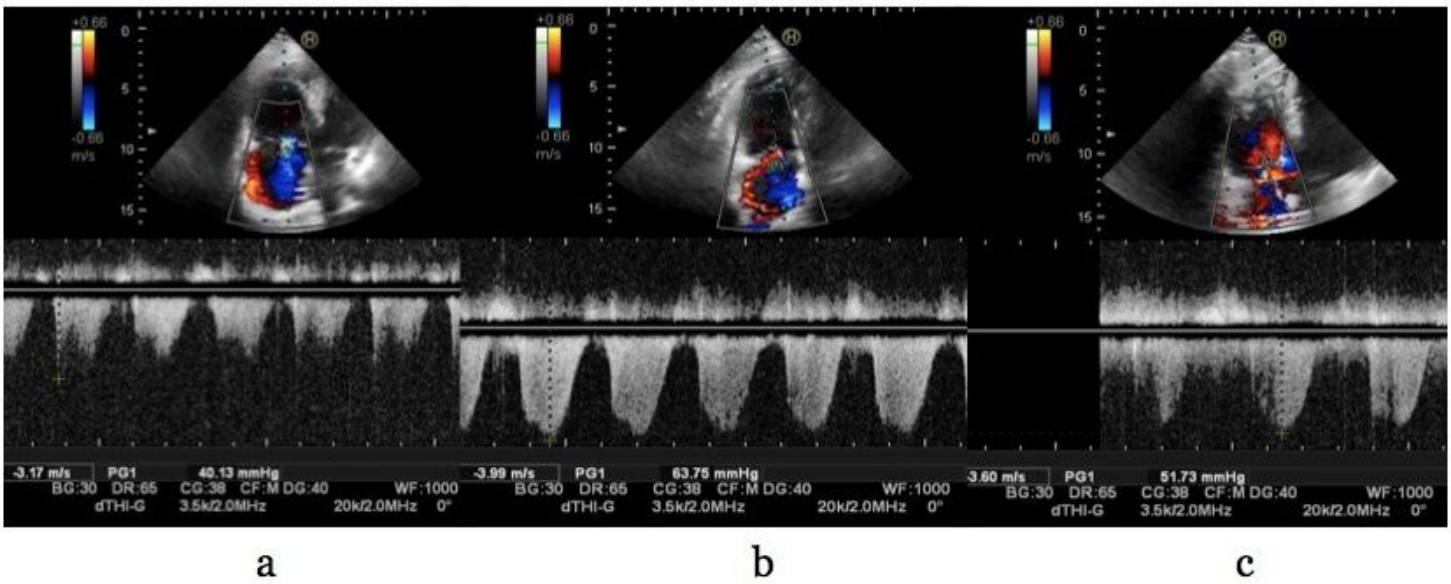

Figure 2

A 60-year-old male patient with pulmonary hypertension was presented with tricuspid regurgitation by color Doppler echocardiography, and pulmonary systolic pressure was estimated on days 3(a), 8(b), and 13 (c)by the gradient of tricuspid regurgitation pressure.