Comparison of the GlideScopeTM Visualization and Neck Flexion with Lateral Neck Pressure Nasogastric Tube Insertion techniques in Anaesthetized Patients: A Prospective Randomized Clinical Study

Pitchaporn Purngpipattrakul
Prince of Songkla university

Suttasinee Petsakul (p.suttasinee@gmail.com)
https://orcid.org/0000-0002-5478-6948

Asst. Prof. Sunisa Chatmonkolchart
Prince of Songkla University

Somrutai Boonchuduang
Prince of Songkla University

Kanjana Nuanjun
Prince of Songkla University

Research article

Keywords: Anesthesia, Nasogastric tube, GlideScope, Intubation

Posted Date: February 5th, 2020

DOI: https://doi.org/10.21203/rs.2.22366/v1

Abstract

Background

Nasogastric tube (NGT) insertion in anaesthetized and intubated patients can be challenging even for experienced anesthesiologists. Various techniques have been proposed to facilitate NGT insertion in these patients. This study aimed to compare the success rate and time required for NGT insertion between the GlideScope TM visualization and neck flexion with lateral neck pressure techniques.

Methods

This randomized clinical trial was performed at a teaching hospital on 86 adult patients undergoing abdominal surgery under relaxant general anaesthesia who required intraoperative NGT insertion. The patients were randomized into two groups, the GlideScope TM group (group G) and the neck flexion with lateral neck pressure group (group F). The success rate of first and second attempts, duration of insertion, and complications were recorded.

Results

The total success rate was 79.1% in Group G compared with 76.7% in Group F (P=1) The median time required for NGT insertion was significantly longer in Group G, for both first and second attempts (97 vs 42 seconds P<0.001) and (70 vs 48.5 seconds P=0.015), respectively. Complications were reported in 23 patients (53.5%) in group G and 13 patients (30.2%) in group F. Bleeding and kinking were the most common complications in both techniques.

Conclusions

Using GlideScope TM visualization to facilitate NGT insertion was comparable to neck flexion with lateral neck pressure technique in degree of success rate of insertion and complications were not statistically significant between groups, while neck flexion with lateral neck pressure technique was less time-consuming significantly both first and second attempts.

1. Background

Nasogastric tube (NGT) insertion is indicated during many surgical operations. As we have known that it is often difficult to place the NTG in anesthetized, paralyzed, and intubated patients [1–3]. The conventional method for NGT insertion is blinded technique with the patient's head in a neutral position, whereby success rates have been reported to vary from 40–58% [9–11]. Various techniques have been proposed to facilitate NGT insertion with variable success rate [4–15]. Study by Appukutty and Shroff [9] reported that flex neck with lateral neck pressure was the easy method with high success rate. Recently, A visualization-aided device was focused on the role of facilitating NGT insertion. Moharari and colleages [4] showed that the GlideScope™ could be a safe and effective device, successfully helping NGT insertion

in anesthetized and intubated patients by provides a direct view of larynx during insertion that could confirm NGT was placed in esophagus, not in trachea.

The objectives of this study were to compare and evaluate these two techniques between using GlideScope™ visualization versus Flex neck with lateral neck pressure technique with regards to success rate, time required and complications for NGT insertion in anesthetized and intubated patients.

2. Methods

After the approval from Office of Human Research Ethics Committee, faculty of medicine, Prince of Songkla University (REC 60-188-08-4), this study was conducted at the operating theatre of Songklanagarind Hospital, Thailand, from March 2018 to October 2018. Subjects were chosen from the elective schedule of the operations which required general anesthesia with oroendotracheal tube (ETT). The eligible patients were 18–65 years old, had ASA physical status 1 to 3. The exclusion criteria were patients with deformities of chin, pharynx and/or larynx, base of skull lesion, neck mass, upper airway obstruction, abnormal prothrombin time, activated partial thromboplastin time and platelet disorder, esophageal stenosis or varices, history of radiotherapy in the head and neck region, unstable cervical spine, head injury, limit neck motion and previous esophageal surgery.

Written informed consent was obtained from each patient after discussion of the study procedure and expected complications. The patients were then randomized into 2 groups with 43 patients in each group. Group G (GlideScope™ visualization), Group F (neck flexion with lateral pressure) using computerized random allocation soft-ware with opaque envelopes. Standard monitoring with continuous electrocardiography, non-invasive blood pressure monitoring, pulse oximetry and capnograph were used for all patients. After preoxygenation, nonrapid sequence of induction and intubation for anesthesia consists of administration of an induction agent, proof of the ability to mask ventilate, administration of a neuromuscular blocking agent (NMBA), and endotracheal intubation once paralysis is achieved. Intubation was performed with a cuffed, polyvinyl chloride endotracheal tube (7–8 mm internal diameter as per patient's size). The ETT cuff was inflated and the pressure kept between 15 and 25 cm H_2O using a pressure gauge manometer. Anesthesia was maintained by sevoflurane/desflurane at an end-tidal concentration of one minimum alveolar anesthetic concentration. All patients were blinded, but we could not blind accessors and investigators. Three attending anesthesiologists was responsible for all NGT placements with the aim to reduce skill bias (our attendants had practiced the two methods of NGT insertion for two weeks (5 patients in each group) before the study began. And there are no differences of success rate, time required for NGT insertion, and complication among each anesthesiologists.

In all patient groups, a 14 French gauge (FG), 125 cm NGT with lead was used.

The length of NGT necessary to reach the stomach was assessed before insertion and measured by placing the tip of the NGT on the patient’s xiphoid process and extending it to the tip of his/her nose and over the earlobe. Immediately before insertion, KY jelly was applied. In the neck flexion with lateral neck

pressure group (Group F), a lubricated NGT was inserted through the selected nostril to a depth of 10 cm. Lateral neck pressure was applied at the same side as that of the selected nostril with the neck flexed and the NGT was advanced. In the GlideScope™ visualization group, the blade of the GlideScope™ visualization was inserted into the patients' mouths, the tracheal tube and the tongue were lifted to provide the physician with the best view of the pharyngeal area.

In case of failure of insertion in the first attempt second attempt was made by that same technique.

If both attempts were unsuccessful, then the technique was considered as a 'procedure failure'. The NGT was reinserted switching over these two techniques. If that too failed the NGT was introduced under direct vision by Macintosh laryngoscope and was manipulated using Magill's forceps. (refer to Fig. 1 for the study flow chart).

Position was confirmed by epigastric auscultation of a gargling sound when 10 mL of air was insufflated via the NGT and no coiled/kinked NGT in the oral cavity.

The time taken for insertion was calculated from the initiation of NGT insertion through nostril until confirmation of its successful placement into the stomach. A general anesthesia assistant measured the time taken using stop-watch.

The occurrence of complications such as bleeding, kinking and coiling during the procedure was noted. The rate of successful NGT insertion and the duration needed for successful insertion on the first and second attempt was compared between the 2 groups.

The primary outcome of this study was the overall success rate which was defined as succeeded within two attempts. Secondary outcomes were failure rate, and the duration of insertion time in both groups. The complications of NGT passage, such as bleeding, kinking and coiling.

The sample size was calculated by two independent proportions, two-tailed test, formula; based on previous data [4, 12]. Those authors reported that first-attempt success rate was 85% in GlideScope™ visualization group and 56.7% in head flexion and lateral neck pressure group. Alpha error was 0.05, whilst ß error was 0.2. The calculated sample size per group was 38, after adding 10% dropout the final sample size was 43 subjects per group. Performed by R language, version 3.3.3 Categorical variables were compared by Chi-square or Fisher's exact test, whilst continuous variables were assessed by Shaparo-Wilk normality test before compared by t-test or Wilcoxon rank-sum test. The p-value of less than 0.05 was considered statistically significant.

3. Results

A total of 108 patients were assessed for eligibility into the study, 92 patients were enrolled into the study. Two patients in each group were excluded from this study on account of no requirement for NGT insertion, A patient in GlideScope™ visualization group required orogastric tube and one patient in Flex

neck with lateral neck pressure group need to control blood pressure. Hence, data from 86 patients were available for analysis. (Fig. 2)

There were no statistically significant differences of demographic profile such as age, sex, height, weight, BMI, ASA physical status, Mallampati grade and size of endotracheal tube. The demographic data was comparable between both groups. (Table 1)

Table 1
Patients characteristics

	Total (n = 86)	**Group G (n = 43)**	**Group F (n = 43)**	**p-value**
Gender				1
Male	47(54.7)	19 (44.2%)	20 (46.5%)	
Female	39(45.3)	24 (55.8%)	23 (53.5%)	
Age[b] (years)	56 (43,64.8)	52 (40,63)	58 (49,66)	0.442
Body weight[b] (kg)	60 (52.2,69)	61 (53.5,73)	58 (51.5,68)	0.199
Height[a] (cm)	160.5 ± 8.9	160.6 ± 8	160.3 ± 9.8	0.857
BMI[b] (kg/m^2)	23.4(20.6,27.4)	25.3(21.4,27.9)	22.4(20.4,25.5)	0.054
ASA classification				0.792
2 3 Mallampati I II III	66 (77.6%) 18 (21.2%) 29 (33.7%) 47 (54.7%) 10 (11.6%)	33 (76.7%) 10 (23.3%) 14 (32.6%) 24 (55.8%) 5 (11.6%)	33 (78.6%) 8 (19%) 15 (34.9%) 23 (53.5%) 5 (11.6%)	0.973
ETT diameter				0.374
7	5 (5.8%)	1 (2.3%)	4 (9.3%)	
7.5	42 (48.8%)	23 53.5%)	19 (44.2%)	
8	39 (45.3%)	19 (44.2%)	20 (46.5%)	

Data are presented as frequency (percentage) format unless stated otherwise.

[a] Data are presented as mean ± Standard Deviation

[b] Data are presented as median and interquartile range

Group G - GlideScope™ Visualization; Group F- neck flexion with lateral pressure; ASA- American Society of Anesthesiologists; BMI – Body mass index; ETT – endotracheal tube

In group G, a successful NGT insertion was achieved in 34/43 patients (79.1%), with 28/43 patients (65.1%) tube being inserted in the first attempt and 6/43 (14%) tubes in the second attempt. In group F, the NGT was placed successfully in 33/43 (76.7%, P = 1 compared with group G), with 26/43 (60.5%) tube being inserted in the first attempt and 7/43 (16.3%) tubes in the second attempt. (Table 2)

Table 2

Comparisons of outcomes between GlideScope™ Visualization group and neck flexion with lateral pressure group

Parameter	**Total (n = 86)**	**Group G (n = 43)**	**Group F (n = 43)**	**p-value**
Attempts				
1st	54 (62.8%)	28 (65.1%)	26 (60.5%)	0.823
2nd Switch-over Magill forceps Failure	13 (15.1%) 12 (14%) 1 (1.2%) 6 (7%)	6 (14%) 6 (14%) 0 (0%) 3 (7%)	7 (16.3%) 6 (14%) 1 (2.3%) 3 (7%)	1 1 1 1
Success rate overall success [a] unsuccessful	67 (77.9%) 19 (22.1%)	34 (79.1%) 9 (20.9%)	33 (76.7%) 10 (23.3%)	1 1
[a] Overall success rate defined as succeeded within two attempts				
Group G – GlideScope™ Visualization; Group F- neck flexion with lateral pressure				

Table 3

Duration for nasogastric tube insertion and complications

Parameter	**Group G (n = 43)**	**Group F (n = 43)**	**p-value**
Duration for insertion (s)			
1st attempt [b] 2nd attempt [b]	97 (62.5,140) 70 (55,120)	42 (32.8,55) 48.5 (43.8,58)	< 0.001 0.015
Complication Coiling Kinking Bleeding	2 (4.7%) 10 (23.2%) 11 (25.6%)	1 (2.3%) 5 (11.6%) 7 (16.3%)	1 0.256 0.426
[b] Data are presented as median and interquartile range			
Group G - GlideScope™ Visualization; Group F- neck flexion with lateral pressure			

There were 3 patients in each group that NGT were failed inserted even implemented the switch over and MacIntosh laryngoscope with Magill forceps techniques, finally 5 of them subsequently succeed the NGT insertion by blind technique and 1 patient was cancelled NGT insertion because of pharyngeal bleeding.

The median time required for NGT insertion was significantly longer in Group G, for both first and second attempts (97 vs. 42 seconds $P < 0.001$) and (70 vs. 48.5 seconds $P = 0.015$), respectively.

A total of 33 of the 86 study patients developed complications and there were no statistically significant differences between both groups. Pharyngeal bleeding was the most common complication observed in both group, 11 patients (25.6%) in Group G and 7 patients (16.3%) in Group F ($P = 0.426$).

The second most common complication was kinking of the NGT which occurred in 10 patients (23.2%) in Group G and 5 patients (11.6%) in Group F ($P = 0.256$). Coiling was seen in 2 patients (4.7%) in Group G and 1 patient (2.3%) in Group F ($P = 1$). There were no instances of inadvertent placement of the NGT into the trachea in both groups.

4. Discussion

Our study showed that there was no clinically significance difference of the success rate in GlideScope™ visualization group compared to head flexion and lateral neck pressure group in the patients with normal airway anatomy

The total success rate was 79.1% in Group G and 76.7% in Group F. As a result, we concluded that using GlideScope™ to facilitate NGT insertion was comparable to neck flexion with lateral neck pressure technique in degree of success rate of insertion, nonetheless a larger sample size would be required in further studies.

Our first attempt success rate of NTG insertion in the GlideScope™ group was lower than the study by Moharari and colleagues [4] which achieved success rate of 85%, the reason may be due to different methodologies. In the study by Moharari and colleagues [4], they deflated the cuff of endotracheal tube that may transmit pressure posteriorly toward to the esophageal before NGT insertion that might release the pressure of esophagus, more facilitating the NGT insertion, increasing the success rate but may lead to potential risk of aspiration when the endotracheal tube cuff is deflated.

The time required for NGT insertion was significantly longer in Group G, the operator noticed more time had spent to inserted the GlideScope™ blade into the patient’s mouth with preexisting ETT. It should be noted that the duration of NGT insertion in our study may be prolonged because of three difference anesthetists performing the NGT insertion and anesthetists in the operating room were aware of the interventions assigned for them, there might be potential of skill bias also investigator bias existed in this study.

Appukutty and Shroff discussed about neck flexion and lateral neck pressure technique help keeping the NGT along the posterolateral of pharyngeal wall, thus facilitate the NGT pass into esophagus and reported that was an easiest technique with a high success rate [9]. Although this study supported that neck flexion with lateral pressure technique is more simple, faster and lesser complications than using GlideScope™ for NGT insertion in anesthetized and intubated patients, but this technique should be avoided in patients those with cervical instability, limited range of neck motion, patient with previous cervical spine surgeries or obese patients those has very thick chest wall so limit neck flexion. In such cases using GlideScope™ facilitate NGT insertion maybe more appropriate. This would remain a future scope.

Our results obviously observed that the most common adverse event is a bleeding in both techniques. We proposed a possible explanation that because of prolonged time taken for the NGT insertion due to the difficulties may elevated risks of mucosal injury. However, they were minimal bleeding, and hemodynamic of the patients were stable and spontaneously resolved. There were no instances of inadvertent placement of the NGT into the trachea or other life-threatening complications seen in our study.

In conclusions, using GlideScope™ to facilitate the NGT insertion in anesthetized and intubated patients can comparable to neck flexion with lateral neck pressure technique in degree of success rate of insertion and acceptable adverse events. Whilst neck flexion with lateral neck pressure technique was less time-consuming, however we should consider about the patient's conditions individually then choose a proper technique, in future a larger sample size would be required.

Abbreviations

NGT = Nasogastric tube; group G = GlideScope™ group; group F = lateral neck pressure group; NMBA = neuromuscular blocking agent; ASA = American Society of Anesthesiologists; ETT = endotracheal tube; FG = French gauge; BMI = body mass index;

Declarations

Ethics approval and consent to participate: We further confirm that any aspect of the work covered in this manuscript that has involved human patients has been conducted with the ethical approval of all

relevant bodies and that such approvals are acknowledged within the manuscript and all participants

informed in written consent.

Consent for publication: Not applicable

Availability of data and material: Not applicable

Competing interests: no competing interests

Funding: none

Authors contributions:

PP - Conception of study, literature review, study design, study execution, data collection, data analysis, data interpretation, writing of study.

SP - Literature review, study design, data interpretation, writing of study.

SC - Data interpretation, writing of study.

KN - NGT placement

SB - NGT placement

Acknowledgements: Not applicable

References

1. Ozer S, Benumof JL. Oro-and nasogastric tube passage in in-tubated patients: Fiberoptic description of where they go at the laryngeal level and how to make them enter the esophagus. Anesthesiology 1999;91:137-43. [PubMed].
2. Bautista EM. Complications of nasogastric tube insertion. Chest 1988; 93(5): 1119b–120.
3. Rai MR, Dering A, Verghese C. The GlideScope® system: a clinical assessment of performance. Anaes thesia 2005;60:60-4.
4. Moharari RS, Fallah AH, Khajavi MR, Khashayar P, Lakeh MM, Najaf A. The GlideScope facilitates nasogastric tube insertion: a randomized clinical trial. Anesth Analg 2010;110(1):115–8.
5. Roberts JR, Halstead J. Passage of a nasogastric tube in an intubated patient facilitated by a video larygoscope. J Emerg Med. 2011;40:330.
6. Parris WC. Reverse sellick manoeuvre. Anesth Analg. 1989;68:423.
7. Chun DH, Kim NY, Shin YS, Kim SH. A randomized, clinical trial of frozen versus standard nasogastric tube placement. World journal of surgery. 2009 Sep 1;33(9):1789-92.
8. Illias AM, Hui YL, Lin CC, Chang CJ, Yua HP. A comparison of nasogastric tube insertion techniques without using other instruments in anesthetized and intubated patients. Annals of Saudi medicine. 2013 Sep 1;33(5):476.
9. Appukutty J, Shroff PP. Nasogastric tube insertion using different techniques in anesthetized patients: a prospective, randomized study. Anesthesia & Analgesia. 2009 Sep 1;109(3):832-5.
10. Mahajan R, Gupta R, Sharma A. Role of neck flexion in facil-itating nasogastric tube insertion. Anesthesiology 2005;103:446-7.
11. Bong CL, Macachor JD, Hwang NC. Insertion of the naso-gastric tube made easy. Anesthesiology: The Journal of the American Society of Anesthesiologists. 2004 Jul 1;101(1):266-.
12. Kirtania J, Ghose T, Garai D, Ray S. Esophageal guidewire-assisted nasogastric tube insertion in anesthetized and intubated patients: a prospective random-ized controlled study. Anesth Analg

2012;114:343–8
13. Mandal MC, Dolai S, Ghosh S, Mistri PK, Roy R, Basu SR, Das S. Comparison of four techniques of nasogastric tube insertion in anaesthetised, intubated patients: A randomized controlled trial. Indian J Anaesth 2014;58:714-8.
14. Mandal M, Karmakar A, Basu SR. Nasogastric tube insertion in anaesthetised, intubated adult patients: A comparison between three techniques. Indian journal of anaesthesia. 2018 Aug;62(8):609.
15. Sheetalshah, Bhavinchudasama, Krupa P. Comparison of Three Techniques of Nasogastric Tube Insertion in Anaesthetised, Intubated Patients. IOSRJournals 2016;12:126-129.

Figures

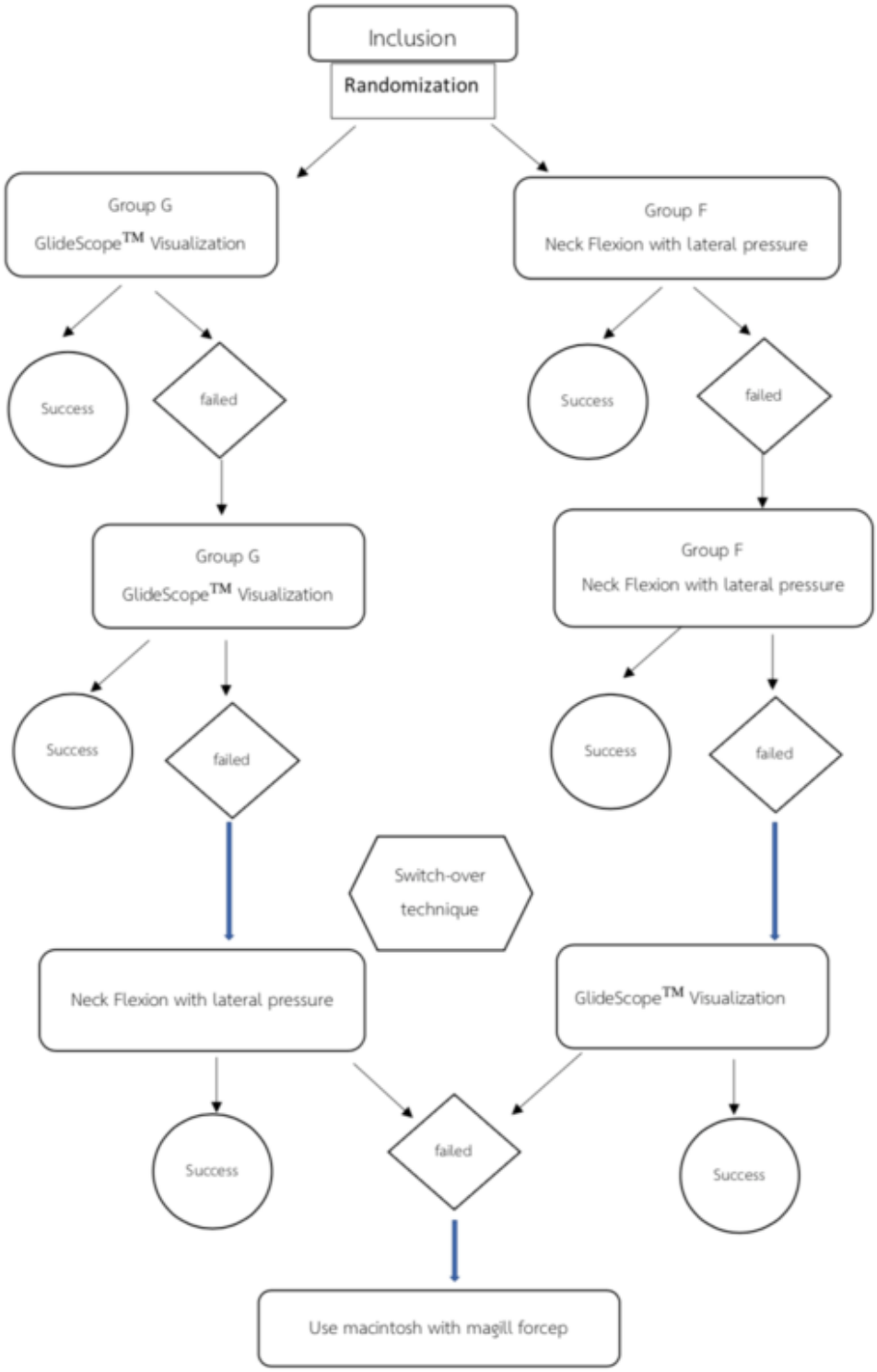

Figure 1

Study flow chart

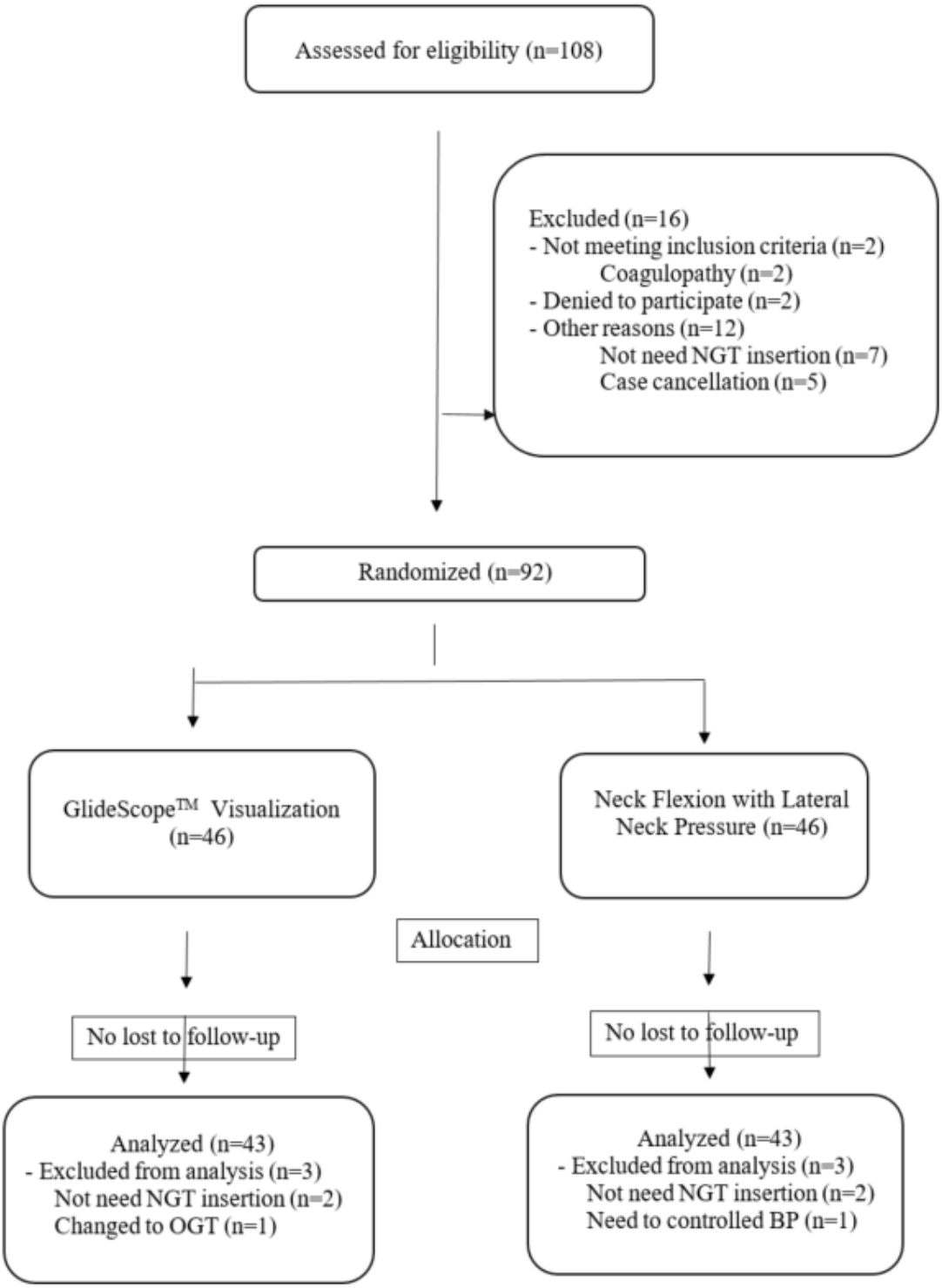

Figure 2

CONSORT flow diagram

Supplementary Files

This is a list of supplementary files associated with this preprint. Click to download.

- CONSORT2010Checklist.doc