Routine colonoscopy may not be needed for uncomplicated acute right colonic diverticulitis

Kil-yong Lee
Uijeongbu Saint Mary's Hospital https://orcid.org/0000-0002-7949-0166

Jaeim Lee (lji96@catholic.ac.kr)
https://orcid.org/0000-0002-4074-3904

Youn Young Park
Uijeongbu Saint Mary's Hospital

Seong Taek Oh
Uijeongbu Saint Mary's Hospital

Research article

Keywords: Diverticulitis, Acute diverticulitis, Colonic evaluation, Endoscopy, Colonoscopy, Colonic neoplasia

Posted Date: February 3rd, 2020

DOI: https://doi.org/10.21203/rs.2.22488/v1

Version of Record: A version of this preprint was published on February 27th, 2021. See the published version at https://doi.org/10.1186/s12876-021-01672-1.

Abstract

BACKGROUND Routine colonoscopy is recommended to determine the coexistence of colon cancer after medical treatment for colon diverticulitis. However, in the case of uncomplicated diverticulitis diagnosed by computed tomography imaging, the clinical relevance of routine follow-up colonoscopy has recently been debated. Yet, the role of follow-up colonoscopy for right colon diverticulitis, which tends to develop at a younger age than left colon diverticulitis, has not been specifically evaluated. Therefore, or aim in this study was to evaluate the incidence of colon cancer, detected by routine colonoscopy, after conservative management of acute uncomplicated right colon diverticulitis. METHODS Included were patients with uncomplicated right colon diverticulitis (modified Hinchey stage Ia) diagnosed by computed tomography imaging, between 2011 and 2017, and who underwent follow-up colonoscopy surveillance after treatment. The primary outcome was the incidence of colon cancer, with the detection rate of adenoma being the secondary outcome. Information for analysis was retrieved, retrospectively, from patients' medical records. RESULTS The study group included 330 consecutive patients, with a mean age of 41.9 years, and 51.9% being men. For the primary outcome, the rate of colon cancer on follow-up colonoscopy was 0.3% (1/330 cases). The rate of adenoma detection was 20.3% (67/330 cases), with advanced adenoma identified in 9 of these cases (13.4%). CONCLUSION In patients with acute uncomplicated right colonic diverticulitis, routine colonoscopy after conservative treatment may not be necessary.

Introduction

The prevalence of diverticular disease has increased, both the in East and West, due to a lack of dietary fiber intake [1]. In contrast to complicated diverticulitis, which requires surgical treatment, uncomplicated acute diverticulitis can improve with conservative management, with colonoscopy recommended to identify accompanying disease, such as cancer [2]. Yet, a review article reported a low rate of cancer diagnosis during colonoscopy surveillance in patients treated for uncomplicated diverticulitis, with 1 case of cancer among the 67 cases included in the analysis [3]. However, these statistics are based solely on cases with left colon diverticulitis. As such, the likelihood of cancer among patients treated with uncomplicated right colon diverticulitis is unknown. This knowledge, however, would be important as right-sided colon diverticulitis tends to occur at a younger age than left-sided colon diverticulitis, with a low stage Hinchey classification being common on computed tomography (CT) [4]. Generally, the American Cancer Society guideline recommends colonoscopy surveillance to begin at the age of 45 years [5]. Moreover, the onset of colon cancer at a younger age is more likely to occur in the left than right colon [6]. Considering these points, it is unclear how routine colonoscopy evaluation after right colon diverticulitis could be of clinical benefit with regard to diagnostic performance and economic burden.

Of the literature published on the effects of routine colonoscopy after the treatment of uncomplicated colon diverticulitis, few articles have exclusively included patients with right colon diverticulitis. Thus, the aim of our study was to evaluate the incidence of colon cancer, by routine colonoscopy, after conservative management of acute uncomplicated right colon diverticulitis.

Materials And Methods

We retrospectively reviewed the electronic medical records of patients diagnosed with acute right-sided colon diverticulitis, between January 2011 and December 2017, at our hospital. Patients with acute uncomplicated diverticulitis (Stage Ia, based on the modified Hinchey classification), confirmed by CT, were included. The modified Hinchey classification is a more detailed classification derived from the Hinchey classification, and consists of stages 0-IV, based on CT imaging [7]. Follow-up colonoscopy was performed after improvement in the signs of inflammation corresponding to acute diverticulitis, with the consent of the patient. Exclusion criteria were as follow: cancer stage other than Ia; accompanying colon cancer; patients who underwent emergency surgery; and patients in whom follow-up colonoscopy was not performed or was not consented to. The reasons why a patient did not undergo colonoscopy was investigated based on a previous paper [8].

The following colonoscopy findings were documented: hyperplastic polyp, adenoma (including advanced adenoma), and carcinoma. Patients with polyps detected in the right colon were the focus of our analysis. The primary outcome was the detection rate of colon cancer, confirmed by pathological diagnosis, on follow-up colonoscopy. The secondary outcome was the detection rate of hyperplastic polyp and adenoma on follow-up colonoscopy.

Statistical analysis

Categorical variables were reported as a count (and associated percentage, %), with continuous variables reported as the median and interquartile range (IQR). To compare the group with and without colonoscopy, the chi-squared or Fisher exact test was used for categorical variables, as appropriate. As such, between-group comparisons of continuous variables were evaluated using the Mann-Whitney test.

All analyses were performed using SPSS (version 21, IBM, NY, USA).

Results

A total of 668 consecutive patients were diagnosed with acute right colon diverticulitis, by CT, over the period of observation of the study. From these, the following patients were excluded from the analysis: 51 who had a modified Hinchey classification other than Ia; 1 with sigmoid colon cancer simultaneously diagnosed on CT imaging; and 1 who underwent emergency surgery because symptoms did not improve. Of the remaining 615 patients, follow-up colonoscopy was performed in 330 (Fig. 1). Follow-up colonoscopy was performed at a median of 32 days (IQR, 25–42 days) after recovery from acute diverticulitis.

Clinical characteristics of patients included in the analysis are reported in Table 1, with salient characteristics as follows: median age, 40 (IQR, 33–49) years; male, 59.7%; and predominant involvement of the cecum (48.3%) and ascending colon (49.9%). With regard to clinical factors, only the length of hospital stay was significantly different between the two groups.

Table 1
Clinical characteristics of patients with acute uncomplicated diverticulitis

Variables	Colonoscopy (n = 330)	No Colonoscopy (n = 285)	p-value
Age (years)	40 (34–50)	40 (31-47.8)	0.136*
Sex Male Female	195 (59.1%) 135 (40.9%)	172 (60.4%) 113 (45.6%)	0.751¶
Height	167.5 (160.0-173.5)	168.0 (160.1–173)	0.993*
BMI (kg/m^2)	23.8 (21.7–26.3)	23.4 (21.6–25.9)	0.139*
Duration of hospital stay (days)	4 (4–5)	4 (3–5)	0.019*
Social history Smoking Alcohol	142 (43%)† 137 (42.7%)‡	137 (48.1%) 109 (40.1%)§	0.223¶ 0.521¶
Past medical history Hypertension Diabetes	50 (15.2%) 14 (4.2%)	30 (10.5%) 12 (4.2%)	0.089¶ 0.984¶
Location of the lesion Cecum Ascending Hepatic flexure Transverse	154 (46.7%) 171 (51.8%) 3 (0.9%) 2 (0.6%)	143 (50.2%) 136 (47.7%) 3 (1.1%) 3 (1.1%)	0.587¶
White blood cell count (10^3/μL)	11.1 (9.2–12.9)	11.5 (9.7–14.0)	0.071*
C-reactive protein (mg/dl)	3.5 (1.6–6.5)	3.8 (1.7-7.0)	0.337*
IQR, interquartile range; BMI, body mass index.			
Continuous variables are reported as the median (and IQR)			
Categorical variables are reported as a count (and percentage, %)			
‡ Missing data: n = 1, ‡ Missing data: n = 9, §Missing data: n = 13			
*Mann-Whitney test, **Fisher exact test, ¶chi-squared test			

On follow-up colonoscopy, hyperplastic polyps were identified in 30 patients (9.1%) and adenomas in 67 patients (20.3%), with evidence of high-grade dysplasia in 2 of these cases. An advanced adenoma, including colon cancer, was observed in 9 patients (2.7%), one of whom was diagnosed with ascending colon cancer. Polyps were found in the right colon in 46 of 87 patients with colon polyps (Table 2). Additionally, on biopsy, chronic inflammation of the right colon was confirmed in 13 patients: erythematous mucosal change (n = 5) or ulceration (n = 8). There was no incidence of inflammatory bowel disease combined with diverticulosis.

Table 2
Results of colonoscopy examination

Variables	Value
Hyperplastic polyp	30 (9.1%)
Adenoma Low grade dysplasia High grade dysplasia	67 (20.3%) 2 (0.6%)
Adenocarcinoma	1 (0.6%)
Advanced adenoma	9 (2.7%)
Right-sided polyp†	46 (52.9%) †
† number of patients in whom polyps were detected in the right colon (total number of patients, 87)	

Ascending colon cancer was confirmed by pathological examination in one male patient in his late 40 s, who sought consultation at our emergency department owing to a 2-day history of abdominal pain. He was admitted and treated with a 5-day course of intravenous antibiotics. CT examination, performed by an expert radiologist, revealed a segmented cecum and thickening of the wall of the ascending colon, with perilesional fat infiltration. Follow-up colonoscopy was performed 6 weeks after imaging, with a diagnosis of ascending colon cancer confirmed.

The reasons for lack of follow-up colonoscopy are summarized in Table 3, and summarized as follows: 22 patients (7.8%) had a history of a recent prior colonoscopy; 15 (5.3%) underwent follow-up colonoscopy at another hospital; and 10 (3.5%) were followed up using colon barium study at the patient's request.

Table 3
Reasons for patients to not undergo colonoscopy

Reasons	Number (%)
Prior colonoscopy ≤ 12 months prior	15 (5.2%)
12 < Prior colonoscopy ≤ 24 months	3 (1.1%)
24 < Prior colonoscopy ≤ 36 months	1 (0.4%)
36 < Prior colonoscopy ≤ 60 months	2 (0.7%)
60 < Prior colonoscopy ≤ 120 months	1 (0.4%)
Patient declined	12 (4.2%)
Lost to follow-up	85 (29.8%)
Patient frailty	2 (0.7%)
No recommendation by treating team	12 (4.2%)
Not scheduled, reason unknown	25 (8.8%)
Colonoscopy scheduled, but not yet performed	100 (35.1%)
Colonoscopy performed at another hospital	15 (5.3%)
Double-contrast barium enema only performed	10 (3.5%)
Death prior to colonoscopy	1 (0.4%)

Discussion

The incidence rate of colon cancer detected by routine colonoscopy performed after conservative treatment of right colon acute uncomplicated diverticulitis was low at 0.3% (1/330 cases). The detection rate of adenoma in the whole colon was higher at 20.3%, with a detection of polyps in the right colon of 52.8%.

Clinically, the features of right colon diverticulitis are different from those of left colon diverticulitis. Specifically, compared to left colon diverticulitis, right colon diverticulitis tends to occur at a younger age, with a lower Hinchey stage, and a lower rate of recurrence (3.1% versus 17.9% for left colon diverticulitis) [9]. Based on these facts, and considering the high diagnostic yield of CT imaging and the development of accurate pathological finding for colon cancer, the utility of routine colonoscopy in patients after treatment of acute right colon diverticulitis, in the absence of complications, such as perforation, abscess formation, and/or obstruction, has been questioned [10]. It has also been questioned if the incidence of colorectal cancer at younger ages is indeed more common on the left than on the right colon [6].

Several studies have been published on the effects of routine colonoscopy after conservative treatment of acute uncomplicated diverticulitis. Among 205 patients who underwent colonoscopy or CT colonoscopy, Westwood et al. reported a detection rate of 9.3% for adenomas and 0.5% for colorectal cancer [11]. Additionally, Horesh et al. reported a rate of malignant findings of 1.6% among 310 patients who underwent colonoscopy. Of specific clinical relevance is the finding that there was no incidence of adenocarcinoma of the colon on follow-up colonoscopy after uncomplicated colon diverticulitis among patients younger than 50 years of age [12]. However, the majority of this evidence included only patients with left colon diverticulitis. In fact, to our knowledge, only two previous studies addressed right colon diverticulitis [13, 14]. In their study of 109 patients with right-sided colon diverticulitis, Hashimoto et al. did not identify any cases of colorectal cancer, with a rate of advanced adenoma of 6.4% (7/109 cases) and non-advanced adenoma of 21.1% (23/109 cases) [14]. Chan et al. reported on 27 patients with right colon diverticulitis, with no incidence of colorectal cancer or advanced adenoma identified [13]. However, both of these studies included a small number of patients. By contrast, our study included 330 patients, a relatively large sample size. Similar to previous findings, adenoma and cancer detection rates were very low. Of significance was our finding that adenoma were identified only in the right colon.

The adenoma detection rate (ADR) has been associated with the interval risk of colorectal cancer [15]. The ADR can be used as a colonoscopy quality indicator, with an ADR of < 20% being associated with a 10-fold increase in the interval cancer risk [16]. The ADR in our study, which included only patients with right colon diverticulitis, was 20.3%. We consider this rate to be appropriate for our study as our primary outcome was the detection rate of colon cancer.

Limitation

The limitations of our study need to be acknowledged. Foremost, this is a retrospective study, with no knowledge of the outcomes of colonoscopy surveillance for patients who did not undergo follow-up colonoscopy. We do note that patients who did not undergo follow-up colonoscopy tended to be younger than those who did undergo colonoscopy follow-up, although there was no statistical significance. Furthermore, among the total of 355 patients (57.7%), including patients who performed follow-up colonoscopy at another hospital and those who underwent colon barium were confirmed that there was no colon cancer. This rate (57.7%) of colonoscopy surveillance is comparable to previously reported rate in review articles [17, 18]. Second, as our study is not a population based, our findings do not provide an estimate of colon cancer incidence in all patients with uncomplicated right colon diverticulitis. However, the strength of our study is the relatively large sample size which, in fact, is the largest study to date evaluating routine colonoscopy results among patients with right colon diverticulitis.

In conclusion, in patients with acute uncomplicated right colon diverticulitis, routine colonoscopy after conservative treatment may not be necessary. Therefore, for patients with CT findings of uncomplicated diverticulitis, regular colorectal cancer screening colonoscopy is likely to be sufficient for those 45 years of age and older, which is consistent with published guidelines.[5] It will be necessary to confirm the

results of our study by collecting a larger number of patients through a multicenter or population based study.

Declarations

Ethics approval and consent to participate: This study was approved by our hospital's institutional review board. Owing to the retrospective design of the study, the need for informed consent was waived. The study was conducted according to the principles of the Declaration of Helsinki.

Conflict-of-interest Statement: None of the authors have any conflict of interest.

Consent for publication: Not applicable

Availability of data and materials: Not applicable

Funding: Not applicable

Acknowledgements: Not applicable

Author Contributions

KYL and JIL designed the study. KYL and YYP collected the data and performed the statistical analysis. KYL, JIL, YYP and STO interpreted the results of the analysis and prepared the manuscript. All authors contributed extensively to the work presented.

Abbreviations

ADR, adenoma detection rate; CT, computed tomography; IQR, interquartile range

References

1 Painter NS, Burkitt DP. Diverticular disease of the colon: a deficiency disease of Western civilization. *Br Med J* 1971; **2**(5759): 450-454 [PMID: 4930390 PMCID: PMC1796198 DOI: 10.1136/bmj.2.5759.450]

2 Strate LL, Morris AM. Epidemiology, Pathophysiology, and Treatment of Diverticulitis. *Gastroenterology* 2019; **156**(5): 1282-1298 e1281 [PMID: 30660732 PMCID: PMC6716971 DOI: 10.1053/j.gastro.2018.12.033]

3 Strate LL, Peery AF, Neumann I. American Gastroenterological Association Institute Technical Review on the Management of Acute Diverticulitis. *Gastroenterology* 2015; **149**(7): 1950-1976 e1912 [PMID: 26453776 DOI: 10.1053/j.gastro.2015.10.001]

4 Chung BH, Ha GW, Lee MR, Kim JH. Management of Colonic Diverticulitis Tailored to Location and Severity: Comparison of the Right and the Left Colon. *Ann Coloproctol* 2016; **32**(6): 228-233 [PMID: 28119866 PMCID: PMC5256252 DOI: 10.3393/ac.2016.32.6.228]

5 Wolf AMD, Fontham ETH, Church TR, Flowers CR, Guerra CE, LaMonte SJ, Etzioni R, McKenna MT, Oeffinger KC, Shih YT, Walter LC, Andrews KS, Brawley OW, Brooks D, Fedewa SA, Manassaram-Baptiste D, Siegel RL, Wender RC, Smith RA. Colorectal cancer screening for average-risk adults: 2018 guideline update from the American Cancer Society. *CA Cancer J Clin* 2018; **68**(4): 250-281 [PMID: 29846947 DOI: 10.3322/caac.21457]

6 Segev L, Kalady MF, Church JM. Left-Sided Dominance of Early-Onset Colorectal Cancers: A Rationale for Screening Flexible Sigmoidoscopy in the Young. *Dis Colon Rectum* 2018; **61**(8): 897-902 [PMID: 29771800 DOI: 10.1097/DCR.0000000000001062]

7 Wasvary H, Turfah F, Kadro O, Beauregard W. Same hospitalization resection for acute diverticulitis. *Am Surg* 1999; **65**(7): 632-635; discussion 636 [PMID: 10399971]

8 Suhardja TS, Norhadi S, Seah EZ, Rodgers-Wilson S. Is early colonoscopy after CT-diagnosed diverticulitis still necessary? *Int J Colorectal Dis* 2017; **32**(4): 485-489 [PMID: 28035461 DOI: 10.1007/s00384-016-2749-5]

9 Soh NYT, Teo NZ, Tan CJH, Rajaraman S, Tsang M, Ong CJM, Wijaya R. Perforated diverticulitis: is the right and left difference present here too? *Int J Colorectal Dis* 2018; **33**(5): 525-529 [PMID: 29532203 DOI: 10.1007/s00384-018-3007-9]

10 Agarwal AK, Karanjawala BE, Maykel JA, Johnson EK, Steele SR. Routine colonic endoscopic evaluation following resolution of acute diverticulitis: is it necessary? *World J Gastroenterol* 2014; **20**(35): 12509-12516 [PMID: 25253951 PMCID: PMC4168084 DOI: 10.3748/wjg.v20.i35.12509]

11 Westwood DA, Eglinton TW, Frizelle FA. Routine colonoscopy following acute uncomplicated diverticulitis. *Br J Surg* 2011; **98**(11): 1630-1634 [PMID: 21713756 DOI: 10.1002/bjs.7602]

12 Horesh N, Saeed Y, Horesh H, Berger Y, Speter C, Pery R, Rosin D, Gutman M, Zmora O. Colonoscopy after the first episode of acute diverticulitis: challenging management paradigms. *Tech Coloproctol* 2016; **20**(6): 383-387 [PMID: 27170283 DOI: 10.1007/s10151-016-1478-7]

13 Chan DKH, Tan KK. There Is No Role for Colonoscopy after Diverticulitis among Asian Patients Less than 50 Years of Age. *Gastrointest Tumors* 2017; **3**(3-4): 136-140 [PMID: 28611980 PMCID: PMC5465732 DOI: 10.1159/000446565]

14 Hashimoto R, Matsuda T, Chonan A. Colonoscopy After Computed Tomography-diagnosed Acute Right-sided Diverticulitis May Be Unnecessary. *J Clin Gastroenterol* 2016; **50**(7): 611-612 [PMID: 26974757 DOI: 10.1097/MCG.0000000000000516]

15 Corley DA, Jensen CD, Marks AR, Zhao WK, Lee JK, Doubeni CA, Zauber AG, de Boer J, Fireman BH, Schottinger JE, Quinn VP, Ghai NR, Levin TR, Quesenberry CP. Adenoma detection rate and risk of colorectal cancer and death. *N Engl J Med* 2014; **370**(14): 1298-1306 [PMID: 24693890 PMCID: PMC4036494 DOI: 10.1056/NEJMoa1309086]

16 Kaminski MF, Regula J, Kraszewska E, Polkowski M, Wojciechowska U, Didkowska J, Zwierko M, Rupinski M, Nowacki MP, Butruk E. Quality indicators for colonoscopy and the risk of interval cancer. *N Engl J Med* 2010; **362**(19): 1795-1803 [PMID: 20463339 DOI: 10.1056/NEJMoa0907667]

17 Sai VF, Velayos F, Neuhaus J, Westphalen AC. Colonoscopy after CT diagnosis of diverticulitis to exclude colon cancer: a systematic literature review. *Radiology* 2012; **263**(2): 383-390 [PMID: 22517956 PMCID: PMC3329267 DOI: 10.1148/radiol.12111869]

18 de Vries HS, Boerma D, Timmer R, van Ramshorst B, Dieleman LA, van Westreenen HL. Routine colonoscopy is not required in uncomplicated diverticulitis: a systematic review. *Surg Endosc* 2014; **28**(7): 2039-2047 [PMID: 24488358 DOI: 10.1007/s00464-014-3447-4]

Figures

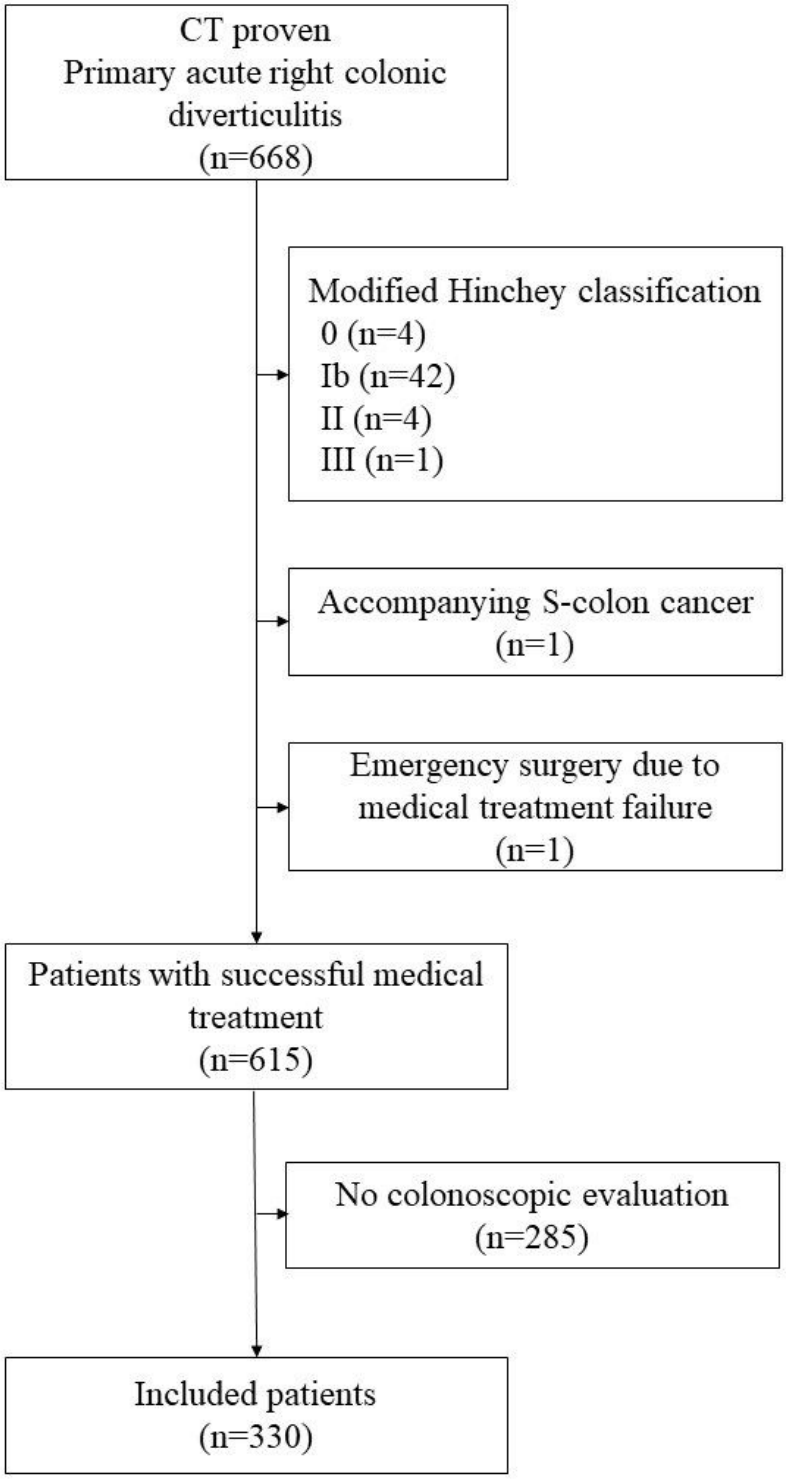

Figure 1

Flow diagram of patient selection.