Proximal junction kyphosis in adult scoliosis. best post-operative radiological predictors. Retrospective cohort study.

Daudi Romani Manini (daudiromani@yahoo.co.uk)
Central South University Xiangya School of Medicine

Hong-qi Zhang
Central South University Xiangya School of Medicine

Yu-Xiang Wang
Central South University Xiangya School of Medicine

Frank Damas Shega
Central South University Xiangya School of Medicine

Yuxuan Du
central south university xiangya school of medicine

Research article

Keywords: Proximal junction kyphosis, post-surgical, radiographic, spinal deformity

Posted Date: February 3rd, 2020

DOI: https://doi.org/10.21203/rs.2.22491/v1

Abstract

Background: Proximal junction kyphosis is the post-surgical radiographic event seen in the surgical plane after the fusion of spinal deformity. No common agreement on direct postoperative radiographic prognostic criteria for occurrences of proximal junctional kyphosis that justify close monitoring for the patients. The purpose of this study is to assess which immediate post-surgical radiographic variable is best in forecasting the occurrences of proximal junction kyphosis. Methods: Data for adult scoliosis patients who underwent curve correction were extracted from the hospital database. Pelvic and spinal parameters were measured, Fisher exact test was performed for continuous variables and the Chi-square test was used for noncontinuous variables to compare four immediate post-surgical radiographic variables for occurrences of proximal junctional kyphosis. These variables were; Restoration of hypothetical values of lumbar lordosis and thoracic kyphosis according to pelvic incidence, evaluation of global sagittal alignment. Restoration of the apex of lumbar lordosis to its hypothetical position according to the spine shape and evaluation of positive-sum and negative-sum of lumbar lordosis and thoracic kyphosis. Results: The excellent predictor for occurrences of proximal junctional kyphosis was restoration of the apex of lumbar lordosis to its hypothetical position according to the spine shape. The second good predictor for occurrences of proximal junctional kyphosis was evaluation of global sagittal alignment. The Restoration of hypothetical values of lumbar lordosis and thoracic kyphosis according to pelvic incidence and evaluation of positive-sum and negative-sum of lumbar lordosis and thoracic kyphosis were both poor predictors for occurrences of proximal junction kyphosis. Conclusion: Among the four proposed formulae for predicting occurrences of proximal junctional kyphosis, the position of the sagittal apex of lumbar lordosis is an excellent predictor for the development of proximal junctional kyphosis followed by global sagittal alignment. Therefore, during scoliosis deformity correction hypothetical position of the sagittal apex of lumbar lordosis should be used to decide the level of pedicle subtraction osteotomy or a suitable place to put lordotic cages to reduce the risk of the future occurrences of proximal junctional kyphosis.

Introduction

Proximal junction kyphosis (PJK) is the post-surgical radiographic event seen in the surgical plane after the fusion of spinal deformity. In wide view PJK is regarded as a form of adjacent segment disease associated with spinal fusion, mostly occurring after scoliosis or kyphosis surgery(1, 2). PJK frequently arises just above the uppermost instrumented vertebrae (UIV). The most accepted PJK definition is the one defined by Glattes et al:(3) PJK angle is the angle subtended by the lower endplate of the UIV to the upper endplate of two vertebrae proximal. PJK is said to be present if the sagittal Cobb angle is $\geq 10^0$ and at least 10^0 larger than preoperative measurement(4). The incidence of PJK as reported from the literature varies greatly and ranges from 5–46% to spinal patients who undergo deformity curve correction. PJK can be diagnosed in the radiographic film as soon as 8 weeks postoperatively(5, 6).

Several risk factors for occurrences of PJK have been reported in the literature including Age more than 55 years, large abnormal preoperative sagittal parameters (high lumbar lordosis and long thoracic

kyphosis), application of pedicle screws, thoracoplasty procedures, big curvature correction, posterior and combined anteroposterior spinal fusion (i.e., distraction of the posterior tension band and other posterior intervertebral elements), fusion involving the lower lumbar spine and sacrum, osteoporosis and high body mass index(2, 7, 8).

More unfavorable scoliosis research society (SRS) and Oswestry disability index (ODI) scores have been reported in symptomatic PJK patients relative to none-PJK patients. Moreover, it may lead to revision surgery(1, 9).

There is no common agreement on direct postoperative radiographic prognostic criteria for PJK that justify close monitoring for the patients. Vialle et al(10) suggested that physiological spinal sagittal balance should serve as a

baseline in the assessment of pathological state. They further advocated the restoration of lumbar lordosis (LL) and thoracic kyphosis (TK) to their normal theoretical value according to pelvic incidence (PI). Again in 2012 Yagi et al(2) found that many preoperative patients with imperfect global sagittal alignment (GSA) ($TK + LL + PI > 45^0$) have a high tendency of developing PJK. They further proposed that high postoperative GSA result in the positive sagittal vertical axis (SVA) and increase the stress for the proximal and distal junctions of instrumentation that lead to the development of PJK.

Roussouly et al(11) suggested that the sagittal apex of LL be placed at L4 when PI is small (in type 1 and type2 lordosis curve). On the other hand, the apex is placed at L3 or L3-L4 disc when PI is larger (in type 3 and type 4 lordosis curve) during deformity correction. They further argued that restoration of sagittal LL apex to its hypothetical standard could radiologically predict the occurrence of PJK and implant breakage. Also, Mendoza et al(12) in a retrospective study of adult spine deformity patients who underwent curve correction found that PJK occurred in patients whose TK remained bigger compared to LL postoperatively. They further hypothesized that the positive sum of LL and TK was associated with a high rate occurrence of PJK.

The aim of this retrospective study is to assess which immediate post-surgical radiographic variable among the proposed above is the best in forecasting the future occurrences of PJK in adult scoliosis after deformity correction.

Materials And Method

A retrospective study of 52 adult scoliosis patients who underwent scoliosis curve correction in Xiangya Hospital of Central South University from January 2012 to December 2016 was done. After approval from the institutional review board of Xiangya hospital of Central South University. Data were retrieved from the hospital database.

Inclusion criteria: (1) Patient with scoliosis deformity Cobb $\geq 25^0$ on the anteroposterior (AP) view. (2) patients aged ≥25 years. (3) patients with a follow-up period of at least 2 years. (4) Patients with all

radiological films (preoperative, immediate postoperative and last follow-up films) available. (5) Patients with lower instrumented vertebra end at L4 or below.

Exclusion criteria: (1) Patients with surgery of other spinal abnormalities such as tumor, tuberculosis or accident.

(2) Patients with incomplete radiographic data. (3) Patients with a follow-up of fewer than 6 months.

Radiographic measurements: Both pelvic and sagittal parameters were measured by the method previously described by Lafage et al(13) and Lagaye et al(14). This was done independently by two authors and the differences between them were solved through discussion with the 3rd author. TK angle was measured from the upper endplate of T4 and the lower endplate of T12. LL angle was measured from the upper endplate of L1 to the upper endplate of S1. PI angle was measured between the line drawn perpendicular to the sacral endplate at its center and the line drawn from the center of the sacral endplate to the midpoint of the bicoxofemoral axis. PT angle was measured between the line joining the center of the sacral endplate to the center of the bicoxofemoral axis and the vertical. SS was the angle formed between the horizontal and superior sacral endplate of S1. And Proximal junctional angle (PJA) was measured from the lower endplate of the UIV to the upper endplate of 2 levels superior to the UIV.

Four formulae were used immediately postoperatively to forecast the future occurrence of PJK as follows:

Formula 1: hypothetical values of LL and TK were calculated as previously stated by Vialle et al(10)

LL=0.67PI+23.7 and TK=0.15PI+43. Then the rate of occurrences of PJK to patients whose immediate postoperative LL and TK values were equal or nearly equal to their theoretical value was compared to patients whose LL and TK values deviated far from their theoretical value. (discrepancy of 3^0 of a real value from theoretical value was accepted).

Formula 2: immediate postoperative GSA was calculated by the formula; **GSA=LL+TK +PI** as previously reported by Yagi et al(2). And the occurrence of PJK to patients with GSA > 45^0 versus GSA < 45^0 were compared.

Formula 3: The position of the sagittal apex of LL was marked on immediate postoperative radiological films. The hypothetical apex value of LL was assumed to be at L4 in PI < 55^0 and L3 when PI > 55^0 as stated by Roussouly et al(11). Then the occurrences of PJK between patients whose sagittal apexes of LL were at theoretical value were compared to patients whose sagittal apexes of LL were not at their theoretical value.

Formula 4: The sum of LL and TK was calculated from the immediate postoperative radiological films as stated by Mendoza et al(12). The occurrences of PJK between positive-sum (LL + TK) and negative-sum (LL + TK) were compared.

PJK angle was calculated from radiological films in the final follow-up visit as previously described by Glattes et al(3).

Statistical analysis

IBM SPSS (version 21) was used for statistical analysis. Fisher exact test was performed for continuous variables and the Chi-square test was used for noncontinuous variables. The odds ratio (OR) was calculated.

A p-value of < 0.05 was considered to be statistically significant.

Results

52 patients fulfilled our inclusion criteria, the ratio of female to male was 16.3:1, with the mean age for all cases, was 61.1±6.3. The mean follow-up time in years was 2.05 ± 0.85. The mean time in years for the occurrence of PJK was 1.25 ± 0.61, (0.5-3), with 71.43% of cases occurring within 1 year postoperatively. There were 14 cases of PJK, the incidence of PJK was 26.9% and the mean age for PJK cases was 63.2±5.2. The mean PI was 54.64 ± 13.91. The mean preoperative PT was 22.98 ± 8.08 which changed to 19.28 ± 7.64, (p = 0.018). The average LL preoperatively was -41.26 ± 10.95 changed to -54.25 ± 11.41, (p = 0.000). The average preoperative TK was 39.76 ± 12.17 and 14.91 ± 14.91 postoperatively (p = 0.076). The average preoperative SS was 29.99 ± 10.44 and 33.84 ± 9.73 (p = 0.054). UIV was located in upper thoracic (T1-T4) in 67.3%, in mid-thoracic (T5 -T9) in 25% and thoracolumbar (T10 -L2) in 7.7%. The rate of occurrences of PJK in these regions were respectively 25.71%, 30% and 25% (p =0.94). The preoperative LL apex was located at L2 in 1.92% patients, L2-L3 disc in 21.15% patients, L3 in 26.92% patients, L3-L4 disc in 25% patients and L4 in 25% patients.

The occurrences of PJK as speculated by different formula from immediate postoperative hypothetical calculated value were as follows:

Formula 1: The mean theoretical value of LL as calculated from Vialle et al method was -60.31±9.31, different from the true value -54.25±11.41 (p = 0.004). And the mean theoretical value of TK was 51.2 ± 2.08 different from the real value 44.54±14.91 (P= 0.002). PJK occurred in 26% of patients with postoperative LL and Tk equal or nearly equal to their hypothetical value. While PJK occurred in 27.6% of patients when LL and TK were far different from their theoretical value. Odds ratio (OR) 1.08, 95% confidence interval (CI), (0.31- 3.72), P = 0.9

Formula 2: The mean GSA was 44.93 ± 18.6. 44.23% of patients had GSA < 45^0 and 55.77% of patients had GSA > 45%. PJK occurred in 16% of cases with GSA < 45^0 and 34.5% of cases with GSA > 45^0. OR= 2.5, (95% CI, 0.67-9.38), P= 0.17.

Formula 3: postsurgical sagittal apexes of lumbar lordosis were located in their hypothetical position in 24 cases, and 12.5% of these cases developed PJK. While sagittal apexes were not located their

hypothetical position in 28 patients and PJK occurred in 39.3% of them. P =0.03, OR 4.53, (95% CI 1.09-18.9).

Formula 4: The mean sum of (LL+TK) was -9.7 ± 17.4. The sum (LL+ TK) was positive in 14 patients and 28.6% of these patients developed PJK. and the sum (LL+ TK) was negative in 38 patients, from which 26.3% of patients developed PJK. OR = 1.12, 95%CI (0.29-4.31), P = 0.87.

Table 1
Preoperative and postoperative spinal pelvic parameters in degree.

		preoperative	**postoperative**		
	MEAN	SD	MEAN	SD	P-value
Pelvic incidence	54.64	13.91			
Pelvic tilt	22.98	8.08	19.28	7.64	0.018
Lumbar lordosis	-41.26	10.95	-54.25	11.41	000
Thoracic kyphosis	39.76	12.17	44.54	14.91	0.076
Sacral slope	29.99	10.44	33.84	9.73	0.054
SD = Standard deviation.					

Discussion

Several risk factors for occurrences of PJK have been reported in the literature including age more than 55 years, large abnormal preoperative sagittal parameters (high lumbar lordosis and long thoracic kyphosis), application of pedicle screws, thoracoplasty procedures, big curvature correction, posterior and combined anteroposterior spinal fusion (i.e., distraction of the posterior tension band and other posterior intervertebral elements), fusion involving the lower lumbar spine and sacrum, osteoporosis and high body mass index(7, 8). The common agreement on direct postoperative radiographic prognostic criteria for PJK has not yet established. Maruo et al(15) suggested that improved postoperative radiographic sagittal alignment parameters are an important method to mitigate the development of PJK after adult deformity correction.

In this retrospective study, we have used four formulae, to predict the development of PJK based on immediate post-operative radiological films. We found that among the four proposed formulae, the position of the sagittal apex of lumbar lordosis (**formula 3**) is the best immediate postoperative radiographic predictor of occurrences of PJK among the four hypothesized formulae. It has a great predictive value OR 4.5 (95% CI 1.09-18.9). This means that the occurrence of PJK is almost 5 times high when the apex of LL is not at its theoretical position compared to when it is at its theoretical position. The second good predictor parameter in our study for the occurrence of PJK was GSA (**formula 2**). The predictive value for GSA was OR= 2.5, (95% CI, 0.67-9.38). This means that when GSA is > 45^0 the

occurrence of PJK is 2.5 times compared to when GSA is < 45^0. Even though formula 2 failed to reject the null hypothesis as the CI includes 1. The 3rd good predictor for occurrences of PJK was **formula 4,** when the sum positive (LL+TK) was compared with negative-sum (LL+TK) the predictive value was OR 1.12, (95% CI 0.29-4.39). but failed to reject the null hypothesis as the CI includes 1. The least predictive formula for occurrences of PJK among the four proposed formulae was **formula 1.** When the LL and TK were equal or nearly equal to their theoretical value the predictive ability for occurrences of PJK was OR 1.08 (95% CI 0.31.-3.72). The CI includes 1, it also failed to reject the null hypothesis.

Lafage et al(16) in their virtual model stated that realignment surgery for the adult spinal deformity (ASD) can be extremely successful by restoring a balanced sagittal alignment. Rose et al(17) defined ideal GSA as PI + LL +TK less than 45^0 and they found that the formula has a great sensitivity in forecasting the success of pedicle subtraction osteotomy (PSO) for two years. Yagi et al(2) in their retrospective review of 157 cases, they found that more than 80% of patient with non-ideal global sagittal alignment (GSA> 45^0) developed PJK, and the OR for these patients was 29. Sebaaly et al(18) in their retrospective study of 250 cases of adult idiopathic scoliosis from a multicentric database, found that GSA >45^0 was associated with the occurrences of PJK, with OR 1.7. in this study we also found that GSA> 45^0 is highly associated with occurrences of PJK, with OR 2.5. This might be explained by the reason that increased GSA results in the positive (SVA) and increases the stress for the proximal and distal junctions of instrumentation that lead to the development of PJK(19).

Roussouly et al(11) after studying the sagittal alignment of 160 healthy volunteers divided the spine into four types based on inflexion point. Type 1 and type 2 had low PI, type 3 and type 4 had high PI. They found that the lower arc of lordosis is a key determinant of global lordosis (lordosis tilt angle, location of the apex, and the number of lordotic vertebras). Both low SS and low PI are accompanied by flat and short lumbar lordosis while high SS and high PI are accompanied by long and curved lumbar lordosis. They further proposed that the spine is well balanced when lordosis apex is at L4 for low PI and L3 for high PI. In our study, the occurrences of PJK were very high when apexes of sagittal lordosis were not at their theoretical position compared to when they're positioned at their theoretical position. These findings are similar to what has been reported in the literature by other scholars(18). This may be explained as when the postoperative apex is located high above its theoretical position kyphosis has less room to be constructed and increase the risk of occurrences of PJK and other spinal abnormalities(20).

In this study, we found that both **formula 1** and **formula 4** have low predictive ability for occurrences of PJK. this similar to what has been reported recently in the literature(18).

Despite meeting the criteria of all formula above yet occurrences of PJK were still there. and even some of the formulae failed to reject the null hypothesis. This might be the reason that risk factors for occurrences of PJK are many. some have been reported in the literature, including age, low bone mineral density, the use of pedicle screws, thoracoplasty, combined anteroposterior fusion surgery, and long fusion surgery(21-23).

The most important finding of this study is that the theoretical position of the sagittal apex of lumbar lordosis is a preventive factor for the development of PJK. This finding can guide the surgeon to decide the level of pedicle subtraction osteotomy (PSO) or a suitable place to put lordotic cages during spine deformity correction. Lafage et al(24) in a multicenter retrospective study of 70 cases of adult spine deformity who underwent PSO found no difference in sagittal curve correction between L3 and L4 PSO. But in this study, we suggest that PSO be done at L4 in low PI and at L3 in high PI patients.

This study has some weaknesses which are: is a retrospective study design with some data missing and some patients lost follow-up, for example, the data for bone mineral density and Oswestry disability index scores were not found. It also is a single-center study with a small sample size. But despite these limitations, the results from this study are similar to what has been reported by other scholars.

Conclusion

Among the four proposed formulae for predicting occurrences of proximal junctional kyphosis, the position of the sagittal apex of lumbar lordosis is an excellent predictor for the development of proximal junctional kyphosis followed by global sagittal alignment. Therefore, during scoliosis deformity correction hypothetical position of the sagittal apex of lumbar lordosis should be used to decide the level of pedicle subtraction osteotomy or a suitable place to put lordotic cages to reduce the risk of the future occurrences of proximal junctional kyphosis.

Abbreviations

PJA= proximal junctional angle, **PJK**= proximal junctional kyphosis, **PJF**= proximal junctional kyphosis, **IUV**= upper instrumented vertebra, **TK**= thoracic kyphosis, **LL**= lumbar lordosis, **GSA**=global sagittal alignment, **PT**=pelvic tilt, **SS**= sacral slope, **SVA=** sagittal vertical axis, **SRS**=scoliosis research society **ODI**= Oswestry disability index, **AP**=anteroposterior, **PSO**=pedicle substraction osteotomy, **OR**= odds ratio, **CI=**confidance interval.

Declarations

Ethical approval and consent to participate:

The study protocol was approved by the Ethics Committee of the Xiangya first Hospital of Central South University.

Consent for publication:

“Not applicable”

Availability of data and material:

“All datasets analyzed during this study are included in this article given as additional file 1”

Competing Interest

The authors declare that they have no competing interest.

Funding:

No fund received during the preparation of this work

Authors contribution:

HZQ, gave the idea and designed the study, MDR and YXW collected the data, analyzed the data and wrote the paper. All authors read and approved the final manuscript.

Acknowledgements

The authors cordially appreciate the assistance from the working staff of the medical record department of Xiangya first hospital for providing the data whenever needed.

Authors information

Hongqi Zhang: Is currently head of department of spine surgery of Xiangya hospital of Central South University.

Daudi Romani Manini: Is currently a 3rd year resident in spine department of Xiangya hospital of Central South University.

YuXiangWang; Is currently a spinal surgeon, in the department of spine surgery of Xiangya hospital of Central South University.

Du Yuxuan: Is currently a first year Phd students in spine department of Xiangya hospital of Central South University.

References

1. Cho SK, Shin JI, Kim YJ. Proximal junctional kyphosis following adult spinal deformity surgery. Eur Spine J. 2014;23(12):2726-36.
2. Yagi M, Akilah KB, Boachie-Adjei O. Incidence, risk factors and classification of proximal junctional kyphosis: surgical outcomes review of adult idiopathic scoliosis. Spine (Phila Pa 1976). 2011;36(1):E60-8.
3. Glattes RC, Bridwell KH, Lenke LG, Kim YJ, Rinella A, Edwards C, 2nd. Proximal junctional kyphosis in adult spinal deformity following long instrumented posterior spinal fusion: incidence, outcomes, and risk factor analysis. Spine (Phila Pa 1976). 2005;30(14):1643-9.

4. Cammarata M, Aubin CE, Wang X, Mac-Thiong JM. Biomechanical risk factors for proximal junctional kyphosis: a detailed numerical analysis of surgical instrumentation variables. Spine (Phila Pa 1976). 2014;39(8):E500-7.
5. Lau D, Clark AJ, Scheer JK, Daubs MD, Coe JD, Paonessa KJ, et al. Proximal junctional kyphosis and failure after spinal deformity surgery: a systematic review of the literature as a background to classification development. Spine (Phila Pa 1976). 2014;39(25):2093-102.
6. Lee J, Park YS. Proximal Junctional Kyphosis: Diagnosis, Pathogenesis, and Treatment. Asian Spine J. 2016;10(3):593-600.
7. Bridwell KH, Lenke LG, Cho SK, Pahys JM, Zebala LP, Dorward IG, et al. Proximal junctional kyphosis in primary adult deformity surgery: evaluation of 20 degrees as a critical angle. Neurosurgery. 2013;72(6):899-906.
8. O'Shaughnessy BA, Bridwell KH, Lenke LG, Cho W, Baldus C, Chang MS, et al. Does a long-fusion "T3-sacrum" portend a worse outcome than a short-fusion "T10-sacrum" in primary surgery for adult scoliosis? Spine (Phila Pa 1976). 2012;37(10):884-90.
9. Hassanzadeh H, Gupta S, Jain A, El Dafrawy MH, Skolasky RL, Kebaish KM. Type of Anchor at the Proximal Fusion Level Has a Significant Effect on the Incidence of Proximal Junctional Kyphosis and Outcome in Adults After Long Posterior Spinal Fusion. Spine Deformity. 2013;1(4):299-305.
10. Vialle R, Levassor N, Rillardon L, Templier A, Skalli W, Guigui P. Radiographic analysis of the sagittal alignment and balance of the spine in asymptomatic subjects. The Journal of bone and joint surgery American volume. 2005;87(2):260-7.
11. Roussouly P, Gollogly S, Berthonnaud E, Dimnet J. Classification of the normal variation in the sagittal alignment of the human lumbar spine and pelvis in the standing position. Spine (Phila Pa 1976). 2005;30(3):346-53.
12. Mendoza-Lattes S, Ries Z, Gao Y, Weinstein SL. Proximal junctional kyphosis in adult reconstructive spine surgery results from incomplete restoration of the lumbar lordosis relative to the magnitude of the thoracic kyphosis. The Iowa orthopaedic journal. 2011;31:199-206.
13. Lafage V, Ames C, Schwab F, Klineberg E, Akbarnia B, Smith J, et al. Changes in thoracic kyphosis negatively impact sagittal alignment after lumbar pedicle subtraction osteotomy: a comprehensive radiographic analysis. Spine (Phila Pa 1976). 2012;37(3):E180-7.
14. Legaye J, Duval-Beaupere G, Hecquet J, Marty C. Pelvic incidence: a fundamental pelvic parameter for three-dimensional regulation of spinal sagittal curves. Eur Spine J. 1998;7(2):99-103.
15. Maruo K, Ha Y, Inoue S, Samuel S, Okada E, Hu SS, et al. Predictive factors for proximal junctional kyphosis in long fusions to the sacrum in adult spinal deformity. Spine (Phila Pa 1976). 2013;38(23):E1469-76.
16. Lafage R, Bess S, Glassman S, Ames C, Burton D, Hart R, et al. Virtual Modeling of Postoperative Alignment After Adult Spinal Deformity Surgery Helps Predict Associations Between Compensatory Spinopelvic Alignment Changes, Overcorrection, and Proximal Junctional Kyphosis. Spine (Phila Pa 1976). 2017;42(19):E1119-e25.

17. Rose PS, Bridwell KH, Lenke LG, Cronen GA, Mulconrey DS, Buchowski JM, et al. Role of pelvic incidence, thoracic kyphosis, and patient factors on sagittal plane correction following pedicle subtraction osteotomy. Spine (Phila Pa 1976). 2009;34(8):785-91.
18. Sebaaly A, Riouallon G, Obeid I, Grobost P, Rizkallah M, Laouissat F, et al. Proximal junctional kyphosis in adult scoliosis: comparison of four radiological predictor models. Eur Spine J. 2018;27(3):613-21.
19. Yagi M, King AB, Boachie-Adjei O. Incidence, Risk Factors, and Natural Course of Proximal Junctional Kyphosis. Spine. 2012;37(17):1479-89.
20. Yu M, Silvestre C, Mouton T, Rachkidi R, Zeng L, Roussouly P. Analysis of the cervical spine sagittal alignment in young idiopathic scoliosis: a morphological classification of 120 cases. Eur Spine J. 2013;22(11):2372-81.
21. Lowe TG, Kasten MD. An analysis of sagittal curves and balance after Cotrel-Dubousset instrumentation for kyphosis secondary to Scheuermann's disease. A review of 32 patients. Spine (Phila Pa 1976). 1994;19(15):1680-5.
22. Kim YJ, Lenke LG, Bridwell KH, Kim J, Cho SK, Cheh G, et al. Proximal junctional kyphosis in adolescent idiopathic scoliosis after 3 different types of posterior segmental spinal instrumentation and fusions: incidence and risk factor analysis of 410 cases. Spine (Phila Pa 1976). 2007;32(24):2731-8.
23. Wang J, Zhao Y, Shen B, Wang C, Li M. Risk factor analysis of proximal junctional kyphosis after posterior fusion in patients with idiopathic scoliosis. Injury. 2010;41(4):415-20.
24. Lafage V, Schwab F, Vira S, Hart R, Burton D, Smith JS, et al. Does vertebral level of pedicle subtraction osteotomy correlate with degree of spinopelvic parameter correction? J Neurosurg Spine. 2011;14(2):184-91.

Supplemental Information

Additional file 1: Microsoft excel worksheet (.xlsx), containing data used in analysis for this study.

Figures

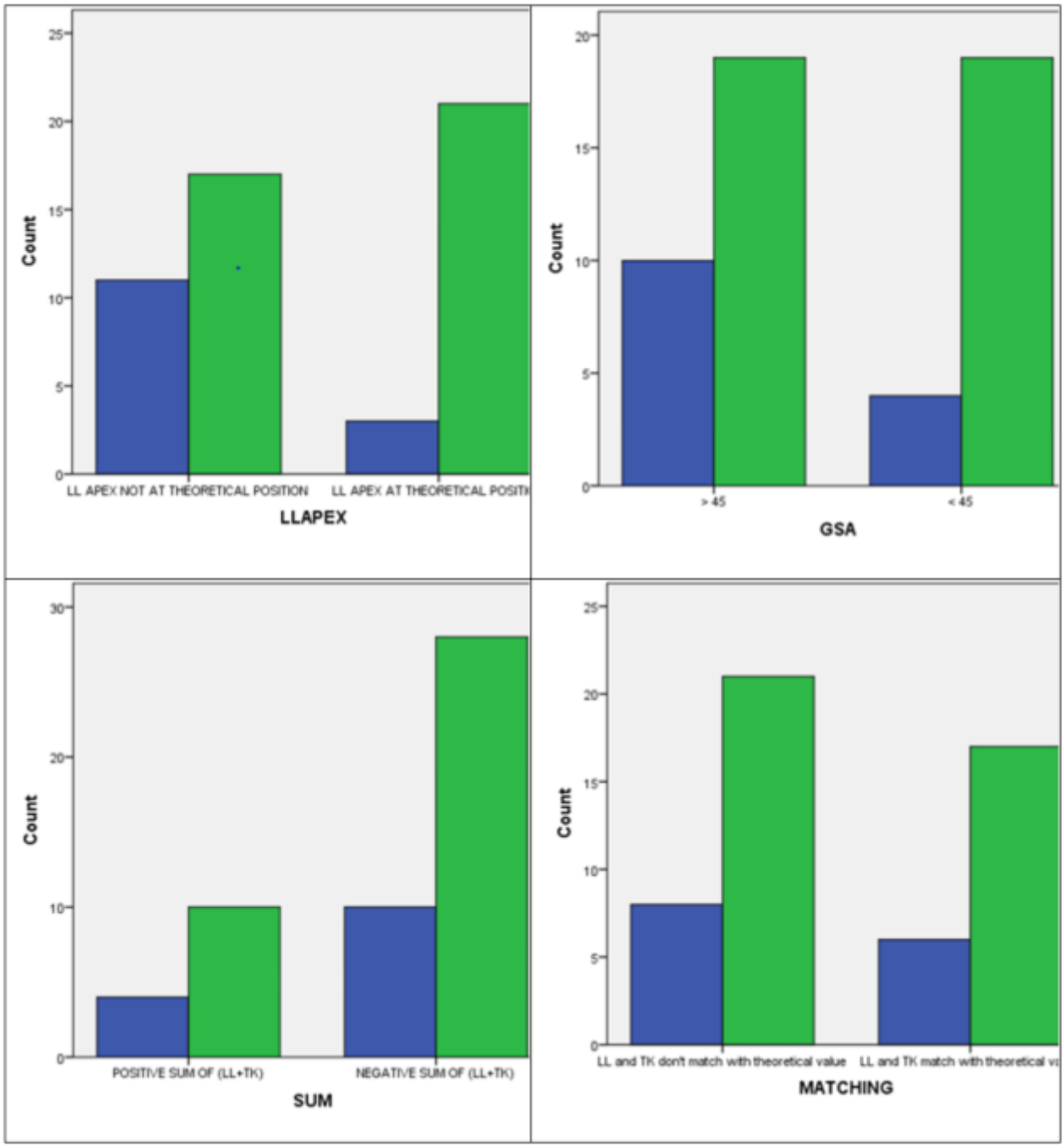

Figure 1

Bar charts to show the occurrences of PJK as predicted by each proposed formula. Blue shows the number of patients who developed PJK while green shows the number of patients who have not developed PJK in each formula.

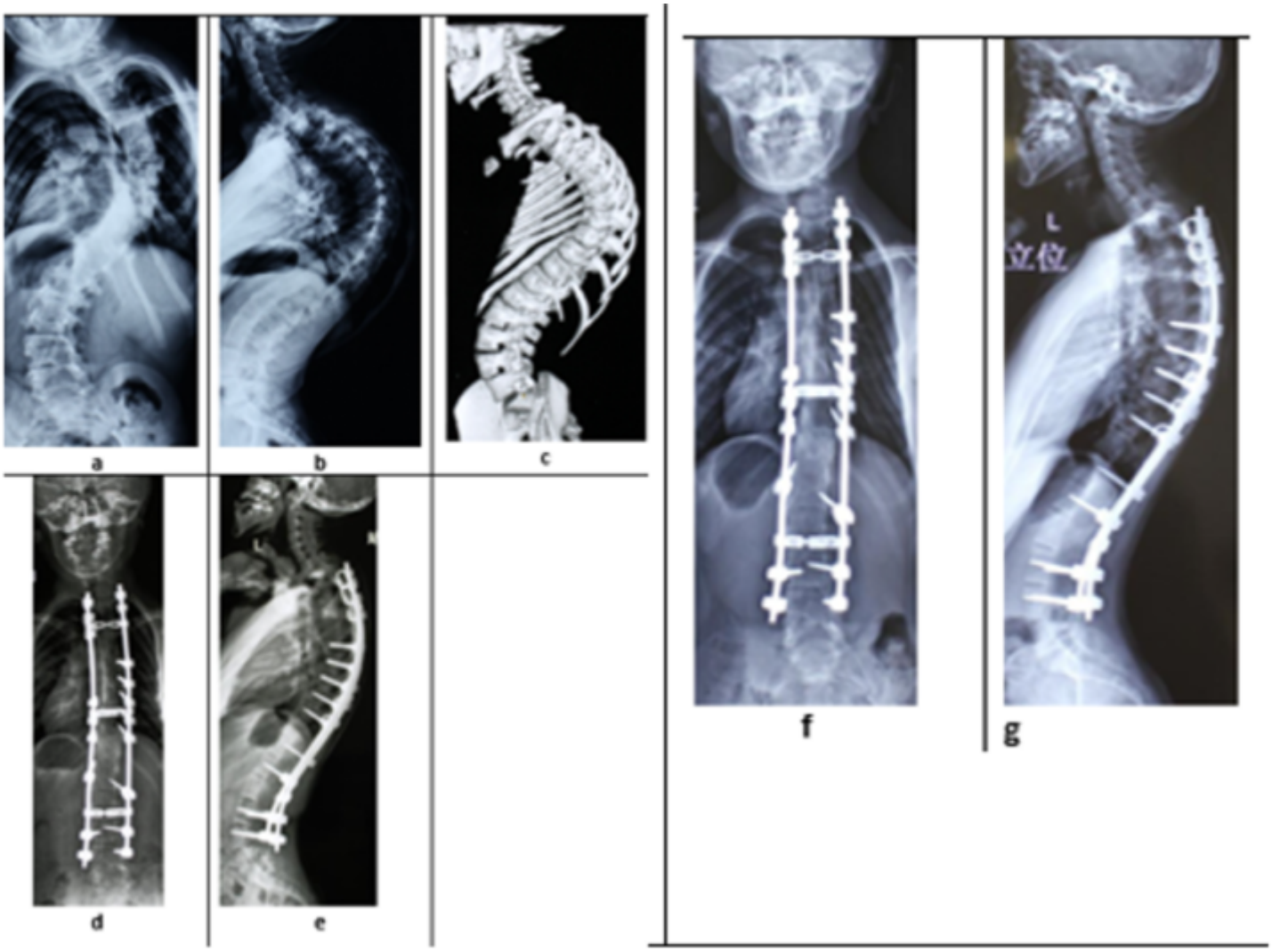

Figure 2

Radiographic films of a 40-year-old female patient with neglected scoliosis who underwent scoliosis curve correction and developed asymptomatic PJK after one year. “a” is preoperative anteroposterior (AP) X-ray views, “b” is preoperative lateral X-ray view and “c” is a bone scan 3D model done preoperatively. “d” and “e” are immediate postoperative AP and lateral x-ray films and “f” and g are AP and lateral x-ray films done after 1 year. The PJK angle after 1 year was 110 greater than immediate postoperative.

Supplementary Files

This is a list of supplementary files associated with this preprint. Click to download.

- Additionalfile1.xlsx