Minimally invasive plating of midshaft clavicle fractures with distal clavicle anatomic locking plate

Qing Liu (yxyxs0698@sina.com)
The Affiliated Hospital of Medical School of Ningbo University

Wenwei Dong
The Affiliated Hospital of Medical School of Ningbo University

Haijiao Mao
The Affiliated Hospital of Medical School of Ningbo University

Liwei Yao
The Affiliated Hospital of Medical School of Ningbo University

Zeting Wu
The Affiliated Hospital of Medical School of Ningbo University

Research Article

Keywords: Minimally invasive surgery, midshaft clavicle fracture, operative technique, plate

Posted Date: February 4th, 2022

DOI: https://doi.org/10.21203/rs.3.rs-1310784/v1

Abstract

Background: Minimally invasive plating has been widely applied to treat long bone shaft fractures. But it was rarely used in clavicle fractures because of the technical difficulties of closed reduction and fixation. We report our improved techniques of minimally invasive treatment for midshaft clavicle fractures using distal clavicle anatomic locking plate and compare its result with that of open reduction and internal fixation.

Materials and methods: A retrospective comparative study was performed in our institution from Jan 2019 to May 2020. Patients with acute midshaft clavicle fractures that were treated with minimally invasive technique or open reduction and internal fixation using distal clavicle anatomic locking plate were included. According to the included and excluded criteria, a total of 58 patients were included and divided into two groups based on the operation technique. We compared the two groups in surgical duration, fracture reduction, time for union, Constant-Murley score, cosmetic result and other complications.

Results: There was no significant difference in quality of reduction between the two groups. The mean surgical duration in minimally invasive group was longer than that in open group (59.5±8.9 min vs. 52.2±7.2 min, $P< 0.05$). The mean incision length in minimally invasive group was shorter than that in open group (2.1±0.5 cm vs. 11.6±2.0 cm, $P< 0.05$). In minimally invasive group the mean union time was 3.3±1.1months, no patient complained of paresthesia on subclavicular region, and all patients were satisfied with the cosmesis of the wounds and showed excellent shoulder joint function with a mean Constant-Murley score of 93.8±3.8 at sixth month after the operation. In open reduction group the mean union time was 4.3±0.8months, 8 patients complained of paresthesia on subclavicular region, and only 5 patients were satisfied with the cosmesis of the wounds with a mean Constant-Murley score of 90.6±4.0 at sixth month after the operation. There was a significant difference in statistic by comparing union time, cosmetic result, Constant-Murley score and other complications (P 0.05).

Conclusion: Minimally invasive surgery using distal clavicle anatomic locking plate seems to be a good option for the treatment of midshaft clavicle fractures with satisfactory cosmetic result and excellent return to function.

Background

Clavicle fractures are among the most common fractures in clinical practice. Due to the fairly thin adhesion between the middle and lateral third about 80% of fractures occur in midshaft and half of these fractures will displace[1]. According to Neer's [2] and Row's [3] researches, the conservative treatment for midshaft fractures of the clavicle had a lower nonunion rate than open reduction and internal fixation. Historically nonoperative treatment for midshaft clavicle fractures was one of the few golden rules in orthopaedics.

However, some recent studies [4,5,6] showed that operative treatment of midshaft clavicle fractures had a better result than nonoperative treatment in terms of functional recovery, pain relief, clavicle shortening, and pseudarthrosis rate. Therefore operative treatment for midshaft clavicle fractures was usually recommended under some circumstances.

Although, open reduction and plate fixation has been considered as the golden standard in midshaft clavicle fractures treatment, it may lead to large incision and wide soft tissue stripping which destroy the blood supply of fracture site and result in considerable complications, such as poor cosmetic result, nonunion, paresthesia or infection[7]. To overcome these problems, intramedullary nailing has been widely used to treat displaced midshaft clavicle fractures[8,9]. However, migration of the internal fixation and clavicle shortening were common in comminuted fractures and early exercise was restricted due to its weak fixation strength to resist fracture site motion[10]. And it had been confirmed in a recent published prospective randomized controlled trial that plate fixation is the superior method in dealt with comminuted midshaft clavicle fractures [11]. To eliminate these limitations, we designed a minimally invasive percutaneous plating technique for midshaft clavicle fractures treatment using distal clavicle anatomic locking plate[12,13] and improved it in recent years. The purpose of this study is to report our improved minimally invasive techniques and compare its radiographic and clinical outcomes with that of open reduction and internal fixation.

Materials And Methods

Patient selection

This retrospective comparative study was approved by Medical Research Ethics Committee of our hospital. From Jan 2019 to May 2020, a total of 91 cases were diagnosed as clavicle fractures in our institution. Patients with midshaft clavicle fractures were included and those corresponding to the exclusion criterion were excluded: 1) a patient’s refusal to participate; 2) proximal or distal clavicle fracture; 3) neurovascular injury; 4) open fractures; 5) pathological fractures; 6) fracture seen beyond 2 weeks after the injury; 8).intramedullary nailing fixation. Finally, 58 cases were retrospectively reviewed in this study. According to the surgical technique they were divided into minimally invasive group and open reduction group(Fig.1).

Surgical techniques

Minimally invasive plate osteosynthesis

Under general anaesthesia, the patient was placed in a supine position on a radiolucent operating table. For ease of closed reduction muscle relaxant was always required in our cases. A well-padded adequately sized soft bump was placed between the scapulae. To make sure there was no shelter when the C-arm was used, and was tilted in order to obtain inlet and outlet views, if necessary. The involved shoulder and

the whole upper extremity were prepared and draped in a sterile fashion so that the whole upper extremity was placed in the operative field. This allowed easier intra-operative manipulation and reduction.

After palpating, the proximal end, distal end and fracture site, a suitable distal clavicle anatomic locking plate was selected and placed along the clavicle. The provisional position of the plate was drawn on the skin under an image intensifier（Fig. 2.c）. According to the provisional position of the plate, a 1.0cm-sized oblique incision was performed along the long axial of the clavicle at the center of the distal clavicle end, sharp dissection to the bone and exposing the distal clavicle end. A sub-muscular tunnel along the clavicle was developed with a periosteal elevator and the plate was inserted from the distal incision.

A locking sleeve was placed at the distal end of the plate. The distal plate and segment were fixed in the optimal position with both anterior borders of the plate and distal clavicle end at same horizontal using a K-wire through the locking hole. A tractive force was used through the locking sleeve. After restoration of clavicular length and realignment of the comminuted fragment, we percutaneously fixed the proximal plate and fragment using K-wire through a proximal locking hole to maintain the realignment (Fig. 2.d), and the status of the reduction was confirmed by fluoroscopy (Fig. 2.e).

In some cases the fracture ends were still severely displaced in a “back to back” position after preliminary reduction(Fig. 3.bd). Before inserting the plate we could insert a small hook from the distal incision along the sub-muscular tunnel and fix the hook in the medullary canal of the distal fragment, then using a traction or rotate force to reduce the displacement (Fig. 3.ef), this technique was reported in our previous reach[13].If the gap between distal clavicle and plate was wide after inserting the plate, we could use a conventional screw first to reduce the gap when we fixed the distal plate and segment (Fig. 3.gh). A conventional screw also could be used to reduce the proximal fragment displacement or minimize the gap between the plate and proximal fragment.

In some cases the sharp vertical segment could insert into the surrounding soft tissue. If there was still severely displaced after preliminary reduction(Fig. 5.b). We could insert forceps from the distal incision along the sub-muscular tunnel to clip the vertical segment, then using a traction and rotate force to unlock it (Fig. 5.cde).

The same size and type distal locking plate was used as a guide in proximal percutaneous fixation once an acceptable realignment of the fracture was achieved. A 0.5cm-sized incision was made on proximal site and fixed the proximal segment with the plate using a conventional screw (Fig. 2.f). The proximal K-wire was retrieved with the slide of the skin on clavicle region the proximal segment was fixed using a percutaneous technique through two 0.5cm-sized incisions, and at least three 3.5mm screws were fixed at proximal side of the fracture. The distal segment was fixed using 4-6 2.7mm locking screws.

Following the placement of distal and proximal screws, intra-operative fluoroscopic images were taken again to confirm the good reduction and fixation. Upon satisfactory radiograph, the wound was irrigated, the proximal incisions could be sutured using intradermic suture technique and the lateral incision was

sutured in the standard fashion without a drain (Fig. 4.b, Fig. 5.i). Fluoroscopy times and operation time were also recorded.

Open reduction and plate fixation

Under general anaesthesia, the patient was placed in a supine position on a radiolucent operating table. An incision along the long axial of the clavicle was made after draping and preparation. Supraclavicular nerve was identified and protected. Sharp dissection to the bone and expose the fracture site, the fracture site was reduced and fixed with K-wires after debridement. A good reduction was confirmed by intraoperative fluoroscopy. A suitable distal clavicle anatomic locking plate was selected and fixed the fracture site with both proximal and distal segment at least three screws. Intra-operative fluoroscopic images were taken again to confirm the good reduction and fixation. The incision was sutured using standard fashion without a drain (Fig. 6).

Assessment of outcomes

Baseline characteristics, including age, sex, side, mechanism of injury, Robinson classification, interval from injury to surgery, and follow-up period, were assessed. The fracture pattern was classified according to Robinson classification system [14].

Clinical and radiological outcomes of the technique included reduction quality, union time, and complications. For clinical evaluation, we used the Constant-Murley score [15], which were assessed from pain, daily activities, range of motion and power at sixth month postoperative. Incision length was measured at sixth month postoperative, and the incision length was proximal incision length plus distal incision length in minimally invasive group. The quality of reduction was measured as the proportional difference in clavicle length between the injured and uninjured side [16]. An anteroposterior view X-ray was taken at the latest follow-up to reveal shortening of the clavicle. The radiographs were examined for evidence of fracture healing, short displacement or implant failure. Fracture healing was defined clinically and radiographically as the absence of pain and visible callus on anteroposterior X-ray plain. Radiographs were read by an independent examiner blinded to the study details in order to verify the short displacement and state of the bone union. Complications, such as nonunion, postoperative infection, and major neurovascular injury, were assessed.

Statistical analyses of the data were performed by an independent statistician blinded to clinical outcomes using the Statistical Package for the Social Sciences (SPSS), version 20.0 (SPSS, Inc., Chicago, IL, USA). All quantitative variables were expressed as means and standard deviation (SD) and paired student's t tests were used to analyze the difference. Categorical variables were shown as number and percentages (%) and tested by the chi-squared test. Statistical significance was defined at the level of $P < 0.05$.

Results

The baseline characteristics of the two groups are presented in Table 1. The minimally invasive group consisted of 30 patients (22 males, 8 females) and the open reduction group consisted of 28 patients (22 males, 6 females). There were no statistically significant differences in the demographics and fracture classifications between the minimally invasive group and the open reduction group.

In minimally invasive group the average proportional difference of the clavicular length was 12.0±2.0% preoperative and 0.4± 0.4% postoperative comparing with the opposite healthy side, in open reduction group the average proportional difference of the clavicular length was 11.6±1.9% preoperative and 0.4±0.1% postoperative comparing with the opposite healthy side. There was no significant difference in quality of reduction by comparing the fracture reduction in these two groups(p 0.05). The mean surgical duration in minimally invasive group was longer than that in open group (59.5±8.9 min vs. 52.2±7.2 min, P< 0.05). The mean incision length in minimally invasive group was shorter than that in open group (2.1±0.5 cm vs. 11.6±2.0 cm, P< 0.05). In minimally invasive group the mean union time was 3.3±1.1months, no patient complained of paresthesia on subclavicular region, and all patients were satisfied with the cosmesis of the wounds and showed excellent shoulder joint function with a mean Constant-Murley score of 93.8±3.8 at sixth month after the operation. In open reduction group the mean union time was 4.3±0.8months, 8 patients complained of paresthesia on subclavicular region, and only 5 patients were satisfied with the cosmesis of the wounds with a mean Constant-Murley score of 90.6±4.0 at sixth month after the operation. One patient had superficial infection in both groups. There was a significant difference in statistic by comparing union time, cosmetic result, Constant-Murley score and other complications (P 0.05). No perioperative complications, such as neurovascular injury or pneumothorax happened. Details are presented in Table 2.

Table 1

Baseline characteristics of the Minimally invasive group and Open reduction groups.

	Minimally invasive group(n=30)	Open reduction group(n=28)	P-value
Sex			
Male	22□73%□	22□79%□	0.299
Female	8□27%□	6□21%□	
Side			0.695
Right	20□67%□	20□71%□	
Left	10□33%□	8□29%□	
Mechanism of injury			0.849
Low-energy trauma	10□33%□	8□29%□10	
High-energy trauma	20□67%□	20□71%□18	
Robinson classifification			0.723
Type 2A2	3□10%□	3□11%□	
Type 2B1	19□63%□	20□71%□	
Type 2B2	8□27%□	5□18%□	
Interval from injury to surgery	3.5±1.1	3.2±1.1	0.449
Follow-up period□months□	19.5±3.5	18.8±3.6	0.208

Table 2

Radiological and clinical outcome of Minimally invasive group and Open reduction groups.

	Minimally invasive group(n=30)	Open reduction group(n=28)	P-value
Surgical duration（min）	59.5±8.9	52.2±7.2	0.001
Quality of reduction			
Preoperative short displacement	12.0±2.5%	11.6±1.9%	0.517
Postoperative short displacement	0.4±0.4%	0.4±0.1%	0.136
Union time（months）	3.3±1.1	4.3±0.8	0.000
Constant-Murley score	93.8±3.8	90.6±4.0	0.003
Cosmetic result			
Incision length（cm）	2.1±0.5	11.6±2.0	0.000
Satisfied with cosmetic result	30（100%）	5（19%）	<0.000
Other complications			0.035
Paresthesia on subclavicular region	0（0）	8（29%）	
Postoperative infection	1（3%）	1（4%）	
Nonunion	0（0）	0（0）	

Discussion

Currently the optimal treatment for displaced midshaft clavicle fractures is still controversial. Although operation is usually recommended for midshaft clavicle fractures under certain circumstances[17], it has been realized that surgery is the main reason of infection or nonunion because of extensive soft tissue dissection around the fracture site[18]. In order to reduce the complications of open reduction and internal fixation, minimally invasive plating technique was developed and widely used to treat long bone shaft fractures and has received good clinical results, especially for comminuted fractures[19,20]. Because of technical difficulties of closed reduction and its complex anatomical features (S-shaped curvature) which makes it hard to be tightly fit, performing plate fixation in midshaft clavicle fractures using minimally invasive technique is more difficult. Therefore, for midshaft clavicle fractures, the minimally invasive plating technique is rarely used. According to anatomic research and the theory of closed reduction used in conservative treatment, we have designed an indirect reduction technique for midshaft clavicle fractures using distal clavicle anatomic locking plate [12,13] that enabled the surgeon to achieve an adequate reduction and fixation without wide soft tissue stripping.

Clavicle has different muscle attaching at different part of the shaft. Most of the fractures will displace under the different deforming forces on the proximal and distal segment. The proximal segment will have

upward and backward displacement because of the pulling of sternocleidomastoid muscle. The distal fragment will have inferior displacement because of the downward dragging caused by the weight of upper extremity[21]. Additionally, the pectoralis major muscle pulls the distal segment medially which cause short displacement. General anaesthesia and muscle relaxants to make sternocleidomastoid muscle and pectoralis major muscle relaxed decreases the pulling force which eased fracture reduction. In our minimally invasive technique supine position eliminates the affect of the weight of upper extremity can partially correct fracture displacement. An adequately sized bump is placed between the scapulae to make the back straight and keep the shoulder joints on an abduction position, which will primarily correct the short displacement. With external traction through the distal locking sleeve and upper extremity the short displacement could be precisely reduced. In some cases still have “back to back” position or vertical segment displacement after closed reduction which also can be easily corrected using an indirect reduction technique with the help of a small hook or forceps. After intra-operative traction on the locking sleeve the reduced state of short displacement is maintained with the placement of a K-wire through the proximal locking hole. In order to achieve a good reduction conventional screw can be placed distal or proximal to the fracture line to minimize the gap between the plate and fragment. In our minimally invasive group most of the cases had anatomic reduction, the average proportional difference in length of the clavicle improved from 12.0±2.0% preoperative to 0.4± 0.4% postoperative between the affected and unaffected side, and there was no significant difference in quality of fracture reduction when comparing with the open group which average proportional difference in length of the clavicle improved from 12.0±2.0% preoperative to 0.4± 0.1% postoperative(p 0.05). Technical errors such as poor positioning of the plate (too anterior or posterior) must be avoided to achieve a good outcome. The optimum position of the plate is with its distal anterior border and the anterior clavicle border on the same plane.

In our minimally invasive technique the anatomic locking plate was originally designed for distal clavicle fractures. It is an anatomically precontoured plate that fits the S-shape morphology and facilitates optimal implant placement. It can exactly match the clavicle’s anatomical feature and does not need any contouring. It is available in 4 lengths (92, 104, 116 and 128 mm) and has 2 locking screw hole sizes (3.5 mm on the shaft portion and 2.7 mm on the distal portion). The direction of the locking screw holes are in multiple directions which maximizes bone purchase and increases resistance to pullout forces compared with screws placed perpendicular to the plate. Unlike conventional locking plates, the distal locking screw holes are angled, which maximize pullout strength and improve overall plate stability regardless of bone quality especially in a small distal clavicle bone. Using this locking plate, the distal segment can be fixed at least eight to twelve cortices with four to six 2.7 mm multidirectional locking screws, and the proximal segment is also fixed with one 3.5mm conventional screw and two 3.5mm locking screws. Due to the rigid fixation patients were encouraged to begin early functional exercise which prevents joint stiffness. In minimally invasive group the mean Constant-Murley score was 93.8±3.8 at sixth month after the operation, and there was a significant difference when comparing with the open group with a mean Constant-Murley score of 90.6±4.0. (P 0.05)

Because of supraclavicular nerve injury the rate of incisional and proximal chest wall numbness was reported 10% to 29% after operative fixation of the clavicle [22,23]. Nathe T et al. [24] dissected 37 cadavers, found there were two or three branches of the supraclavicular nerve crossing the clavicle 97% of the time and no branch was found within 1.9cm of the acromioclavicular joint. In our minimally invasive technique the distal 1.0cm-size incision is located in this safe zone, and the rate of supraclavicular nerve injury in the two proximal percutaneous incisions is also rare. There were no clavicle region paresthesia or numbness was observed in this group. In open group there were 8 patients reported paresthesia or numbness because of supraclavicular nerve injury which was accordance with previous reports[22,23].

The minimally invasive group has a much smaller incision length（2.1±0.5 cm）when compared with open group（11.6±2.0 cm）, and the obscure scar also had a better cosmetic results in comparing with other reported minimally invasive plating techniques from their typical case pictures[25,26,27,28,29].

When the minimally invasive plating technique with distal anatomic locking plate is used to treat midshaft clavicle fractures, periosteal stripping can be minimized which promote fracture union. In the current study all fractures healed within an average period of 3.3±1.1months, which was shorter when comparing with open group（4.3±0.8months）. This might be not only because of periosteal circulation could be preserved with the minimization of the soft tissue stripping using percutaneous technique but also a good reduction could be well maintained through a rigid fixation. Minimally invasive surgery using distal clavicle anatomic locking plate seems to be a good option for the treatment of midshaft clavicle fractures with satisfactory cosmetic result and excellent return to function. It keeps soft tissue envelope, periosteum, and vascular integrity of fracture site, decreasing infection rates and enhancing fracture callus formation. In addition, this technique had an advantage of not requiring a special instrument and ease of performance.

There are some limitations to the present study. First, the relatively small number of cases may limit statistical reliability. Second, we have selection bias because the selection of the technique was not randomized. Third, the present study cannot prove the superiority of minimally invasive group over open group in terms of surgical duration. However, with relatively short union time, good cosmetic result and less complications we believe that comparable results can be meaningful.

Conclusion

Minimally invasive surgery using distal clavicle anatomic locking plate seems to be a good option for the treatment of midshaft clavicle fractures with satisfactory cosmetic result and excellent return to function.

Declarations

- Consent for publication

Not applicable

- Competing interests

The authors declare that they have no competing interests.

- Funding

Zhejiang Province Public Welfare Technology Application Research Project (Award Number: LGF20H060008)

- Authors' contributions

All authors have contributed significantly to the study design, date collections, date analysis, writing the whole process.

References

1. Yang S, Andras L. Clavicle Shaft Fractures in Adolescents. Orthop Clin North Am 2017; 48: 47-58.
2. Neer CS II. Nonunion of the clavicle. J Am Med Assoc 1960; 5: 1006-11.
3. Rowe CR. An atlas of anatomy and treatment of midclavicular fractures. Clin Orthop Relat Res 1968; 58: 29-42.
4. Ahrens PM, Garlick NI, Barber J, Tims EM. The Clavicle Trial: A Multicenter Randomized Controlled Trial Comparing Operative with Nonoperative Treatment of Displaced Midshaft Clavicle Fractures. J Bone Joint Surg Am 2017; 99: 1345-54.
5. Woltz S, Krijnen P, Schipper IB. Mid-Term Patient Satisfaction and Residual Symptoms After Plate Fixation or Nonoperative Treatment for Displaced Midshaft Clavicular Fractures. J Orthop Trauma 2018; 32: e435-39.
6. Qvist AH, Væsel MT, Jensen CM, Jensen SL. Plate fixation compared with nonoperative treatment of displaced midshaft clavicular fractures: a randomized clinical trial. Bone Joint J 2018; 100-B: 1385-91.
7. Leroux T, Wasserstein D, Henry P, Khoshbin A, Dwyer T, Mamhomed N, et al. Rate of and Risk Factors for Reoperations After Open Reduction and Internal Fixation of Midshaft Clavicle Fractures: A Population-Based Study in Ontario, Canada. J Bone Joint Surg Am 2014; 96: 1119-25.
8. Fu B. Minimally invasive intramedullary nailing of clavicular fractures by a new titanium elastic nail. Acta Orthop Traumatol Turc 2016; 50: 494-500.
9. Smekal V, Irenberger A, Attal RE, Oberladstaetter J, Krappinger D, Kralinger F. Elastic stable intramedullary nailing is best for mid-shaft clavicular fractures without comminution: results in 60 patients. Injury 2011; 42: 324-29.

10. Eickhoff A, Fischer M, Gebhard F, Ehrnthaller C. Komplikationen nach intramedullärer Stabilisierung von Klavikulafrakturen. Complications after intramedullary stabilization of clavicle fractures. Unfallchirurg 2018; 121: 810-16.
11. Fuglesang HFS, Flugsrud GB, Randsborg PH, Oord P, Benth JS, Utvag SE. Plate fixation versus intramedullary nailing of completely displaced midshaft fractures of the clavicle. Bone Joint J 2017; 99-B: 1095–101.
12. Dong WW, Zhao X, Mao HJ, Yao LW. Minimally-invasive internal fixation for mid-lateral 1/3 clavicle fracture with distal clavicular anatomic locking plate. China Journal of Orthopaedics and Traumatology 2019; 32: 28-32.
13. Dong WW, Mao HJ, Shi ZY, Yao LW, Wu ZT. Mini-invasive percutaneous plating of midshaft clavicle fractures with locking plate. Chin J Orthop 2020; 40: 1601-11.
14. Robinson CM. Fractures of the clavicle in the adult. Epidemiology and classification. J Bone Joint Surg Br 1998; 80: 476-84.
15. Constant CR, Murley AH. A clinical method of functional assessment of the shoulder. Clin Orthop Relat Res 1987; 214: 160-64.
16. Smekal V, Deml C, Irenberger A, Niederwanger C, Lutz M, Blauth M, et al. Length determination in midshaft clavicle fractures: validation of measurement. J Orthop Trauma 2008; 22: 458-62.
17. Burnham JM, Kim DC, Kamineni S. Midshaft Clavicle Fractures: A Critical Review. Orthopedics 2016; 39: e814-21.
18. Singh A, Schultzel M, Fleming JF, Navarro RA. Complications after surgical treatment of distal clavicle fractures. Orthop Traumatol Surg Res 2019; 105: 853-59.
19. Dong WW, Shi ZY, Liu ZX, Mao HJ. Indirect reduction technique using a distraction support in minimally invasive percutaneous plate osteosynthesis of tibial shaft fractures. Chin J Traumatol 2016; 19: 348-52.
20. Zhang YZ. Minimally Invasive Reduction and Fixation in Orthopedic Trauma. Chin Med J (Eng) 2016; 129: 2521-23.
21. Smekal V, Oberladstaetter J, Struve P, Krappinger D. Shaft fractures of the clavicle: current concepts. Arch Orthop Trauma Surg 2009; 129: 807-15.
22. Li R, Ke T, Xiong S, Xiong G, Lin Z, Lin F. Comparison of the effectiveness of oblique and transverse incisions in the treatment of fractures of the middle and outer third of the clavicle. J Shoulder Elbow Surg 2019; 28: 1308-15.
23. Erdoğan M, Desteli EE, Ímren Y, Kiliç M, Ulusoy S, Varli A. Supraclavicular neuropathy after surgical treatment of clavicular fractures: comparison of two incisions. Acta Chir Orthop Traumatol Cech 2014; 81: 387-91.
24. Nathe T, Tseng S, Yoo B. The anatomy of the supraclavicular nerve during surgical approach to the clavicular shaft. Clin Orthop Relat Res 2011; 469: 890-94.

25. Jung GH, Park CM, Kim JD. Biologic fixation through bridge plating for comminuted shaft fracture of the clavicle: technical aspects and prospective clinical experience with a minimum of 12-month follow-up. Clin Orthop Surg 2013; 5:327-33.
26. Lee HJ, Oh CW, Oh JK, Yoon JP, Kim JW, Na SB, et al. Percutaneous plating for comminuted midshaft fractures of the clavicle: a surgical technique to aid the reduction with nail assistance. Injury 2013; 44: 465-70.
27. Zhang T, Chen W, Sun J, Zhang Q, Zhang Y. Minimally invasive plate osteosynthesis technique for displaced midshaft clavicular fracture using the clavicle reductor. Int Orthop 2017; 41: 1679-83.
28. Jiang H, Qu W. Operative treatment of clavicle midshaft fractures using a locking compression plate: comparison between mini-invasive plate osteosynthesis (MIPPO) technique and conventional open reduction. Orthop Traumatol Surg Res 2012; 98: 666-71.
29. Wang X, Wang Z, Xia S, Fu B. Minimally invasive in the treatment of clavicle middle part fractures with locking reconstruction plate. Int J Surg 2014; 12: 654-58.

Figures

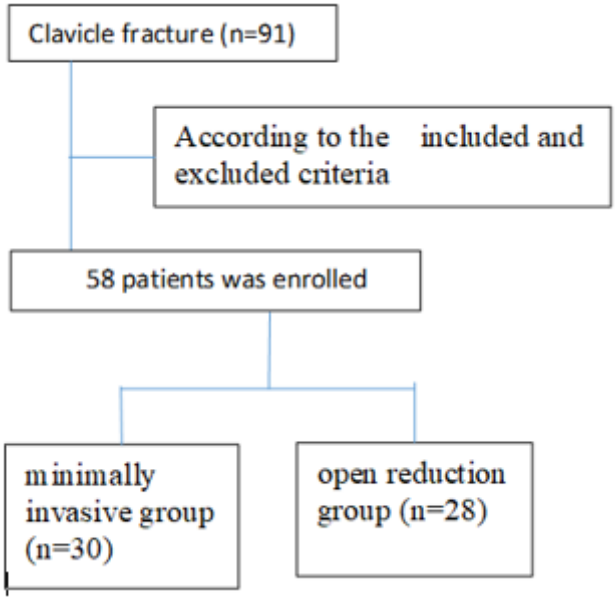

Figure 1

Flow diagram of patient enrollment and grouping.

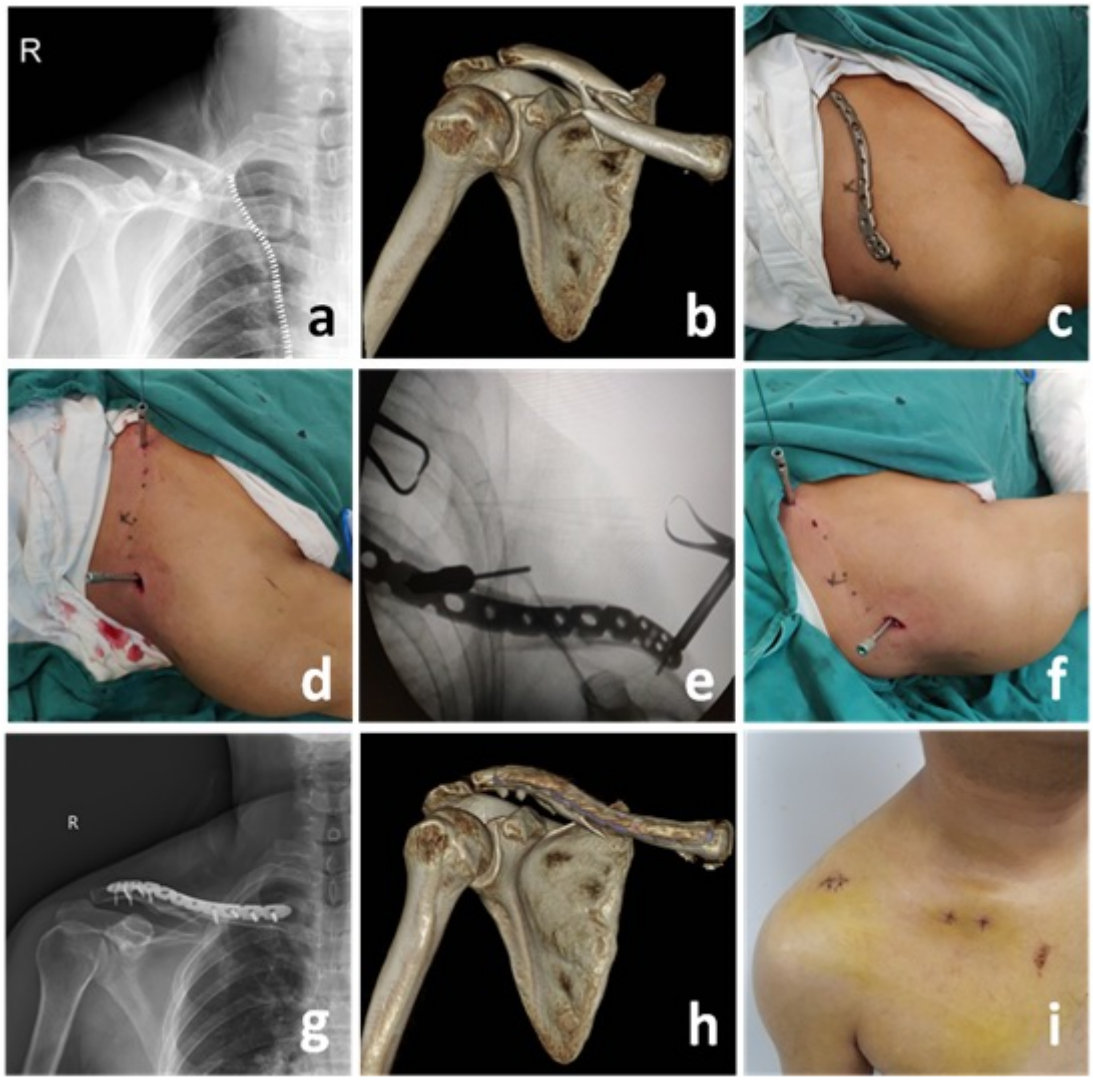

Figure 2

A forty-two years old man suffered right midshaft clavicle fracture because of car accident. **a**. The fracture site was smashed with severely short displacement on anteroposterior x-ray. **b**. Preoperative CT scan showed fracture site was segmental and smashed. It was type 2B2 according to Robinson classification. **c**. He had a minimally invasive plating treatment two days later. A suitable distal clavicle anatomic locking plate was selected and placed along the clavicle. The provisional position of the plate was drawn on the skin under an image intensifier. **d**. A distal clavicle anatomic locking plate was inserted and fixed percutaneously with a K-wire on proximal segment. **e**. Intraoperative fluoroscopy confirmed a good reduction and plate position. **f**. A 0.5cm percutaneous incision was made on proximal site and fixed the proximal segment with the plate using a conventional screw. **g**. Intraoperative fluoroscopic images were taken again to confirm the good reduction and fixation. **h**. One day postoperative CT scan showed a good reduction and plate fixation. **i**. The wound had a good recovery seven days postoperative.

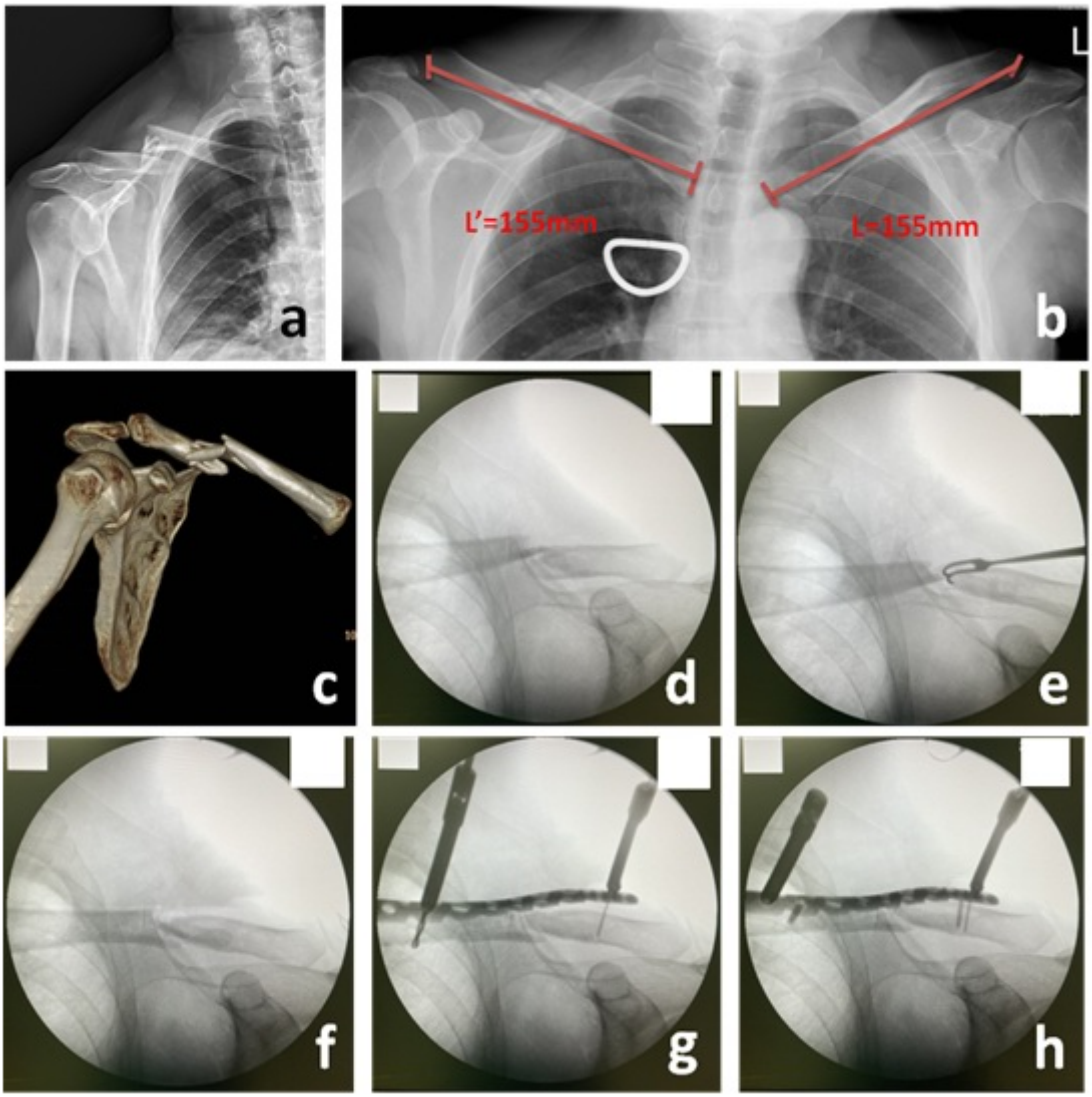

Figure 3

A thirty-seven years old man had right midshaft clavicle fracture because of e-bike accident. **a.** Anteroposterior X-ray showed fracture site was severely displaced with short displacement. **b.** The short displacement was corrected using figure 8 bandage fixation with 0 proportional difference in length of the clavicle(L-L'/L: 155-155/155), While the fracture site was still displaced in a "back to back" locking position. **c.** Fracture site was smashed from CT scan and it was type 2B2 according to Robinson classification. **d.** Two days later the patient received a minimally invasive plating treatment. Intraoperative fluoroscopy showed the fracture ends were still displaced in a "back to back" position after preliminary reduction. **e.** A small hook was inserted to correct the displacement using a traction force. **f.** Intraoperative fluoroscopy confirmed the "back to back" position was unlocked. **g.** The status of reduction was maintained using percutaneously fix proximal and distal segment with the plate, while there was a gap between distal clavicle and the plate. **h.** A conventional screw was used to reduce the gap between distal plate and segment.

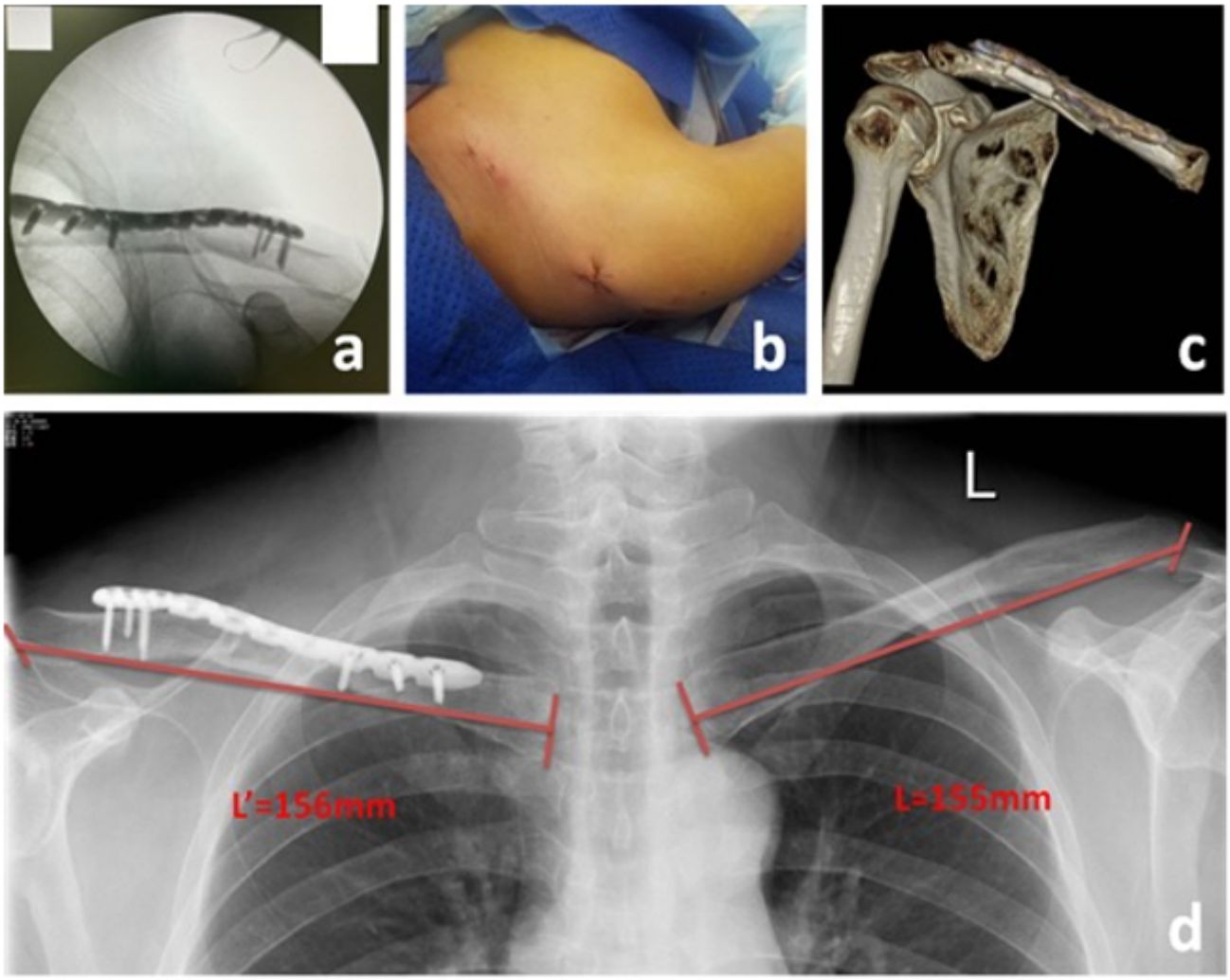

Figure 4

a. Intraoperative fluoroscopic images were taken again to confirm the good reduction and fixation. **b.** The distal incision was sutured with one stitch and two small proximal incisions were sutured with intradermic suture technique. **c.** Postoperative CT scan showed a good reduction and plate fixation. **d.** Postoperative x-ray showed a good reduction and fixation with -0.6% proportional difference in length of the clavicle(L-L'/L: 155-165/155).

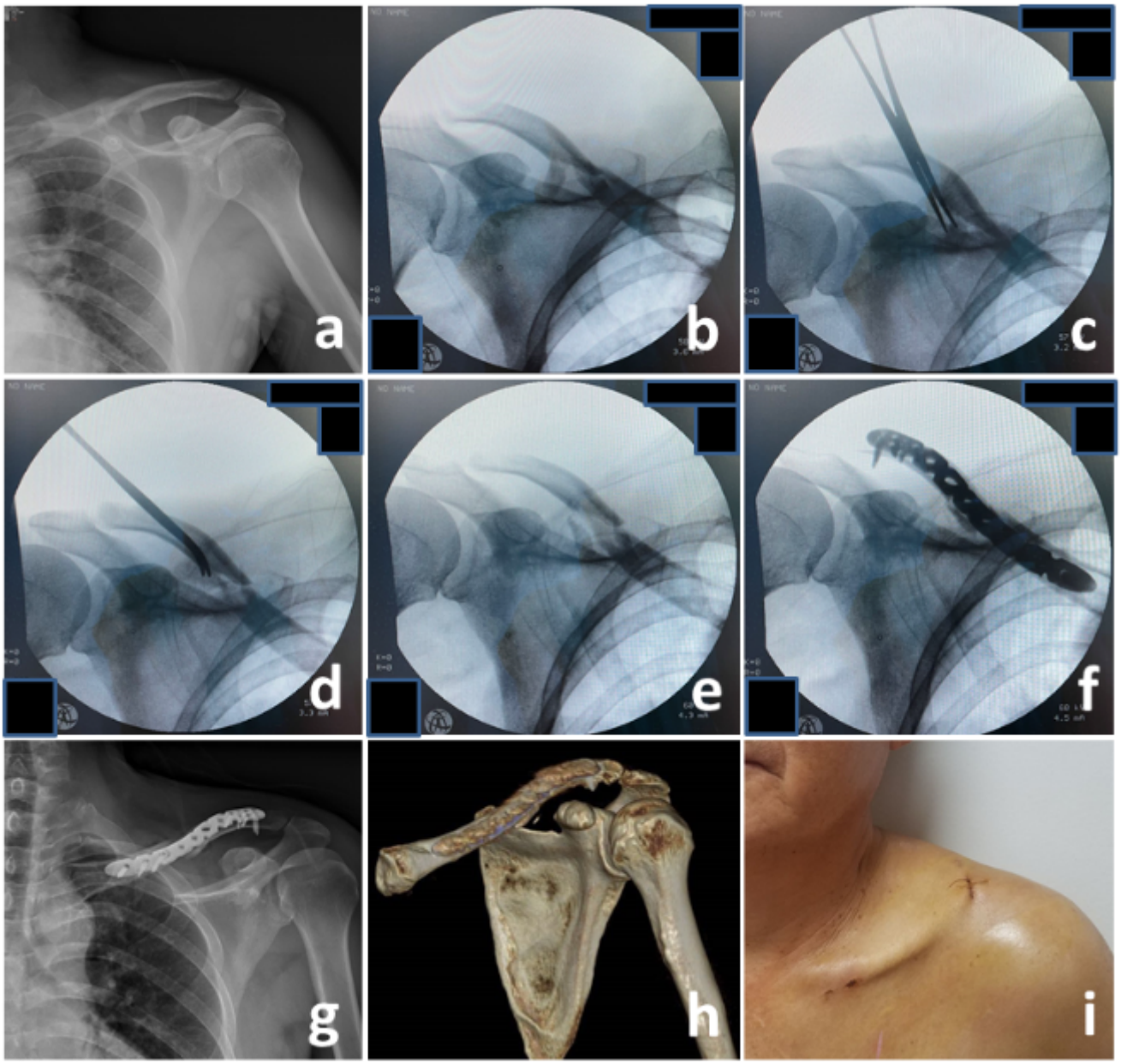

Figure 5

A fifty-nine year old man had a left clavicle fracture because of work related accident, he was hospitalized and received a minimally invasive plating treatment two days later. **a.** X-ray showed a left midshaft clavicle fracture, the fracture site was smashed with a vertical segment. It's a type 2B2 fracture according to Robinson classification. **b.** Intraoperative fluoroscopy showed the vertical segment was still severely displaced after preliminary reduction. **c.** A forceps was inserted from the distal incision along the sub-muscular tunnel and clipped the vertical segment. **d.** Intraoperative fluoroscopic images showed the vertical segment was unlocked maintaining with a traction and rotate force. **e.** Intraoperative fluoroscopic images confirmed the vertical segment was alignment without the maintaining force. **f.** Intraoperative fluoroscopic images were taken to confirm the good reduction and fixation. **g.h.** Postoperative x-ray and CT scans showed a good reduction and internal fixation. **i**. The wound had a good recovery seven days postoperative.

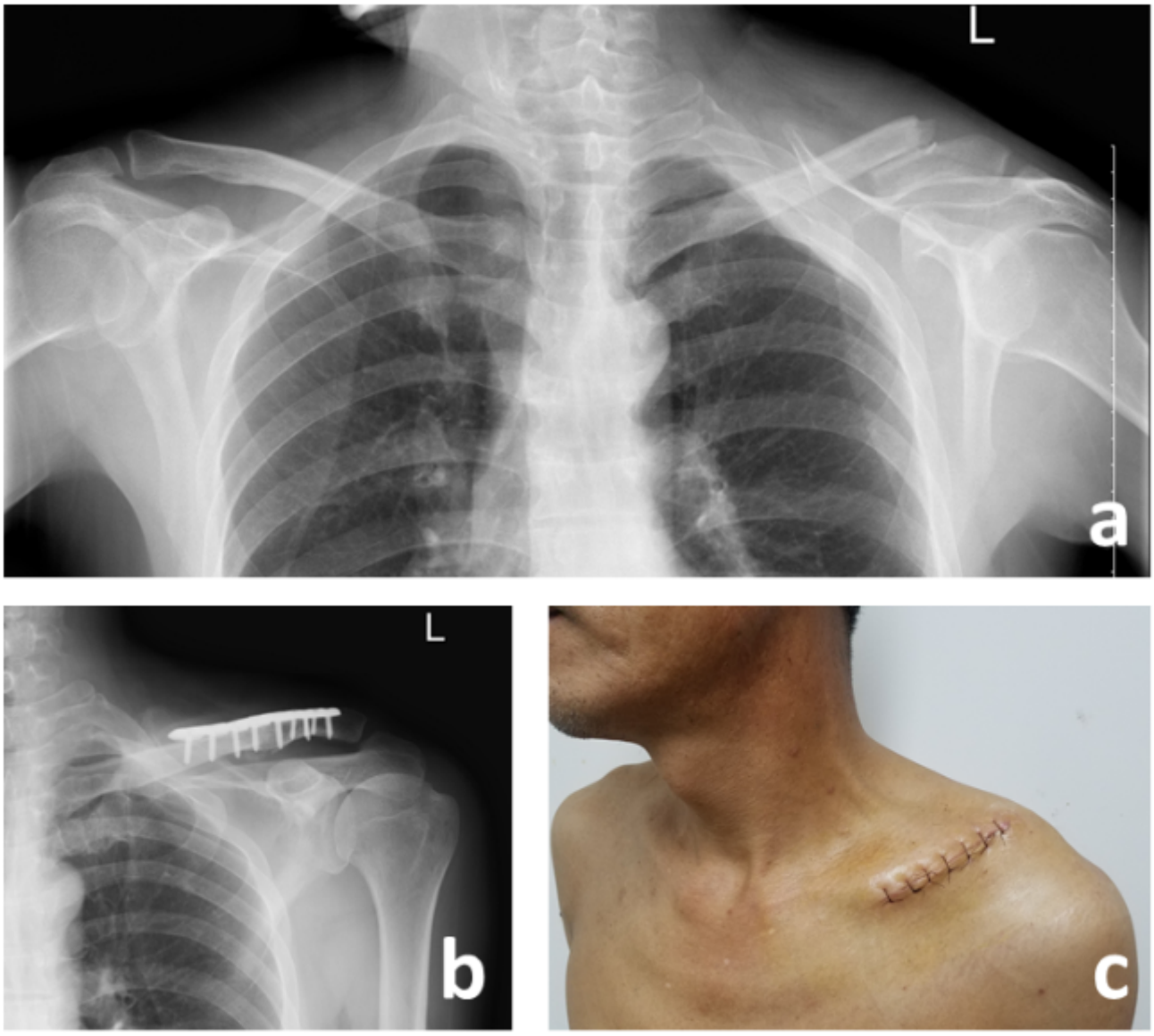

Figure 6

A forty-seven year old man had a left clavicle fracture because of work related accident, he was hospitalized and received an open reduction and plate fixation treatment two days later. **a.** X-ray showed a left midshaft clavicle fracture, the fracture site was total displaced with a short displacement. It's a type 2B1 fracture according to Robinson classification. **b.** Postoperative x-ray showed a good reduction and internal fixation after open reduction and plate fixation treatment. **c.** The incision was sutured in a stand fashion. The wound had a good recovery seven days postoperative.