Does intra-articular injection of adipose-derived stem cells improve cartilage mass? A case report on a 3D MRI quantitative evaluation of cartilage in knee osteoarthritis using SYNAPSE VINCENT: a case report

Ayano Kuwasawa (rmoinfo2@n-place.co.jp)
Saitama Cooperative Hospital
Kotaro Nihei
Saitama Cooperative Hospital

Case Report

Keywords: Case Report, Knee osteoarthritis, Adipose-derived Stem Cell, Mesenchymal stem cells, Magnetic resonance imaging, Act on issue repair, Quantification of cartilage

Posted Date: December 24th, 2020

DOI: https://doi.org/10.21203/rs.3.rs-131250/v2

Does intra-articular injection of adipose-derived stem cells improve cartilage mass? A case report on a 3D MRI quantitative evaluation of cartilage in knee osteoarthritis using SYNAPSE VINCENT: a case report

Ayano Kuwasawa[1*]、Kotaro Nihei[1]

[1] Saitama cooperative hospital. 1317 Kizoro, Kawaguchi, Saitama, 333-0831, Japan

*Corresponding author

Ayano Kuwasawa, M.D., Ph.D

Saitama cooperative hospital

1317 Kizoro, Kawaguchi, Saitama, 333-0831, Japan

TEL: +81-570-00-4771, FAX: +81-48-296-7182

Abstract:

Background: Mesenchymal stem cells (MSC) are currently in focus because of the possibility of cartilage regeneration through several ways, including MSC sheets. However, there is no published report that visualizes cartilage in three dimensions. Here, we report a case of improved cartilage volume. We purified and cultured adipose-derived mesenchymal stem cells (ASC) and then performed ASC therapy by directly injecting these cells into the articular cartilage. Cartilage was quantitatively evaluated before and after injection using a three-dimensional (3D) image analysis software based on the MRI imagery.

Case presentation: The patient, a 55-year-old woman, experienced pain in both knees and was diagnosed with osteoarthritis of the knee. We performed ASC therapy in both knees at our hospital and quantitatively evaluated cartilage before and after the treatment using the 3D image analysis software "SYNAPSE VINCENT".

Conclusions: For the quantitative analysis of cartilage, SYNAPSE VINCENT visualizes the state of cartilage in a high-definition 3D image, which is excellent for understanding the state of the disease and explaining it to the patient. Though there is room for debate about the reproducibility of errors, etc., SYNAPSE VINCENT would be useful as a clinical tool for regenerative medicine.

Keywords: Case Report, Knee osteoarthritis, Adipose-derived Stem Cell, Mesenchymal stem cells, Magnetic resonance imaging, Act on issue repair, Quantification of cartilage

38 Background

39 Osteoarthritis (OA), which is different from trauma, is a disease that is caused by
40 dysplasia and malalignment. In OA, deterioration and wear of cartilage, which are associated
41 with synovitis, progress over time. The number of patients with OA of the knee in Japan
42 (diagnosed by X-ray) is estimated to be about 25.30 million (8.6 million males and 16.7
43 million females), and the number of symptomatic patients is estimated to be about 8 million
44 (a large-scale epidemiologic survey ROAD) [1]. In addition, 11% of the main causative
45 diseases requiring care for those aged 65 years or older were caused by joint diseases (Cabinet
46 Office White Paper on Aging Society 2017) [2]. OA reduces the patients' quality of life and
47 daily living activities, leading to the shortening of healthy life expectancy.

48

49 According to the guidelines, the optimal management of OA of the knee requires a
50 combination of non-drug therapy and drug therapy [3]. However, regenerative medicine cell
51 therapy, including platelet-rich plasma (PRP) therapy, has recently become widespread and
52 gathered attention as the third type of treatment. As a method of using somatic stem cells, we
53 perform adipose-derived mesenchymal stem cell (ASC) therapy in the hospital, where
54 adipose-derived mesenchymal stem cells (MSCs) are purified, cultured, and injected into the
55 joint. To initiate regenerative medicine using ASCs, a medical institution is required to submit

56 “a plan for regenerative medicine, etc. based on the article 4, paragraph 1 of the regenerative
57 medicine safety assurance law” to the Ministry of Health, Labour and Welfare in Japan. At
58 our hospital, our application protocol, titled “joint treatment by administration of adipose
59 tissue-derived stem cells”, has received approval since April 2018.
60
61 Transplantation of ASCs is one of mesenchymal stromal stem cell-based therapies. This
62 can be performed in two ways: one is a method of extracting and culturing only ASCs for
63 transplantation, called adipose-derived MSC; another is a method of treating adipose tissue
64 with an enzyme to separate a stromal vascular cell group from other fat cells, which is then
65 used for transplantation, called stromal vascular fraction (SVF). Although SVF is not common
66 in Japanese hospitals, a cohort study of patients with knee OA who underwent ASC or SVF
67 showed that there were no serious side effects in both groups and that ASC groups had less
68 adverse events associated with fat collection [4]. This is likely due to the fact that ASCs can
69 be cultured by collecting a small amount of fat with local anesthesia. Additionally, compared
70 to SVF, though it takes longer to prepare (about 6 weeks), ASCs can be cryopreserved. Indeed,
71 the survival rate of ASCs from freeze to thaw is 96.7% when frozen and 83.5% when thawed;
72 thus, more than 80% of stem cells can act in the joint. Moreover, by injecting MSCs, a factor
73 secreted by stem cells affects the environment in the joint and is expected to act on tissue

74 repair (paracrine effect).

75

76 About 20 mL of adipose tissue used for ASC preparation is collected from the patient
77 by a clean operation using a cannula and syringe at Saitama cooperative hospital. The syringe
78 filled with the collected adipose tissue is enclosed in a biohazard bag, packed with a cushioning
79 material, and then shipped to the CellSource Regenerative Medicine Center, a manufacturer
80 of specific cell processed products in Shibuya-ku, Tokyo. After the subculture, ASCs are
81 delivered to our hospital in a frozen state on the day of their scheduled administration and
82 used for the treatment of OA once thawed.

83

84 Quantification of cartilage was performed before and after treatment using Fujifilm's
85 3D image analysis system "SYNAPSE VINCENT," which can convert 2D images produced
86 by an magnetic resonance imaging (MRI) into high-quality 3D images, and used to confirm
87 the adaptation of autologous cartilage jack during the transplantation of ASCs.

88

89 This is the first case report of ASC therapy for a patient with knee OA at Saitama cooperative
90 hospital.

91

92 Case presentation:

93 Patient: 55 years old, female

94 Medical history

95 In 2013, due to pain in both knees, she visited our hospital and was diagnosed with OA of the

96 knee.

97 In December 2017, while playing tennis, the right knee developed a knee collapse. She was

98 examined at the hospital, and an MRI of the right knee was performed. Horizontal dissection

99 of the lateral meniscus and cartilage defect on the lateral condyle of the femur were observed.

100 Since 2018, injection of hyaluronic acid has been continued every 2 weeks, but joint edema

101 and pain recurrence have been remitted.

102 In April 2018, MRI of the right knee was performed. A cartilage defect was found in the

103 external condyle of the femur, and the patient desired ASC transplantation.

104 On April 28, 2018, 20 mL ASCs were collected from the abdomen.

105 On June 11, 2018, the first ASC transplantation was performed on the right knee.

106 On July 2, 2018, although the effect was experienced after 1 week of treatment, the pain

107 recurred when the subject moved violently.

108 On August 6, 2018, the patient was in a good condition. When the Timed Up and Go Test

109 was conducted, it showed improvement from 10 seconds to 7 seconds.

On September 10, 2018, the patient was in a good condition. She resumed playing tennis and was living almost without pain.

On December 10, 2018, an MRI was performed. There was no pain even when the subject jumped on one leg and a repaired cartilage defect was observed.

On April 22, 2019, the second ASC transplant was performed on the right knee and the first ASC transplant was performed on the left knee.

On June 22, 2019, there was a slight fever on the day of the procedure.

On August 5, 2019, the patient was in a good condition. It became possible to assume a sitting position.

121 Results:

122 Before the operation, the cartilage defect area was 33.59 mm^2 in the femur and 122.31

123 mm^2 in the tibia; however, 6 months after the operation, it improved to 4.59 mm^2 in the femur,

124 34.48 mm^2 in the tibia, and 12 months after the operation, it improved to 13.59 mm^2 in the

125 femur and 51.43 mm^2 in the tibia. The bone volume before the procedure was 9.58 mL for the

126 femur and 3.82 mL for the tibia; however, 6 months after the procedure, it improved to 10.36

127 mL for the femur and 4.00 mL for the tibia, and 12 months after the procedure, it improved

128 to 10.00 mL for the femur and 4.17 for the tibia (Figure 1, 2, Table 1).

129

130 Discussion and Conclusions:

131 In this case, ASC therapy not only reduced pain but also regenerated the cartilage defect.

132 The side effects were temporary and minor. The reason for the temporary and minor side

133 effects was considered to be the minimal invasion of fat collection and the low burden on the

134 patient.

135

136 The reason for regeneration of the cartilage defect area in this case is considered to be

137 that the paracrine effect of the stem cells affected existing surrounding cells in the joint and

138 repaired cartilage around the defect area. In addition, conditions that enable repair of a

139 cartilage defect include the presence of chondrocytes (a limited defect), a small defect, good
140 alignment, and low mechanical stress.
141
142 Although there is a published report stating that a capsule was formed by PRP and stem
143 cell transplantation, there is no published report that states that cartilage regeneration was
144 observed by stem cell transplantation in humans. This case shows an increase in the amount
145 of cartilage by directly injecting MSCs into joints.
146
147 It is believed that the results of this study were obtained due to the usefulness of
148 SYNAPSE VINCENT as a diagnostic method, our technical skills, and the culture methods of
149 ASCs. SYNAPSE VINCENT enables the quantitative analysis of cartilage, providing 3D
150 visualization of the state of cartilage in an easy-to-understand manner, which is excellent for
151 understanding the state of the disease and explaining it to the patient. Although there might
152 be room for debate about the reproducibility of errors, etc., SYNAPSE VINCENT would be
153 useful as a clinical tool for regenerative medicine.
154
155

156 Abbreviations

157 3D: Three-dimensional; ASC: Adipose-derived mesenchymal stem cells; MRI: magnetic

158 resonance imaging; MSC: Mesenchymal stem cells; OA: Osteoarthritis; PRP: platelet-rich

159 plasma; SVF: stromal vascular fraction.

160

161 Acknowledgements

162 Not applicable.

163

164 Author's contribution

165 AK wrote the manuscript. KN reviewed the manuscript and gave suggestions as a

166 supervisor. All authors read and approved the final manuscript.

167

168 Funding

169 None.

170

171 Availability of data and materials

172 Not applicable.

173

Ethics approval and consent to participate

Ethics approval was obtained from the Saitama cooperative hospital.

Consent for publication

Written informed consent was obtained from the patient for publication of this case report and any accompanying images.

Competing interests

The authors declare no competing interests regarding the publication of this article.

Author details

[1] Saitama cooperative hospital

References

[1] Yoshimura N, Muraki S, Oka H, Kawaguchi H, Nakamura K, Akune T. Cohort Profile: Research on Osteoarthritis/Osteoporosis Against Disability Study. Int J Epidemiol. 2010 Aug;39(4):988-995.

[2] Annual Report on the Aging Society, Cabinet Office, Government of Japan (2017).

[3] Bannuru RR, Osani MC, Vaysbrot EE, Arden NK, Bennell K, Bierma-Zeinstra SMA, et al. OARSI Guidelines for the Non-Surgical Management of Knee, Hip, and Polyarticular Osteoarthritis. Osteoarthritis Cartilage. 2019 Nov;27:1578-1589.

[4] Yokota N, Hattori M, Ohtsuru T, Otsuji M, Lyman S, Shimomura K, et al. Comparative Clinical Outcomes After Intra-articular Injection With Adipose-Derived Cultured Stem Cells or Noncultured Stromal Vascular Fraction for the Treatment of Knee Osteoarthritis. Am J Sports Med. 2019 Sep;47(11):2577-2583.

203

Table 1. Change of cartilage defect area and cartilage volume

		Before operation	After 6 months	After 12 months
Cartilage defect area (mm^2)	Femur	33.59	4.59	13.59
	Tibia	122.31	34.48	51.43
Cartilage volume (mL)	Femur	9.58	10.36	10.00
	Tibia	3.82	4.00	4.17

Fig. 1 Clinical course of cartilage area evaluated by MRI (3D image rendered by SYNAPSE VINCENT)

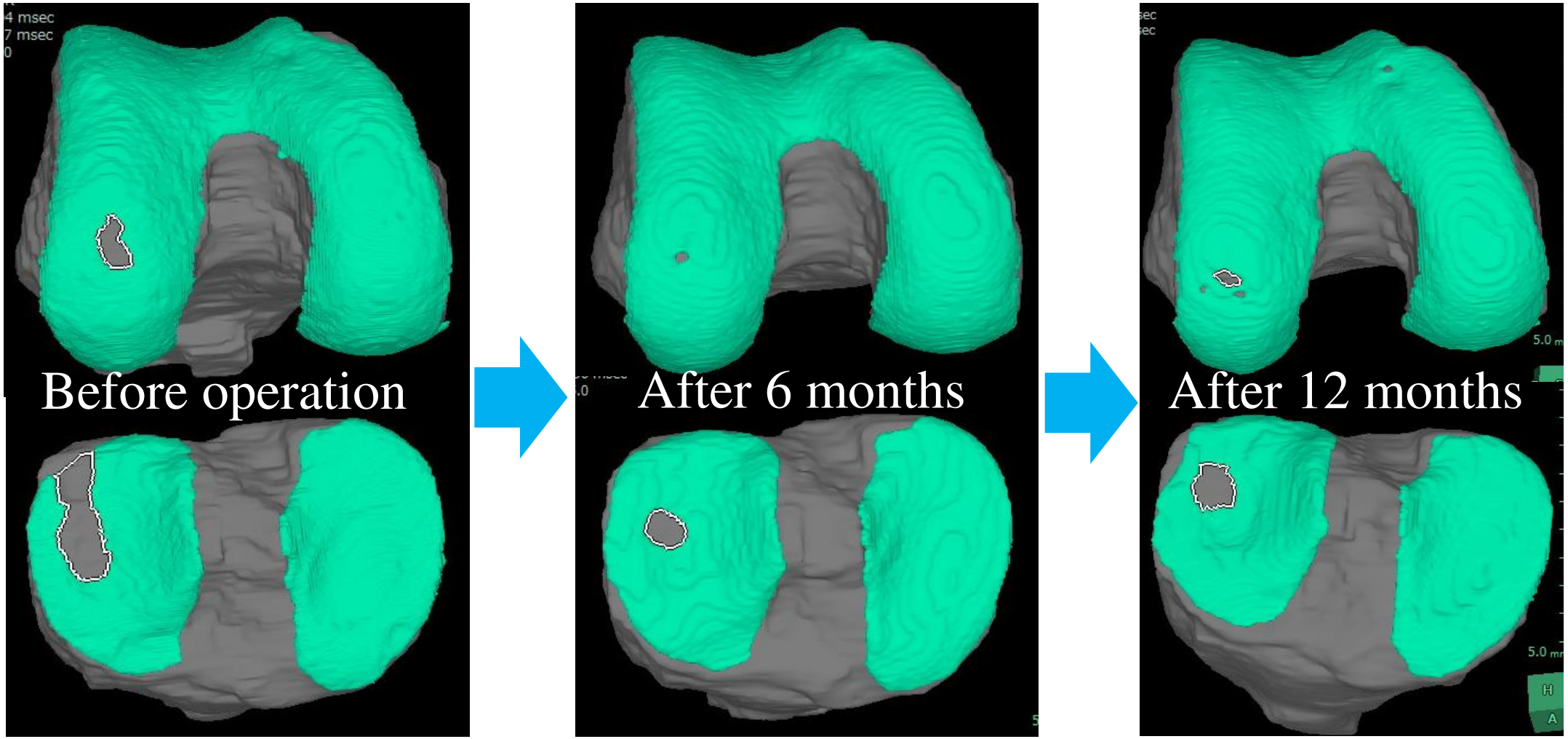

Fig. 2 Clinical course of cartilage thickness evaluated by MRI (3D image rendered by VINCENT)

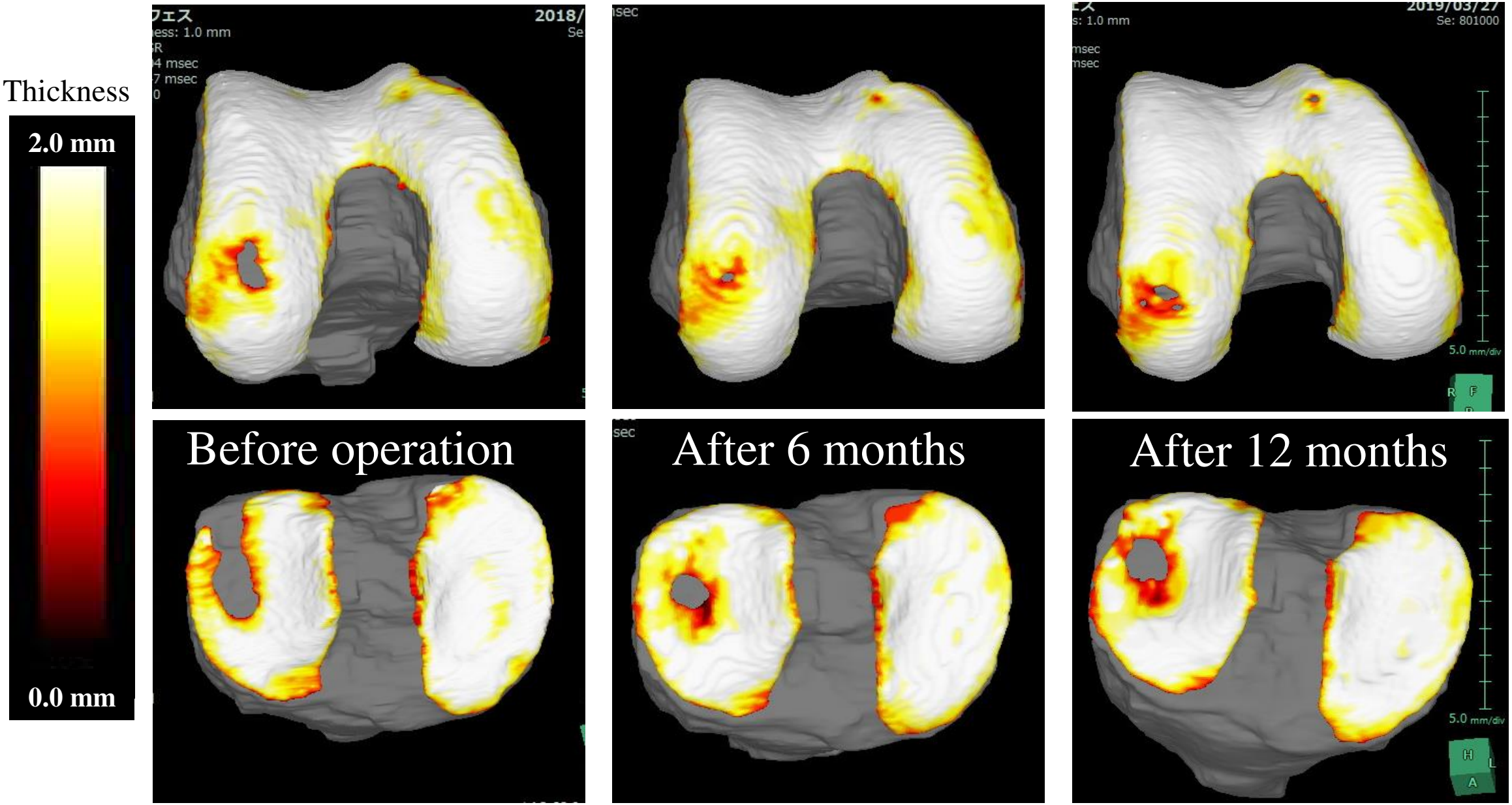

Figures

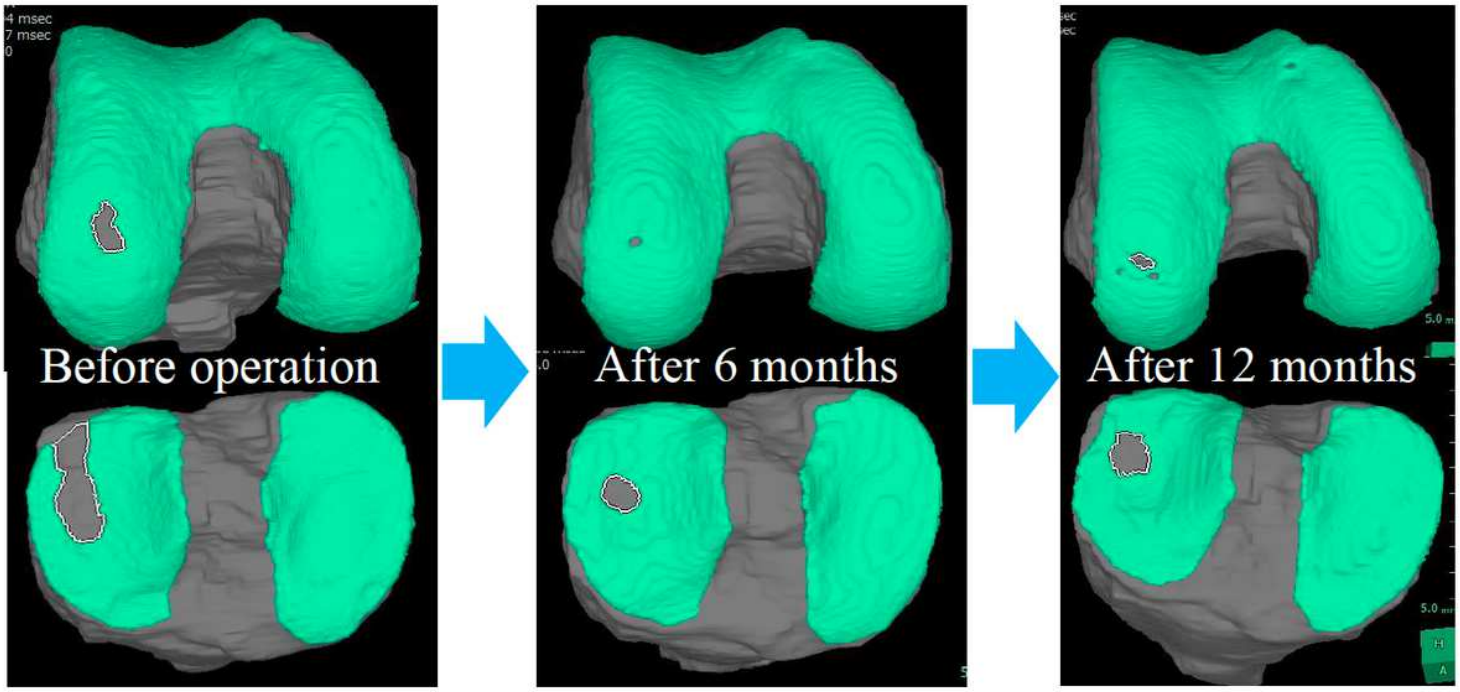

Figure 1

Clinical course of cartilage area evaluated by MRI (3D image rendered by SYNAPSE VINCENT)

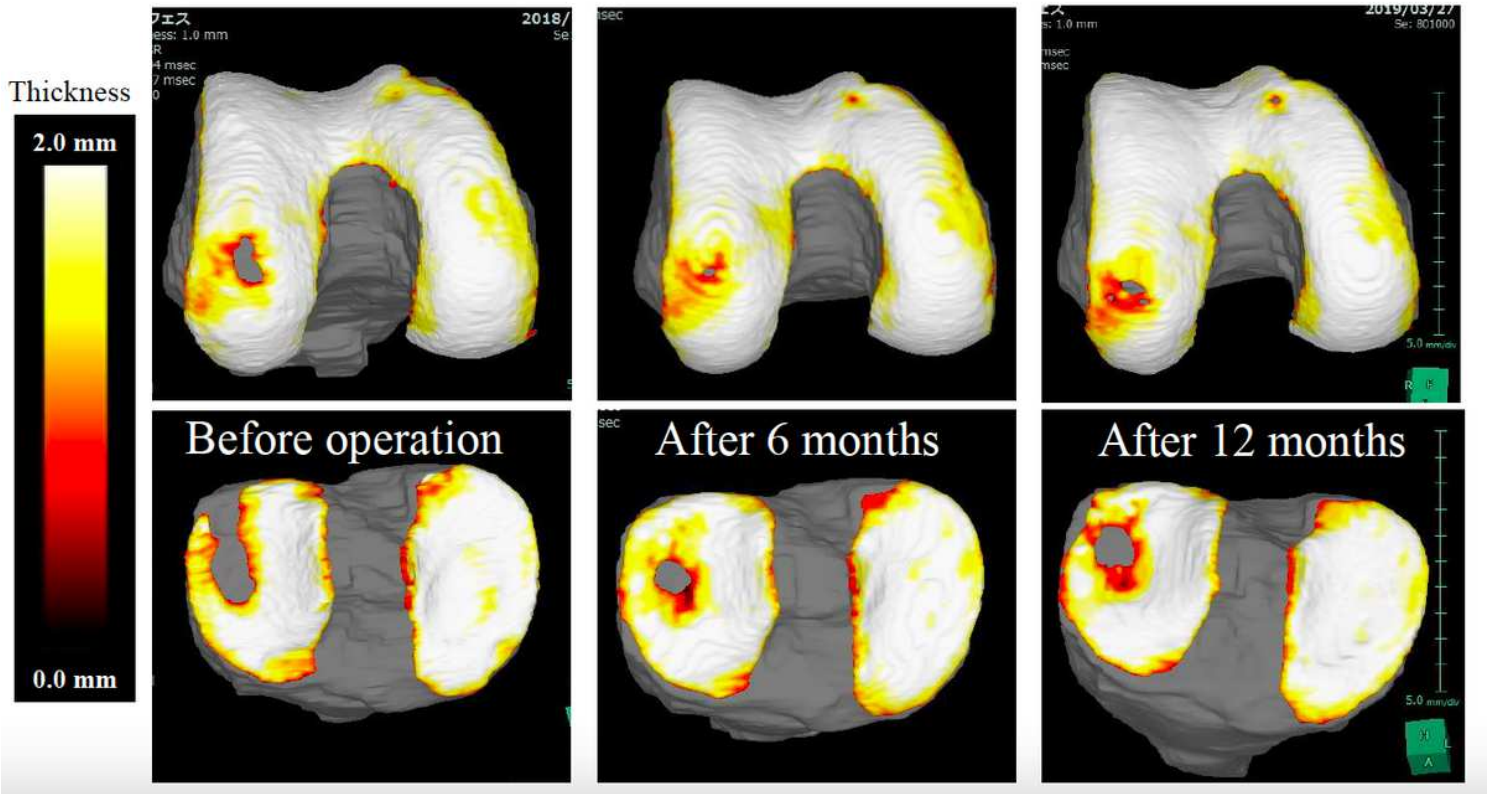

Figure 2

Clinical course of cartilage thickness evaluated by MRI (3D image rendered by VINCENT)