Computed Tomography Evaluation of Risk Factors for an Undesirable Buccal Split During Sagittal Split Ramus Osteotomy

Yasuyuki Fujii (yfujii@tokyo-med.ac.jp)
Tokyo Medical University

Ayano Hatori
Tokyo Medical University

Tomoko Sugiyama-Tamura
Tokyo Medical University

Hayato Hamada
Tokyo Medical University

Risa Sugisaki
Tokyo Medical University

Yuki Kanno
Tokyo Women's Medical University

Marika Sato
Tokyo Medical University

Michihide Kono
Tokyo Medical University

On Hasegawa
Tokyo Medical University

Yoko Kawase-Koga
Tokyo Women's Medical University

Daichi Chikazu
Tokyo Medical University

Research Article

Keywords: sagittal split ramus osteotomy (SSRO), bad split, Hunsuck/Epker, risk factors, orthognathic surgery

Posted Date: February 16th, 2022

DOI: https://doi.org/10.21203/rs.3.rs-1314336/v1

Abstract

Background: Sagittal split ramus osteotomy (SSRO) sometimes induces an irregular split pattern referred to as a bad split. We investigated the risk factors for bad splits in the buccal plate of the ramus during SSRO.

Methods: Ramus morphology and bad splits in the buccal plate of the ramus were assessed using preoperative and postoperative computed tomography images.

Results: Of the 53 rami analyzed, 45 had a successful split, and 8 had a bad split in the buccal plate. Horizontal images at the height of the mandibular foramen showed that there were significant differences in the ratio of the forward thickness to the backward thickness of the ramus between patients with a successful split and those with a bad split. In addition, the distal region of the cortical bone tended to be thicker and the curve of the lateral region of the cortical bone tended to be smaller in the bad split group than in the control group.

Conclusion: These results indicated that a ramus shape in which the width becomes thinner towards the back frequently induces bad splits in the buccal plate of the ramus during SSRO, and more attention should be paid to patients who have rami of these shapes in future surgeries.

Introduction

Sagittal split ramus osteotomy (SSRO) is a common surgical method for the correction of mandibular prognathism. Compared with intraoral vertical ramus osteotomy, which is another common method for orthognathic surgery, SSRO requires a shorter period of intermaxillary fixation because of the large area of bony contact and the rigid fixation. However, SSRO sometimes induces an irregular split pattern referred to as a bad split. Previous studies reported that 0.2% to 14.6% of split sites result in undesirable fractures [1, 2]. Bad splits during SSRO have been reported to occur in the buccal plate of the proximal segment, lingual plate of the distal segment, coronoid process, and condylar neck [3]. Among them, the buccal plate of the proximal segment is the most frequent site of fracture. Buccal plate fractures in the anterior site may heal just by removing the small segment. However, it is difficult to treat a bad split in the ramus. An undesirable buccal split in the ramus results in bony interference between the proximal and distal segments during setback movement, or results in attachment of the condyle to the distal segment. Salvage surgical approaches for buccal fractures in the ramus are sometimes challenging. Previous studies have reported risk factors for bad splits during SSRO [4-7], but there is controversy regarding some of the risk factors. It is still unclear whether older age of the patients, the presence of the third molar, and mandibular anatomy increases the risk of bad splits during SSRO.

Little is known about whether the anatomical features of the ramus affect the risk of buccal fractures in the proximal segment. Therefore, the aim of this study was to investigate the risk factors for bad splits in the buccal plate of the ramus during SSRO by analyzing the anatomy of the ramus using computed tomography (CT).

Materials And Methods

Patients and surgical treatments

A total of 27 Japanese patients (13 men and 14 women) who were treated by SSRO at Tokyo Medical University Hospital between January and December 2020 were analyzed. Patients who underwent extraction of the lower third molars or advanced movement of the proximal segment during SSRO were excluded. Features of the jaw deformities were mandibular prognathism with/without maxillary retrusion and/or facial asymmetry. The age of the patients at the time of orthognathic surgery ranged from 17 to 51 years (mean: 25.5 years; median: 24.0 years).

SSRO procedures were performed basically according to the Hunsuck-Epker modification, which is known as short lingual osteotomy (SLO) [8, 9]. A modified version of the SLO was performed using an ultrasonic bonecutting device to determine the posterior osteotomy boundary [10]. Briefly, vertical osteotomy of about 10 mm was performed from the posterior edge of the horizontal osteotomy, in close proximity to the mandibular foramen, toward the inferior border, using an ultrasonic bone-cutting device to split the sagittal surface of the ramus. Nine surgeons who were trained in oral surgery for 9 or more years performed all operations.

CT analysis of rami anatomy and buccal fracture of the rami

CT analyses were performed about 1 month before the surgery, and 4 or 5 days after the surgery, using a Revolution CT device (GE Healthcare) at Tokyo Medical University Hospital (tube voltage: 120 kV; tube current: auto mA; rotation time: 0.5 s/rotation; slice width: 2.5 mm; slice interval: 0.625 mm; field of view: 23 cm; reconstruction kernel: bone; scan pitch: 0.561).

Horizontal images were obtained at the height of the lingula of the mandible (Image A, Fig. 1A) and the mandibular foramen (Image B, Fig. 1B), and the landmarks for measurement were manually identified (Fig. 1C, D); in Image A, the forward point (A), the backward point (B), the intersection point of the perpendicular bisector of line AB and the lateral surface of the buccal cortical bone (C), in Image B, the medial point (D), the point on the medial surface 5 mm behind point D (E), the point of tangency of the mandibular foramen and point D (F), the center of the mandibular foramen (G), the point of tangency of the lateral surface of the lingual cortical bone and point F (H), the backward point (I), the point on the medial surface 5 mm in front of point I (J), the point on the lateral surface 5 mm in front of point I (K), the forward point (L), the point on the lateral surface 5 mm behind point L (M), and the intersection point of the perpendicular bisector of line IL and the lateral surface of the buccal cortical bone (N). Angle ACB as the curve of the medial region of the cortical bone and the thickness of the distal region of the cortical bone were measured in Image A. Angle DFH as the curve of the medial region of the cortical bone, angle LNI as the curve of the lateral region of the cortical bone, the distance of EM as the forward thickness of the ramus, the distance of JK as the backward thickness of the ramus, the distance of GI, and the thickness of the distal region of the cortical bone were measured in Image B. Whether or not the mandibular foramen was in direct contact with the buccal cortical bone was also evaluated in Image B.

Bad splits in the buccal plate of the ramus were evaluated in Image A or B after surgery, when a split line appeared on the buccal cortical bone 3 mm or more lateral from point I (Fig. 1E). These measurements were conducted 3 times by 2 experienced oral surgeons, and the mean values were analyzed.

Statistical analysis

Statistical analysis was performed by the Student *t*-test or the Fisher exact test using Prism 8 software (GraphPad Software). A *p*-value of less than 0.05 was considered to indicate a statistically significant difference between 2 groups.

Results

Of the 53 rami analyzed, 45 had a successful split (control group: 84.9%), and 8 had a bad split in the buccal plate of the ramus (bad split group: 15.1%, Fig. 2). There was no significant difference in the age of the patients between the control and the bad split groups. Bad splits occurred more frequently in female patients (87.5%) than in male patients. In Image A, there were no significant differences in angle ACB and the thickness of the distal region of the cortical bone between the control group and the bad split group (Fig. 3A, B). On the other hand, there was a statistically significant difference in the ratio of EM to JK between the two groups (Fig. 3C). In addition, the distal region of the cortical bone in the bad split group tended to be thicker ($p = 0.099$) (Fig. 3D), and angle LNI in the bad split group tended to be smaller than in the control group ($p = 0.087$) (Fig. 3E), although the difference was not statistically significant. There were also no significant differences in angle DFH and the distance of GI between the two groups (Fig. 3F, G). In four patients of the control group and one patient of the bad split group, the mandibular foramen was in direct contact with the buccal cortical bone, although there was no significant difference in the frequency between the two groups (Table 1; $p = 0.574$).

Discussion

Bad split is a major complication in SSRO. The reported incidence of bad splits in SSRO ranges from 0.5% to 5.5% per site [11, 12]. Among the cases of bad splits, the most frequent site is the buccal plate of the proximal segment [13]. In the present study, the rate of bad splits in the buccal plate was higher than that of previous studies. This difference may be owing to the definition of a bad split. We defined a bad split as a buccal split, which is the appearance of a split line on the buccal cortical bone 3 mm or more lateral from point I. A split line near the posterior edge of the buccal cortical bone might not result in any problems during surgery.

Risk factors of a bad split in SSRO, such as older age, a thick mandible, surgical technique, horizontal osteotomy line, and presence of the lower third molars have previously been investigated [4-7, 14, 15]. However, the results remain controversial. For example, a previous study demonstrated that the presence of mandibular third molars increased the risk of a bad split [16]. However, other studies reported that the presence of mandibular third molars do not increase the risk of bad splits [5, 17].

Mandibular anatomy also affects the risk of bad splits during SSRO. Previous studies suggested that patients with a shorter ramus and thinner buccolingual alveolar region distal to the second molar have a higher risk of bad splits than other patients [6, 18]. Moreover, in a study by Aarabi et al., patients with a shorter ramus and buccolingually thin mandible were found to be more susceptible to fracture during sagittal osteotomy than other patients [1]. In the present study, we analyzed mandibular anatomy using preoperative CT to determine whether the shape of the ramus affects the risk of bad splits in the buccal plate of the proximal segment. Compared with the control group, the ratio of EM to JK was larger in the bad split group. This result indicates that a ramus shape in which the width becomes thinner from the front to the back increases the risk of bad splits in the buccal plate. Angle LNI, which was regarded as the curve of the lateral region of the cortical bone at the height of the mandibular foramen, in the bad split group tended to be smaller than that in the control group, although the difference was not statistically significant. The split may be caused by pressure applied on the distal aspect of the posterior ramus during SSRO in patients with such a mandibular shape. The distal region of the cortical bone also tended to be thicker in the bad split group. This shape may result in force being applied to the medial or distal aspect of the posterior ramus in the front of the distal region of the cortical bone, because it is difficult to split the thick cortical bone. However, there were no differences in ramus shape between the two groups in the analysis of horizontal images at the height of the lingula of the mandible. It was difficult to identify the points of measurement, such as the medial point and the center of the mandibular foramen, because the lingula of the mandible had various shapes. Anatomical analyses using axial images at other heights of the ramus or using three-dimensional images may reveal more details regarding the association between mandibular anatomy and the occurrence of bad splits in the buccal plate of the proximal segment during SSRO.

Conclusions

Patients with a ramus shape in which the width becomes thinner from the front to the back, a cortical bone that is thick in the distal region, or a lateral cortical bone that has a sharp curve at the height of the mandibular foramen are more susceptible to bone fracture during SSRO than other patients.

List Of Abbreviations

SSRO: Sagittal split ramus osteotomy

CT: computed tomography

SLO: short lingual osteotomy

Declarations

Ethical approval and consent to participate

This research was conducted in accordance with the Declaration of Helsinki. The Ethics Committee of the Faculty of Medicine, Tokyo Medical University reviewed and approved the study design (study approval number: T2021-0061). Informed consent was obtained from all individual participants included in the study.

Consent for publication

Written informed consent for publication of their clinical details and/or clinical images was obtained from the patient.

Availability of data and materials

The datasets collected and analyzed during the current study are available from the first author on reasonable request.

Competing interests

None declared.

Funding

This work was partly supported by the Japan Society for the Promotion of Science (JSPS) KAKENHI Grant (No. 21K17098).

Authors' contributions

YF, HH, TS-T, YK-K, and DC conceived and designed the study. YF, RS, MS, YK, MK and OH were responsible for data collection. YF and AH analyzed the data and wrote the manuscript. All authors read and approved the final manuscript.

Acknowledgements

Not applicable

References

1. Aarabi M, Tabrizi R, Hekmat M, Shahidi S, Puzesh A: Relationship Between Mandibular Anatomy and the Occurrence of a Bad Split Upon Sagittal Split Osteotomy. *Journal of Oral and Maxillofacial Surgery* 2014, 72(12):2508-2513.
2. Akhtar S, Tuinzing DB: Unfavorable splits in sagittal split osteotomy. *Oral Surg Oral Med Oral Pathol Oral Radiol Endod* 1999, 87(3):267-268.
3. Steenen SA, Becking AG: Bad splits in bilateral sagittal split osteotomy: systematic review of fracture patterns. *Int J Oral Maxillofac Surg* 2016, 45(7):887-897.

4. Steenen SA, van Wijk AJ, Becking AG: Bad splits in bilateral sagittal split osteotomy: systematic review and meta-analysis of reported risk factors. *Int J Oral Maxillofac Surg* 2016, 45(8):971-979.
5. Jiang N, Wang M, Bi R, Wu G, Zhu S, Liu Y: Risk factors for bad splits during sagittal split ramus osteotomy: a retrospective study of 964 cases. *Br J Oral Maxillofac Surg* 2021, 59(6):678-682.
6. Wang T, Han JJ, Oh HK, Park HJ, Jung S, Park YJ, Kook MS: Evaluation of Mandibular Anatomy Associated With Bad Splits in Sagittal Split Ramus Osteotomy of Mandible. *J Craniofac Surg* 2016, 27(5):e500-504.
7. Yu IH, Wong YK: Evaluation of mandibular anatomy related to sagittal split ramus osteotomy using 3-dimensional computed tomography scan images. *International Journal of Oral and Maxillofacial Surgery* 2008, 37(6):521-528.
8. Epker BN: Modifications in the sagittal osteotomy of the mandible. *J Oral Surg* 1977, 35(2):157-159.
9. Hunsuck EE: A modified intraoral sagittal splitting technic for correction of mandibular prognathism. *J Oral Surg* 1968, 26(4):250-253.
10. Kawase-Koga Y, Fujii Y, Ikehata M, Ikehata N, Kono M, Kimoto A, Watanabe M, Chikazu D: Usefulness of Early Plate Removal in Patients With Occlusal Discrepancies After Sagittal Split Ramus Osteotomy. *J Craniofac Surg* 2018, 29(4):900-903.
11. Doucet J-C, Morrison AD, Davis BR, Gregoire CE, Goodday R, Precious DS: The Presence of Mandibular Third Molars During Sagittal Split Osteotomies Does Not Increase the Risk of Complications. *Journal of Oral and Maxillofacial Surgery* 2012, 70(8):1935-1943.
12. Mensink G, Verweij JP, Frank MD, Eelco Bergsma J, Richard van Merkesteyn JP: Bad split during bilateral sagittal split osteotomy of the mandible with separators: a retrospective study of 427 patients. *Br J Oral Maxillofac Surg* 2013, 51(6):525-529.
13. Chrcanovic BR, Freire-Maia B: Risk factors and prevention of bad splits during sagittal split osteotomy. *Oral Maxillofac Surg* 2012, 16(1):19-27.
14. Suzen M, Uckan S, Munevveroglu S, Ozel A: Effect of Horizontal Osteotomy Level on Complication Rates and Neurosensory Deficits After Sagittal Split Ramus Osteotomy. *J Craniofac Surg* 2021, 32(5):1712-1715.
15. Möhlhenrich SC, Kniha K, Peters F, Ayoub N, Goloborodko E, Hölzle F, Fritz U, Modabber A: Fracture patterns after bilateral sagittal split osteotomy of the mandibular ramus according to the Obwegeser/Dal Pont and Hunsuck/Epker modifications. *J Craniomaxillofac Surg* 2017, 45(5):762-767.
16. Verweij JP, Mensink G, Fiocco M, van Merkesteyn JPR: Presence of mandibular third molars during bilateral sagittal split osteotomy increases the possibility of bad split but not the risk of other post-operative complications. *Journal of Cranio-Maxillofacial Surgery* 2014, 42(7):e359-e363.
17. Kriwalsky MS, Maurer P, Veras RB, Eckert AW, Schubert J: Risk factors for a bad split during sagittal split osteotomy. *British Journal of Oral and Maxillofacial Surgery* 2008, 46(3):177-179.
18. Zamiri B, Tabrizi R, Shahidi S, Pouzesh A: Medial cortex fracture patterns after sagittal split osteotomy using short versus long medial cuts: can we obviate bad splits? *Int J Oral Maxillofac*

Surg 2015, 44(7):809-815.

Tables

Table 1. Comparison of the location of the mandibular foramen between the control group and bad split group in Image B.

Group	Direct contact with buccal cortical bone	No contact with buccal cortical bone	Total
Control	4 (8.3)	44 (91.7)	48 (100)
Bad split	1 (12.5)	7 (87.5)	8 (100)

Data are shown as number of patients (%).

Figures

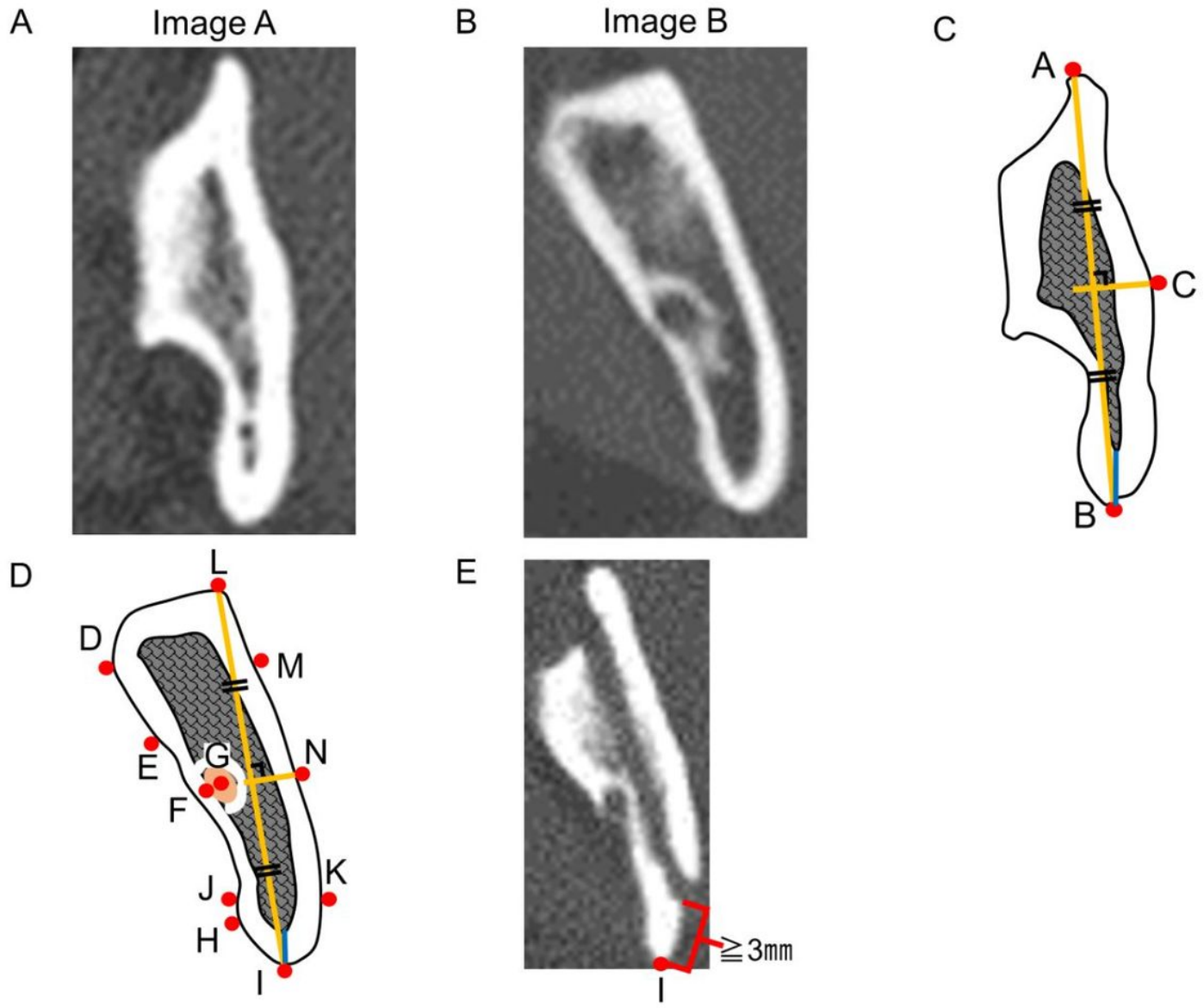

Figure 1

Measurement of mandibular morphology in the ramus and evaluation of bad splits during SSRO. Horizontal images at the height of the lingula of the mandible **(Image A, A)** and the mandibular foramen **(Image B, B)** were obtained on preoperative CT, and the landmarks for measurement were manually identified in Image A **(C)** and Image B **(D)**; in Image A, the forward point (point A), the backward point (point B), the intersection point of the perpendicular bisector of line AB and the lateral surface of the buccal cortical bone (point C), in Image B, the medial point (point D), the point on the medial surface 5 mm behind point D (point E), the point of tangency of the mandibular foramen and point D (point F), the center of the mandibular foramen (point G), the point of tangency of the lateral surface of the lingual cortical bone and point F (point H), the backward point (point I), the point on the medial surface 5 mm in front of point I (point J), the point on the lateral surface 5 mm in front of point I (point K), the forward point (point L), the point on the lateral surface 5 mm behind point L (point M), and the intersection point of the perpendicular bisector of line IL and the lateral surface of the buccal cortical bone (point N). The thickness of the distal region of the cortical bone was measured in both Images A and B (blue lines in **(C)**

and **(D)**, respectively). Bad splits in the buccal plate of the ramus were evaluated in Image A or B after surgery, when the split line appeared on the buccal cortical bone 3 mm or more lateral from point I **(E)**.

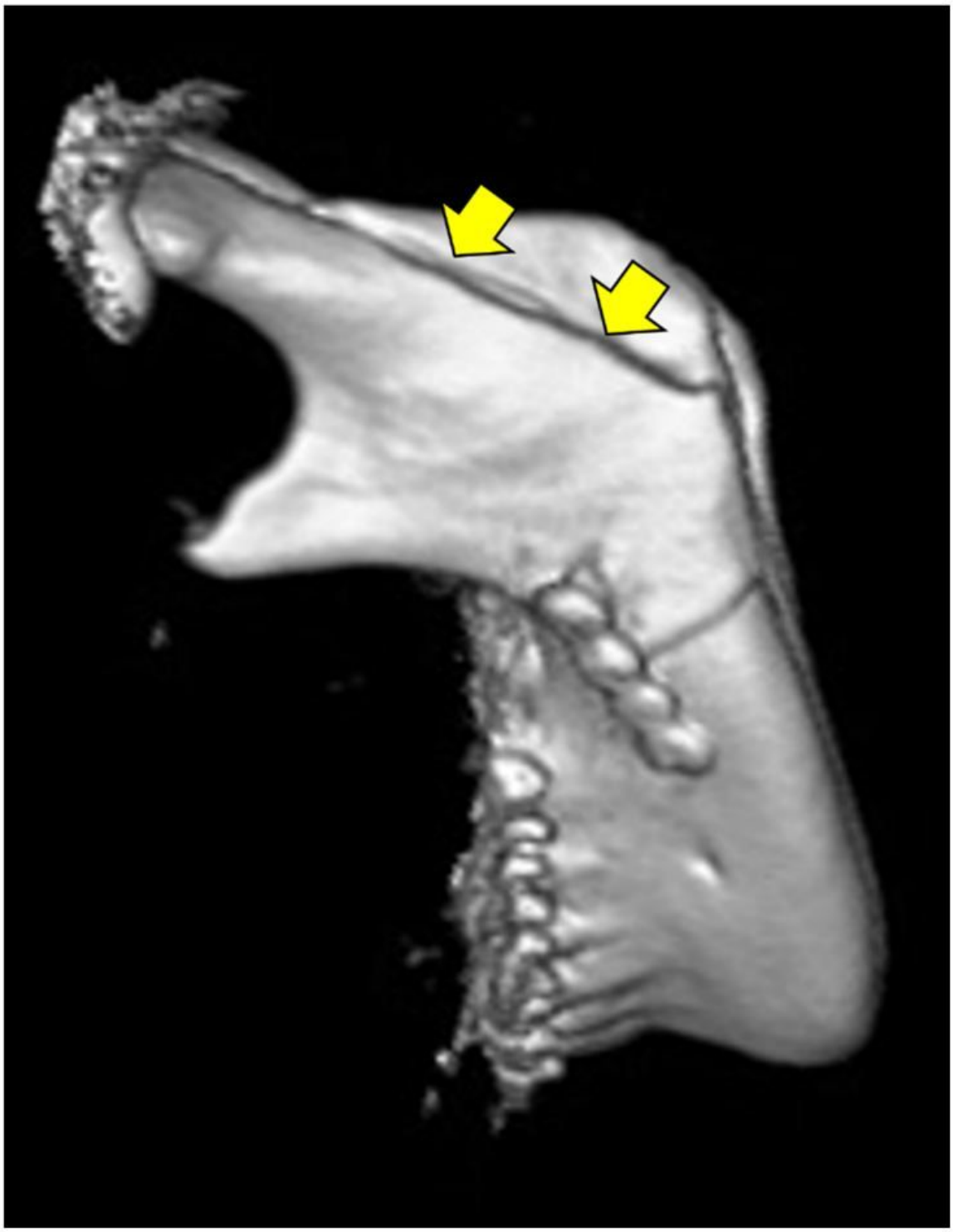

Figure 2

Representative three-dimensional image of an undesirable buccal split during SSRO. The yellow arrows indicate a bad split in the buccal plate of the ramus.

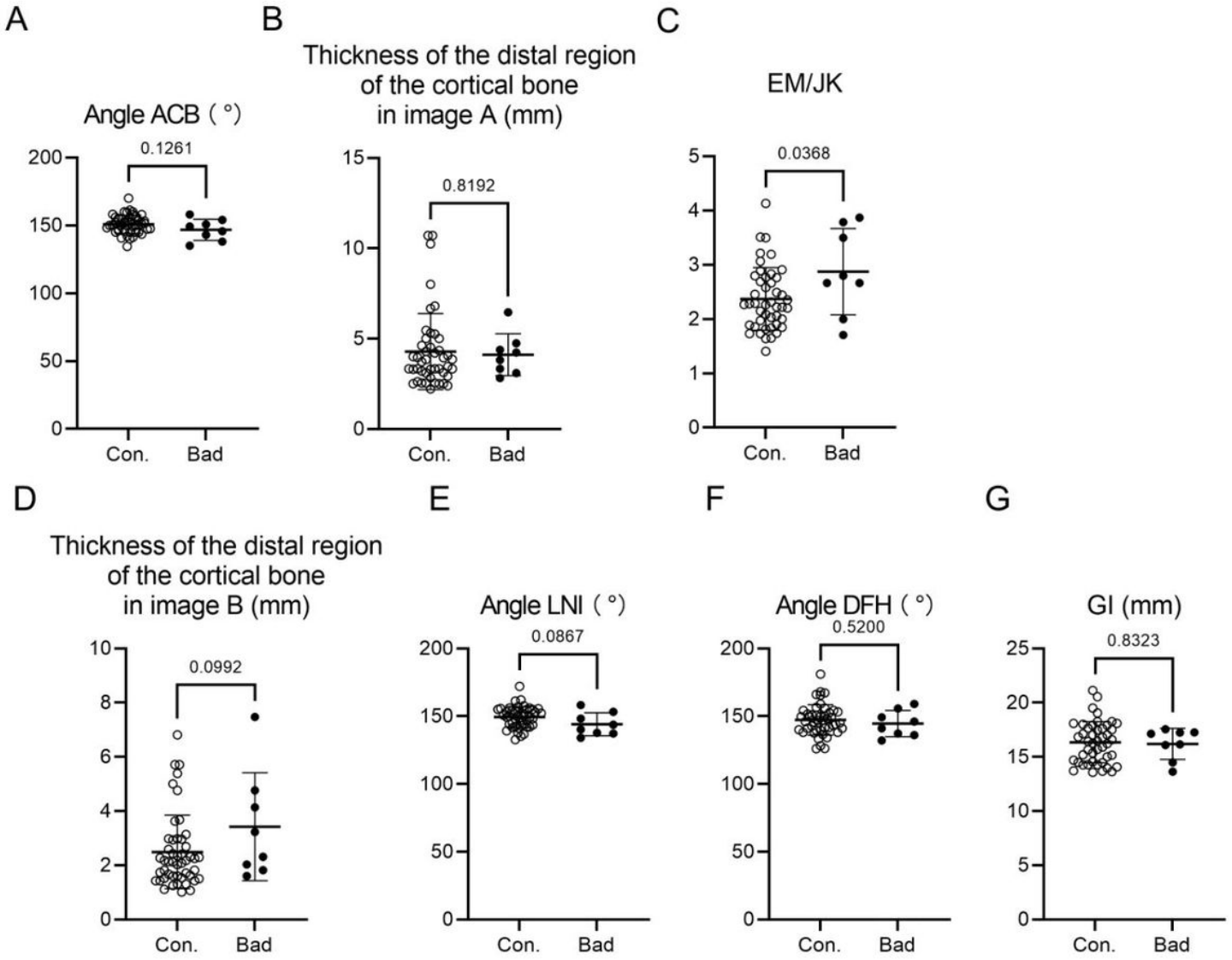

Figure 3

Analysis of mandibular morphology in the ramus and evaluation of bad splits occurring during SSRO. Comparisons between the control and the bad split group regarding angle ACB **(A)**, thickness of the distal region of the cortical bone in Image A **(B)**, the ratio of EM to JK **(C)**, thickness of the distal region of the cortical bone in Image B **(D)**, angle LNI **(E)**, angle DFH **(F)**, and distance of GI **(G)**.