A Case of Complete Double Layer Stents Fracture in Right Coronary Artery

Xuhe Gong

Capital Medical University Affiliated Beijing Friendship Hospital https://orcid.org/0000-0002-0513-6674

Daokuo Yao (yaodaokuo@126.com)

Capital Medical University Affiliated Beijing Friendship Hospital

---

Case report

Keywords: coronary artery disease, stent fracture, optical coherence tomography

Posted Date: December 21st, 2020

DOI: https://doi.org/10.21203/rs.3.rs-131514/v1

Abstract

Background: Coronary stent fracture is a rare and serious complication, because it is closely related to restenosis, stent thrombosis, and subsequent target lesion revascularization. We describe the fracture of a double layer of stents in a patient with recurrent acute inferior myocardial infarction.

Case presentation: A 67-year-old man was hospitalized for untypical chest pain, with prior stents implantation twice in proximal of right coronary artery due to acute and recurrent myocardial infarction, complete stent fracture was revealed in right coronary artery by angiography and optical coherence tomography. Conservative therapy was chosen, as enough lumen area was observed without aneurysm. No recurrent chest discomfort was reported in 3 month after discharge.

Conclusion: Our case describes complete double layer of stents fracture in right coronary artery, the patient get better prognosis through conservative treatment.

Background

Stent fracture is one of the rare and dangerous complications after coronary stenting. It can cause stent restenosis or thrombus, and the incidence rate of stent fracture is 1.7-7%[1]. Treatment of stent rupture depends on the type of stent rupture and the severity of clinical events. Comprehensive analysis of the possible causes of stent fracture, careful observation of morphology, and considering patients symptoms, will help choosing a reasonable treatment strategy.

Case Presentation

A 67-year-old man was hospitalized on April, 2020 for chest pain. The patient had a history of precordial chest pain for 5 years, and aggravation for 1 month. Five years ago, he was diagnosed as acute inferior myocardial infarction. Angiography revealed double vessel disease involving diagonal branch and proximal right coronary artery (RCA) (Fig. A,B). The patient was underwent percutaneous coronary intervention (PCI) with a 3.5mm × 29 mm Partner (sirolimus-eluting stent, Lepu Medical Technology Co., Ltd., Beijing, China) stent) in RCA. The patient's symptoms relived after PCI, while secondary prevention medications were taken regularly (clopidogrel was stopped after one year, aspirin, statin continued). Unfortunately, two years ago, the patient had another acute inferior wall myocardial infarction. Urgent coronary angiography showed visible stents in the proximal and middle segments of RCA, with in-stent total occlusion(Fig. B). After thrombus was aspirated, one 4.0mm × 33 mm Partner stent was implanted in RCA(Fig. C), considering prior smaller stent maybe related with re-occlusion. Past medical history includes hypertension for 10 years, hyperlipidemia for 5 years, and smoking for 40 years. His brother had coronary heart disease and stent implantation.

After hospitalization, no obvious abnormality in physical examination, and secondary prevention treatment was prescribed. Creatine kinase-MB, troponin and N-terminal pro-brain natriuretic peptide was negative. Echocardiography revealed left ventricular ejection fraction (68%) was in the normal range, and

the motion of the basal segment of the posterior wall and the inferior wall of the left ventricle is slightly weakened. Coronary angiography revealed zig-zag shape and visible stents in the proximal segments of RCA; stent fracture could be seen at the first turning point of RCA (Fig. E and F), with coronary blood flow of grade TIMI 3.

Optical coherence tomography (OCT) catheter, (ImageWire, LightLab Imaging, Westford, Massachusetts, USA) was used for further evaluation. We found complete two-layer stent fracture in the proximal part of the RCA with a length of 1.3 mm without stent struts in the middle of the prior stents; the mean diameter of lumen without struts is 4.59 mm (Fig. G). Comprehensive consideration of patients with atypical chest pain, no myocardial ischemia basis, and RCA blood flow unobstructed, we did not carry out interventional. The patient was discharged 2 days later, and no recurrent chest discomfort was reported in the 3 month followed-up.

Discussion

This report describes a rare complete double layer stent fracture in a patient. Patients developed acute inferior wall myocardial infarction 5 and 3 years before admission, and were treated with stent implantation, respectively. Coronary angiography revealed zig-zag shape with a possible stent fracture in the RCA. The fracture morphology of stent was observed by OCT imaging. Stent fracture is a rare complication after PCI, which can lead to restenosis, thrombosis, vessel injury and aneurysm formation [2, 3].

Reports have shown that motion of the coronary is the main cause of fracture, angulation of the coronary artery and shear stress potency near the proximal portion of the coronary changed after stenting[4]. Stent fracture was associated with a long stented segment, RCA location and metal overlap [5]. Moreover, Zhen Ge et al found Stent fracture is associated with a higher mortality in patients with type-2 diabetes treated by implantation of a second generation drug-eluting stent, and more often type IV stent fracture was seen in patients with diabetes [6]. In this report, the location of proximal RCA with long stent, motion and shear stress maybe the main reason for stent fracture in this case. Another possible reason for stent fracture maybe related to the bigger size stent implantation in the smaller one. With post-dilation of 4.0 mm non-compliant balloon, the struts of the first stent of diameter 3.5 mm maybe damaged. The reason for the second stent strut fracture was not clear.

Several management options for stent fracture include conservation, the use of the stent-in-stent technique and surgical correction. The treatment principles depend on the type of stent fracture and the severity of clinical events. For stent fracture-induced restenosis or thrombosis should generally try to avoid re-stent implantation. What’s more, whether stent fracture is accompanied by clinical events or not, long-term antiplatelet therapy should be used. Conservative management for our patient was depended on the enough coronary lumen area with good ante grade blood flow though complete stent fracture appeared. At the time coronary angiography performed, the zig-zag part was more like two separated double layer stents with no-stent area between. As in-stent restenosis or thrombosis was not appeared in

the OCT images, and there was no lesion stenosis in the area between the stents, conservative therapy was reasonable. Another suggestion was that during PCI, we should attach great importance to the anatomic characteristics of coronary artery and avoid the long stent implantation in severe tortuous, angled or calcified vessels.

Conclusion

Stent fracture is one of the rare and dangerous complications after coronary stenting. We should analyze the causes of stent rupture, carefully observe the form of stent rupture, and combine with the clinical manifestations of patients, so that patients can get a good outcome.

Abbreviations

DES: Drug eluting stent; ISR: In-stent restenosis; PCI: Percutaneous coronary intervention; RCA: Right coronary artery; OCT: Optical coherence tomography.

Declarations

Authors' contributions

Xuhe Gong, Daokuo Yao performed PCI, Xuhe Gong wrote the paper. All authors have read and approved the manuscript.

Funding

National Natural Science Foundation of China (81600196); Beijing Key Laboratory of Metabolic Disturbance Related Cardiovascular Disease (OP2018DXWL01).

Ethics approval and consent to participate

The study was approved by the ethics committee of Beijing Friendship Hospital.

Consent for publication

Written informed consent was obtained from the patient for publication of this case report and any accompanying images.

Funding

This study was supported by National Natural Science Foundation of China (Grant No. 81600196).

Availability of data and materials

Not applicable

Competing interests

There is no potential, perceived, or real competing interests, and there has been no financial arrangement regarding this paper.

References

1. NAKAZAWA G, FINN A V, VORPAHL M, et al. Incidence and predictors of drug-eluting stent fracture in human coronary artery a pathologic analysis [J]. Journal of the American College of Cardiology, 2009, 54(21): 1924-31.
2. CHHATRIWALLA A K, CAM A, UNZEK S, et al. Drug-eluting stent fracture and acute coronary syndrome [J]. Cardiovascular revascularization medicine : including molecular interventions, 2009, 10(3): 166-71.
3. DEL TRIGO M, JIMENEZ-QUEVEDO P, FERNANDEZ-GOLFIN C, et al. Very late mycotic pseudoaneurysm associated with drug-eluting stent fracture [J]. Circulation, 2012, 125(2): 390-2.
4. KANG W C, MOON C, 2ND, AHN T H, et al. Multiple stent strut fracture-induced restenosis in a diffuse long lesion treated with overlapping heterogeneous drug-eluting stent [J]. International journal of cardiology, 2008, 130(1): e30-3.
5. YANG T H, KIM D I, PARK S G, et al. Clinical characteristics of stent fracture after sirolimus-eluting stent implantation [J]. International journal of cardiology, 2009, 131(2): 212-6.
6. GE Z, LIU Z-Z, KAN J, et al. Stent fracture is associated with a higher mortality in patients with type-2 diabetes treated by implantation of a second-generation drug-eluting stent [J]. The International Journal of Cardiovascular Imaging, 2017, 33(12): 1873-81.

Figures

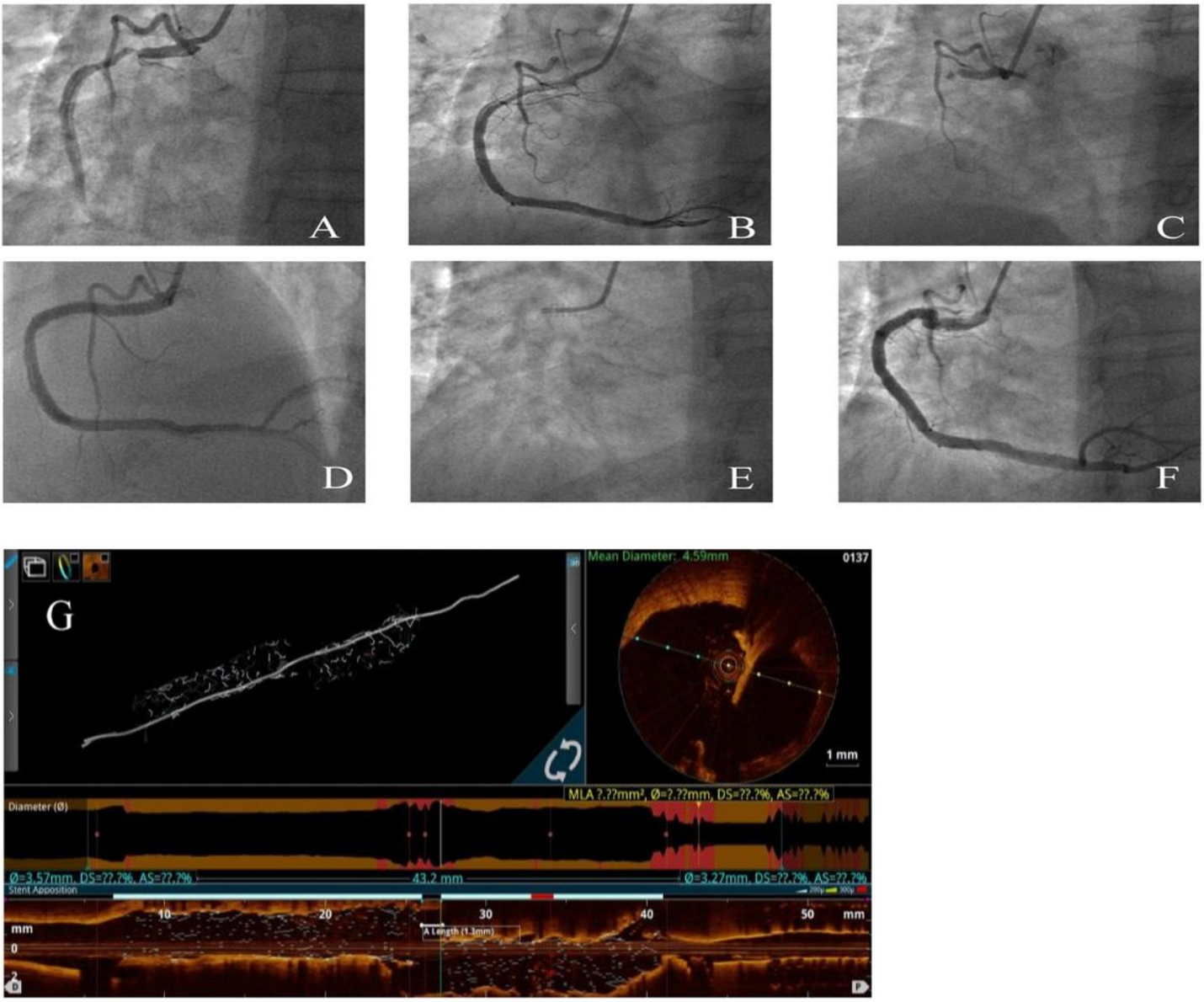

Figure 1

A,B Images of coronary angiography and PCI 5 years ago. Severe stenosis in the proximal segment of RCA (A); poststent angiography of RCA (B). C,D Images of coronary angiography and PCI 2 years ago, acute occlusion in the proximal segment of RCA(C), post-stent angiography of RCA (D). E,F Images of coronary angiographywith complete stent fracture. Stents fracture in proximal RCA(E), zig-zag shape and stent fracture at the first turning point of RCA with blood flow of grade TIMI 3(F). G Images of stent fracture in the RCA by OCT.