"Multimodal" Imaging Performance and Clinical Application of Coronavirus Disease 2019 (COVID-19)

Guohong Li (1024391352li@sina.com)
Guangdong Provincial Emergency Hospital: Guangdong Second Provincial General Hospital https://orcid.org/0000-0003-3408-0187

Qijian Zhou
Guangdong Provincial Emergency Hospital: Guangdong Second Provincial General Hospital

Jintian Li
Guangdong Provincial Emergency Hospital: Guangdong Second Provincial General Hospital

Lin Zhu
Guangdong Provincial Emergency Hospital: Guangdong Second Provincial General Hospital

Yan Chen
Guangdong Provincial Emergency Hospital: Guangdong Second Provincial General Hospital

Yushan Du
Guangdong Provincial Emergency Hospital: Guangdong Second Provincial General Hospital

Zhengguang Wu
Guangdong Provincial Emergency Hospital: Guangdong Second Provincial General Hospital

---

Research article

Keywords: Coronavirus disease 2019, Novel coronavirus pneumonia, digital tomosynthesis (DTS), Computed tomography (CT)

Posted Date: December 22nd, 2020

DOI: https://doi.org/10.21203/rs.3.rs-132295/v1

Abstract

Background: To investigate the diagnostic value of three different examination methods of chest radiography (CXR), digital tomosynthesis (DTS) and Computed tomography (CT) scan on the diagnosis of novel coronavirus pneumonia (COVID-19).

Methods: A retrospective analysis of three examination methods of chest: CXR, DTS, and CT scan of COVID-19 pneumonia patients diagnosed in our hospital from January, 23, 2020 to February, 29, 2020. And we compared three different imaging methods to COVID-19 display ability of pneumonia intrapulmonary lesions.

Results: A total of 37 patients diagnosed as COVID-19 by nucleic acid testing were included. The CXR group (10/37) and DTS group (21/28) of 37 patients with COVID-19 pneumonia showed significant differences in intrapulmonary ground glass opacities ($P<0.05$); DTS group (21/28) and CT group (25/27) showed no statistically significant differences in intrapulmonary ground glass opacities ($P> 0.05$).

Conclusion: Comparison of the three imaging methods of COVID-19 pneumonia, the diagnostic efficiency of CXR is low, which is easy to be false negative and miss lesions; diagnostic resolutions of DTS are higher than CXR, which can improve the ability to display the fine structure of intrapulmonary lesions; CT scan shows the intrapulmonary of COVID-19 pneumonia low-density ground glass opacities and internal structures have equal capacity compared with DTS. Therefore, DTS and CT are the best choices for the image diagnosis of COVID-19 pneumonia.

Background

The novel coronavirus pneumonia was an acute infectious disease which was first discovered in the Wuhan's Huananseafood market,Hubei in December 2019.The disease outbreak in China and has rapidly spread worldwide since the end of 2019[1,2]. Among the clinical diagnostic standards for this disease, the National Health Commission has successively issued Seventh edition of the diagnosis and treatment guideline of COVID-19 pneumonia [3], in which imaging performance plays a critical role in the diagnosis [4]. At present, domestic and foreign literatures had described the imaging characteristics of COVID-19 pneumonia [5]. This article focuses on the comparison of three different examination methods of COVID-19 pneumonia through CXR, DTS and CT scans for the diagnosis of COVID-19 pneumonia.

1 Materials And Methods

1.1 General information

From January, 23, 2020 to February, 29, 2020, the patient in our hospital, who's the COVID-19 nucleic acid test was positive, by real-time reverse transcription polymerase chain reaction (RT-PCR) or next-generation sequencing and at least had two of the three image examination methods of chest: CXR, DTS, and CT were included.

There are 37 patients included in this research, 19 males (51%)and 18 females(49%), the aged range from 12 to 74 years old, with an average age of 45.1 (45.1±14.3)years old. Among the 37 cases, 25 (68%) were from Hubei even from Wuhan, and 12(32%) had close physical contact with patients who diagnosed of novel coronary pneumonia. 6 (16%) of the 37 were from one family. The time from onset of symptomsto admission was 1 to 20 days. The clinical symptoms are shown in Table 1.

Table1: Clinical symptoms and Comorbidities of patients with COVID-19 pneumonia

symptoms	fever	cough	Sputum	Fatigue	Muscle ache	diarrhea	hypertension	diabetes	Cardiovascular disease	COPD
case	28	24	13	11	10	2	2	2	1	2

Note: COPD: Chronic Obstructive Pulmonary Disease

1.2 Apparatus and method Among the 37 cases, 28 cases had the CXR and DTS images of the chest□27 cases had CT imaging, including DTS and CT in 20 cases.CXR and DTS examinations are completed just before the patient check-in. CT examinations are performed on the day of check-in or the next day. The interval between all examinations is within 48 hours.

1.2.1 CXR and DTS photographs were taken by Shimadzu sonialvsion satire II digital continuous tomography Fusionsystem (Tomosynthesis). At first, we took standard CXR anterior view, with conditions: 120 kV, 5.0 mAs, distance 1800 mm.

Then DTS photo was taken. The patient took a standing position and positioned under perspective. After setting the irradiation center, the patient was instructed to take a deep breath and hold it. An arc-shaped movement with an angle of 40° between the tube and the centerline was used. Medium continuous exposure, set the source image distance to 1100 mm, layer spacing to 2 mm, and the imaging conditions to be set to: peak voltage of 100 kVp, current of 0.5 mA / s, and exposure time of 3.2 ms. The whole chest images werereconstructed with a slice thickness of 2 mmand an interval of 2 mm, at the PACS workstation.

1.2.2 The Philips 16-row helical mode CT spiral scan was used. The patient was supine, and the scan begins at the end of inspiration. Scans were done from the level of the upper thoracic inletto the inferior level of the costophrenic angle, and the following parameters were used: tube voltage 120KV, 250mAs, FOV 250mm × 250mm, scanning and reconstruction matrix is 512 × 512, reconstruction layer thickness is 1mm, reconstruction layer moment is 1mm. scanning image observation: lung window (window width: 1500 ~ 2000, window level-700 ~ -550), mediastinum window (window width 250 ~ 300, window level 30 ~ 55), patients all informed consent.

1.2.3 Image post-processing analysis. All CXR, DTS, and CT images were transmitted to the hospital PACS workstation in DICOM format and evaluated by two senior doctors of attending or higher level to confirm the differences in lesion distribution and density, internal structure and edges clarity[6]. Observation indicators: □ground glass opacities, □ consolidation shadow, □ nodular shadow, □ thickening of small blood vessels, □air bronchial sign, □interlobular septum thickening, □ anti-halo sign, □ lesions involving the lung lobe.

1.2.4 Statistical methods SPSS 22.0 statistical software was used to process the data. The ability of each group to display image signs was tested by Fisher's exact probabilities, $P<0.05$ was considered statistically significant.

2 Results

Orthotropic CXR of 37 patients showed patchy ground glass opacities, mainly in the field distribution of the lungs (Figure 1a). One patient showed consolidation of two lung patches, and the remaining 27 chest radiographs did not show clear Intrapulmonary lesions. 21 cases of 28 DTS showed snowflake-like ground glass opacities, mainly with multiple patches in the field of both lungs. In 7 cases of ground glass opacities, thickened small blood vessels and inflated bronchioles and bronchioles were seen. Uneven thickening of small blood vessels (Figure 1b, c), 2 cases showed patchy consolidation in the lung, 2 cases showed ground glass opacities (Figure 2b, c), and 2 cases had anti-halo signs (Figure 3b, c). Of the27 CT scans found ground glass opacities in one or both lungs in 24 cases. In the ground glass opacities, there were 19 cases of small blood vessel thickening signs, 13 bronchiolar inflation signs, and 15 lobular septal thickening signs (Figure 4a- c), 2 cases of anti-halo sign, 2 cases of consolidation shadow and nodule shadow (see Table 2).

Table 2□Compare the founding among the three different image methods

Groups	ground glass opacities	consolidation shadow	nodular shadow	thickening of small blood vessels	air bronchial sign	interlobular septum thickening	anti-halo sign
CXR(n=37)	10	1	0	7	7	0	0
DTS(n=28)	21	2	2	9	9	0	2
CT(n=27)	24	2	2	19	13	15	2

Note: CXR: chest radiography; DTS: digital tomosynthesis; CT: Computed tomography

In terms of the display of ground glass opacities in the lung, group CXR and group DTS were tested by Fisher's exact probabilities, $P<0.05$, there was a statistical difference between the groups, and DTS showed better ground glass opacities than CXR; compared with group DTS and group CT, $P> 0.05$, there was no statistical difference between the them, suggesting that DTS had the similar ability of showing the ground glass opacities compared with CT.

3 Discussions

The COVID-19 pneumonia is a suddenly acute infectious disease of the respiratory system [7]. Given that laboratory tests for the novel coronavirus can be falsely negative, radiologists play a key role in identifying suspicious image findings based on time interval from the onset of symptoms and guide further evaluation and management of patients.Despite the non-specific findings of diffuse alveolar damage is generally seen in viral infections, the specific nature of this pandemic makes imaging a good and accurate tool to stratify patients selected from first-line clinical triage.Image findings of patients with mild COVID-19 pneumonia include predominance of ground glass opacities in the early phase[8].

3.1 Chest radiography (CXR)

As a commonly used imaging examination method, CXR is still useful because it is cheaper, faster and more widespread; it is a commonly used chest imaging examination method in clinical practice [9].

CXR is a two-dimensional image,and the tissue overlap cannot be ignored, which is not conducive to the display of fine structures[10].The ability of CXR to detect more obvious lesions is acceptable, but is considered unreliable in detecting early phase of the pneumonia[11], which can only be used for the initial screening of the COVID-19 pneumonia. CXR is not sensitive for the detection of ground glass opacities, which are the main imaging features of COVID-19 pneumonia. It should not be used as the first-line technique and should not be used to exclude COVID-19 infection. It should be restricted to the follow-up of patients admitted to intensive care units, who are too fragile to be sent for CT [12].

3.2 Digital tomosynthesis (DTS)

DTS technology is an emerging photography technology that combines modern computer reconstruction image theory with traditional X-ray tomography technology. It uses low-dose X-rays with different incidence angles for exposure, collects projection information of tissue and organ images at different angles, and obtains digital images at any coronal level of the examination site by filtered back projection method [13]. Compared with conventional CXR, it avoids many different the effect of overlapping density tissues on the display of fine structures in the lungs improves the ability to detect fine lesions in the lungs[14].DTS can obtain continuous coronal tomographic images, breaking through the "visual barrier" caused by the large number of anatomical structures overlapped on the conventional CXR to the diagnostician, and can show the detail of the lesion more clearly[15].

DTS can obtain continuous multi-layer images of the coronal position of the chest. Due to partial volume effects and human factors such as the breath of the subject, the area near the ribs, mediastinum and other high-density tissues shows poor microstructure of the lung tissue, which may appear missed diagnosis. However, DTS inspection equipment is easily available and the inspection method is simple, which can effectively reduce the radiation dose of the examinee. DTS examinations can perform conventional CXR examinations on the same examination equipment without the need for additional, separate equipment. Therefore, in clinical work, both routine examinations can be completed, and DTS examinations can be performed immediately on those cases that require further examination.

In recent years, many studies had also corroborated the important role of DTS in the discovery and follow-up of chest nodular lesions, and even the discovery and evaluation of lung cancer [16]. With the development and expansion of DTS technology, its role in the neck, breast [17], the thoracic spine, abdomen and skeletal system becomes more and more significant [18].

In this study, 21 cases of plaque ground glass lesions in both lungs were found among the 28 cases of DTS examination, 7 cases of thickened small blood vessels in ground glass opacities. 37 cases of conventional CXR showed only 10 cases of ground glass opacities, and 1 case of consolidation shadows. DTS showed that the ability of ground glass opacities was significantly higher than that of conventional CXR ($P<0.05$)

3.3 Chest CT examination

CT is transverse tomographic imaging, and can perform post-processing of multi-planar images such as coronal and sagittal. CT greatly reduces the effect of volumetric effects, the examination speed is fast, and it takes only one breath to complete the examination. The density and spatial resolution of the images are better than DTS films. Therefore, "The novel Coronavirus Diagnosis and Treatment Program (Seventh Edition Trial)" issued by the National Health Commission believes that CT imaging changes have important clinical value for the diagnosis and evaluation of COVID-19.The CT scan is fast and gets high resolution volume data, and can carry out various images post-processing, greatly improving the accuracy of the detection and diagnosis of COVID-19 pneumonia.

In this study, a total of 27 confirmed patients underwent CT examination, except for 3 cases where no positive lesion was found during the first chest CT examination, and 24 cases were positive. Compared with DTS, CT excepted for the discovery of 24 ground glass opacities in the lung [19]. In addition, there were more subtle structures that show signs of thickening of small blood vessels in the lesion, signs of bronchiole inflation, signs of thickening of leaflet septa, etc. than DTS. According to published reports, common CT findings consist of bilateral patchy ground glass opacities with peripheral predominance [20]. However, according to Fisher's exact probability test, there was no statistically significant difference between DTS and CT [21] in the diagnosis of ground glass opacities of COVID-19 pneumonia ($P > 0.05$) [22].

Considering the high dose X-rays of CT examination and the expense of it, DTS could replace CT scan as the economic screening imagines method to diagnosis the COVID-19 pneumonia.

3.4 Comparison of clinical application of different imaging examination methods

The early imaging manifestations of COVID-19 pneumonia are mainly ground glass opacities lesions. Ordinary CXR photos are difficult to find early COVID-19 pneumonia due to overlapping images and low resolution. As the COVID-19 pneumonia progresses, the density of the lesions can gradually increase to form a solid transformation. Portable radiography unit can only be used as a means to review and evaluate the efficacy of clinical treatment in patients with severe COVID-19 pneumonia. DTS is an image technology specially used to display the specific layer structure of tissue. The literature reported that DTS is significantly better than CXR for the detection of ground glass opacities in the lung [23]. Our results of this group were basically the same as those reported in the literature consistent. DTS can display lesions from the coronal plane. Though the formation of images is affected by the interference of ribs, heart beats, and respiratory movements of the subject. Compared with CT images, there is still a certain gap in the ability to display the lesions in the lungs. The CT examination results of the patients were compared, and statistical analysis showed that the difference between DTS and CT in the discovery of ground glass density lesions of COVID-19 pneumonia was not statistically significant, suggesting that the diagnostic efficacy of DTS for COVID-19 pneumonia is basically equivalent to CT, DTS can be used as an imaging examination method for preliminary screening of suspected cases.

The shortcomings of this study: The number of cases in this study is limited, and most of them were e mild or ordinary type of COVID-19 pneumonia. The lung inflammation is relatively simple, and some patients had lung inflammation later after the imaging examination.

In summary, the ability of DTS to detect the lesion of ground glass opacities of COVID-19 pneumonia is not significantly different from that of CT. The ability of DTS in this diagnosis is significantly better than CXR; DTS can be used as an important supplementary method for CT examination of COVID-19 pneumonia; CXR can be used as a method for the diagnosis and treatment of severe COVID-19 pneumonia.

Declarations

- **Ethics approval and consent to participate**

Institutional Review Board approval was obtained by Guangdong Second Provincial General Hospital, Guangdong Provincial Emergency Hospital. Written informed consent was obtained from all patients in this study.

- **Consent for publication**

My manuscript contains person’s images dates, consent for publication had been obtained from every person, and there was no children in our study. All the presentations of case reports had consent for publication.

Availability of data and materials

- The datasets during and analysed during the current study available from the corresponding author on reasonable request.
- **Competing interests**

The authors declare that they have no competing interests.

- **Funding**

The authors state that this work has not received any funding.

- **Authors' contributions**

GHL was a major contributor in writing the manuscript and completed the statistical analysis. QJZ analysed and interpreted the patients' image examination data regarding the COVID-19 disease. JTL rechecked the image examination result of the patients. LZ offered all the patients' images. YC and YSD supervised and guidance this manuscript. ZGW performed the original ideal. All authors read and approved the final manuscript.

Acknowledgements

Not applicable

References

[1] Dalglish SL. COVID-19 gives the lie to global health expertise. Elsevier 2020;395:1189.

[2] Zhu N, Zhang D, Wang W, et al. A Novel Coronavirus from Patients with Pneumonia in China, 2019. N Engl J Med 2020;382(8):727-33.

[3] □□□□□□□□□□□□□□□□□□□□□□□□□□□□□. In, 2020 http://www.nhc.gov.cn/yzygj/s7653p/202003/46c9294a7dfe4cef80dc7f5912eb1989.shtml

[4] Chen X, Tang Y, Mo Y, et al. A diagnostic model for coronavirus disease 2019 (COVID-19) based on radiological semantic and clinical features: a multi-center study. EUR RADIOL 2020.

[5] Fu F, Lou J, Xi D, et al. Chest computed tomography findings of coronavirus disease 2019 (COVID-19) pneumonia. EUR RADIOL 2020.

[6] Zhou S, Zhu T, Wang Y, et al. Imaging features and evolution on CT in 100 COVID-19 pneumonia patients in Wuhan, China. EUR RADIOL 2020.

[7] Xu X, Chen P, Wang J, et al. Evolution of the novel coronavirus from the ongoing Wuhan outbreak and modeling of its spike protein for risk of human transmission. SCI CHINA LIFE SCI 2020;63(3):457-60.

[8] Felix Chua DASR, Joseph Barnett VKOM, Ricardo José RVMR, et al. The role of CT in case ascertainment and management of COVID-19 pneumonia in the UK: insights from high-incidence regions. LANCET 2020.

[9] Dennie C, Hague C, Lim RS, et al. Canadian Society of Thoracic Radiology/Canadian Association of Radiologists Consensus Statement Regarding Chest Imaging in Suspected and Confirmed COVID-19. Canadian Association of Radiologists Journal 2020:93311700.

[10] Pereira RM, Bertolini D, Teixeira LO, et al. COVID-19 identification in chest X-ray images on flat and hierarchical classification scenarios. COMPUT METH PROG BIO 2020;194:105532.

[11] Jacobi A, Chung M, Bernheim A, et al. Portable chest X-ray in coronavirus disease-19 (COVID-19): A pictorial review. CLIN IMAG 2020;64:35-42.

[12] Revel M, Parkar AP, Prosch H, et al. COVID-19 patients and the radiology department – advice from the European Society of Radiology (ESR) and the European Society of Thoracic Imaging (ESTI). EUR RADIOL 2020.

[13] Tongkum S, Suwanpradit P, Vidhyarkorn S, et al. Determination of radiation dose and low-dose protocol for digital chest tomosynthesis using radiophotoluminescent (RPL) glass dosimeters. Phys Med 2020;73:13-21.

[14] Dobbins JT, McAdams HP, Godfrey DJ, et al. Digital tomosynthesis of the chest. J Thorac Imaging 2008;23(2):86-92.

[15] Wu JT, Leung K, Leung GM. Nowcasting and forecasting the potential domestic and international spread of the 2019-nCoV outbreak originating in Wuhan, China: a modelling study. LANCET 2020;395(10225):689-97.

[16] Chauvie S, De Maggi A, Baralis I, et al. Artificial intelligence and radiomics enhance the positive predictive value of digital chest tomosynt hesis for lung cancer detection within SOS clinical trial. EUR RADIOL 2020.

[17] Li Y, He Z, Lu Y, et al. Deep learning on mammary glands distribution for architectural distortion detection in digital breast tomosynthesis. Phys Med Biol 2020.

[18] Ferrari A, Bertolaccini L, Solli P, et al. Digital chest tomosynthesis: the 2017 updated review of an emerging application. Annals of translational medicine 2018;6(5):91.

[19] Yin Z, Kang Z, Yang D, et al. A Comparison of Clinical and Chest CT Findings in Patients With Influenza A (H1N1) Virus Infection and Coronavirus Disease (COVID-19). AJR Am J Roentgenol 2020;215:1-7.

[20] Liang T, Liu Z, Wu CC, et al. Evolution of CT findings in patients with mild COVID-19 pneumonia. EUR RADIOL 2020.

[21] Erturk SM. CT Is Not a Screening Tool for Coronavirus Disease (COVID-19) Pneumonia. AJR 2020;215:W1.

[22] Miyata K, Nagatani Y, Ikeda M, et al. A phantom study for ground-glass nodule detectability using chest digital tomosynthesis with iterativ e reconstruction algorithm by ten observers: association with radiation dose and nodular characteris tics. Br J Radiol 2017;90(1071):20160555.

[23] Nagatani Y, Takahashi M, Ikeda M, et al. Sub-solid nodule detectability in seven observers of seventy-nine clinical cases: comparison between ultra-low-dose chest digital tomosynthesis with iterative reconstruction and chest radiography by re ceiver-operating characteristics analysis. EUR J RADIOL 2018;107:166-74.

Figures

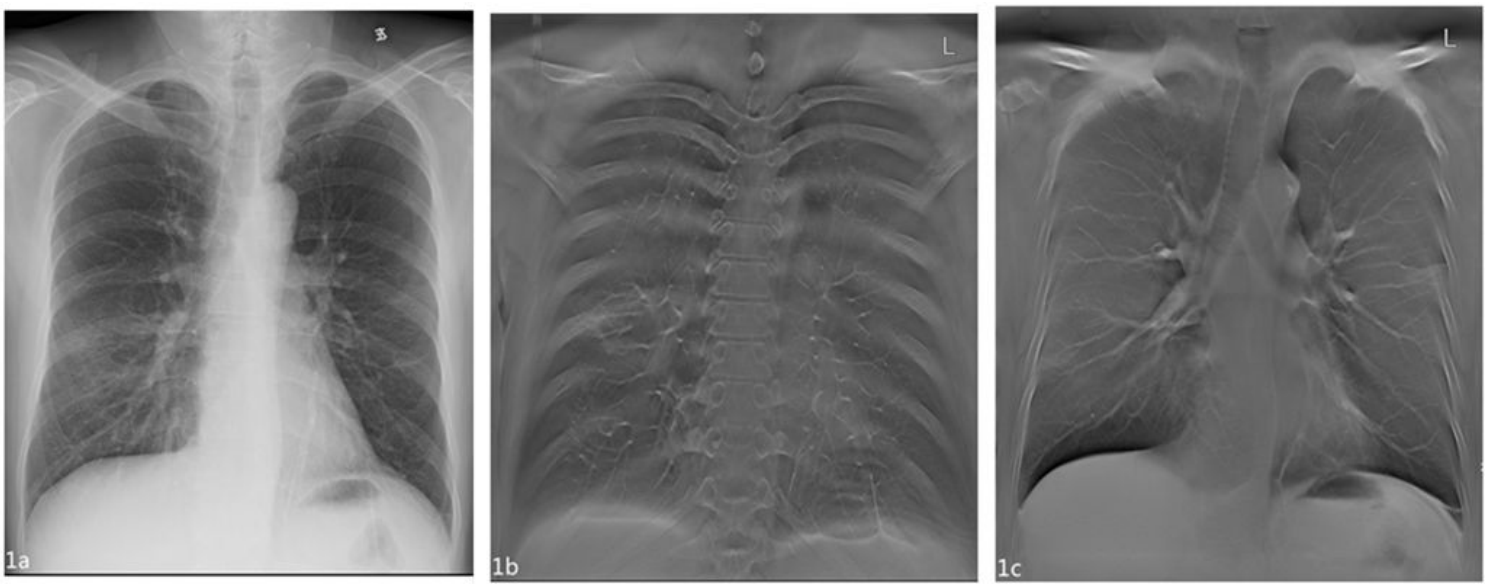

Figure 1

Male patient, 25-30years old, temperature 38.0℃. On January 20, he came to GuangZhou from XianNing, HuBei province. The COVID-19 nucleic acid test was positive on January 28. 1a: The CXR on January 24,2020both of the middle of lung field showed ground glass opacities. Fig b,c On the same day(2020-1-24), the DTS showed multiple flaky ground glass opacities in the both lungs field in different lays, it also showed the uneventhickening of small blood vessels .

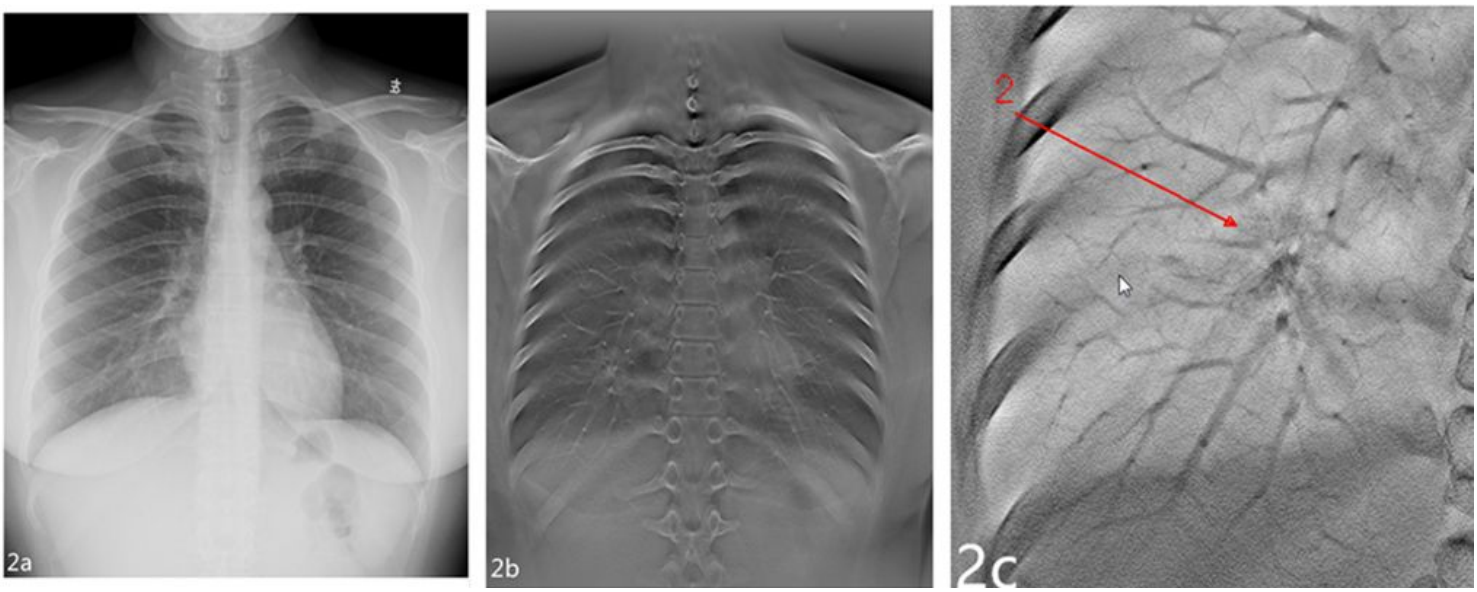

Figure 2

Famle 30-35 years old, had fever for 1day with uncomfortable in the throat. She had been WuHan, HuBei on Janaury 18, 2020. On January 22, she began to heve fever, the max tempeature is 37.9℃,then she came back to GuangZhou on January 23. Her parents came along with her, both of them got fever and had treatment in hospital on January 28. All of these three patients'COVID-19 nucleic acid test were positive on January 29. a The CXR on January 29,2020it showed no abnormal in the picture. (b,c (picture C is the Partially enlarged view) the DTS showed ground glass opacitiesdistributed around the bronchial vessels on the right lower lung, the air bronchial sign could been seen.

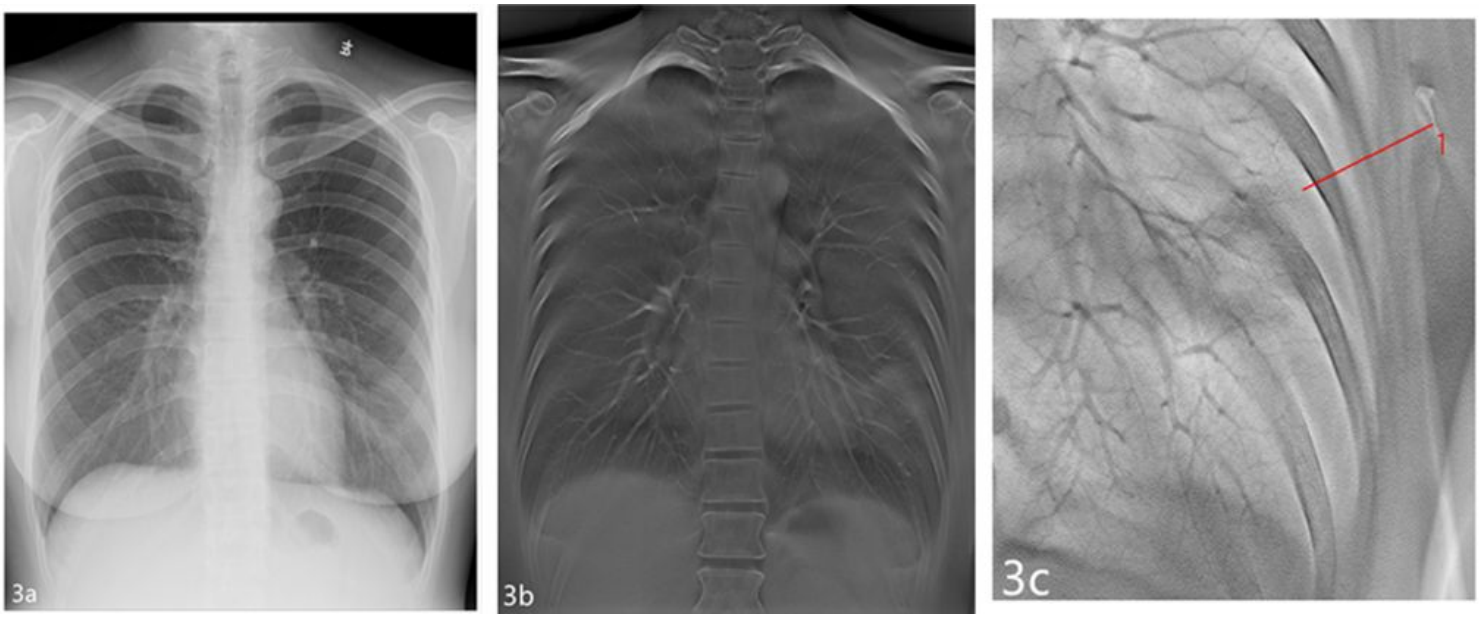

Figure 3

Famle 35-40 years old. She traveled from WuHan to Philippines on January,20,2020she got fever when she back to GuangZhou on January 28,T39.5℃ without cough and sputum . The COVID-19 nucleic acid test was positive on January 31. 3(a) The CXR on January 28,2020it showedthe left lower lung field faintly seen flaky shadows with uneven density. 3 b,c (picture C is the Partially

enlarged view) On the same day, the DTS showed ground glass opacities in the left lower lung field, low center density, showed anti-halo sign.

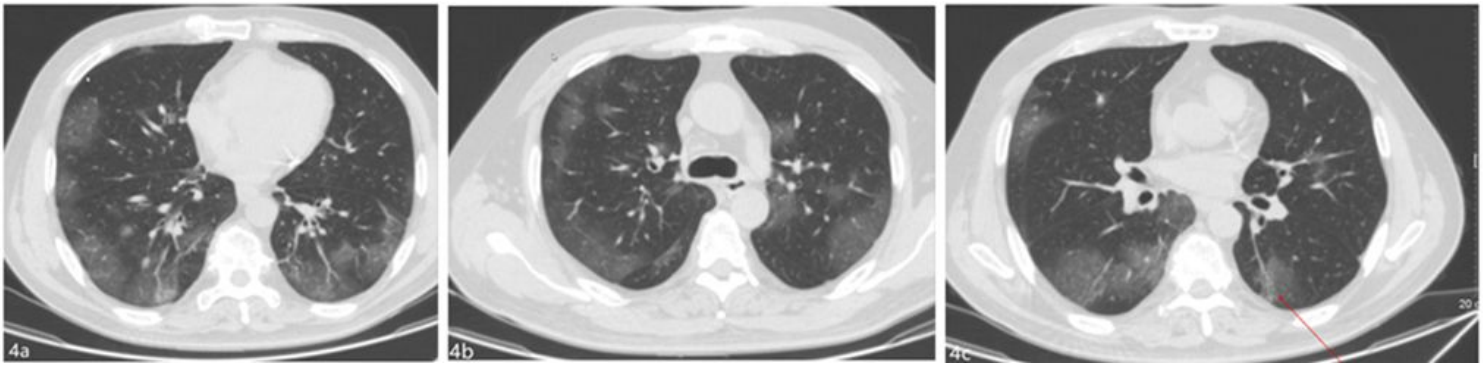

Figure 4

a-c Male, 50-55 years old, got fever for 6 days with sweating, body temperature 37.0 ℃ to 37.5 ℃,no cough, sputum, chest pain, chest tightness. The body temperature increased to 38 ℃, the condition gradually aggravated, with dyspnea, cough, and a small amount of yellow sputum. The COVID-19 nucleic acid test was"weakly positive". He had diabetes, coronary heart disease coronary stent implantation.2020-01-19, he had meals with a fever patient from WuHan. (a-c 2020-2-1 CT showed The ground glass opacities of the two lungs are unequal in size, with the middle and lower lungs being the most prominent. The large lesions in the right lung subpleural area are in the shape of a lunar arch, with air bronchial sign and thickening of the wall.