Impact of Adjuvant Amniotic Membran Transplantation In Infectious Ulcerative Keratitis

Okyanus Bulut
Ege University Faculty of Medicine: Ege Universitesi Tip Fakultesi
Gunel Musayeva
Ege University Faculty of Medicine: Ege Universitesi Tip Fakultesi
ozlem barut selver (ozlembarutselver@yahoo.com)
Ege University Faculty of Medicine: Ege Universitesi Tip Fakultesi https://orcid.org/0000-0003-3333-3349

Research Article

Keywords: Amniotic membrane, cornea, infectious keratitis

Posted Date: February 28th, 2022

DOI: https://doi.org/10.21203/rs.3.rs-1327742/v1

Abstract

PURPOSE: To evaluate the impact of adjuvant human amniotic membrane transplantation(hAMT) in patients with infectious ulcerative keratitis on wound healing without waiting for the sterile phase of the infectious keratitis.

METHODS: A retrospective cohort study based on medical records of patients who underwent hAMT procedure over a 2-year period (2020-2021) was conducted at Ege University Hospital, Turkey. Cryopreserved hAM was used. Best corrected visual acuity (BCVA) was measured with the Snellen chart. Detailed ophthalmological examination was performed at all visits. Treatment success was defined as complete healing including disappearance of corneal infiltrates, epithelial defect closure, reduction of anterior segment reaction.

RESULTS: A total of 13 eyes of 12 patients who were diagnosed with ulcerative keratitis between 2020-2021. The mean age was 60.9 years and 66.6% of the patients were male. Average ulcer horizontal diameter was 9.7 (4.5–12) mm. A single layer human amniotic membrane (hAM) was transplanted 92.3% of eyes. Overlay technique was used in all patients for hAMT. The mean residence time of the amniotic membrane on the ocular surface was 13.3 (5-40) days. The mean time from the first presentation to the hAM transplantation was 9.8 (3-30) days. The average hospitalization time of all patients was 15 (3-46) days, pre- hAMT was 10.2 days and post hAMT was 4.8 days. The mean follow up time was 3 months. Recovery response was positive in 76.9%. Average healing time was 32.1 (6-57) days.

CONCLUSIONS: hAMT was effective in the treatment of infectious ulcerative keratitis by accelerating wound healing and supporting the ocular surface biochemically and mechanically. Performing hAM transplantation at the early stages of the disease and prolonged residence of membrane on the ocular surface increase the success of the treatment and moreover abbreviates hospitalization time.

Introduction

The human amniotic membrane (hAM) is the deepest layer of the fetal membranes and consists of three parts: epithelium, basement membrane and stroma. The aids of the hAM are based on its anti-inflammatory, anti-microbial, anti-angiogenic properties and depends on not stimulating immune mechanisms. [1], [2]. It is known that the hAM is an excellent biological substrate by reducing water loss and apoptosis, containing several growth factors, facilitating to maintain normal epithelial cell morphology, promoting wound healing and new cell growth. It also contains multiple antiangiogenic proteins, which inhibits neovascularization [3].

Besides the prominent physical advantages, general availability of the tissue for grafting and low immun response are unique specialties of the hAM [4]. Required surgical procedure is relatively easy with minimal postoperative complications [5].

hAMT is a common surgical procedure for the treatment of ocular surface pathologies such as autoimmune persistent corneal epithelial defects, vernal keratoconjunctivitis, limbal stem cell deficiency, bullous keratopathy and conjunctival reconstruction. [6] Infectious keratitis is one of the further indications of hAMT due to its antimicrobial nature. Also, surface material effect is advantageous for severe infectious keratitis cases in order to prevent progression of corneal melting to perforation. [7] In a recent metanalysis, it was stated that hAMT usage tends to be reserved as a second-line therapy in infectious keratitis, mainly to promote cornea healing in non-healing ulcer after the sterilization phase. Thus, the value of using AMT in addition to antimicrobial treatment during the active phase of infectious keratitis remains still uncertain.

In the present study, it is aimed to evaluate the impact of adjuvant hAMT in infectious keratitis on wound healing without waiting for the sterile phase of the infectious keratitis.

Methods

Patients who were admitted to Ege University Department of Ophthalmology between the years of 2020–2021 with infectious keratitis who underwent hAMT were included. Medical records of patients including age, gender, causative microorganism, applied medical therapy, clinical features of keratitis from onset to final visit, healing response and complications after hAMT procedure were reviewed.

Reduction of inflammation, restoration of ocular surface epithelial integrity and improvement of anterior chamber reaction were defined as effective treatment findings. hAMT was performed under local anesthesia by using overlay technique in all patients by same surgeon (OBS). Patients who underwent other types of surgical intervention rather than the hAMT during the initial management were excluded.

Statistical analysis for the data obtained from the study was performed using SPSS v.20.0 (IBM Co. Armonk, NY, USA).

Results

A total of 13 eyes of 12 patients with infectious keratitis who underwent hAMT procedure were included in the study (Fig. 1). The mean age was 60.9 years and 66.6% of the patients were male.

Causative factors were proven in 3 patients. Staph aureus growth was seen in cultures of a patient who underwent immunosuppressive treatment. Achantamoeba was demonstrated with the aid of confocal microscopy in a patient with contact lens wear (Fig. 2). Fusarium solani was isolated in one patient with ocular trauma history. In 4 patients, ocular examination findings were consistent with herpetic keratitis. Patients with known causative agents received appropriate antimicrobial treatment and rest of them received empiric antimicrobial treatment. There was no sign of endophthalmitis in any patient at the presence and none of the patient’s infection was progressed to endophthalmitis during the follow up. Excluding one patient with absolute glaucoma diagnosis, ocular pressure values were in normal limits.

Predisposing factors including topical steroid use (4) and surgical trauma (4; penetrating keratoplasty, phacoemulsification, trabeculectomy), poorly controlled diabetes mellitus presence (2) and chemotherapy use (1; oropharyngeal squamous cell carcinoma) were observed in 11 patients.

Average ulcer horizontal diameter was observed as 9.7 (4.5–12) mm. Total corneal staining was observed in 7 eyes and four of them had anterior chamber reaction accompanied by hypopyon. Characteristics of the ulcers are shown in Table 1.

A single layer hAMT procedure was performed with the overlay technique 92.3% of eyes and two layers were performed in only one patient.

The mean time between first presentation and hAMT was 9.8 (3–30) days. The average hospitalization time of all patients was 15 (3–46) days, pre- hAMT was 10.2 days and post hAMT was 4.8 days. Six patients who underwent hAMT in 7 days or less from the first presentation, the average recovery time was 29 days, and if it is over 14 days, it was extended to 41 days. The mean follow up time was 3 months.

The mean remaining time of the hAM on the ocular surface was 13.3 (5–40) days, and the cause of premature separation from the ocular surface was suture rupture in 7 eyes. Three patients with premature separation underwent multiple hAMT procedures due to the absence of ulcer healing and the hAM remaining time were calculated separately for each procedure.

Baseline BCVA of the patients ranged between no light perception and 1 meter.

Recovery response was positive in 76.9% (10 eyes) with an average healing time of 32.1 (6–57) days. One patient (2 eyes) who did not respond to treatment was receiving aggressive chemotherapy. The other nonresponding patient (1 eye) with Fusarium solanii keratitis underwent therapeutic keratoplasty twice after failure of intensive medical treatment (Fig. 3). Recovery findings are summarized in Table 2.

Discussion

hAMT in infectious disease are generally based on the antimicrobial and anti-inflammatory advantages of hAM. Antimicrobial activity is associated with the presence of several components in the amniotic fluid, including lysozyme, transferrin, and immunoglobulin [1]. Additionally, studies have shown that hAM can act as an effective reservoir of antimicrobials and provide sustained medication in compiled treatment [9]. Anti-inflammatory function of hAM ensues through regulation of T cell function and anti-inflammatory secretion [10].

In the literature, microbial keratitis due to several causative microorganism has been reported to be treated with hAMT. Herpetic keratitis is one of these infectious keratitis categories. In herpetic keratitis, associated neurotrophic keratopathy, causes delay in corneal healing [11] [12] .Therefore, hAMT serves as a useful adjunctive therapy by inducing corneal epithelial regeneration in this clinical situation. Although the benefits in herpetic keratitis have not been established in randomized controlled trials, a high rate

(94%) of complete corneal healing was demonstrated [13]. In the present study, healing response was reported to be 100% in herpes keratitis patients.

Resistant bacterial keratitis is another indication for hAMT. In previous studies, successful results as immediate pain relief and epithelial recovery in patients with bacterial keratitis who were treated by topical antibiotics and hAMT was reported [7]. In the present study, patients with proven causative agents received appropriate treatment, while patients with unknown causative agents were treated with empirical antibiotic therapy, and the majority showed a recovery response to combined antimicrobial and hAMT treatment. Both eyes of one patient, who was receiving immunosuppressive treatment for terminal stage oropharyngeal squamous cell cancer, hAMT was unsuccessful.

In fungal keratitis, in which pathogens usually infiltrates deep layers of cornea, hAMT may not be effective. In such cases, antifungal treatment may also be insufficient due to the minimal corneal stromal penetration of topical antifungal medications[14]. Chen et al [15] showed that in fungal corneal ulcers, amniotic membrane lysis was prominent and 25% of the cases required keratoplasty. In the present study, in one fungal (Fusarium solani) keratitis patient, who had a history of organic based trauma, combination of hAMT and antifungal therapy were ineffective. Patient underwent two therapeutic keratoplasty surgery in order to control infection.

Acanthamoeba infection is one of the most feared keratitis types especially in contact lens wearers. hAMT was reported to be effective in patients with Acanthamoeba keratitis [13] [16] [17]. In the present study, one patient with Acanthamoeba keratitis had an absolute recovery response after hAMT additionally to appropriate medical therapy.

There are several factors such as ulcer size and inflammation grade, effecting the hAMT success in infectious keratitis beside the causative microorganism. Abdulhalim et al [18] and Chen et al [15] reported the success rates as 90% and 83%, in average ulcer sizes of 5.45 ± 1.73 mm and 5.43 ± 2.61 mm, respectively. In the present study, hAMT success rate was observed to be 76.9% with an average ulcer size of 9.7 (4.5–12) mm, which is consistent with the estimated efficiency according to the previous reports in a larger average ulcer size.

Another factor that may affect the hAMT success in infectious keratitis is the time duration between the presentation and hAMT intervention. It was emphasized that in clinical practice, hAMT usage tends to be reserved as a second-line therapy in infectious keratitis, mainly to promote cornea healing in non-healing ulcer after the sterilization phase. Thus, the value of using hAMT in addition to antimicrobial treatment during the active phase of infectious keratitis remains still uncertain [13]. In the present study, it was aimed to evaluate the antimicrobial effect of hAM on wound healing without waiting for the sterile phase of the infectious keratitis. In this direction, the cases in which hAM application was performed in the first 7 days of the presentation tends to be successful in order to control the infection and promote wound healing than the cases in which hAMT was performed after the 7 days of presentation. Moreover, average recovery time was prolonged after hAMT which was performed after the first 7 days of presentation. This

observation reveals that an initial hAMT within 2 weeks of the therapy may probably support decrease inflammation, induce healing of infectious ulcers.

The facilitating effect of antimicrobial agent maintenance and its tectonic features are also prominent for the hAMT usage in infectious keratitis. Although, the more prolonged residency of hAM on ocular surface may provide better results in especially inflammatory situations, membrane dissolvement becomes faster due to the increased proteolytic features of the ocular surface[19] [20]. Kheirkhah at al [21] revealed the amniotic membrane lysis time as 5.8 ± 1.2 days (range, 4 to 8 days) in microbial keratitis. In the present study, the residence time of the amniotic membrane on the ocular surface was a slight longer with 13.3 days of average. The higher success rate of the present study may be attributed to this longer the amniotic membrane residence time on the ocular surface. Also, in severe cases of keratitis, it may be necessary to repeat hAMT in order to provide extended properties of hAM on healing time [7]. In the present study, average hAMT surgery was 1,46 for each eye.

Additionally, hAM has reported to be have an effect of shortening the healing time with 4.08 days of average in microbial keratitis[13]. Zeng et al. [22] showed that the average healing time was statistically shorter in the hAMT group (6.89 ± 2.98d), compared to the control group (10.23 ± 2.78d). In the present study average healing time of 32.1 (6–57) days with hAMT was found to be consistent with the previous literature.

Moreover, there is a pain relief advantage of hAMT. This relief has been attributed to the biological patch feature and anti-inflammatory effects of the membrane [23]. In the present study, the mean hospitalization time was shortened after hAMT. hAM facilitates outpatient follow up of the patient by acting as a biological bandage for tectonic purposes, which may prevent the patient form additional resistant hospital-based infections, maintain the antimicrobial agent presence on the ocular surface and relieving the pain.

In conclusion, hAM application in infectious keratitis can be performed in the early period without waiting for the sterile phase following antimicrobial treatment with relatively higher success possibility. Its antimicrobial, and anti-inflammatory features facilitate the control of the disease. Also, hAMT usage in infectious keratitis shortens the healing and hospitalization time.

Declarations

Conflicts of interest/Competing interests: The authors have no relevant financial or nonfinancial interests to disclose. Author Okyanus Bulut declares that she has no conflict of interest. Author Gunel Musayeva declares that she has no conflict of interest, author Ozlem Barut Selver declares that she has no conflict of interest.

Funding: No funds, grants, or other support were received.

Conflicts of interest/Competing interests: The authors have no relevant financial or nonfinancial interests to disclose. Author Okyanus Bulut declares that she has no conflict of interest. Author Gunel Musayeva declares that she has no conflict of interest, author Ozlem Barut Selver declares that she has no conflict of interest.

Ethics approval: All procedures performed in studies involving human participants were in accordance with the ethical standards of the institutional and/or national research committee and with the 1964 Helsinki declaration and its later amendments or comparable ethical standards.

Animal Research: Not applicable

Plant Reproducibility: Not applicable

Clinical Trials Registration: Not applicable

Consent to participate: Informed consent was obtained from all individual participants included in the study.

Consent for publication: All authors read the final manuscript and give consent for the article to be published.

Availability of data and material: Not applicable

Code availability: Not applicable

Acknowledgement: None

Authors' Contributions: Okyanus Bulut was responsible for conducting research, screening potentially eligible studies, extracting and analyzing data, drafting manuscript. Gunel Musayeva was responsible for helping to draft the manuscript. Ozlem Barut Selver was responsible for designing the study protocol, coordinating the study, interpreting results and providing feedback on the final report. All authors read and approved the final manuscript.

Compliance with Ethical Standards

Funding: No funds, grants, or other support were received.

Ethical approval: All procedures performed in studies involving human participants were in accordance with the ethical standards of the institutional and/or national research committee and with the 1964 Helsinki declaration and its later amendments or comparable ethical standards.

Informed consent: Informed consent was obtained from all individual participants included in the study.

References

1. Solomon MD (2001) Suppression of Interleukin1 alpha and Interleukin1 beta in the human limbal epithelial cells cultured on the amnitic membrane stromal matrix. Br J Ophthalmol 85:444–449
2. Hori J, Wang M, Kamiya K, Takahashi H, Sakuragawa N (2006) “Immunological Characteristics of Amniotic Epithelium,” *Cornea*, vol. 25, no. Supplement 1, pp. S53–S58, doi: 10.1097/01.ico.0000247214.31757.5c
3. Ohno-Matsui K et al (2005) “The effects of amniotic membrane on retinal pigment epithelial cell differentiation,” *Mol. Vis.*, vol. 11, no. January, pp. 1–10,
4. Iakimenko SA, Buznyk OI, Rymgayllo-Jankowska B (2013) Amniotic membrane transplantation in treatment of persistent corneal ulceration after severe chemical and thermal eye injuries. Eur J Ophthalmol 23(4):496–503. doi: 10.5301/ejo.5000243
5. Casalita V, Nora RLD, Edwar L, Susiyanti M, Sitompul R (2020) Amniotic membrane transplantation for infectious corneal ulcer treatment: A cohort retrospective study. Med J Indones 29(4):379–385. doi: 10.13181/mji.oa.203849
6. Heiligenhaus A, Bauer D, Meller D, Steuhl KP, Tseng SCG (2001) Improvement of HSV-1 necrotizing keratitis with amniotic membrane transplantation. Investig Ophthalmol Vis Sci 42(9):1969–1974
7. Gicquel JJ, Bejjani RA, Ellies P, Mercié M, Dighiero P (2007) Amniotic membrane transplantation in severe bacterial keratitis. Cornea 26(1):27–33. doi: 10.1097/ICO.0b013e31802b28df
8. Zarbin M, Chu D, Dua HS, Gomes JAP, King AJ, Maharajan VS (2004) DIAGNOSTIC AND SURGICAL TECHNIQUE The Amniotic Membrane in Ophthalmology. 49. 10.1016/j.survophthal.2003.10.004. 1
9. Yelchuri ML, Madhavi B, Gohil N, Sajeev HS, Prajna NV, Srinivasan S (2017) In vitro evaluation of the drug reservoir function of human amniotic membrane using moxifloxacin as a model drug. Cornea 36(5):594–599. doi: 10.1097/ICO.0000000000001168
10. Laranjeira P et al (2018) Amniotic membrane extract differentially regulates human peripheral blood T cell subsets, monocyte subpopulations and myeloid dendritic cells. Cell Tissue Res 373(2):459–476. doi: 10.1007/s00441-018-2822-1
11. Sibley D, Larkin DFP (2020) Update on Herpes simplex keratitis management. Eye 34(12):2219–2226. doi: 10.1038/s41433-020-01153-x
12. Semeraro F et al (2014) Neurotrophic keratitis. Ophthalmologica 231(4):191–197. doi: 10.1159/000354380
13. Ting DSJ, Henein C, Said DG, Dua HS (2021) Amniotic membrane transplantation for infectious keratitis: a systematic review and meta-analysis. Sci Rep 11(1):1–15. doi: 10.1038/s41598-021-92366-x
14. Thatte S, Choudhary U, Sharma B (2017) Efficacy of Amniotic Membrane Transplantation in Refractory Infective Keratitis Leading to Stromal Thinning, Descematocele and Perforations. 3:1–6. 10.19080/JOJO.2017.03.555611. 3
15. Chen HC, Tan HY, Hsiao CH, Huang SCM, Lin KK, Ma DHK (2006) Amniotic membrane transplantation for persistent corneal ulcers and perforations in acute fungal keratitis. Cornea 25(5):564–572. doi: 10.1097/01.ico.0000227885.19124.6f

16. Kim JS, Kim JC, Hahn TW, Park WC (2001) Amniotic membrane transplantation in infectious corneal ulcer. Cornea 20(7):720–726. doi: 10.1097/00003226-200110000-00010
17. Bourcier T et al (2004) Importance of amniotic membrane transplantation in the treatment of severe Acanthamoeba keratitis. Can J Ophthalmol 39(6):621–631. doi: 10.1016/s0008-4182(04)80027-9
18. Abdulhalim BEH, Wagih MM, Gad AAM, Boghdadi G, Nagy RRS (2015) Amniotic membrane graft to conjunctival flap in treatment of non-viral resistant infectious keratitis: A randomised clinical study. Br J Ophthalmol 99(1):59–63. doi: 10.1136/bjophthalmol-2014-305224
19. Chen JHC, Ma DHK, Tsai RJF (2002) Amniotic membrane transplantation for pseudomonal keratitis with impending perforation. ” Chang Gung Med J 25(3):144–152
20. Riley SC, Leask R, Denison FC, Wisely K, Calder AA, Howe DC (1999) Secretion of tissue inhibitors of matrix metalloproteinases by human fetal membranes, decidua and placenta at parturition. J Endocrinol 162(3):351–359. doi: 10.1677/joe.0.1620351
21. Kheirkhah A, Tabatabaei A, Zavareh MK, Khodabandeh A, Mohammadpour M, Raju VK (2012) A controlled study of amniotic membrane transplantation for acute Pseudomonas keratitis. Can J Ophthalmol 47(3):305–311. doi: 10.1016/j.jcjo.2012.03.014
22. Bo Z, Ping W, Ling Juan X, Xin Yu L, Zhang H, Gui Gang L (2014) Amniotic membrane covering promotes healing of debridement for fungal keratitis cornea epithelium and improves visual acuity after debridement for fungal keratitis. Int J Ophthalmol 7(3):785. doi: 10.3980/j.issn.2222-3959.2015.03.38
23. Espana EM et al (2003) Amniotic membrane transplantation for bullous keratopathy in eyes with poor visual potential. J Cataract Refract Surg 29(2):279–284. doi: 10.1016/S0886-3350(02)01525-0

Tables

Table 1.

Variable	n (%) N=13
Ulcer features	
Location	
Central	4 (30.7)
Paracentral	2 (15.3)
Total	7 (53.8)
Hypopyon	4 (30.7)
Size	
4-9mm	5(38.4)
>9mm	8 (61.5)

Table2.		Outcomes, n(%)	
hAMT outcomes	**n(%)**	**Success**	**Failure**
Risk factor (n=12)*			
Topical steroid use	4(30.7)	4(100)	-
Non surgical trauma	1(7.6)	-	1(100)
Surgical trauma	4(30.7)	4(100)	-
Contact lens use	1(7.6)	-	1(100)
Immunosupression and chemo	2(15.2)	-	2(100)
Poor controlled diabetes mellitus	2(15.2)	2(100)	-
Antiglaucomatous use	2(15.2)	2(100)	-
Etiology (n=8)			
Achantamoeba	1(12.5)	1(100)	-
Herpes virus	4(50)	4(100)	-
Fusarium solani	1(12.5)	-	1(100)
Staph aureus	2(25)	-	2(100)
Ulcer location and size (n=13)			
Central	4(23)		
4-9 mm	3(75)	3(100)	-
9-12 mm	1(25)	1(100)	-
Paracentral	2(15.3)		
4-9 mm	2(100)	2(100)	-
Total	7(53.8)	5(71.4)	2(28.5)
Time to first presentation to hAMT(n=13)			
≤7 days	6(46.1)	6(100)	-
7-14 days	6(46.1)	3(50)	3(50)
>14 days	1(7.6)	-	1(100)

Ham duration on ocular surface(n=19)**			
≤7 days	6(31.5)	3(50)	3(50)
7-15 days	10(52.6)	5(50)	5(50)
>15 days	3(15.7)	2(66.6)	1(33.3)

* Two eyes had multiple predisposing factors

**Repeated hAMT were also included and all applications with early separation from the ocular surface were evaluated as failure

Figures

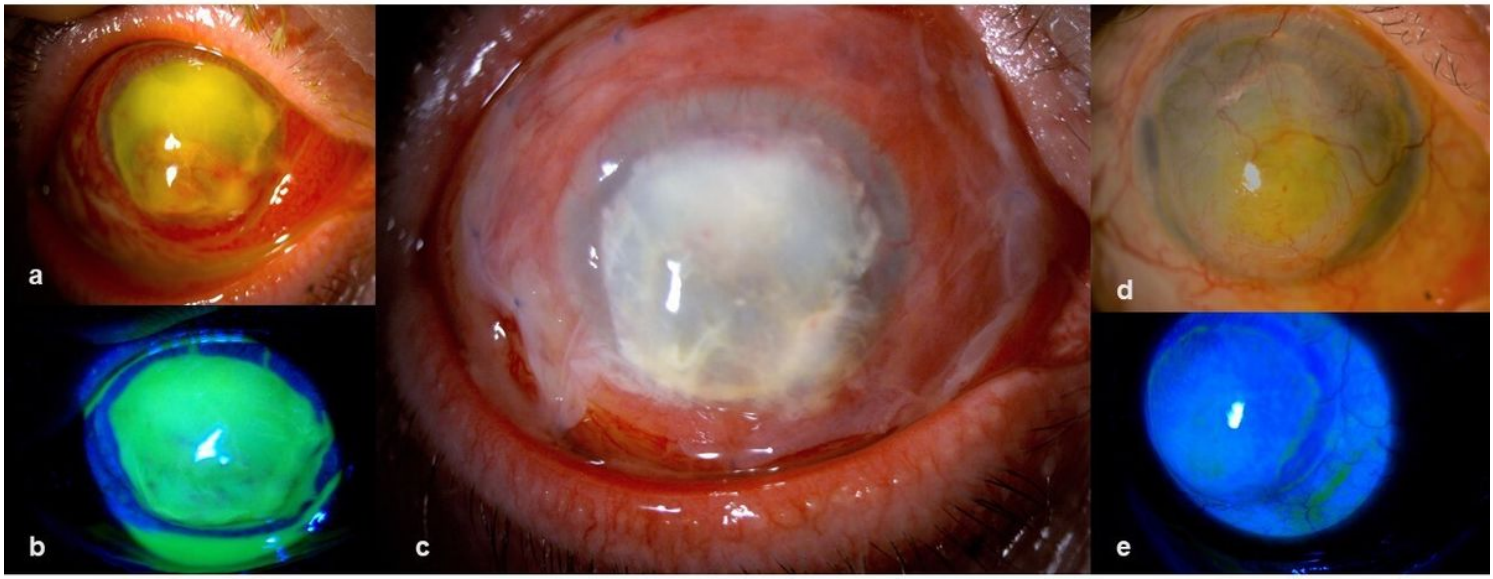

Figure 1

Demonstration of hAMT surgery as an adjuvant treatment in ulcerative microbial keratitis. Total corneal ulcerative keratitis, melting (A) and fluorescein staining (B) was observed in slit lamp examination. hAMT was performed (C). An absolute recovery response (D, E) was achieved.

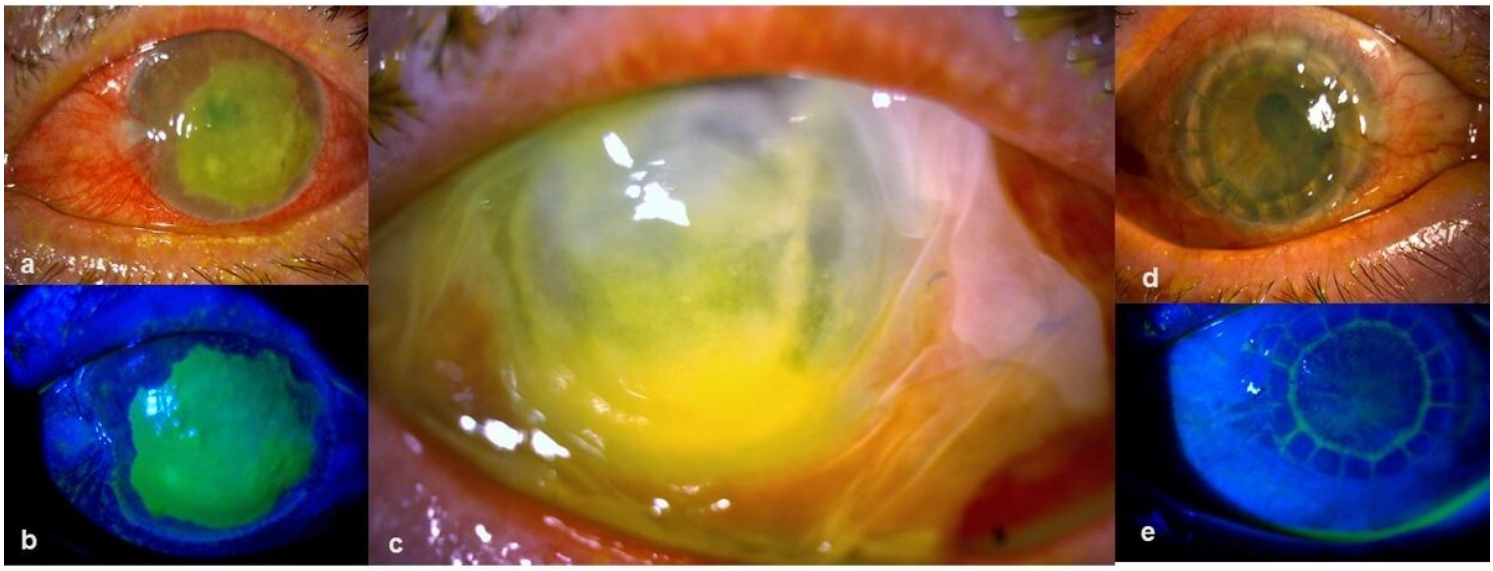

Figure 2

Illustration of Achantamoeba keratitis case. Slit lamp examination (A) and fluorescein staining (B) of 28-year-old female who wore soft contact lenses, revealed a central stromal infiltrate with hypopyon. hAMT was performed (C). Then, epithelialization was completed (D) and was negative for fluorescein staining (E).

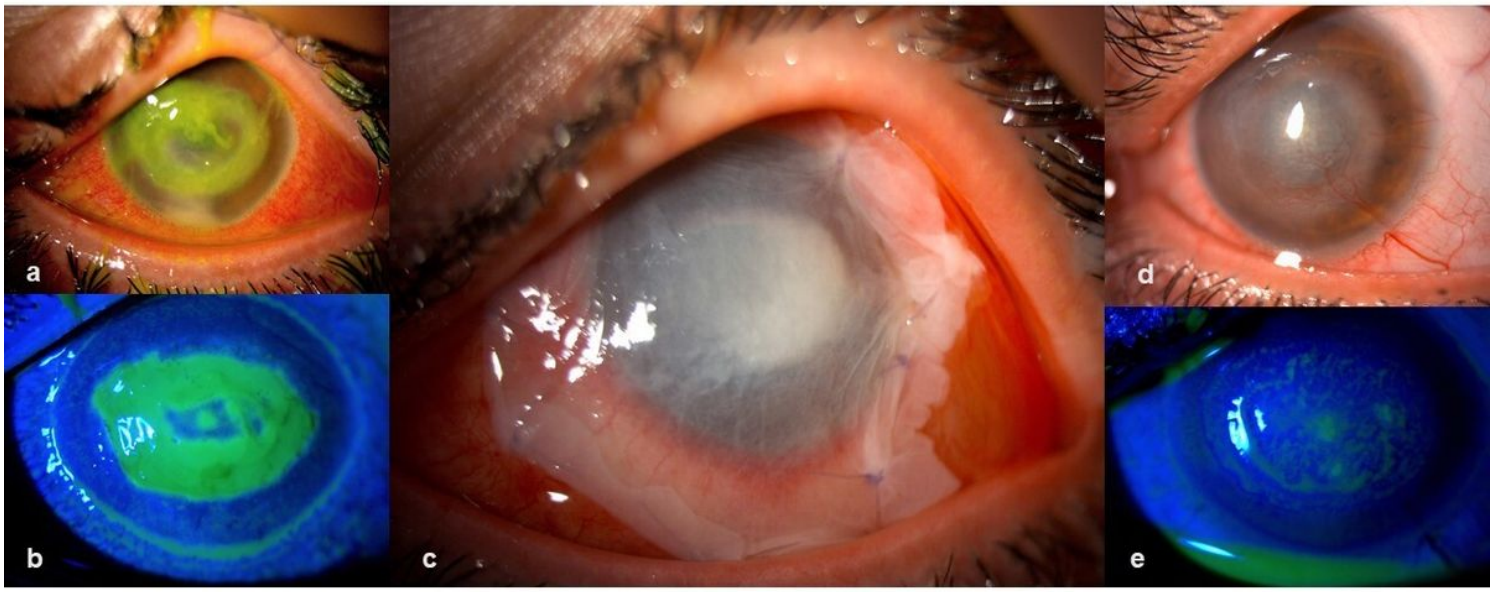

Figure 3

A 59-year-old male patient had an organic based trauma, suffered from keratitis caused by Fusarium solani. At presentation, a central dense stromal infiltrate was noted (A, B). hAMT was performed (C). After patient underwent two therapeutic keratoplasty surgery, the infection was under control (D, E)