Research Square

Preprints are preliminary reports that have not undergone peer review. They should not be considered conclusive, used to inform clinical practice, or referenced by the media as validated information.

Endoscopic Management for Difficult Biliary Cases in the era of Laparoscopic Surgery

Cosmas Rinaldi Adithya Lesmana (medicaldr2001id@yahoo.com)
Hospital Dr Cipto Mangunkusumo: Rumah Sakit Dr Cipto Mangunkusumo https://orcid.org/0000-0001-9992-9968

Maria Satya Paramitha
Hospital Dr Cipto Mangunkusumo: Rumah Sakit Dr Cipto Mangunkusumo

Yulia Estu Pratiwi
Digestive Disease & GI Oncology Center, Medistra Hospital, Jakarta

Laurentius Adrianto Lesmana
Digestive Disease & GI Oncology Center, Medistra Hospital, Jakarta

Research Article

Keywords: Difficult biliary cases, biliary leakage, biliary obstruction, endoscopic retrograde cholangiography, laparoscopic procedure

Posted Date: April 6th, 2022

DOI: https://doi.org/10.21203/rs.3.rs-1334564/v1

License: This work is licensed under a Creative Commons Attribution 4.0 International License. Read Full License

Abstract

Background: Biliary disorders are still the most challenging cases in the field of gastroenterology, as comprehensive clinical evaluation and treatment considerations are still necessary. In the era of laparoscopic procedure, there are a lot of innovations on non-surgical management approaches, such as endoscopic retrograde cholangiopancreatography (ERCP) and endoscopic ultrasound (EUS). Since there is no clear consensus yet in managing complicated biliary disorders, this study is aimed to see the impact of endoscopic management for difficult biliary cases.

Methods: A cohort-retrospective endoscopy database study was conducted at a tertiary-referral private hospital in Jakarta, Indonesia, between January and December 2020. Difficult biliary cases defined as biliary case which required at least one of the following conditions: multi-management approach, biliary obstruction with cholangitis or biliary sepsis, difficult CBD stone, recurrent CBD stone, or advanced progressive malignant biliary obstruction.

Results: Sixty-one subjects in this retrospective database study were suitable as difficult biliary cases. The proportions of malignant and non-malignant etiologies were similar (44.3% *versus* 55.7%, respectively). In this study, 68.8% of all subjects underwent standard therapeutic ERCP procedure, while 16.4% of the subjects underwent combination of therapeutic ERCP and EUS in one session based on the complexity of the case; and 8.2% of the subjects underwent therapeutic ERCP with additional single operator cholangioscopy procedure. One subject underwent rendezvous ERCP procedure through percutaneous approach. Around 4.9% of the subjects underwent EUS-biliary drainage procedure. The technical success rate of all procedures was 100%. Re-intervention ERCP was performed in 6 subjects (9.8%). No significant association was observed between all mortality outcomes and baseline characteristics of the patients. There were also no significant associations between re-intervention procedures, as well as post-procedural pain or acute pancreatitis, with mortality outcomes.

Conclusion: Difficult biliary cases require a good clinical approach algorithm to decide which procedure comes first based on comprehensive evaluation consists of patient's factor, expertise, cost, and the risk of complications.

1. Introduction

Biliary disorders have been considered as the most common challenging problem and costly of all gastrointestinal diseases. Among them, gallbladder stone is the most common etiology, estimated to affect 20.5 million people (6.3 million males and 14.2 million females) in the United States ([1]). The prevalence of gallbladder stone in Europe has also been roughly estimated to 5.9% until 21.9% of the population ([2]). Additionally, since many biliary diseases are still considered as scarce cases, significant geographical variation in the rates of prevalence and incidence can still be found among many regions worldwide. Variable distribution of risk factors also contributes to varied healthcare burdens ([3]).

Another clinical challenge is the case related to biliary malignancies. As the most common malignancy of biliary tree, gallbladder cancer has been discovered in 80%-95% cases of autopsy findings; accounting for less than 1% of all cancer-related deaths ([4,5]). Approximately 1%-2% gallbladder cancer is discovered from incidental findings during cholecystectomy procedure ([5,6]). Cholangiocarcinoma is also known as a common biliary malignancy, with most tumors are located at hilar region (60%-70%). It has been acknowledged as the second most common primary liver cancers after hepatocellular carcinoma ([7]). Biliary malignancies are also known to have non-specific clinical manifestation; therefore, it is mostly found in the late stage of the disease ([5,8]).

Management of most biliary disorders have been extremely changed in the last three decades by non-surgical innovation minimally invasive procedures, such as endoscopic retrograde cholangiopancreatography (ERCP), and interventional endoscopic ultrasound (EUS) ([9]). Recently, there are two main considerations of attitudes on facing complicated biliary problems. The first approach is the “laparoscopy-first” attitude, which primarily consists of intraoperative cholangiography and laparoscopic exploration of common bile duct (CBD). This approach, however, is still facing challenges due to its invasiveness and high cost. For high-risk choledocholithiasis, the success rates of laparoscopic approach are higher than 90% with morbidity rates ranging from 8%-15%, and mortality rate of 1%. The most common complications associated with laparoscopic approach are bile leakage, residual stones, infections on surgical sites, and sub-hepatic abscesses. Meanwhile, the second approach with “endoscopy-first” attitude yields success rates in stone extraction, ranging from 74.4–100%. The most common complications of this approach are acute pancreatitis (1.6%-15.7%), bleeding (1%-3%), perforation (0.1%-0.6%), and infection (< 1%) ([10,11]). Failure of attempted biliary cannulation also becomes one of the concerns in difficult biliary cases ([12,13]).

Nevertheless, no consensus has clearly stated the most preferable approach in management of complicated or difficult biliary cases since it also highly relies on the availability of instrumentations and skillful personnel. This study is aimed to see the impact of endoscopic approach management in difficult biliary cases performed in a single referral tertiary healthcare center.

2. Materials And Methods

2.1 *Study Design and Subjects*

A cohort-retrospective endoscopy database study was conducted at a tertiary-referral private hospital in Jakarta, Indonesia, between January and December 2020. Subjects were adult patients, who were indicated for therapeutic ERCP/EUS procedures due to biliary disorders. Inclusion criteria for difficult biliary cases which required at least one of the following conditions: multi-management approach, biliary obstruction with cholangitis or biliary sepsis, difficult CBD stone, recurrent CBD stone, or advanced progressive malignant biliary obstruction. Diagnostic confirmation of malignant etiologies was

established based on EUS biopsy with fine-needle aspiration biopsy (FNAB) or cytology or combination of imaging studies, tumor markers, and other clinical findings.

All procedures were performed by a senior consultant gastroenterohepatologist who has experiences for more than 10 years in advanced therapeutic endoscopy procedures. The ERCP equipment used was Olympus TJF Q 180 V scope. The EUS equipment used was an Olympus GF UCT 180 EUS scope connected to a high-end US equipment (Aloka IPF-1701C, Tokyo, Japan). EUS-guided approach was performed with 19-G FNA needle (Echo Tip, Wilson-Cook) for puncturing the bile duct followed by making the fistula tract using 6-Fr cystotome. A 210-cm-long, 0.35-inch guidewire (Boston Scientific, USA) was used for guidance inside the bile duct. Clinical observation and laboratory assessment after the procedures were done within 7 days.

2.2 *Data Analysis*

Characteristics of the study subjects, including demography and clinical data, were presented descriptively. Technical success rate was defined as completion of the procedure performed on the patients. A bivariate analysis was also performed to evaluate the outcome of the subjects after procedure. A statistically significant result was considered if P-value was < 0.05. Statistical analysis was conducted using SPSS version 21.0 (SPSS Inc., Chicago, IL, USA).

3. Results

Sixty-one subjects in this database review study were suitable as difficult biliary cases included in this study. The proportions of malignant and non-malignant etiologies were similar (44.3% *versus* 55.7%, respectively). Among these subjects, the most common etiology were choledocholithiasis (44.3%) and pancreatic cancer (18.0%) (Table 1). Of sixty-one recruited subjects, 59 subjects underwent therapeutic ERCP and/or interventional EUS as the initial procedure, whereas two subjects underwent cholecystectomy as the initial procedure from another hospital. Peritonitis due to biliary leak complication occurred on the latter subjects (Fig. 1).

Table 1
Baseline characteristics of the study subjects

Difficult Biliary Cases (n = 61)	
Demographic characteristic	
Gender, n (%)	
Male	35 (57.4)
Female	26 (42.6)
Age, mean ± SD	62 ± 15.74
Body Mass Index (kg/m^2), mean ± SD	24.43 ± 4.35
Aetiology, n (%)	
Malignant	27 (44.3)
Non-malignant	34 (55.7)
Primary Disease, n (%)	
Choledocholithiasis	27 (44.3)
Cholelithiasis	2 (3.3)
Cholecystitis	1 (1.6)
Pancreatic cancer	11 (18.0)
Cholangiocarcinoma	8 (13.1)
Bile leakage (post-laparoscopic cholecystectomy)	2 (3.3)
Hepatocellular carcinoma	1 (1.6)
Duodenal tumour	2 (3.3)
Biliary stricture	4 (6.6)
Papilla of Vater tumour	1 (1.6)
Ampullary mass	1 (1.6)
Colorectal tumour	1 (1.6)
Laboratory findings	
Haemoglobin (g/dL), mean ± SD	11.96 ± 2.44
White Blood Cells (10^3/mcL), median (min – max)	8.85 (3.4–33)
Platelets (10^3/mcL), mean ± SD	319.616 ± 186.25

Difficult Biliary Cases (n = 61)	
Total Bilirubin (mg/dL), median (min – max)	5.39 (0.25–40.92)
Direct Bilirubin (mg/dL), median (min – max)	4.57 (0.12–37.22)
Albumin (g/dL), median (min – max)	3.4 (2.1–4.9)
Amylase (mg/dL), median (min – max)	27.5 (5–722)
AST (U/L), median (min – max)	60.5 (15–773)
ALT (U/L), median (min – max)	71.5 (13–794)
GGT (U/L), median (min – max)	200.5 (34–4357)
ALP (U/L), median (min – max)	195 (58–1041)

In this study, 68.8% of all subjects underwent standard therapeutic ERCP procedure, while 16.4% of the subjects underwent combination of therapeutic ERCP and EUS in one session based on the complexity of the case; and 8.2% of the subjects underwent therapeutic ERCP with additional single operator cholangioscopy procedure. One subject underwent rendezvous ERCP procedure through percutaneous approach. Around 4.9% of the subjects underwent EUS-biliary drainage procedure. The technical success rate of all procedures was 100%. In addition, post-procedural observation within 7–14 days was also performed in all subjects. Re-intervention with ERCP was performed in 6 subjects (9.8%), with clinical indications varied from recurrent biliary obstruction caused by infiltrative malignant process or recurrent CBD stones. The most common adverse event observed in this study was post-procedural pain (50.8%) (measured by Visual Analog Scale: ≥ 4). Approximately, 14.8% of the subjects also experienced post-procedural acute pancreatitis without any further complications requiring intensive care and/or life-threatening complications. Four subjects (6.6%) died within one month after procedure. One patient died due to procedure-related events, while the other cases of death were due to the malignant process of the diseases (Table 2, Table 3). Comparison of the mortality outcome was also analyzed in this study. It was demonstrated that no significant association was observed between all mortality outcomes and baseline characteristics of the patients. There were also no significant associations between re-intervention procedures, as well as post-procedural pain or acute pancreatitis, with mortality outcomes (Table 3).

Table 2
Summary of result endoscopic approach in patients with difficult biliary cases

Endoscopic Approach in Patients With Difficult Biliary Cases (n = 61)	
Primary Procedures, n (%)	
ERCP	42 (68.8)
Rendezvous	1 (1.6)
ERCP + EUS	10 (16.4)
ERCP + Single Operator Cholangioscopy	5 (8.2)
EUS-BD	3 (4.9)
Technical success rate, n (%)	61 (100)
Post procedure intervention, n (%)	
Re-intervention ERCP	6 (9.8)
Adverse event, n (%)	
Pain (Scale ≥ 4)	31 (50.8)
Acute Pancreatitis	9 (14.8)
Outcome of patient, n %)	
Death	4 (6.6)
Alive	57 (93.4)

Table 3
Comparison of mortality outcome

Variable	Outcome of Patient		
	Death	Alive	P value
Gender, n (%)			
Male	3 (8.8)	31 (91.2)	0.414
Female	1 (3.8)	25 (96.2)	
Age, mean ± SD	63.75 ± 12.99	61.16 ± 15.99	0.444
Body Mass Index (kg/m^2), mean ± SD	24.95 ± 5.63	24.46 ± 4.32	0.551
Etiology, n (%)			
Malignant	3 (11.5)	23 (88.5)	0.212
Non-malignant	1 (3)	33 (97)	
Haemoglobin (g/dL), median (min – max)	11.05 (7.8–12.2)	12.1 (9.5–16.1)	0.123
White Blood Cells (10^3/mcL), median (min – max)	11.4 (6.8–33)	8.75 (3.4–21.1)	0.349
Platelets (10^3/mcL), median (min – max)	230.5 (58–455)	284 (59–118.8)	0.483
Total Bilirubin (mg/dL), median (min – max)	6.42 (1.26–14.75)	5.39 (0.25–40.92)	0.966
Direct Bilirubin (mg/dL), median (min – max)	4.08 (0.96–12.93)	3.91 (0.12–37.22)	0.742
Albumin (g/dL), median (min – max)	3.3 (2.4–3.9)	3.45 (2.10–4.9)	0.742
Amylase (mg/dL), median (min – max)	28 (22–71)	26.5 (5–722)	0.577
AST (U/L), median (min – max)	102 (26–262)	60.5 (15–773)	0.635
ALT (U/L), median (min – max)	75 (56–98)	71.5 (13–794)	0.898
GGT (U/L), median (min – max)	243 (91–523)	200.5 (34–4357)	0.989
ALP (U/L), median (min – max)	287 (89–641)	184 (58–1041)	0.413
Re-intervention ERCP, n (%)			
Yes	1 (16.7)	5 (83.3)	0.351
No	3 (5.5)	52 (94.5)	
Pain (Scale ≥ 4), n (%)			

Variable	Outcome of Patient		
	Death	Alive	P value
Yes	3 (9.7)	28 (90.3)	0.332
No	1 (3.4)	28 (96.6)	
Acute Pancreatitis, n (%)			
Yes	2 (22.2)	7 (77.78)	0.103
No	3 (5.8)	49 (94.2)	

Some interesting difficult cases which required complex procedures are described in this study (Fig. 1). One subject, who experienced bile peritonitis and bile leakage after laparoscopic cholecystectomy procedure at another hospital (two weeks prior to hospital admission) underwent ERCP procedure in our hospital due to migrated plastic CBD stent which has been placed during pre-operative ERCP procedure. The patient also underwent percutaneous drainage-trans abdominal ultrasound guided for bile fluid drainage in the abdominal cavity. Another subject was referred to our hospital for ERCP procedure due to hyperbilirubinemia caused by bile duct obstruction after laparoscopy and conversion to open cholecystectomy with biliodigestive procedures. In this patient, very tight biliary stricture was found around the biliodigestive anastomotic area and need to be managed with tapered dilator and Soehendra screw before stent placement. One subject underwent salvage ERCP procedure at our hospital for biliary stenting due to bile leakage and bile peritonitis after laparoscopic cholecystectomy procedure, where surgical abdominal drains have been placed during the operative procedure. During the salvage ERCP procedure (CBD stent placement), the presence of a large distal CBD stone was noted. It was decided to place two stents (10-fr straight plastic stent across the leakage area and single 7-fr double pigtail stent. One month after the first ERCP procedure, the second ERCP procedure was performed for stone crushing by single operator cholangioscopy procedure due to narrowing of distal CBD. One subject with advanced pancreatic cancer underwent repeated ERCP procedure due to metal stent blockage caused by biliary stone and sludge. Another subject with malignant biliary obstruction underwent ERCP procedure for nasobiliary tube placement insertion due to progressive hilar cholangiocarcinoma at the proximal area through the previous biliary self-expanded metallic stent (SEMS). Salvage ERCP procedure was also conducted in one severely ill patient in the ICU with ventilator who experienced biliary sepsis due to large stone at distal CBD area and distal bile duct compression by large pancreatic pseudocyst. The patient also suffered from cardiovascular problems, hypothyroidism, and type 2 diabetes mellitus. Prior to the ERCP procedure, a bedside biliary drainage procedure with percutaneous transhepatic biliary drainage (PTBD) under transabdominal ultrasound guidance (without fluoroscopy) had been performed along with percutaneous cyst aspiration to improve the breathing system. The patient also received wide-spectrum antibiotics and other supportive treatment for her sepsis condition. During the ERCP procedure, salvage biliary drainage was performed by placing a 7-Fr double-pigtail stent inside the CBD. After ERCP, EUS was also conducted to evaluate the large cyst. After a fistula tract had been established sufficiently, a 7-Fr

double-pigtail stent was inserted into the cyst cavity. A clinically significant improvement was observed, afterwards. The patient could be transferred from the ICU without any ventilator to the common ward and even discharged from the hospital.

4. Discussion

This study showed the complexity of management approach in difficult biliary cases with two sides of the story (innovation in surgical and endoscopic approach). Both malignant and non-malignant complicated biliary cases are remaining a major challenge for diagnostic approach as well as management, which requires a multidisciplinary approach. The decision regarding which modalities should be chosen usually depends on the complexity of the case, patient's condition, and the approach invasiveness. Although endoscopic procedures are considered as less invasive compared to intraoperative procedures, several controversies can still arise due to their non-negligible morbidity (4%-15.9%) and mortality (0–1%) rates based on technical difficulties or anatomically challenging situations during the procedures. For instance, difficulty in identifying major papilla or failure in performing cannulation of biliary tract or even obtaining a cholangiogram in challenging anatomy ([9,13]). Another common cause of ERCP failure is history of previous surgical procedures on the stomach, such as Roux-en-Y gastrojejunostomy ([13]) or gastrectomy with closure of duodenal stump or reconstruction of Billroth II. Other factors, which may influence the failure rate of ERCP are infiltration of the tumor into the ampulla, obstruction of gastrointestinal passage, or peptic ulcer ([14]).

The most common non-malignant etiology found in this study was choledocholithiasis. According to the guideline from the American Society for Gastrointestinal Endoscopy (ASGE), even though the strategies of removing bile duct stones have shifted from major surgery into minimally invasive procedures, the risk of major adverse events associated with ERCP-guided treatment is still ranging from 6–15%. However, the guideline still recommends ERCP with placement of plastic and covered metal stents in patients with difficult choledocholithiasis and signs of infection with planned exchange or removal. For minimizing the risk of diagnostic ERCP, ASGE has also established risk stratification criteria to determine whether ERCP should be performed immediately or to choose other modalities for suspected choledocholithiasis (Table 4) ([15]). In this study, these criteria were also used to stratify the risk of the subjects with choledocholithiasis to determine the next procedure to be performed.

Table 4
Proposed recommendations by ASGE (2019) for management strategies in choledocholithiasis according to risk stratification[15].

Probability of Risk	Predictors	Recommended Strategy
High Risk	CBD stone on ultrasound/cross-sectional imaging OR Clinical ascending cholangitis OR Total bilirubin > 4 mg/dL and dilated CBD on ultrasound/cross-sectional imaging.	ERCP
Intermediate Risk	Abnormality in liver function tests OR Age > 55 years-old OR Dilated CBD on ultrasound/cross-sectional imaging.	EUS, MRCP, laparoscopic intraoperative cholangiography, or intraoperative ultrasound.
Low Risk	N/A	Cholecystectomy with or without intraoperative cholangiography or intraoperative ultrasound.

In management of CBD stones, nowadays, ERCP with ES still the most common treatment approach with reported success rate over 90% ([15]). However, as a post-operative procedure, failure of ERCP which may lead to another surgical procedure, raising the issues of cost and complications. ([16]). Meanwhile, since almost three decades ago, laparoscopic CBD exploration has been considered as one of the surgical managements of biliary cases. Depending on the experiences of the operators, the effectiveness of laparoscopy cholecystectomy is comparable with ERCP for CBD clearance. Nevertheless, longer operating time (300–358 minutes), expensive instruments, and adequacy of surgical skills remain a hindrance to apply this technique widely ([9,17]). A retrospective study in 141 post-cholecystectomy subjects with choledocholithiasis showed higher success rates for CBD clearance in ERCP group (97.7% *versus* 87%), shorter mean duration of the procedure, and shorter post-operative hospital stay compared to groups who underwent laparoscopic CBD exploration ([18]). Based on our case series, there were three patients who underwent ERCP procedure due to complications after laparoscopic cholecystectomy procedure. Bile leakage is still considered as the most common post-procedural complication after laparoscopic cholecystectomy. In our study, two subjects with bile leakage and one subject with stricture at the site of

biliodigestive bypass were referred from another healthcare center, in which, they underwent second operation before ERCP.

Another focus of our results is the malignant biliary cases. Malignant distal biliary obstruction itself is still considered as a challenging condition since the diagnosis often found at advanced stage due to unspecific early clinical manifestation. In line with the epidemiological data, the most common malignant distal biliary obstruction cases in our study were pancreatic adenocarcinoma and cholangiocarcinoma. ([19,20]).

As demonstrated by our descriptive findings, advances in endoscopic approaches have also been applied in endoscopic biliary malignancies. Approximately 70% of malignant distal biliary obstruction is considered unresectable at the time of diagnosis. Nevertheless, various clinical manifestation, such as nausea, recurrent cholangitis, pruritus, loss of appetite, renal dysfunction, and delayed wound healing may still cause discomfort for the patients ([21]). Therefore, palliative biliary stenting is expected to reduce these symptoms. According to ESGE guidelines, ERCP remains the modality of choice for biliary drainage compared to surgical by-pass due to significantly higher post-operative morbidity and mortality rates with the latter ([22]). One meta-analysis also showed significantly lower 30-day mortality after primary biliary stenting compared to surgical bilio-digestive anastomosis ([23]). In case of failed ERCP procedure, rendezvous maneuver can be solicited if access to papilla is available. If papilla is inaccessible (*i.e.*, anomaly in anatomical structure, gastric outlet syndrome, duodenal obstruction, or history of enteral stents) or if the wire cannot be advanced due to the presence of strictures, EUS-guided biliary drainage (EUS-BD) can be performed by creating non-anatomic direct access with hepaticogastrostomy or choledochoduodenostomy ([16]). A recent retrospective study also demonstrated similar technical success rate between EUS-BD and PTBD (87.5% *versus* 86.7%) ([24]). One meta-analysis demonstrated higher rates of clinical success and lower rates of post-procedural adverse events, as well as lower rates of repeated procedures in EUS-BD compared to PTBD ([25]). However, previous evidence indicated higher risk of hemorrhage, cutaneous infection or tumor seeding, and catheter tract recurrence related to PTBD ([21,22]). Another common issue with endoscopic biliary palliation is re-occlusion of stents. In our study, 3 out of 8 subjects who underwent repeated ERCP procedures had clogged stents, in which all of them had advanced malignant biliary obstruction. Several approaches have been developed to overcome the patency issue; for instance, by assimilating chemotherapeutic agent, applying anti-reflux covered SEMS design, or anti-migration system ([21]). Further studies are still necessary to confirm the efficacy of these approaches.

In our special case, an ERCP procedure was also performed without any technical problem and post-procedural complications in one pregnant subject with biliary obstruction due to gallstone. Although no guideline has clearly evaluated the effectiveness of treating gallstones in pregnancy, surgery is usually only indicated when the patient suffers from recurrent or refractory biliary pain ([27]).

In addition, four subjects passed away within 30 days due to their advanced malignancy-related cause. None of the repeated procedures conducted due to technical failure. None of the subjects suffered from bile leakage, cholangitis, or stent migration complications, as well.

There are limitations in this study. This was a cohort retrospective study and was conducted in a single tertiary referral endoscopic center; therefore, larger sample size in multi-center study with longer follow-up is necessary to further validate our findings. However, this study demonstrated the real workflow in daily clinical practice situation, in which, the attitude of “endoscopy-first” does appear to have a significant effect in the clinical outcomes in patients with complicated biliary problems if the procedure is performed by skillful operators in specialized endoscopic centers. Low number of surgical procedures performed after endoscopic management from our data also showed that endoscopic management can still be a single-stage therapeutic option for complicated biliary cases; thus, also decreasing the concern of surgical complications and cost (Fig. 2). Second, this was not a head-to-head comparison study between endoscopic vs surgery approach, however this study was not meant to show which one is better as this was based on consecutive real life clinical problems, where sometimes it could not show the outcome prediction before the procedure.

Conclusions

Difficult and complicated biliary cases require a good clinical approach algorithm to decide which procedure comes first based on comprehensive evaluation consists of patient’s factor, expertise, cost, and the risk of complications. It would need further and larger study to have a good recommendation for clinical-based approach.

Abbreviations

CBD
Common bile duct
ERCP
Endoscopic Retrograde Cholangio-Pancreatography
EUS
Endoscopic Ultrasound
FNAB
Fine Needle Aspiration Biopsy
PTBD
Percutaneous Transhepatic Biliary Drainage
SEMS
Self-Expanding Metallic Stent

Declarations

Ethics approval and consent to participate

The study was in accordance with the ethical standards of the responsible committee on human experimentation and with the Helsinki Declaration of 1975 (revised in 2008). The patient's informed consent was waived due to retrospective database study. This study has been approved by the Medistra Hospital Institutional Review Board / Ethical Committee (Ethical Approval No:003/EA/KEPKM/2021).

Consent for publication

The consent has been replaced by the approval from the ethic's committee due to retrospective database analysis. This study does not contain any individual images or videos.

Availability of data and materials

All data generated or analyzed during this study are included in this article. Further enquiries can be directed to the corresponding author.

Competing interests

None.

Funding

No funding received in this study.

Author's contributions

C.R.A. Lesmana provided the idea and design of the study, as well as wrote the manuscript. L.A. Lesmana, M.S. Paramitha, and Y.E. Pratiwi were involved in the manuscript patient's data preparation.

Acknowledgement

The authors would like to thank to Ms. Gita Aprilicia who helped to do study analysis.

References

1. Everhart JE, Khare M, Hill M, et al. Prevalence and ethnic differences in gallbladder disease in the United States. *Gastroenterology*. 1999; 117: 632–639. DOI: 10.1016/s0016-5085(99)70456-7. PMID: 10464139.
2. Aerts R, Penninckx F. The burden of gallstone disease in Europe. *Alimentary Pharmacology and Therapeutics*. 2003; 18 Suppl 3: 49–53. DOI: 10.1046/j.0953-0673.2003.01721.x. PMID: 14531741.
3. Boberg KM. The clinical burden of biliary disease: A global perspective. In: Hirschfield G, Adams D, Liaskou E, editors. Biliary disease: From science to clinic. Switzerland: Springer International Publishing; 2017.

4. Gourgiotis S, Kocher HM, Solaini L, et al. Gallbladder cancer. *Am J Surg*. 2008; 196(2): 252–264. DOI: 10.1016/j.amjsurg.2007.11.011. PMID: 18466866.
5. Kiran RP, Pokala N, Dudrick SJ. Incidence pattern and survival for gallbladder cancer over three decades – An analysis of 10301 patients. *Ann Surg Oncol*. 2007; 1492): 827–832. DOI: 10.1245/s10434-006-9224-4. PMID: 17109082.
6. Randi G, Franceschi S, La Vecchia C. Gallbladder cancer worldwide: Geographical distribution and risk factors. *Int J Cancer*. 2006; 118(7): 1591–1602. DOI: 10.1002/ijc.21683. PMID: 16397865.
7. Shaib Y, El-Serag HB. The epidemiology of cholangiocarcinoma. *Semin Liver Dis*. 2004; 24(2): 115–125. DOI: 10.1055/s-2004-828889. PMID: 15192785.
8. Everhart JE, Ruhl CE. Burden of digestive diseases in the United States part III: Liver, biliary tract, and pancreas. *Gastronterology*. 2009; 136(4): 1134–1144. DOI: 10.1053/j.gastro.2009.02.038. PMID: 19245868.
9. Costi R, Gnocchi A, Mario FD, et al. Diagnosis and management of choledocholithiasis in the golden age of imaging, endoscopy, and laparoscopy. *World J Gastroenterol*. 2014; 20(37): 13382–13401. DOI: 10.3748/wjg.v20.i37.13382. PMID: 25309071.
10. Herrera-Ramirez MA, Acevedo HL, Pena GAG, et al. Efficiency of laparoscopic vs endoscopic management in cholelithiasis and choledocholithiasis. Is there any difference? *Cir Cir*. 2017; 85(4): 306–311. DOI: 10.1016/j.circir.2016.10.008. PMID: 28024730.
11. Ainsworth AP, Adamsen S, Rosenberg J. Surgical versus endoscopic treatment of bile duct stones. Ugeskr Laeg. 2007;169:1671–4.
12. Manes G, Paspatis G, Aabakken L, et al. Endoscopic management of common bile duct stones: European Society of Gastrointestinal Endoscopy (ESGE) Guideline. *Endoscopy*. 2019; 51. DOI: 10.1055/a-0862-0346. PMID: 30943551.
13. Balik E, Eren T, Keskin M, et al. Parameters that may be used for predicting failure during Endoscopic Retrograde Cholangiopancreatography. *J Oncol*. 2013. DOI: 10.1155/201681. PMID: 23861683.
14. Patel JA, Patel NA, Shinde T, et al. Endoscopic retrograde cholangiopancreatography after laparoscopic Roux-en-Y gastric bypass: A case series and review of the literature. Am Surg. 2008; 74: 689;693. PMID: 18705568.
15. Buxbaum JL, Fehmi SMA, Sultan S, et al. ASGE guideline on the role of endoscopy in the evaluation and management of choledocholithiasis. *Gastrointest Endosc*. 2019; 1:31. DOI: 10.1016/j.gie.2018.10.001. PMID: 30979521.
16. Hindryckx P, Degroote H, Tate DJ, et al. Endoscopic ultrasound-guided drainage of the biliary system: Techniques, indications, and future perspectives. *World J Gastrointest Endosc*. 2019; 11(2): 103–114. DOI: 10.4253/wjge.v11.i2.103. PMID: 30788029.
17. O'Rourke RW, Lee NN, Cheng J, et al. Laparoscopic biliary reconstruction. *Am J Surg*. 2004; 187: 621–624. DOI: 10.1016/j.amjsurg.2004.01.006. PMID: 15135678.
18. Wang X, Dai C, Jiang Z, et al. Endoscopic retrograde cholangiopancreatography versus laparoscopic exploration for common bile duct stones in post-cholecystectomy patients: A retrospective study.

*Oncotarg*et. 2017; 8(47): 82114–82122. DOI: 10.18632/oncotarget.18839. PMID: 29137249.

19. Khan SA, Tavolari S, Brandi G. Cholangiocarcinoma: Epidemiology and risk factors. *Liver Int*. 2019; 39(Suppl.1): 19–31. DOI: 10.1111/liv.14095. PMID: 30851228.
20. Rahib L, Smith BD, Aizenberg R, et al. Projecting cancer incidence and deaths to 2030: The unexpected burden of thyroid, liver, and pancreas cancers in the United States. *Cancer Res*. 2014; 74(11): 2913–2921. DOI: 10.1158/0008-5472. PMID: 24840647.
21. Viesca MFY, Arvanitakis M. Early diagnosis and management of malignant distal biliary obstruction: A review on current recommendations and guidelines. *Clin Exp Gastroenterol Hepatol*. 2019; 12: 415–432. DOI: 10.2147/CEG.S195714. PMID: 31807048.
22. Dumonceau JM, Tringali A, Papanikolaou I, et al. Endoscopic biliary stenting: Indications, choice of stents, and results. European Society of Gastrointestinal Endoscopy (ESGE) Clinical Guideline. *Endoscopy*. 2018; 50(09): 910–930. DOI: 10.1055/a-0659-9864. PMID: 30086596.
23. Lima LA, Bustamante AC, Moura GH, et al. Endoscopic palliative treatment versus surgical bypass in malignant low bile duct obstruction: A systematic review and meta-analysis. Int J Hepatobiliary Pancreat Dis. 2015;5:35–46. DOI:10.5348/ijhpd-2015-32-CR-7.
24. Lesmana CRA, Gani RA, Hasan I, et al. Palliative endoscopic ultrasound biliary drainage for advanced malignant biliary obstruction: Should it replace the percutaneous approach? *Case Rep Gastroenterol*. 2019; 13: 385–397. DOI: 10.1159/000502835. PMID: 31616233.
25. Sharaiha RZ, Khan MA, Kamal F, et al. Efficacy and safety of EUS-guided biliary drainage in comparison with percutaneous biliary drainage when ERCP fails: A systematic review and meta-analysis. *Gastrointest Endosc*. 2017; 85(5): 904–914. DOI: 10.1016/j.gie.2016.12.023. PMID: 28063840.
26. Rustagi T, Aslanian HR. Endoscopic management of biliary leaks after laparoscopic cholecystectomy. *J Clin Gastroenterol*. 2014; 48: 674–678. DOI: 10.1097/MCG.0000000000000044. PMID: 24296422.
27. Abraham S, Rivero HG, Erlikh IV, et al. Surgical and non-surgical management of gallstones. Am Acad Family Physicians. 2014;89(10):795–802. PMID: 24866215.

Figures

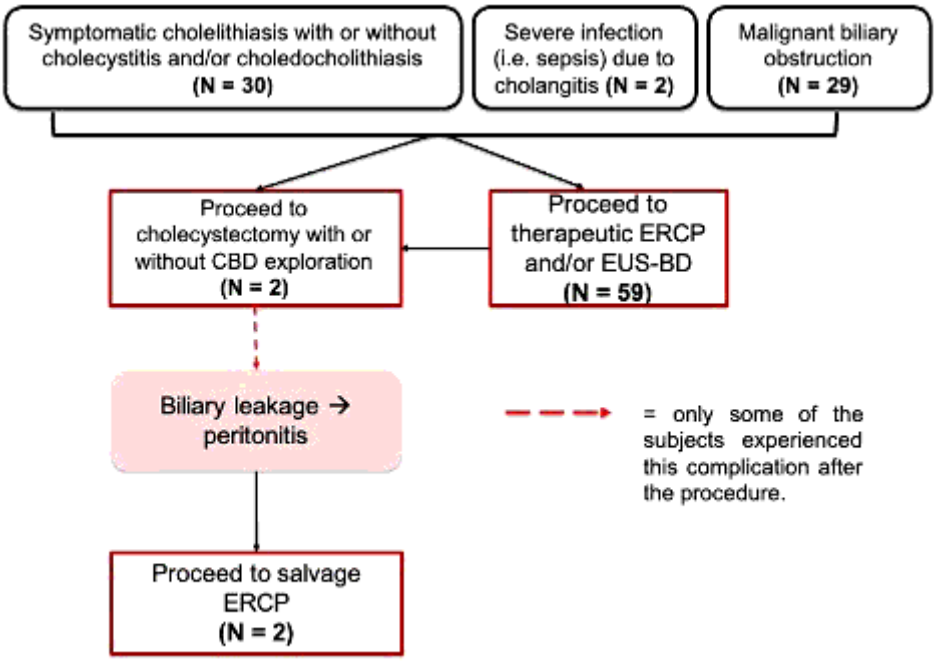

Figure 1. Flow chart of the study subjects' management.

Figure 1

Flow chart of the study subjects' management. This flow chart summarizes the sequential events of the subjects in this study since the admission until the therapeutic procedures.

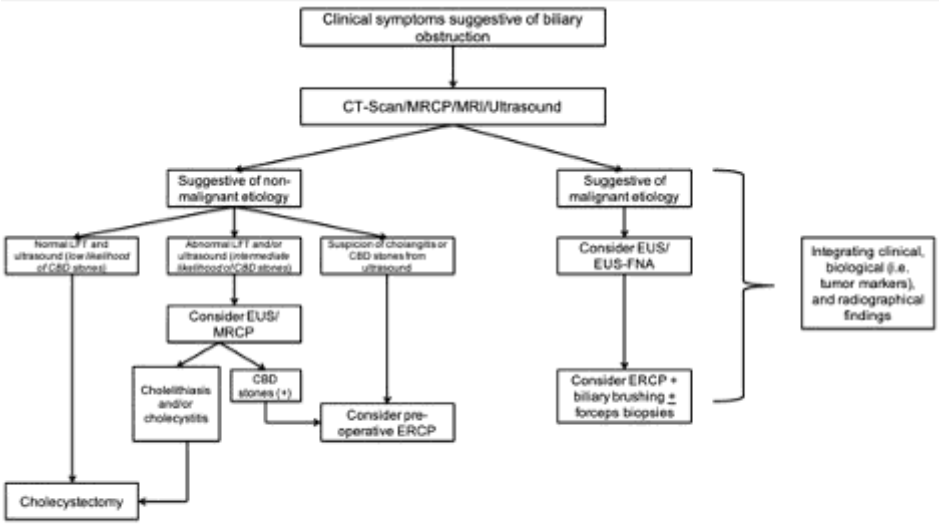

Figure 2. Proposed algorithm for management of complicated biliary cases.

Figure 2

Proposed algorithm for management of complicated biliary cases.