Bi-columnar locking plate fixation through a combined medial and lateral approach for the treatment of low transcondylar fractures of the distal humerus in the elderly

Sam-Guk Park (radiorth@ynu.ac.kr)
Yeungnam University Medical Center

Hyun-Gyu Seok
Yeungnam University Medical Center

Research Article

Keywords: Humerus, distal, low transcondylar, fracture, medial and lateral approach

Posted Date: February 22nd, 2022

DOI: https://doi.org/10.21203/rs.3.rs-1349380/v1

Abstract

Background

Low transcondylar fractures of the distal humerus are relatively uncommon elbow injuries. These fractures tend to occur in elderly patients after low-energy injuries. Due to the complexity of distal humeral geometry and the often small and osteoporotic distal fragments, stable internal fixation may be extremely difficult to achieve. The purpose of this study was to present the outcomes of bi-columnar internal fixation through a combined medial and lateral approach, for the treatment of LTF of the distal humerus in the elderly.

Methods

A total of 46 patients diagnosed with distal humeral fractures between 2017 May and 2020 April were prospectively enrolled in this study. Thirty patients were excluded and 16 patients who underwent medial and lateral approach for open reduction and internal fixation were selected. Clinical outcome was assessed based on the VAS, MEPS, DASH, and ROM of the elbow joint. Standardized radiographs were obtained at 3, 6, and 12 months after surgery, and at the last follow-up visit to evaluate for bony union and to check complications.

Results

The average follow-up period was 23.6 months (range, 12–42 months). The mean age was 81 years (range, 65–91 years). Bony union was achieved in 15 out of 16 patients. The mean VAS score was 2.1 (range, 0–6), the mean MEPS was 84.4 (range, 70–100), and the mean DASH score was 20.6 (range, 9.5–33.6). There were three complications including reduction loss, skin necrosis, and stiffness of the elbow.

Conclusion

LTFs of the distal humerus in the elderly can yield satisfactory results with bi-columnar internal fixation through a combined medial and lateral approach.

Level of evidence

Level IV, case series.

Introduction

Low transcondylar fractures of the distal humerus are relatively uncommon elbow injuries. Most surgeons believe that operative treatment of LTFs in the elderly is particularly challenging. These fractures are characterized by low transverse, intra-capsular and extra-articular fracture lines running across the olecranon and coronoid fossae. These fractures tend to occur in elderly patients after low-energy injuries, not acute trauma on young age patients.[1–3] Due to the complexity of distal humeral geometry and the often small and osteoporotic distal fragments, stable internal fixation may be extremely difficult to achieve.[4]

The principle of non-surgical treatment is limited to patients who cannot tolerate anesthesia. With the emergence and rapid development of the elbow joint in semi-constrained prostheses, total elbow joint replacement has gradually become an important treatment option, particularly in individuals with low physical demand and fractures not amenable do plate fixation.[5] However, there are several limitations in total elbow arthroplasty. The patients who underwent total elbow arthroplasty must do lifelong stringent weight restrictions. Also, relatively critical complications such as aseptic loosening and periprosthetic fractures may occur.

Recently, bi-columnar anatomic locking plate fixation remains the standard of care for most LTF individuals, and has been shown, to provide more predictable outcomes and earlier joint mobilization.[6–8]

Despite these advances in treatment, ORIF yields a fair number of complications. In particular, postoperative ulnar nerve changes, nonunion of the olecranon, removal of the olecranon hardware, and breakdown in the thin posterior elbow skin are inherent complications with the posterior approach. A recent systematic review has shown that ORIF for distal humerus fractures in the elderly population has an over-all associated complication rate of thirty percent, including postoperative ulnar nerve change (7.2%), olecranon osteotomy nonunion (2.7%), and superficial wound problems (6.9%).[9] Pre-existing chronic diseases in elderly patients, can further complicate general anesthesia for the conventional elbow posterior approach in prone or lateral position.

Xie et al.[10] presented a combined medial and lateral approach to treat intra-articular distal humerus fractures. We have treated LTF patients with bi-columnar locking plate fixation through this approach. We could carry out all the surgeries under brachial plexus

anesthesia without violating the elbow extension mechanism and without ulnar nerve dissection. In the present study, we report the results of 16 elderly LTF patients, who underwent open reduction and bi-columnar anatomic LCP fixation through a combined medial and lateral approach.

Methods

After approval of the study protocol by the institutional review board, the patients diagnosed with distal humeral fractures between 2017 May and 2020 April were retrospectively enrolled in this study. The patient records and the serial radiographs were assessed. The medical charts of all patients were reviewed and the following items were retrieved: age, gender, trauma mechanism, other injuries besides the humeral shaft fracture, type of fracture, and union time.

The following inclusion criteria were applied: (1) low transverse type of distal humeral fractures; (2) patients 65 years of age or older; (3) followed-up for at least 12 months after surgery. The exclusion criteria were as follows: (1) polytrauma; (2) pathologic fractures; (3) periprosthetic fractures; (4) severe arthritis or inflammatory arthropathy of the elbow joint; (5) fractures involving the articular surface of the distal humerus; and (6) incomplete follow-up data.

LTF was defined as an extra-articular fracture with a single transverse fracture line that consistently exited at the level of or distal to the lateral epicondyle laterally, and at the level of or just proximal to the medial epicondyle (Fig. 1). None of the fractures included in the study extended proximal to the roof of the olecranon fossa affecting the columns. All patients underwent a CT scan prior to surgery. The radiologic classification was carried out using the Arbeitsgemeinshaft Osteosynthesfragen system, which is identical to the Orthopaedic Trauma Association classification for distal humeral fractures. We selected only patients with type A2 and type A3 according to the AO/OTA classification. Radiological consolidation was defined as cortical bridging of at least three out of four cortices, and was expressed in weeks from the day of the fracture. Delayed union was defined as a failure to heal at 24 weeks post-fracture with no progress towards healing, seen on the most recent radiographs. Nonunion was defined as no evidence of bone union at 1 year after injury. Information about the affected side, the consolidation period and presence of a delayed union were collected from the radiographs and the patient's hospital records.

We identified 46 consecutive distal humeral fractures through our registry. Two individuals reviewed all radiographs to determine how many fractures fulfilled the previously mentioned criteria and excluded thirty patients from the study. Of the thirty, 13 patients had polytrauma and five patients had fractures involving intra-articular surfaces. Twelve others were excluded due to incomplete follow-up data. Ultimately, 16 patients were enrolled in this study.

Surgical technique

Patient positioning and anesthesia

All operations were performed by a single surgeon, with patients under brachial plexus anesthesia, occasionally accompanied by moderate sedation. The patient was placed in the supine position, and the arm to be operated on, was positioned at 90°of abduction on a radiolucent operating table. A sterile pneumatic tourniquet was applied as proximally as possible on the arm. A small, rolled towel was placed under the ipsilateral wrist to keep elbow flexed at about 30°.

Medial approach

First, the medial approach was performed through an incision measuring approximately 8 cm, starting at one finger breadth distally from the tip of the medial epicondyle and proceeding proximally along the medial supracondylar ridge of the humerus toward the axillary line. We dissected the interval between the brachial muscle and the medial intermuscular septum proximal to distally. The ulnar nerves were palpable posterior to the intermuscular septum, so we proceeded to the distal without ulnar nerve dissection or releasing from the ulnar nerve groove. The medial and anteromedial surfaces of the distal humerus were exposed by the dissection through the interval. After we approach the elbow joint, we detach the medial intermuscular septum sufficiently from the bone and partially release the muscular origin of the pronator teres muscle to make space for the plate. And then, the anterior joint capsule was incised to expose the articular surface of the trochlea. The elbow was then flexed about 80°, and the biceps and brachialis muscles were retracted anteriorly (Fig. 2a,b). Any hematoma or small fragments in the coronoid fossa could be debrided. The medial column was first reduced, following which one or two 1.6 mm K-wires were inserted for provisional fixation (Fig. 2a,b).

Lateral approach

A second incision for the lateral approach measured approximately 10 cm, beginning from the distal end of lateral epicondyle and continuing proximally toward the deltoid tuberosity. The interval between the triceps lateral head and brachialis muscle was developed from the distal to the proximal end. We carefully approached at around 10 cm proximal to the lateral epicondyle because the radial nerve pierced the lateral intermuscular septum.[11] Distally, dissection through the interval between the triceps muscle and the origins of the extensor carpi radialis longus and the brachioradialis muscle exposed the lateral border of the humerus. The origin of brachioradialis was partially released, and the anterior articular surface of the capitulum was exposed. The lateral column was also reduced and temporally fixed using 1.6 mm K-wires. In some cases, simultaneous adjustment of both columns was needed (Fig. 3a). The reduction and alignment were subsequently confirmed under direct vision and by using fluoroscopy. Definitive fixation was performed first in the area where more screws could be fixed to the distal bone fragment. In most cases, to create a difference in the length of the plates, a short locking compression plate (2.7 mm Variable Angle LCP Elbow System, Synthes, Oberdorf, Switzerland) was used on the medial column (Fig. 2c) and a long locking compression plate (3.5 mm Variable Angle LCP Elbow System, Synthes) was used on the lateral column (Fig. 3b). The plates were positioned so the distal screws could be fixed parallel to the anterior surface of the humeral condyles. Two or three screws were fixed to the distal bone fragment on each side, and efforts were made to implant one or more long screws on each side, for the opposite column to gain purchase (Fig. 4). The reduction and the length of the screws were checked by the C-arm. Partially released pronator teres and brachioradialis muscle were repaired.

Post-operative protocol

Postoperatively, the elbow was placed in a bulky non-compressive dressing with a posterior plaster slab to maintain the elbow flexed between 40° and 50°. Active-assisted and passive motion was encouraged 3 weeks after the surgical procedure. At 6 weeks, the patients were encouraged to regain range of motion, and gentle daily activities were permitted. At 3 months, usual activity was allowed.

Evaluation of radiologic and clinical outcomes

Standardized radiographs (anteroposterior, lateral, internal, and external oblique views) were obtained at 3, 6, and 12 months after surgery, and at the last follow-up visit to evaluate for bony union, delayed union, nonunion, heterotophic ossification, or hardware failures. The first author, the corresponding author, and a radiologist reviewed the radiographic results. We evaluated the inter-rater reliability with intraclass correlation coefficients; the obtained value of 0.96 indicated that the inter-rater reliability was excellent. Bone mineral densities were measured using dual energy X-ray absorptiometry (Hologic, Bedford, MA, USA). Osteoporosis was defined with a T-score of ≤ -2.5 according to the criteria of the World Health Organization. The complications such as nerve damages and wound problems were also checked.

Clinical outcome was assessed based on the VAS, MEPS, DASH, and ROM of the elbow joint, which were collected at the latest follow-up for all the patients. ROM was measured in degrees for flexion, extension, pronation, and supination. We used GraphPad Prism 5.0 for the statistical analysis of primary data.

Results

Patient characteristics

Solid union was achieved in all patients of which 3 were men and 13 were women. The average follow-up was 23.6 months (range, 12–42 months) and the mean age of the patients was 81 years (range, 65–91 years). Nine fractures involved the right humerus (9 dominant), and 7 involved the left humerus (1 dominant). The mechanism of injury was a slip down in 12 patients and falling down in 4 patients. According to the AO/OTA classification, 13 were classified as type A2.3, 2 patients were classified as A3.2 and 1 was classified as A3.1. We performed internal fixation using parallel plates in 12 cases and orthogonal plates in 4 cases (Table 1).

Radiologic and clinical outcomes

Successful fracture healing was achieved in 15 out of 16 cases with satisfactory bony alignment. Osteoporosis was observed in 13 out of 16 patients, and the average T score was −3.56 (range, −2.3 to −5.1).

At the last follow-up evaluation, the mean VAS score for pain was 2.1 (range, 0–6) and the mean MEPS was 84.4 points (range, 70–100 points). Based on the MEPS, 2 patients had an excellent score; 12, good; and 2, fair. The mean Q-DASH score was 20.6 (range, 9.5–33.6).

The mean ROM was 116º (range, 100º–130º). Mean flexion was 126.9º (range, 100º–130º); extension, 10.9º (range, 0º–20º); pronation, 83.4º (range, 60º–90º); and supination, 79.3º (range, 60º–90º) (Table 1).

Complications

There were three complications (18.8%) in the patients included in the study. Screw migration with loss of reduction in varus, was recognized in one instance during the early months after fixation. However, the fractures eventually healed without additional surgery. Skin necrosis over the ulnar plate was identified in 1 case, 6 months after surgery. Since the fracture was healed, the hardware was removed, and the skin was debrided and re-sutured. One patient suffered about 80º of motion restriction (105º of flexion, 35º of extension) at 6 months after surgery. She recovered a ROM of about 110º after removal of the instrument without release of contracture. No complications such as nerve injuries and heterotopic ossifications were reported in any of the cases.

Discussion

LTFs of the distal humerus occur mainly in the elderly osteoporotic population and distal humeral fractures in the elderly population are on the rise.[2, 12, 13] In previous studies, there were many reports that total elbow arthroplasty was superior to ORIF in terms of reoperation rate and complications.[14, 15] However, recently, studies have been reported that the results of bi-columnar fixation using pre-contoured locking plate are similar to or superior to those of total elbow arthroplasty. Goyal et al.[16] reported that patients who underwent the primary procedure between 2006 and 2016, there was no significant difference in reoperation risk between total elbow arthroplasty and ORIF. The reoperations for TEA consisted of 6.3% aseptic revision, 2.1% removal of implant, and 1.4% elbow release, together comprising nearly 90% of the total reoperations. Conversely, approximately half of the ORIF reoperations (12.1%) were removal of instrumentation. This tends to be a more minor reoperation, assuming that the fracture is healed at the time the instrumentation is removed. It is now generally accepted that the most favorable outcomes can be provided by surgical reduction through elbow posterior approach and rigid internal fixation.[9] Since the posterior approach is performed in the lateral or prone position, most surgery require general anesthesia. Therefore, patients whose state of health precludes general anesthesia, may have to choose non-surgical treatments, predicting the outcome for which, is difficult.

Ulnar neuropathy poses a unique challenge to the posterior elbow approach, as it can be a product of surgical management and associated with DHFs in up to 50% of patients.[17] The meta-analysis of Shearin et al.[18] included 366 patients, of which 187 patients had ulnar nerve in situ decompression and 179 patients had ulnar nerve anterior transposition. The total incidence of ulnar neuropathy was 19.3%, 23.5% in the anterior transposed group, 15.3% in the in-situ group. In 2017, Varecka and Myeroff[9] reported 7.2% new postoperative ulnar nerve changes in a pooled analysis of the distal humeral fracture that included 222 patients. Vazquez et al.[19] explained that neuropathy might bethe result of several causes, including trauma at the time of the injury, manipulation during splinting, intraoperative manipulation, entrapment in scar tissue, or hardware irritation. We performed bi-columnar fixation under brachial plexus anesthesia in the supine position in all 16 patients, including 5 patients with chronic disease with difficulty in general anesthesia. Our approach eliminated the manipulation of the ulnar nerve during surgery by placing the metal plate anterior to the ulnar nerve whilst preserving the soft tissue liner between them, thus minimizing nerve stimulation. In our retrospective analysis of our small cohort, we found no incidence of ulnar nerve symptoms.

This study evaluates the clinical and radiologic outcomes after a minimum follow-up of 12 months after bi-columnar anatomic locking plate fixation of LTFs in 16 elderly patients. We performed the surgery through a combined medial and lateral approach at the elbow without violating the elbow extension mechanism and without ulnar nerve dissection. The mean age at the time of surgery was 81 years (range, 65–91 years) and patients with poor general health received the surgery in the supine position with brachial plexus anesthesia. In most cases, it was possible to achieve adequate fracture fixation, and our results showed a mean range of motion of 10.9° of extension to 126.9º of flexion.

Xie et al.[10] used combined medial and lateral approaches to treat 19 cases of type C (4 cases of C1, 12 of C2, and 3 of C3) fractures of the distal humerus. They were followed up for an average of 15.8 months and the mean age of the patients was 44 years (range, 18–79 years). They reported 2 minor and 1 major complication, but no postoperative ulnar nerve changes as in our results. We believe that for non-comminuted fractures of the distal articular surface of the humerus, this approach can be a reasonable option. However, for C3 type intercondylar fractures or comminuted articular surface fractures, it is relatively difficult to reduce and fix the articular fragments under direct vision through this approach, and it cannot be converted to olecranon osteotomy to expand the scope of exposure. Therefore, we suggest that this approach should be chosen carefully for C3 fractures.

The main shortcomings of our study are the small sample size and the short follow-up period. These limitations may be due to the low incidence rate of these fractures, and because most patients are in their old age. Our strengths are to exclude any other fracture pattern and to have included only a LTF pattern. Additionally, a single surgeon performed all the surgeries, reducing variability.

LTFs of the distal humerus in the elderly can yield satisfactory results with bi-columnar internal fixation through a combined medial and lateral approach.

Abbreviations

AA
aortic aneurysm
AO/OTA
arbeitsgemeinshaft osteosynthesfragen/orthopaedic trauma association
CKD
chronic kidney disease
COPD
chronic obstructive pulmonary disease
CT
computed tomography
DASH
disabilities of the arm, shoulder and hand
DHF
distal humerus fracture
DM
diabetes mellitus
FU
follow up
HTN
hypertension
LCP
locking compression plate
LTF
Low transcondylar fracture
MEPS
Mayo elbow performance score
MI
myocardiac infarction
ORIF
open reduction and internal fixation
ROM
range of motion
TEA
total elbow arthroplasty
VAS
visual analog scale.

Declarations

Acknowledgements

We would like to thank Editage (www.editage.co.kr) for English language editing.

Author’s contributions

S.G.P performed the surgeries, managed the follow-ups of the patients, and supervised the writing of the paper. S.G.P and H.G.S; analyzed and interpreted the patient data and performed the literature search. S.G.P and H.G.S were major contributors in writing the manuscript. Both authors read and approved the final manuscript.

Funding

This work was supported by the 2018 Yeungnam University Research Grant. The authors, their immediate families, and any research foundations with which they are affiliated have not received any financial payments or other benefits from any commercial entity related to the subject of this article.

Availability of data and materials

The datasets used and/or analysed during the current study are available from the corresponding author on reasonable request.

Ethics approval and consent to participate

This study was conducted in accordance with the Declaration of Helsinki and with approval from the Ethics Committee and Institutional Review Board of Yeungnam University Hospital. As a retrospective study, permission was obtained for the consent waiver from the Institutional Review Board.

Consent for publication

Not applicable

Conflict of interest

We have no conflict of interest in this paper.

References

1. Paryavi E, O'Toole RV, Frisch HM, Andersen RC, Eglseder WA. Use of 2 column screws to treat transcondylar distal humeral fractures in geriatric patients. Tech Hand Up Extrem Surg. 2010;14:209–13.
2. Perry CR, Gibson CT, Kowalski MF. Transcondylar fractures of the distal humerus. J Orthop Trauma. 1989;3:98–106.
3. Hwang IY, Park J, Park SS, Yang J, Kang MS. Injury Characteristics and Predisposing Effects of Various Outdoor Traumatic Situations in Children and Adolescents. Clin Orthop Surg. 2021;13:423–35.
4. Simone JP, Streubel PN, Sanchez-Sotelo J, Morrey BF. Low transcondylar fractures of the distal humerus: results of open reduction and internal fixation. J Shoulder Elbow Surg. 2014;23:573–8.
5. Kholinne E, Altamimi LA, Aldayel A, AlSabti R, Kim H, Park D, et al. Primary Linked Total Elbow Arthroplasty for Acute Distal Humerus Fracture Management: A Systematic Review of Clinical Outcome. Clin Orthop Surg. 2020;12:503–13.
6. Schuster I, Korner J, Arzdorf M, Schwieger K, Diederichs G, Linke B. Mechanical comparison in cadaver specimens of three different 90-degree double-plate osteosyntheses for simulated C2-type distal humerus fractures with varying bone densities. J Orthop Trauma. 2008;22:113–20.
7. Werner BC, Rawles RB, Jobe JT, Chhabra AB, Freilich AM. Obesity is associated with increased postoperative complications after operative management of distal humerus fractures. J Shoulder Elbow Surg. 2015;24:1602–6.
8. Korner J, Diederichs G, Arzdorf M, Lill H, Josten C, Schneider E, et al. A biomechanical evaluation of methods of distal humerus fracture fixation using locking compression plates versus conventional reconstruction plates. J Orthop Trauma. 2004;18:286–93.
9. Varecka TF, Myeroff C. Distal Humerus Fractures in the Elderly Population. J Am Acad Orthop Surg. 2017;25:673–83.
10. Xie X, Qin H, Shen L, Zeng B, An Z. Open reduction and bi-columnar internal fixation of intra-articular distal humerus fractures through a combined medial and lateral approach. Eur J Orthop Surg Traumatol. 2014;24:1115–22.
11. Carlan D, Pratt J, Patterson JM, Weiland AJ, Boyer MI, Gelberman RH. The radial nerve in the brachium: an anatomic study in human cadavers. J Hand Surg Am. 2007;32:1177–82.
12. Palvanen M, Kannus P, Niemi S, Parkkari J. Secular trends in the osteoporotic fractures of the distal humerus in elderly women. Eur J Epidemiol. 1998;14:159–64.

13. Dehghan N, Nauth A, Hall J, Vicente M, McKee MD, Schemitsch EH, et al. In Situ Placement Versus Anterior Transposition of the Ulnar Nerve for Distal Humerus Fractures Treated With Plate Fixation: A Multicenter Randomized Controlled Trial. J Orthop Trauma. 2021;35:465–71.
14. McKee MD, Veillette CJ, Hall JA, Schemitsch EH, Wild LM, McCormack R, et al. A multicenter, prospective, randomized, controlled trial of open reduction–internal fixation versus total elbow arthroplasty for displaced intra-articular distal humeral fractures in elderly patients. J Shoulder Elbow Surg. 2009;18:3–12.
15. Githens M, Yao J, Sox AH, Bishop J. Open Reduction and Internal Fixation Versus Total Elbow Arthroplasty for the Treatment of Geriatric Distal Humerus Fractures: A Systematic Review and Meta-Analysis. J Orthop Trauma. 2014;28:481–8.
16. Goyal N, Bohl DD, Ong KL, Lau E, Nicholson GP, Wysocki RW. Reoperation Risk After Total Elbow Arthroplasty Versus Open Reduction Internal Fixation for Distal Humerus Fractures in Elderly Patients. J Orthop Trauma. 2020;34:503–9.
17. Holdsworth BJ, Mossad MM. Fractures of the adult distal humerus. Elbow function after internal fixation. J Bone Joint Surg Br. 1990;72:362–5.
18. Shearin JW, Chapman TR, Miller A, Ilyas AM. Ulnar Nerve Management with Distal Humerus Fracture Fixation: A Meta-Analysis. Hand Clin. 2018;34:97–103.
19. Vazquez O, Rutgers M, Ring DC, Walsh M, Egol KA. Fate of the ulnar nerve after operative fixation of distal humerus fractures. J Orthop Trauma. 2010;24:395–9.

Tables

Case	Age/Sex	Affected side	Mode of injury	AO/OTA classification	Underlying disease	from injury to Surgery (day)	FU period (month)	Flexion (degree)	Extension (degree)	ROM (arc)	Pronation (degree)	Supination (degree)	VAS	MEPS	DASH	T-score	Complications
1	85/M	Left	Slip down	A2.3	AA, CKD	67	40	125	0	125	75	80	0	100 (Excellent)	17.2	-3.4	X
2	73/F	Right	Uncertain	A2.3	Dementia	Uncertain	21	120	-20	100	75	85	3	85 (Good)	24.1	-2.8	X
3	82/F	Right	Slip down	A2.3	Dementia	2	13	110	-5	105	75	85	2	85 (Good)	19.8	-4.3	X
4	81/M	Right	Slip down	A2.3	Arrhythmia, MI	5	32	130	-15	115	60	85	4	70 (Fair)	10.3	-2.3	Loss of reduction in varus
5	66/F	Left	Slip down	A2.3	X	1	25	130	0	130	80	85	3	85 (Good)	19.8	-2.4	X
6	65/F	Right	Slip down	A2.3	X	1	28	130	-20	110	80	60	3	85 (Good)	19.8	-4.4	Stiffness
7	81/F	Left	Slip down	A2.3	HTN	23	19	120	-5	115	85	85	2	85 (Good)	24.1	-2.6	X
8	90/F	Right	Slip down	A2.3	hypothyroidism	13	17	120	-5	115	80	85	1	85 (Good)	26.7	-4.0	X
9	87/F	Right	Slip down	A2.3	COPD	6	18	130	-15	115	80	85	1	85 (Good)	18.1	-5.1	X
10	87/F	Right	Slip down	A3.2	Dementia, HTN	3	16	135	-10	125	90	80	2	85 (Good)	33.6	-4.8	Medial skin necrosis
11	85/F	Right	Slip down	A.2.3	DM, dementia	Uncertain	23	130	-20	110	90	90	3	100 (Excellent)	13.8	-2.4	X
12	82/F	Right	Slip down	A3.1	DM, HTN	6	15	130	-15	115	75	85	4	70 (Fair)	19.8	-3.9	X
13	91/F	Left	Slip down	A3.2	Dementia, HTN	2	12	125	-10	115	85	90	2	75 (Good)	26.7	-4.2	X
14	83/F	Right	Slip down	A2.3	HTN, hypothyroidism	1	13	130	-15	115	80	85	1	85 (Good)	24.1	-2.7	X
15	74/F	Left	Slip down	A2.3	DM,HTN, polyneuropathy	3	13	135	-5	130	80	85	1	85 (Good)	9.5	-3.9	X
16	83/M	Left	Slip down	A2.3	Vascular dementia	2	15	130	-15	115	80	85	2	85 (Good)	21.7	-3.8	X

Table 1 Characteristics and summary of our results in 16 cases

AO/OTA arbeitsgemeinshaft osteosynthesfragen/orthopaedic trauma association, *FU* follow up, *VAS* visual analog scale, *MEPS* Mayo elbow performance score, *DASH* disabilities of the arm, shoulder and hand, *ROM* range of motion, *DM* diabetes mellitus, *HTN* hypertension, *AA* aortic aneurysm, *COPD* chronic obstructive pulmonary disease, *CKD* chronic kidney disease, *MI* myocardiac infarction.

Figures

Figure 1

a Anterior-posterior and **b** lateral X-ray of a 75-year-old female patient taken before surgery. fracture was defined as an extra-articular fracture with a single transverse fracture line that consistently exited at the level of or distal to the lateral epicondyle laterally, and at the level of or just proximal to the medial epicondyle.

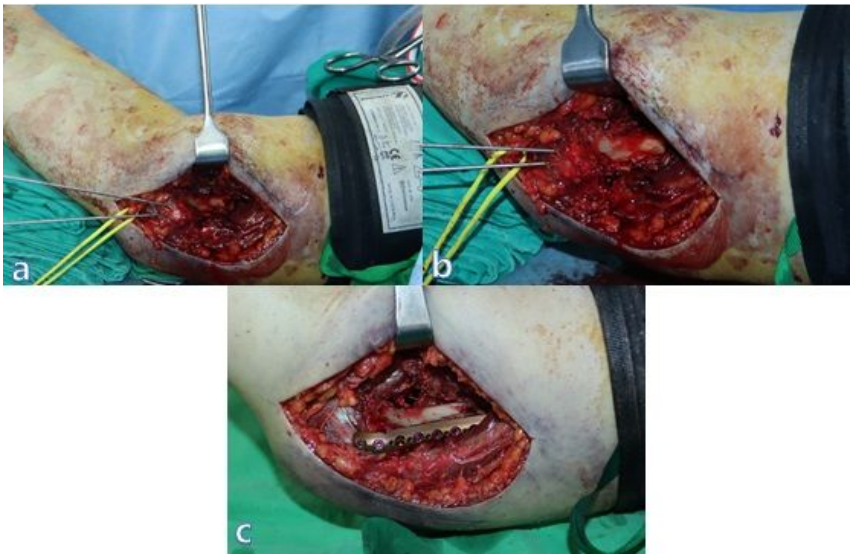

Figure 2

a Medial approach is performed through an incision measuring approximately 8 cm, starting at one finger breadth distally from the tip of the medial epicondyle and proceeding proximally along the medial supracondylar ridge of the humerus toward the axillary line. The elbow was then flexed about 80°, and the biceps and brachialis muscles were retracted anteriorly, the fracture site was subsequently exposed. **b** The medial column was first reduced, following which one or two 1.6 mm K-wires were inserted for provisional fixation. **c** A short locking compression plate on the medial column.

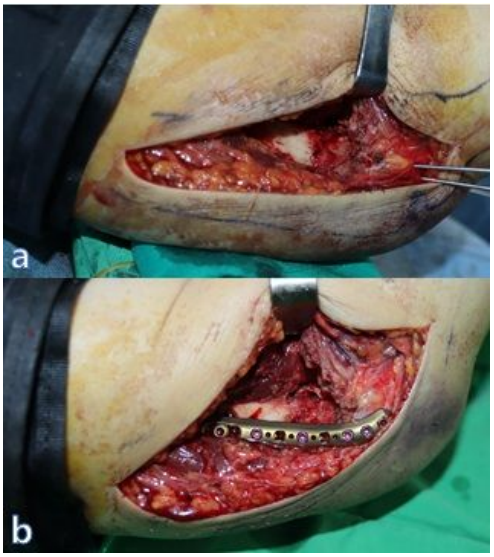

Figure 3

a We carefully approached at around 10 cm proximal to the lateral epicondyle because the radial nerve pierced the lateral intermuscular septum. Distally, dissection through the interval between the triceps muscle and the origins of the extensor carpi radialis longus and the brachioradialis muscle exposed the lateral border of the humerus. The origin of brachioradialis was partially released, and the anterior articular surface of the capitulum was exposed. The lateral column was also reduced and temporally fixed using 1.6 mm K-wires. **b** A long locking compression plate were used on the lateral column.

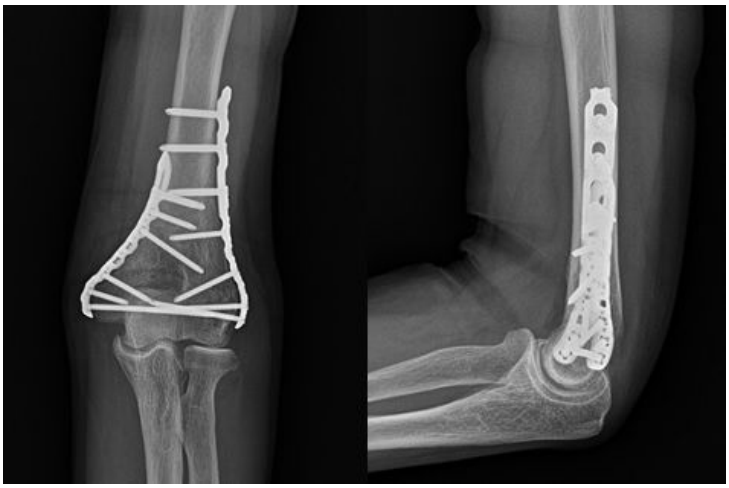

Figure 4

Post-operative X-rays of 75-year-old female patients. The plates are positioned so that the distal screws can be fixed parallel to the anterior surface of the humeral condyles. Two or three screws were fixed to the distal bone fragment on each side, and efforts were made to implant one or more long screws on each side to purchase the opposite column.