Sub-Axillary Cosmetic Incision VS Single-Incision Thoracoscopic Surgery for Primary Spontaneous Pneumothorax

Yuan-Liang Zheng (610070446@qq.com)

Wenzhou Central Hospital, The Dingli Clinical Institute of Wenzhou Medical University, the Second Affiliated Hospital of Shanghai University

Ri-Sheng Huang

Wenzhou Central Hospital, The Dingli Clinical Institute of Wenzhou Medical University, the Second Affiliated Hospital of Shanghai University

---

Research Article

Keywords: Pneumothorax, Single-incision thoracoscopic surgery, Sub-axillary cosmetic incision, Propensity score matching, Video-assisted thoracoscopic surgery

Posted Date: February 24th, 2022

DOI: https://doi.org/10.21203/rs.3.rs-1351964/v1

Abstract

Background

Recently, single-incision thoracoscopic surgery (SITS) has gained attention as an optimal treatment for the primary spontaneous pneumothorax (PSP). However, most SITS techniques use in the fourth to sixth intercostal space between the anterior axillary and mid axillary lines. To find out more concealed incisions, this study performed PSP surgery with the sub-axillary cosmetic incision (SACI) technique.

Methods

A total of 128 patients with PSP underwent video-assisted thoracoscopic surgery (VATS) at our institution between January 2017 and January 2019. These patients were evaluated and divided into SACI (n = 21) and SITS group (n = 57). Propensity score matching (PSM) was performed based on the patient's backgrounds, and the enrolled cohort was divided into 21 pairs. The incision satisfaction was analyzed at 2 weeks and 6 months post-surgery, whereas the recurrence probability of ipsilateral pneumothorax was assessed within 6 months after the operation.

Results

Twenty-one pairs with baseline characteristics matched into the two groups had no significant differences in their backgrounds and surgical results. However, the operation time was longer in the SACI group than in the SITS group ($p = 0.013$). The median age in the SACI group was 24.9 ± 6.6 years, out of the 21 patients, 17 were males, 7 patients had a smoking history, and 2 patients had pleural adhesion. The median age in SITS group was 24.0 ± 4.4 years, out of the 21 patients, 17 were males, 6 patients had smoking history, and 4 patients had thoracic adhesion. There were no post-operative complications found in both groups. The incision satisfaction score in the SACI group was lower than the SITS group at 2 weeks and 6 months, and the difference was statistically significant (respectively, $p = 0.022$ and $p = 0.039$). There were no recurrences of ipsilateral pneumothorax in both groups.

Conclusions

SACI is a safe and feasible surgical method for the treatment of PSP. In addition, incision concealment can be used based on the choice for patients with incision needs.

Background

PSP is the commonest chest disease in adolescents[1]. The standard surgical procedure for these patients includes VATS bullectomy. Compared with traditional thoracoscopic surgery, conventional three-port

VATS provides significant benefits in reduced pain and respiratory function recovery[2]. Recently, Gonzalez et al. [3] have shown that SITS has a better cosmetic effect and less incision pain than conventional multiport procedures. However, most SITS are made in the skin at the fourth to sixth intercostal space between the anterior axillary and mid axillary lines [4,5]. Further, Hee et al. [6] showed 70.4% satisfaction of wound scarring. These studies direct the need for a more concealed incision that can improve the comfort of wound scarring in PSP patients. Therefore, this study aims to evaluate the safety as well as the effectiveness of the SACI technique compared to SITS for treating PSP patients.

Methods

Between January 2017 and January 2019, we retrospectively reviewed the surgical records of 128 consecutive patients who underwent VATS for PSP. Written and oral informed consent was received by all patients. The present study was approved by the ethics committee of Wenzhou Central hospital (L2017-02-140).

Inclusion Criteria: 1) patients with primary pneumothorax; 2) patients whose location and extent of bullae was verified by the pre-operative high-resolution computed tomography scans of the chest; 3) patients aged between 15 and 40 years; 4) patients without insertion of a chest tube before surgery.

Exclusion Criteria: 1) patients with no history of lung diseases, such as pulmonary fibrosis, pulmonary tuberculosis, chronic obstructive pulmonary disease; 2) patients with no history of ipsilateral lung surgery; 3) patients with co-morbidity of hemopneumothorax; 4 patients unwilling to accept surgical treatment, patients did not agree to provide consent; 5 patients with life-threatening tension pneumothorax where emergency thoracic closed drainage is needed; 6) patients with incomplete records.

We surveyed age, sex, height, weight, intra-operative adhesions, smoking history, side involved, operation time, blood loss during surgery, post-operative drainage, duration of post-operative hospital stay, post-operative complications and post-operative pain scores evaluated using visual analog scales (VAS) from 0 (no pain) to 10 (worst pain ever experienced). Pain scores were recorded at 24h, 48h, 72h and the first week after surgery. In addition, all patients were follow-up for at least 6 months using post-operative telephone interviews. The follow-up was conducted to evaluate the level of satisfaction with the surgical wound and recorded in 4 grades (excellent =1~2, good =3~4, fair =5~6, and poor =7~8) at 2 weeks and 6 months after surgery. The detailed guideline of the scoring scale is shown in Table 1.

Table 1
Scoring scale

Grades	Scores	Incision performance
Excellent	1	Good concealment of incision and scar hyperplasia is not obvious
	2	Good concealment of incision and mild scar hyperplasia
Good	3	General concealment and mild scar hyperplasia
	4	General concealment and moderate scar hyperplasia
Fair	5	General concealment and severe scar hyperplasia
	6	Poor concealment and mild scar hyperplasia
Poor	7	Poor concealment and moderate scar hyperplasia
	8	Poor concealment and severe scar hyperplasia

Surgical technique

Using a double-lumen endotracheal tube and one-lung ventilation, two groups of surgeries were performed on the patients under general anesthesia. First, the patients were placed in a lateral decubitus position. Our surgical principle for PSP was to perform lung wedge resection with the same types of endoscopic stapler. No residual lesions were identified intra-operatively. Further, a water inundation test was performed to check for air leakage. Finally, a 20F chest tube was inserted into the top of the pleural cavity and connected to a water-sealed bottle through the incision site. An intradermal suture was performed around the tube with 3-0 Vicryl, and the chest tube was fixed with a suture knot that was not tied under the skin. The thread was removed after the chest tube was removed, and the 3-0 Vicryl suture was tightened further.

SITS technique

A 2.5-cm long skin incision was made in the fourth or fifth intercostal space between the anterior axillary line and mid axillary line. The protective sheath was placed in the incision. The 5-mm, 30^0 thoracoscopy was introduced through the incision, to keep the thoracoscopy close to the mid axillary line. The whole chest was explored with lung collapse, whether there were adhesions, the location and the size of the bulla of the lung. Finally, and the bulla were removed with the same type of endoscopic stapler (Fig. 1).

SACI technique

A 2.5-cm long skin incision was made in the axillary fold, exposing the intercostal space with a hook (because the skin incision was not parallel to the intercostal space, it was about 90 degrees), selected at the third intercostal space. The protective sheath was placed in the incision, the 5-mm, 30^0 thoracoscopy was introduced through the incision, to keep the thoracoscopy close to the mid axillary line. The whole

chest was explored with lung collapse, whether there were adhesions, the location and the size of the bullae of the lung, and the bullae were removed with the same type (Johnson Echelon 45) of the endoscopic stapler (Fig. 1).

Statistical analysis

PSM was performed to reduce the biases in patient selection. The logistic regression was used to calculate the propensity score. The covariates of age, sex, weight, height, side involved, intraoperative adhesions, and smoking history included in the calculation, which might affect the comparison result of the two groups. Patients in both groups were matched 1-to-1 with a caliper distance of 0.2; thus, no replacement was required. After PSM, the matching produced 21 patients in each group after PSM.

Data were analyzed using the Statistical Product and Service Solutions (SPSS) software (version22.0, SPSS Inc., Chicago, IL, USA) program. Categorical variables were presented as percentages and compared by the chi-square test or Fisher's exact test. Shapiro Wilk was used for the normality test (when $p>0.05$, the data is close to normal distribution). Continuous variables with normal distribution were expressed as medians ±standard deviation and compared by student's t-test. The Mann-Whitney U test was used to compare means of continuous variables with non-normal distribution; continuous variables were summarized as median and interquartile range, with statistical significance set at $p<0.05$.

Results

A total of 128 consecutive patients underwent VATS for the treatment of PSP. Among them, cases of spontaneous hemopneumothorax (n = 4), incomplete medical records (n = 7), lung disease (n = 8), older than 40 or younger than 15 (n = 11), history of ipsilateral lung surgery (n = 1), and insertion of chest tube before surgery (n = 19) were omitted from the study. Subsequently, 78 patients were finally included in our study, 21 treated with SACI and 57 with SITS. The baseline characteristics of the included 78 patients are shown in Table 1, The denoted study selection process is shown in Fig. 4. The mismatched analysis revealed significant differences in the age and height of the two groups (p = 0.025 and p = 0.038, respectively). Before propensity score matching, the median age of the SACI group was 24.9 ± 6.6 years, with a median height of 169.8 ± 5.3 cm, 17 patients were male (81%), 7 patients smoked (33.3%), 2 patients had pleural adhesion (9.5%). The median age of SITS group was 22. 1 ± 3.9 years and the median height was 172.6 ± 5.2 cm. Out of 57 patients, 36 patients were male (63.2%), 13 patients were smokers (22.8%), and 10 patients had pleural adhesions (17.5%). Finally, 21 pairs of patients were matched for this study. No significant differences were observed on any baselines after PSM. The baseline characteristics post PSM are presented in Table 2. Post PSM, the median age was 24.9 ± 6.6 and 24.0 ± 4.4 years in the SACI and SITS groups, respectively. The surgical and post-operative outcomes after PSM are shown in Table 3. Patients receiving SACI had significantly longer surgical time than SITS ($p = 0.013$). However, the hospital stays after surgery, post-operative complications, pain scores on post-operative days, blood loss during surgery, and the post-operative drainage was similar in both groups. The SACI group had lower patient satisfaction scores than the SITS group at 2 weeks (Fig. 2) and 6

months (Fig. 3) after surgery, the difference was statistically significant (respectively, p = 0.022 and p = 0.039). Of note, no cases of post-operative complications were observed in either group during the follow-up period.

Table 2
The baseline characteristics of patients

	Before propensity score matching			**After propensity score matching**		
Characteristics	SACI group (n = 21)	SITS group (n = 57)	*p*-value	SACI group (n = 21)	SITS group (n = 21)	*p*-value
Age(years)	24.9 ± 6.6	22.1 ± 3.9	0.025[a]	24.9 ± 6.6	24.0 ± 4.4	0.17
Sex			0.135			1.00
Male	17(81%)	36(63.2%)		17(81%)	17(81%)	
Female	4(19%)	21(36.8%)		4(19%)	4(19%)	
Weight(kg)	57.1 ± 5.0	57.5 ± 4.3	0.752	57.1 ± 5.0	56.8 ± 3.9	0.467
Height(cm)	169.8 ± 5.3	172.6 ± 5.2	0.038[a]	169.8 ± 5.3	170.3 ± 5.2	0.449
Side involved			0.993			0.938
Right	13(61.9%)	36(63.2%)		13(61.9%)	14(66.7%)	
Left	6(28.6%)	16(28.1%)		6(28.6%)	5(23.8%)	
Bilateral	2(9.5%)	5(8.8%)		2(9.5%)	2(9.5%)	
Smoking			0.345			0.739
Yes	7(33.3%)	13(22.8%)		7(33.3%)	6(28.6%)	
No	14(66.7%)	44(77.2%)		14(66.7%)	15(71.4%)	
Pleural adhesion			0.605			0.663
Yes	2(9.5%)	10(17.5%)		2(9.5%)	4(19%)	
No	19(90.5%)	47(82.5%)		19(90.5%)	17(81%)	

SACI = sub-axillary cosmetic incision; SITS = single-incision thoracoscopic surgery; [a] $p<0.05$, the difference was statistically significant. values are medians ± standard deviation for continuous variables or cases (%) for categorical variables.

Table 3
Postoperative events after propensity score matching

Characteristics	SACI group (n = 21)	SITS group (n = 21)	*P*-value
Operation time (min)	71.1 ± 11.6	58 ± 11.4	0.013[a]
Blood loss during surgery (ml)	29.5 ± 18.0	27.1 ± 7.2	0.571
Postoperative drainage (ml)	134.3 ± 40.6	134.8 ± 31.4	0.971
Postoperative hospital stays (d)	2.5 ± 0.7	2.4 ± 0.6	0.629
Postoperative complication			1.00
Yes	0	0	
No	21 (100%)	21 (100%)	
Pain scores after surgery			
24h median (interquartile)	3(1–9)	4(1–10)	0.878
48h	2(1–5)	2(1–6)	0.432
72h	2(1–3)	2 (1–3)	0.776
The first. week	1(1–2)	1(1–2)	1.0
Wound satisfaction scores (2-weeks)	3(1–5)	4(2–6)	0.022[a]
Wound satisfaction scores (6-months)	3(1–6)	4(2–9)	0.039 [a]

SACI = sub-axillary cosmetic incision; SITS = single-incision thoracoscopic surgery; [a] $p<0.05$, the difference is statistically significant. values are medians ± standard deviation or median (interquartile) for continuous variables or cases (%) for categorical variables.

Discussion

Compared with the conventional thoracotomy, VATS has many advantages[7]. The conventional three-port VATS bullectomy is the most popular method for PSP surgery. However, patients who underwent conventional three-port VATS usually complain of post-operative pain and paresthesia[8]. To address these post-operative complications, efforts have been made to reduce the length of incisions, as the SITS approach reportedly had better cosmetic effects and lower rates of post-operative pain and paresthesia[9]. Nonetheless, converting three holes to a single hole is a long process, requiring technological progress apart from appropriate instruments. For example, Racco et al.[10] introduced SITS for treating PSP in 2004, but the SITS technique was not widely used in the last decade. The instrument collision that needed a relatively long skin incision was one of the hindrances for its wide acceptance. Moreover, the lack of

flexible instruments like double joints made it impossible for the operator to complete the operation in a single narrow operation space. To minimize collisions between surgical instruments and reduce incision size, Mogi et al.[11] described a SITS technique which utilized a thin puncture device similar to a retractor. Bong et al.[12] modified the SITS technique using a wound protector and a bidirectional anchoring suture, whereas Kenji et al. [13] used a chest wall pulley for PSP. Despite that, the above single hole operation techniques have not been widely adopted and popularized because of the cumbersome operation steps prolonged operation, and complications in making the pulmonary bullectomy. In 2014, Ng et al.[14] developed novel, smaller, and more specialized procedure-specific instruments for SITS, which allowed the reduction of incision size. Since then, with the continuous advances in endoscopic technology and the use of relatively new instruments, single hole thoracoscopic bullectomy has become more and more simple. Moreover, due to the emergence of new instruments, surgeons are becoming willing to accept and adopt the single-hole thoracoscopic bullectomy. Even though the incision is smaller than before, the wound scarring was not concealed enough, which affected the patient's satisfaction after surgery. Of note, cosmetics requests were more frequent among the younger patients. Therefore, we used the SACI technique, which used a more concealed way of suturing and resulted in better satisfaction, especially for young patients. The satisfaction score of the SACI technique was lower than SITS approach, and the difference is statistically significant.

We presented 128 cases of VATS for PSP, the 5-mm, 30^0 thoracoscopy was used in all the bullectomy. This provided enough visual field for surgery, which was especially suitable for the 2.5-cm incision. At present, 5mm thoracoscopy is the best choice to reduce the operation space without affecting the operation field of vision. There was no conversion reported to open thoracotomy in both groups. Neither group had post-operative complications, indicating that the operation technology was safe and feasible. Previous studies have reported the high recurrence probability of pneumothorax after bullectomy which can be reduced by using pleural abrasion during the operation[15]. However, Hatz et al.[16] showed that pleural abrasion would increase the post-operative thoracic drainage, delay extubation, promote post-operative complications and secondary operation difficulty. In our study, none of the surgical patients received any treatment for pleural abrasion and had no recurrence of pneumothorax during follow-up. However, the routine use of pleural abrasion is not recommended, especially for young patients.

Between both groups, no significant difference was observed for the hospital stay after surgery, post-operative complications, pain scores on post-operative days, blood loss during surgery, and post-operative drainage. However, the operation time of the SACI group was significantly prolonged than the SITS group ($p = 0.013$). In addition to the longer time caused by chest adhesion, the main reason was the surgical path. Due to the high position of sub-axillary cosmetic incision, relatively limited field of vision, the skin incision and subcutaneous muscle direction were not consistent. Consequently, the time from skin incision to entering the chest cavity was also relatively long.

The satisfaction of incision in the SCAI group was higher than the SITS group. First, the incision in the SACI group was at the axillary dermatoglyphic. After the patient hands dropped naturally, the incision

position could hardly be seen. Given the convenience of post-operative follow-up, we evaluated the incision at 2 weeks postoperatively; however, at this time, the incision was not old enough for scar hyperplasia. Therefore, the incision looked smooth, and the satisfaction score was high. However, the overall satisfaction with the incision of the patients at 6 months after the operation was lower than the 2 weeks post-operation. This might have resulted as some patients had obvious scar hyperplasia from the incision 6 months after the operation in the SACI group. The axillary hair of these patients did not cover the scar completely, resulting in a decrease in post-operative satisfaction. Since this study had a short-term follow-up of 6 months after the operation, it was unclear whether the patient's satisfaction with the incision would change one or more years after the operation.

As the treatment methods of pneumothorax were not randomly assigned, the baseline characteristics of the two treatment groups were different. The use of PSM reduced the deviation characteristics caused by the unbalanced covariates. Our study had few limitations. Although we used PSM to reduce selection bias, the total number of patients was small, and the post-operative follow-up time was short.

Conclusions

In this study, we found that the SACI was a safe and effective technique for PSP treatment. This single-center retrospective study of SACI for the treatment of PSP might be a potential alternative way to manage patients with PSP in selected cases, especially for patients with high requirements of wound concealment.

Abbreviations

SITS: Single-incision thoracoscopic surgery; PSP: Primary spontaneous pneumothorax; SACI: Sub-axillary cosmetic incision; VATS: Video-assisted thoracoscopic surgery; PSM: Propensity score matching; VAS: Visual analog scales, SPSS: Statistical Product and Service Solutions.

Declarations

Ethics approval and consent to participate

This study protocol was approved by the ethics committee of Wenzhou Central hospital (L2017-02-140). Written and oral informed consent was received by all patients. This study followed the Declaration of Helsinki.

Consent for publication

Not applicable.

Availability of data and materials

The datasets of the current study are available from the corresponding author upon reasonable request.

Competing interests

The authors have no conflicts of interest in this work.

Funding

This work was supported by the Natural Science Foundation of Zhejiang Province, LQ22H160024.

Authors' contributions

YL collected and recorded the original data. RS analyzed the data and was a major contributor in writing the manuscript.

Acknowledgements

We are gratefully to the following surgeons: Chi-chao Wang, Wen-Shen Ye and Liang-Da Jin

References

1. Mendogni P, Vannucci J, Ghisalberti M, et al. Epidemiology and management of primary spontaneous pneumothorax: a systematic review. Interactive cardiovascular and thoracic surgery. 2020;30(3):337–345.
2. Nagahiro I, Andou A, Aoe M, et al. Pulmonary function, postoperative pain, and serum cytokine level after lobectomy: a comparison of VATS and conventional procedure. The Annals of Thoracic Surgery. 2001;72(2).
3. Gonzalez-Rivas D. Recent advances in uniportal video-assisted thoracoscopic surgery. Chinese Journal of Cancer Research. 2015;27(01):90–93.
4. Chen P-R, Chen C-K, Lin Y-S, et al. Single-incision thoracoscopic surgery for primary spontaneous pneumothorax. Journal of Cardiothoracic Surgery. 2011;6(1).
5. Berlanga LA, Gigirey O. Uniportal video-assisted thoracic surgery for primary spontaneous pneumothorax using a single-incision laparoscopic surgery port: a feasible and safe procedure. Surgical Endoscopy. 2011;25(6).
6. Yang HC, Cho S, Jheon S. Single-incision thoracoscopic surgery for primary spontaneous pneumothorax using the SILS port compared with conventional three-port surgery. Surgical Endoscopy. 2013;27(1).
7. Sawada S, Watanabe Y, Moriyama S. Video-Assisted Thoracoscopic Surgery for Primary Spontaneous Pneumothorax. Chest. 2005;127(6).
8. Mier JM, Chavarin A, Izquierdo-Vidal C, et al. A prospective study comparing three-port video-assisted thoracoscopy with the single-incision laparoscopic surgery (SILS) port and instruments for the video thoracoscopic approach: a pilot study. Surgical endoscopy. 2013;27(7):2557–2560.

9. Jutley RS, Khalil MW, Rocco G. Uniportal vs standard three-port VATS technique for spontaneous pneumothorax: comparison of post-operative pain and residual paraesthesia. European Journal of Cardio-Thoracic Surgery. 2005;28(1).
10. Rocco G, Martin-Ucar A, Passera E. Uniportal VATS wedge pulmonary resections. The Annals of Thoracic Surgery. 2004;77(2).
11. Mogi A, Yamaki E, Kosaka T, et al. Thoracoscopic Wedge Resection Through a Single Incision Using a Thin Puncture Device. Annals of Thoracic and Cardiovascular Surgery. 2014;20(3).
12. Son BS, Kim DH, Lee SK, Kim CW. Small Single-Incision Thoracoscopic Surgery Using an Anchoring Suture in Patients With Primary Spontaneous Pneumothorax: A Safe and Feasible Procedure. The Annals of Thoracic Surgery. 2015;100(4).
13. Tsuboshima K, Nagata M, Wakahara T, Matoba Y, Maniwa Y. Feasibility of single-incision thoracoscopic surgery using a modified chest wall pulley for primary spontaneous pneumothorax: a propensity score matching analysis. Surgery Today. 2017;47(9).
14. H NCS, Gaetano R, L WRH, H LRW, H YSC, C YAP. Uniportal and single-incision video-assisted thoracic surgery: the state of the art. Interactive cardiovascular and thoracic surgery. 2014;19(4).
15. Gossot D, Galetta D, Stern JB, et al. Results of thoracoscopic pleural abrasion for primary spontaneous pneumothorax. Surgical endoscopy. 2004;18(3):466–471.
16. Hatz RA, Kaps MF, Meimarakis G, et al. Long-term results after video-assisted thoracoscopic surgery for first-time and recurrent spontaneous pneumothorax. The Annals of Thoracic Surgery. 2000;70(1).

Figures

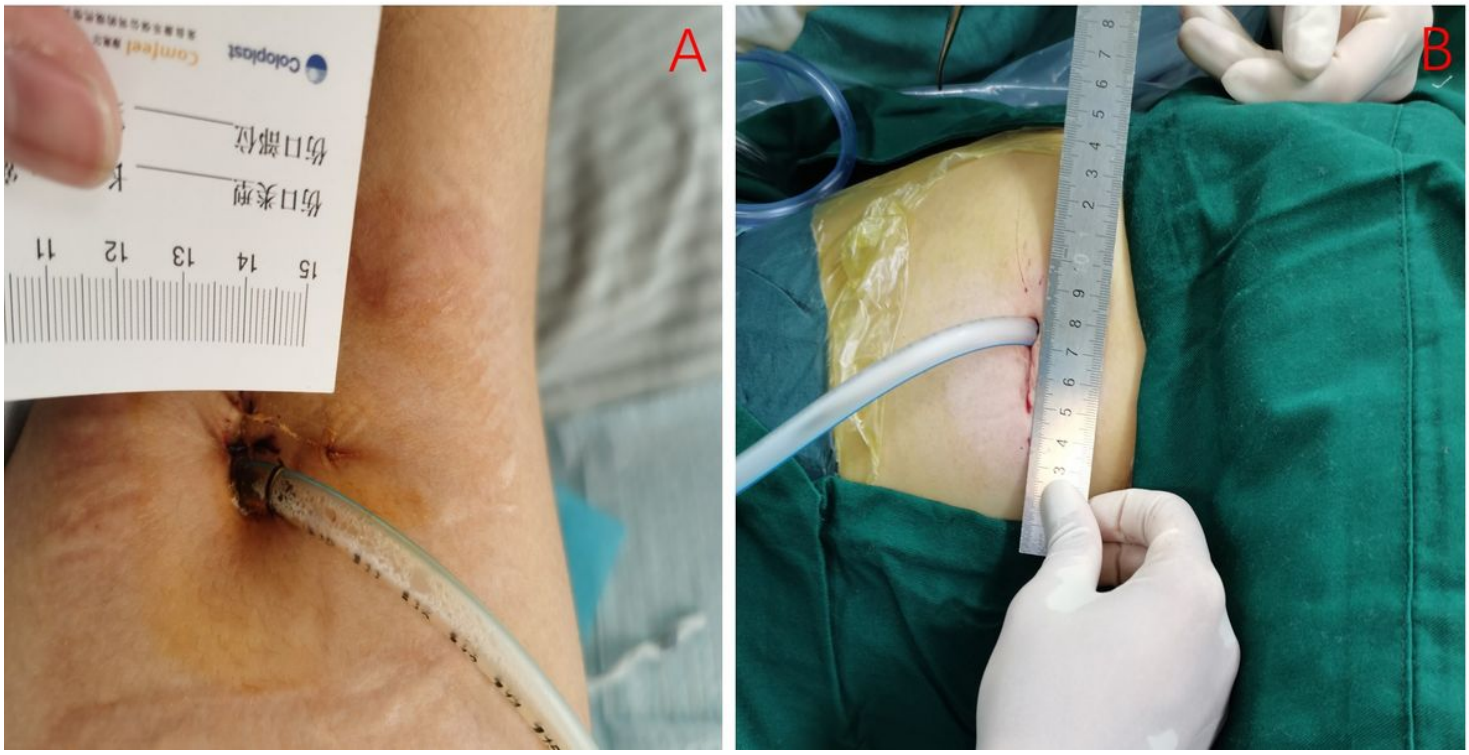

Figure 1

A represent a SACI technique with a 2.5-cm incision to place a chest drainage tube,

B represent a SITS technique with a 2.5-cm incision to place a chest drainage tube.

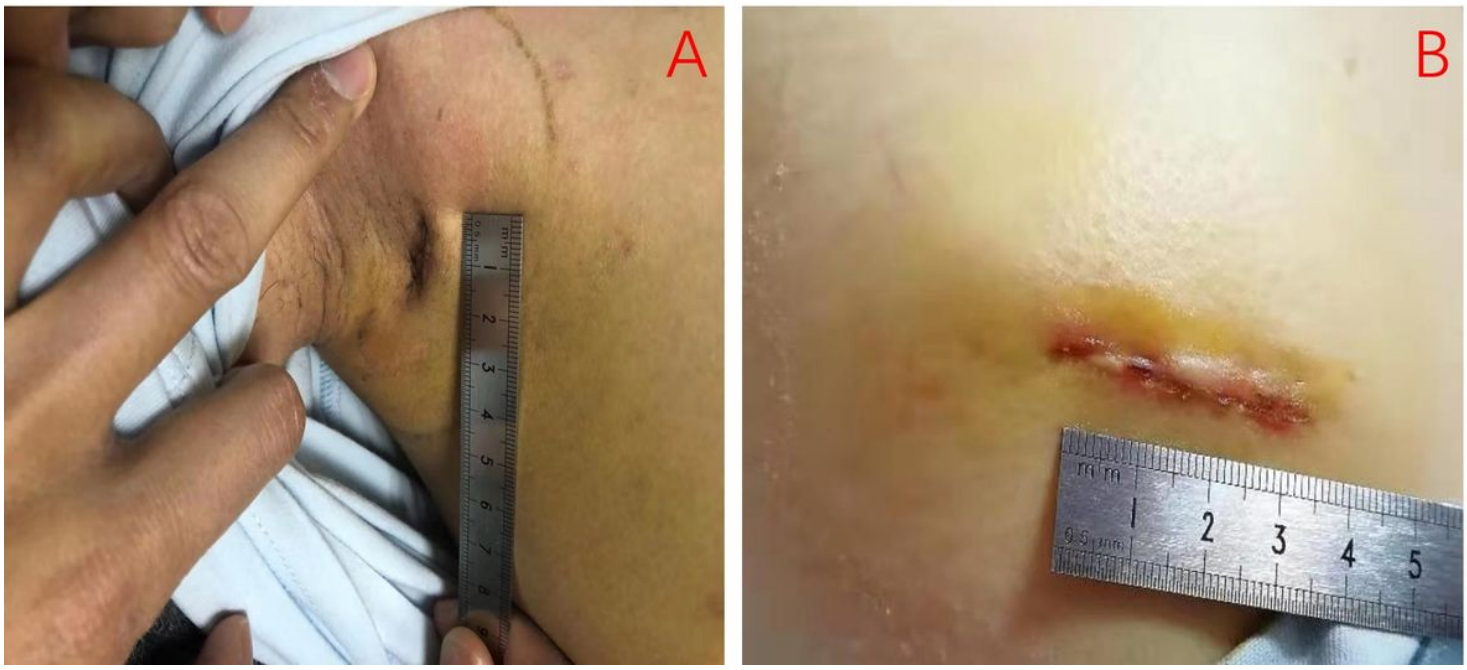

Figure 2

A represent the wound healing in two weeks after operation with SACI technique.

B represent the wound healing in two weeks after operation with SITS technique.

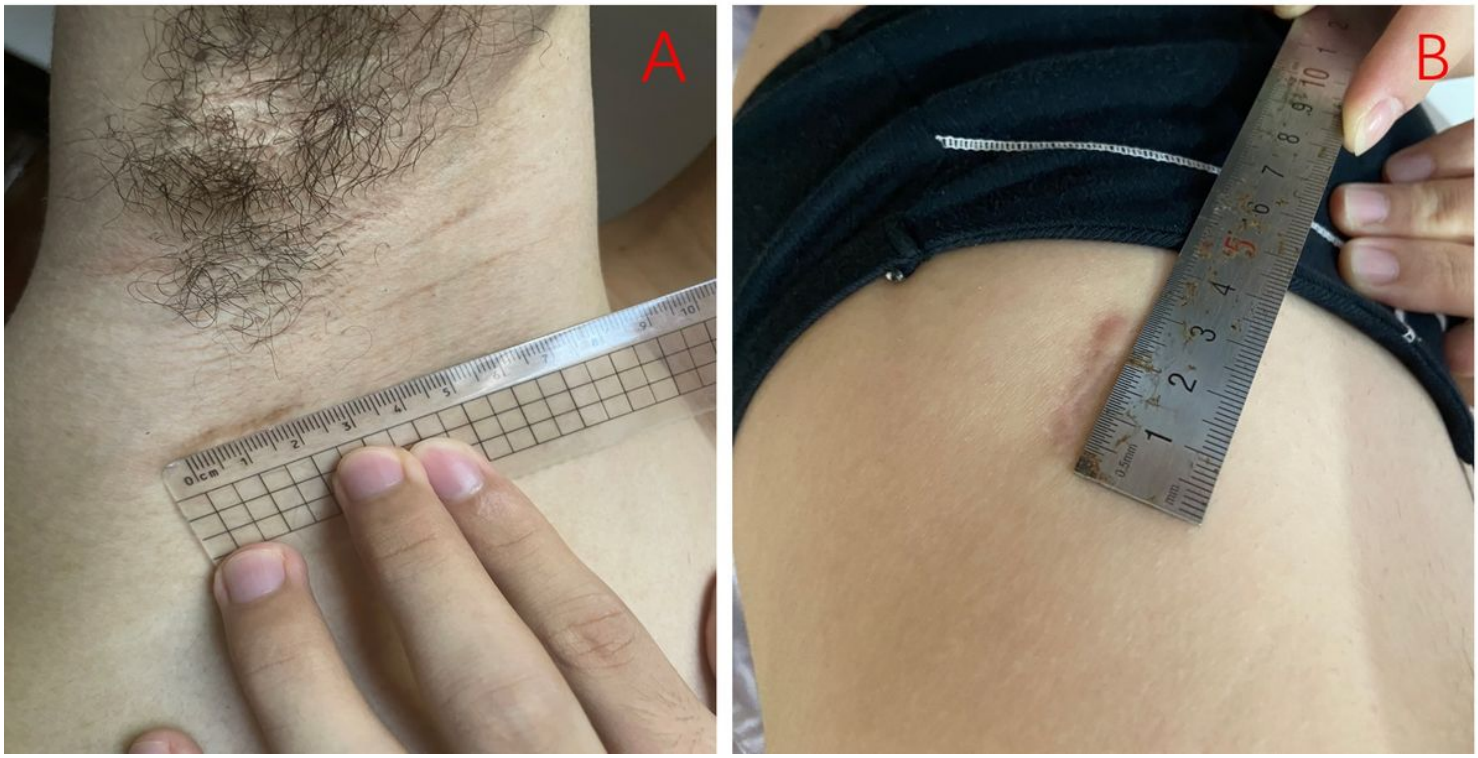

Figure 3

A represent the wound healing in 6 months after operation with SACI technique.

B represent the wound healing in 6 months after operation with SITS technique.

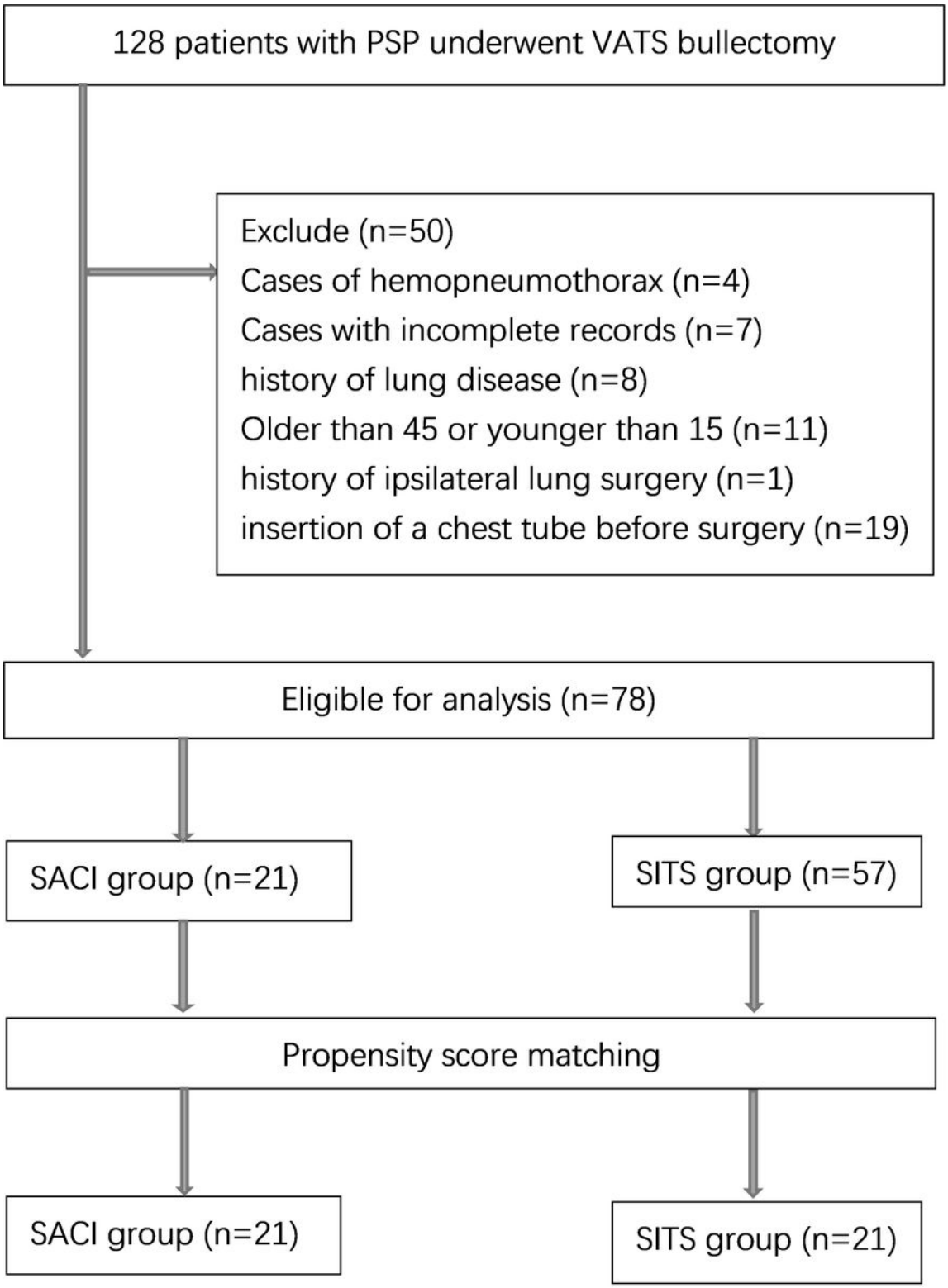

Figure 4

Details of the study enrollment