The characteristic appearance of isolated lenticular posterior capsule rupture captured by Ultrasonic Doppler

Ying-Hua Du (duxuer_doo@126.com)
Beijing Tiantan Hospital https://orcid.org/0000-0002-6660-9105

Ran Li
Hebei Medical University No2 Hospital: Second Hospital of Hebei Medical University

Su-Zhen Cai
Hebei Medical University No2 Hospital: Second Hospital of Hebei Medical University

Zhi-Yang Jia
Hebei General Hospital

Xiao-Ting Ma
Hebei General Hospital

Research Article

Keywords: Ocular blunt trauma, Cataract, Isolated posterior capsule rupture, Ultrasonic doppler, phacoemulsification

Posted Date: March 15th, 2022

DOI: https://doi.org/10.21203/rs.3.rs-1355105/v1

Abstract

Background: The isolated lenticular posterior capsule rupture (ILPCR) due to ocular blunt trauma was too occult to be found. The pictures captured by Ultrasonic doppler (UD) were so distinctive and could help to discover and manage conveniently.

Method: 6 cases (six eyes) were reviewed from 2017 to 2021. The ultrasonogram features were analyzed. All cases accepted surgical management and the best corrected visual acuity (BCVA) were observed by 3 months follow-up.

Results: The sign of ILPCR showed a loose, translucent and flocculence-like cortex in the rupture location of the lens on the view of silt-lamp. All ultrasonograms displayed incomplete waveform of the surface between the lenticular posterior capsule and the anterior vitreous. Lenticular matters scattered in the margin at the interface. All six cases occurred in the young patients and were managed by phacoemulsification with vitrectomy and intraocular lens (IOL) in ciliary groove implantation. The visual acuity at 1 and 3-months post-operation improved significantly in comparison to pre-operation assessment ($P < 0.01$).

Conclusion: ILPCR due to ocular blunt trauma is very rare in clinical practice. Only silt-lamp examination might be not enough. However, UD (7~10MHz) will be a good supplementary method. It has guidance and reference value in clinical therapy and prognosis, and can provide superior and objective information because it has many advantages such as improvement in the axial minimum resolution, variable frequency of the probe and broader detection range.

Background

The traumatic cataract with the isolated rupture of the posterior capsule (ILPCR) was very rare following ocular blunt injury [1]. The external force could display diverse signs and symptoms in clinical practice. With the view of the damaged lens, the blunt force could trigger 3 conditions. Firstly, lens subluxation was due to partially fractured suspensory ligament; Secondly, lens dislocation could happen due to completely fractured suspensory ligament; Last, lens only became opacity without suspensory ligament involvement [2, 3]. However, for the last one, it was easy to ignore what was the truth of serious cataract with the rupture on the posterior capsule. The break of posterior capsule was concealed in opaque cortex, thus giving a false impression of intact one. This would mislead the decision to prepare the following management.

Since ILPCR was too occult to be discovered directly, it was a challenge to distinguish with direct check-up, such as silt-lamp. Thus, Shen [4] and Grewal [5] ever reported that some details about ILPCR by anterior segment OCT and Scheimpflug imaging respectively. But the methods were weak to have limited image quality in some cases with significantly opaque media [6].

However, ultrasonic technique can objectively document the abnormal, predict the operation design, help to evaluate the density of traumatic cataract if any, and monitor its progression. Murat Kucukevcilioglu [7] illustrated that 35 MHz ultrasound biomicroscopy (UBM) could detect ILPCR clearly. But UBM was only limited to show the anterior segment imaging. And in an opaque media, the information of posterior segment was also important. Whether or not was a method simultaneously supply the anterior and posterior segment' imaging accurately in severe traumatic cataract cases? In this study, we tried to take advantage of UD. The design of UD was based on the principles of ultrasonic wave propagation in biological tissue such that the tissue characteristics and geometry size differences facilitate ultrasonic wave transmission, reflection, diffraction and interference propagation. The fluctuations were different because the amplitude, frequency, phase, and other parameters of the received signal could be changed following different interface.

In this study, we firstly studied the UD ultrasonograms of six ILPCR cases (six eyes), which suffered blunt trauma between 2017 and 2021, and collated the data of the characteristics, surgical design and visual acuity progression, in order to discuss the technical features and clinical application.

Methods

Patients

Six male patients, aged 11–33 years. The average age was 19.17 ± 11.125 years. All patients had sustained blunt trauma in one eye. The first time for seeking medical advice was from five days to two weeks post-accident. The patients were enrolled because of diagnosis by UD check-up. And their best corrected visual acuity (BCVA) was followed-up from 1 month to 3 months.

Methods

This research activities were approved by the Medical Research Ethics Committee of HeBei General Hospital. We retrospectively analyzed the UD ultrasonogram MyLab™Seven (Esaote, Genova, Italy) features, surgical design and improvement of visual acuity of the six ILPCR cases. By analyzing the data of UD, technical advantages and clinical signs were found.

The progression of therapy

The visual acuities of all six cases were severely affected on examination of the BCVA (LogMAR) ranged from + 2.00–+3.00. Intraocular pressure, slit-lamp (Carl Zeiss Meditec AG, Germany) and UD were usually carried. The intraocular pressure was normal. The slit-lamp examination revealed transparent cornea, normal pupil, no evident iridotromos, innocent zonule and absence of vitreous hernia into anterior chamber, but showed completely white opaque lens, loose and flocculence-like cortex with partly fluidity near the level of posterior capsule (Figure.1). Further, the UD (7 ~ 10MHz) imaging evaluated the condition of anterior and posterior segment with total cataract. There found almost strong echo from entirely lens, interruption at the level of posterior capsular, some cloddy strong echo/flocculent weak echo at the lens-vitreous interface and nearly intact posterior segment. A provisional diagnosis of ILPCR was

thus made (Figure.2). The ILPCR cases were designed to carry on phacoemulsification with 4.5–5.0 mm anterior capsular continuous curvilinear capsulorhex (CCC), anterior/posterior segment vitrectomy to clear away the dropped residual cortex and nucleus. Intraoperatively, the ruptured posterior capsule became enlarged and couldn't be retained. All cases were carried out intraocular lens implantation (IOL, Hoya 401, Japan) in the ciliary groove during Phase I or II with prepared anterior capsule supporting. All cases were observed and follow-up 3 months postoperatively.

Statistical analysis

The statistical analysis was performed by using SPSS Statistics for Windows (Version 22.0, IBM Corp, Armonk, New York). Comparison between two continuous variables was calculated with the *t*-test. *P* values of less than 0.05 were considered as statistically significant.

Results

Six cases were definitely diagnosed with ILPCR especially based on the hints of UD with the trauma history, clinical presentation, and signs of ocular anterior segment. On the basis of UD, appropriate pre-operation assessment and design were conducted. The six ILPCR patients were regularly followed-up in clinics. Their BCVA were recorded at the first- and third-month post-operation, which were all remarkably increased as compared to pre-operation. The IOLs implanted in the ciliary grooves were centered with the absence of the 4.5–5.0 mm anterior capsular in silt-lamp examination. The posterior segment was innocent. The contrast of the LogMAR BCVA between pre-operation (2.50 ± 0.55) and post-operation after 1 month (0.18 ± 0.08) or 3 months (0.13 ± 0.08) were all statistical significance, respectively. (1 month: $t = 10.617$, $P = 0.000 < 0.01$; 3 months: $t = 9.846$, $P = 0.000 < 0.01$), (Fig. 3).

Discussion

ILPCR is rare and needs to be well-recognized clinical phenomenon. It was easy to be ignored as a simple traumatic cataract case because the lens became entirely opacity with intact suspensory ligament. It was always recognized to be simple case and had no suitable surgery management. Once the broken posterior capsule was found unexpectedly during the operation, extra solutions had to re-plan or be searched for. But after analyzing the six ILPCR cases, their characteristics were outstanding. The particular clinical findings of ILPCR were loose, translucent and flocculence-like cortex near the level of posterior capsule, faster development of cataract and greater incidence happened in the young people. But the ruptures were difficult to judge only by the silt-lamp biomicroscopy examination. With the help of UD (7 ~ 10MHz), the work became easier and the landmark appeared that the posterior capsular waveforms of the lens were interrupted. And some cloddy strong echo/flocculent weak echo were captured at the lens-vitreous interface. There was definite hint which the case had sustained severe traumatic cataract with ILPCR. Thus, the following preparation must be considered. The operation design included 4.5–5.0 mm CCC, phacoemulsification, anterior/posterior segment vitrectomy of the dropped remnant with IOL implantation in the ciliary groove during Phase I or II. Just like our planning, the prognosis of all six cases were satisfactory.

The ILPCR case was opportunistic due to some reasons. It was caused by a sudden force on the eyeball, especially happened in healthy and younger people because of the special anatomical feature of the interface between lens and vitreous. This was coincident with Liu and Tabatabaei's observation [8, 9]. Specifically, in the youth, the vitreous appeared gelatinous, nearly spherical, with flat front surface. Except from the front portion, it could support the eyeball wall, absorb and redistribute external pressure, and alleviate the injury. The front surface was tightly coherent. But everything would be gradually loosened with age. Close to the lens, there was shortage of supporting and negligible buffer. Then, the lens and vitreous had different components and properties. After the sudden force on the eyeball, which was rapidly conducted along the axis of the eyeball, obvious change was observed in the interface between posterior capsule and anterior vitreous surface. Hence, the extruded strain was the same, while the resultant stress was very different. Given the external pressure concentration, the posterior capsule was stretched and fluctuated around the equator port. The thinnest position, only 4 μm, posterior polar, which was especially denied effective support by the vitreous and faced sudden tension, was susceptible to rupture. This was identified in the clinical cases, which often showed rupture around the posterior pole. Occasionally, the lens mistakenly looked tapered through the posterior capsule break, thus giving a false impression of an intact posterior capsule in most cases. Therefore, accurate diagnosis was very important for proper design and decision of the operation in order to achieve ideal results.

We first reported the use of UD (7 ~ 10MHz) to judge the appearance of ILPCR and decide on the treatment plan. According to anterior segment OCT, Scheimpflug and UBM imaging, they failed either to accomplish on a serious opaque media case or only to show the anterior segment imaging. UD conquered the shortcomings. Meanwhile, B-scan, which was commonly used in detecting the situation of traumatic cataract, supplying some information about the posterior segment, but was insufficient for precise details of interface between lens and vitreous. The probe of B-scan is fixed of 10 MHz to focus the object. The distance of B-scan is equal to the diameter of the equator. Hence, the direction of the probe had to changed drastically or the patients need to move their eyeballs in order to bring the lesion picture. Based on clinical experience, there were three requirements to obtain good quality picture in clinics: first, the lesion ultrasonogram should be in the center; next, the ultrasonogram should be vertical to the checked surface; and finally, adequate strength should be maintained and lower decibel should be applied to obtain optimal resolution images. UD had all advantages. It had full scan range around eyeball not to ask patient to match up. With variable probe frequency (3-13MHz inside eyeball), it was enough lower decibel to detect the object at remarkable axial minimum resolution (0.04-0.08mm). Besides, UD could supply better details and higher quality picture because of 256 gray-scale. So, this study had shown that UD (7 ~ 10MHz) was more appropriate than B-scan and others because of more convenient and accurate properties.

Conclusion

In above cases, ILPCR was easy to be ignored because the lens became entirely opacity with intact suspensory ligament. It was always recognized to be simple cataract and had no suitable surgery preparation. With carefully observation, the clinical findings of ILPCR were loose and flocculence-like

cortex at the level of posterior capsule, faster development of cataract and greater incidence happened in the young people. UD (7 ~ 10MHz), could be objectively recorded the characteristics of ILPCR and was very useful to discriminate the lesion from the puzzle condition. It has precise and economic benefit to illustrate the appearance of traumatic anterior and posterior segment at a time. Because that, UD could predict the ILPCR in advance and help to decide how to design operation and solve the occult problem effectively.

Abbreviations

ILPCR
The isolated lenticular posterior capsule rupture
UD
Ultrasonic doppler
BCVA
best corrected visual acuity
IOL
intraocular lens
UBM
ultrasound biomicroscopy
CCC
continuous curvilinear capsulorhex.

Declarations

Availability of data and materials

All data are available upon request from the authors.

We thank all participants who donated their samples.

Funding

This article was supported by the Bureau of Science and Technology of Hebei Province (No. 19277780D).

Author information

Affiliations

Department of Ophthalmology, BeiJing TianTan Hospital, Capital Medical University BeiJing 100070, China

YingHua Du

Department of Ophthalmology, the Second Hospital of HeBei Medical University ShiJiaZhuang, 050000, China

Ran Li & SuZhen Cai

Department of Ophthalmology, HeBei General Hospital ShiJiaZhuang, 050051, China

ZhiYang Jia & XiaoTing Ma

Contributions

YH. Du designed the study; R. Li performed the statistical analysis; YH. Du drafted the initial manuscript; SZ. Cai, ZY. Jia and XT. Ma were responsible for the data collection and analysis. The authors contributed to revision and editing of the final manuscript.

Corresponding author

Correspondence to YingHua Du.

Ethics declarations

Ethics approval and consent to participate

This research activities were approved by the Medical Research Ethics Committee and Institutional Review Board of HeBei General Hospital. Each participant needed to provide a written informed consent before participating in study procedures.

Consent for publication

Not applicable.

Competing interests

The authors declare that they have no competing interests.

Additional information

Publisher's Note

Springer Nature remains neutral with regard to jurisdictional claims in published maps and institutional affiliations.

References

1. Mangan MS, Atalay E. Isolated Anterior Lens Capsule Rupture Secondary to Blunt Trauma: Pathophysiology and Treatment. Turk J Ophthalmol. 2016;46(1):7–10.

2. Vajpayee RB1, Angra SK, Honavar SG, et al. Pre-existing posterior capsule breaks from perforating ocular injuries. J Cataract Refract Surg. 1994;20:291–4.
3. Por YM, Chee SP. Implantation of foldable intraocular lens with anterior optic capture in isolated posterior capsule break. J Cataract Refract Surg. 2006;32:707–8.
4. Shen M, Wang MR, Yuan Y, et al. SD-OCT with prolonged scan depth for imaging the anterior segment of the eye. Ophthalmic Surg Lasers Imaging. 2010;41(suppl):65–9.
5. Grewal DSR, Jain GS, Brar, et al. Posterior capsule rupture following closed globe injury: Scheimpflug imaging, pathogenesis, and management. Eur J Ophthalmol. 2008;18(3):453–5.
6. Coleman DJ, Silverman RH, Chabi A, et al. High-resolution ultrasonic imaging of the posterior segment. Ophthalmology. 2004;111:1344–51.
7. Kucukevcilioglu M, Hurmeric V, Ceylan OM. Preoperative detection of posterior capsule break with ultrasound biomicroscopy in traumatic cataract. J Cataract Refract Surg. 2013;39:289–91.
8. Liu X, Wang L, Du C, et al. Mechanism of lens capsular rupture following blunt trauma: a finite element study. Comput Methods Biomech Biomed Engin. 2015;18(8):914–21.
9. TabatabaeiA1. Hasanlou N, Kheirkhah A1et al. Accuracy of 3 imaging modalities for evaluation of the posterior lens capsule in traumatic cataract. J Cataract Refract Surg. 2014;40(7):1092-96.

Figures

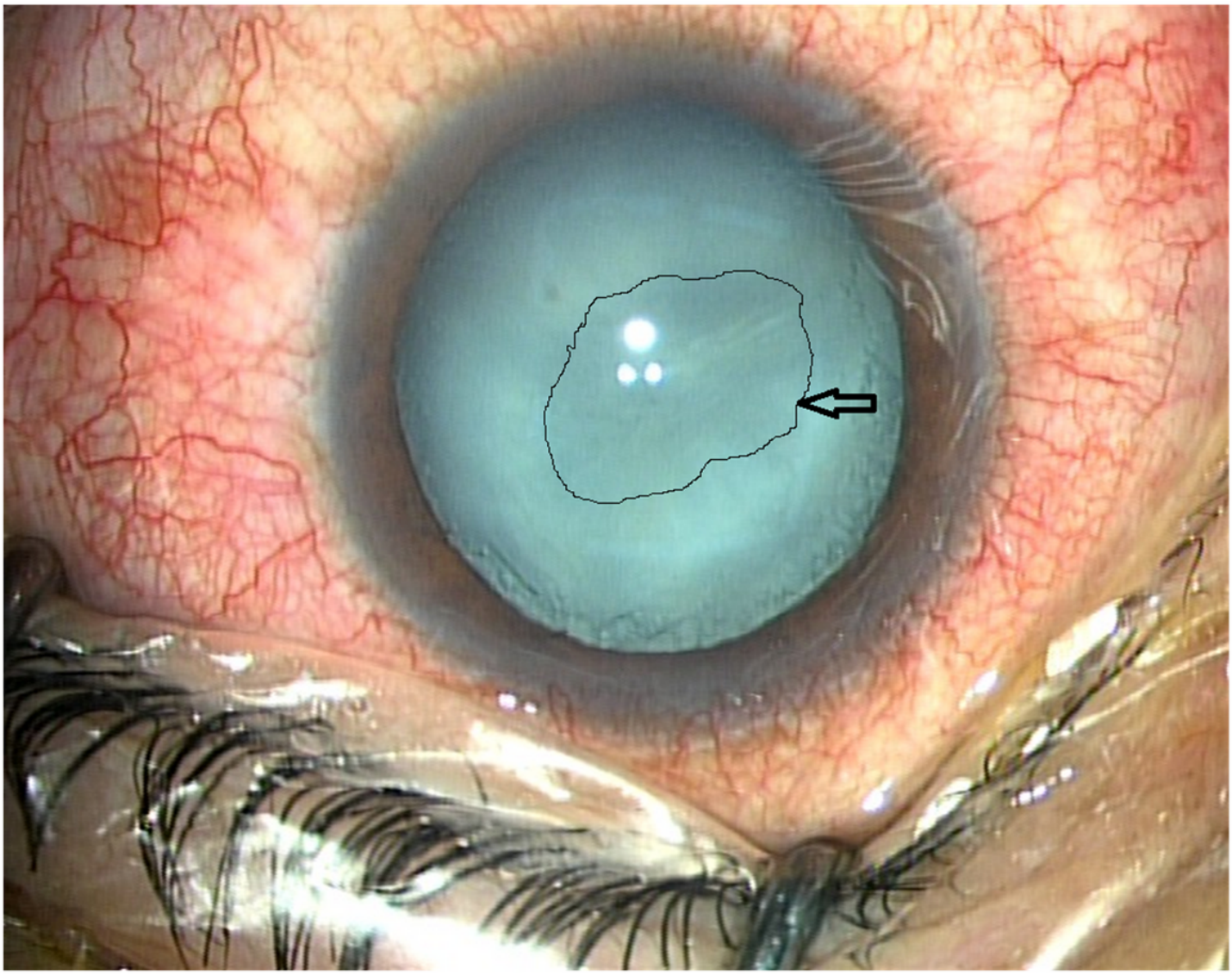

Figure 1

The pre-operation anterior segment picture displayed the completely white, loose and flocculence-like cortex with partly fluidity at the level of posterior capsule (black arrow) on view of diffuse slit-lamp illumination.

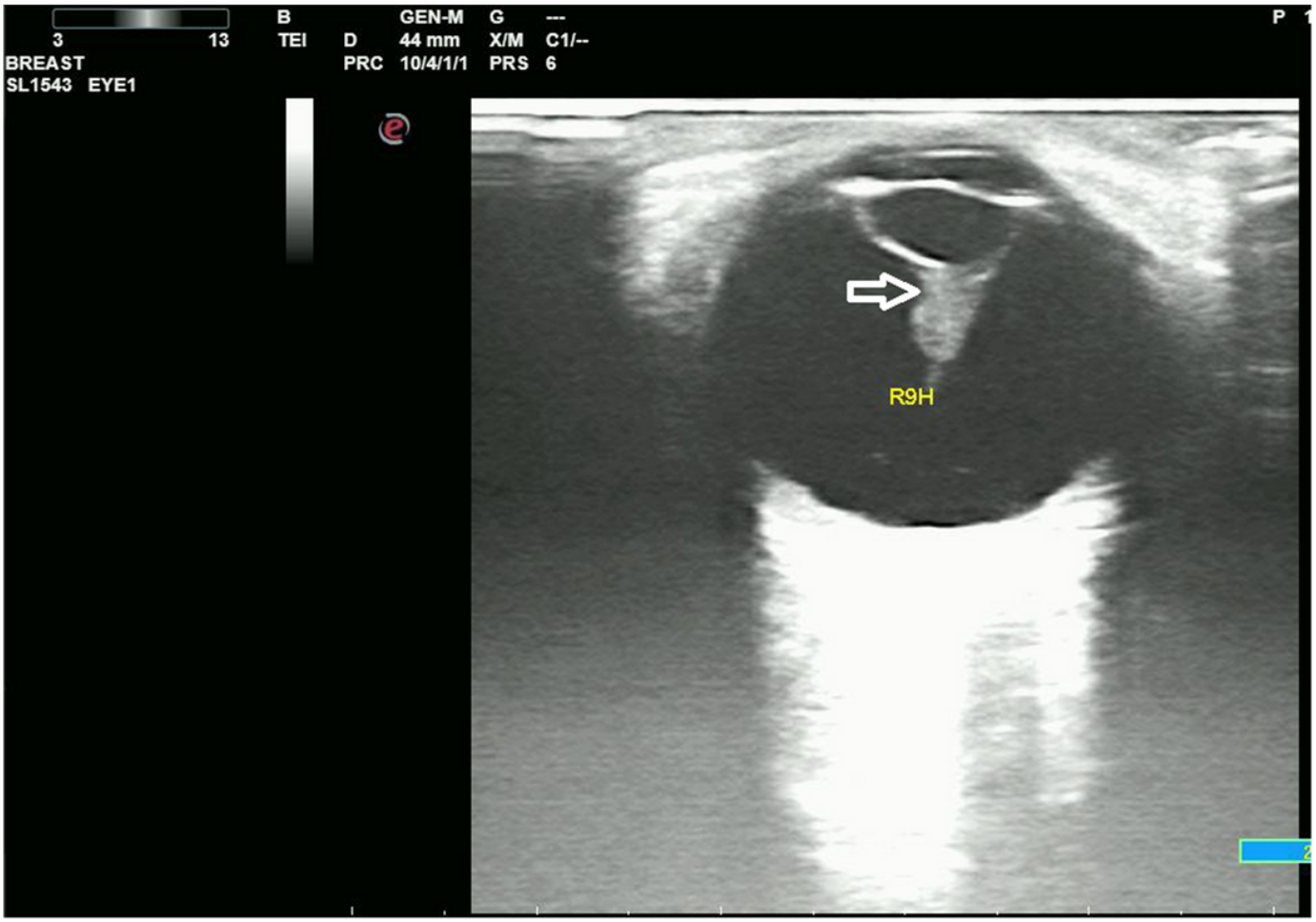

Figure 2

The pre-operation UD (7~10MHz) imaging displayed clearly the condition of anterior and posterior segment with total cataract. There found almost strong echo from entirely lens, interruption at the level of posterior capsular, some cloddy strong echo/flocculent weak echo at the lens-vitreous interface (black arrow) and nearly intact posterior segment.

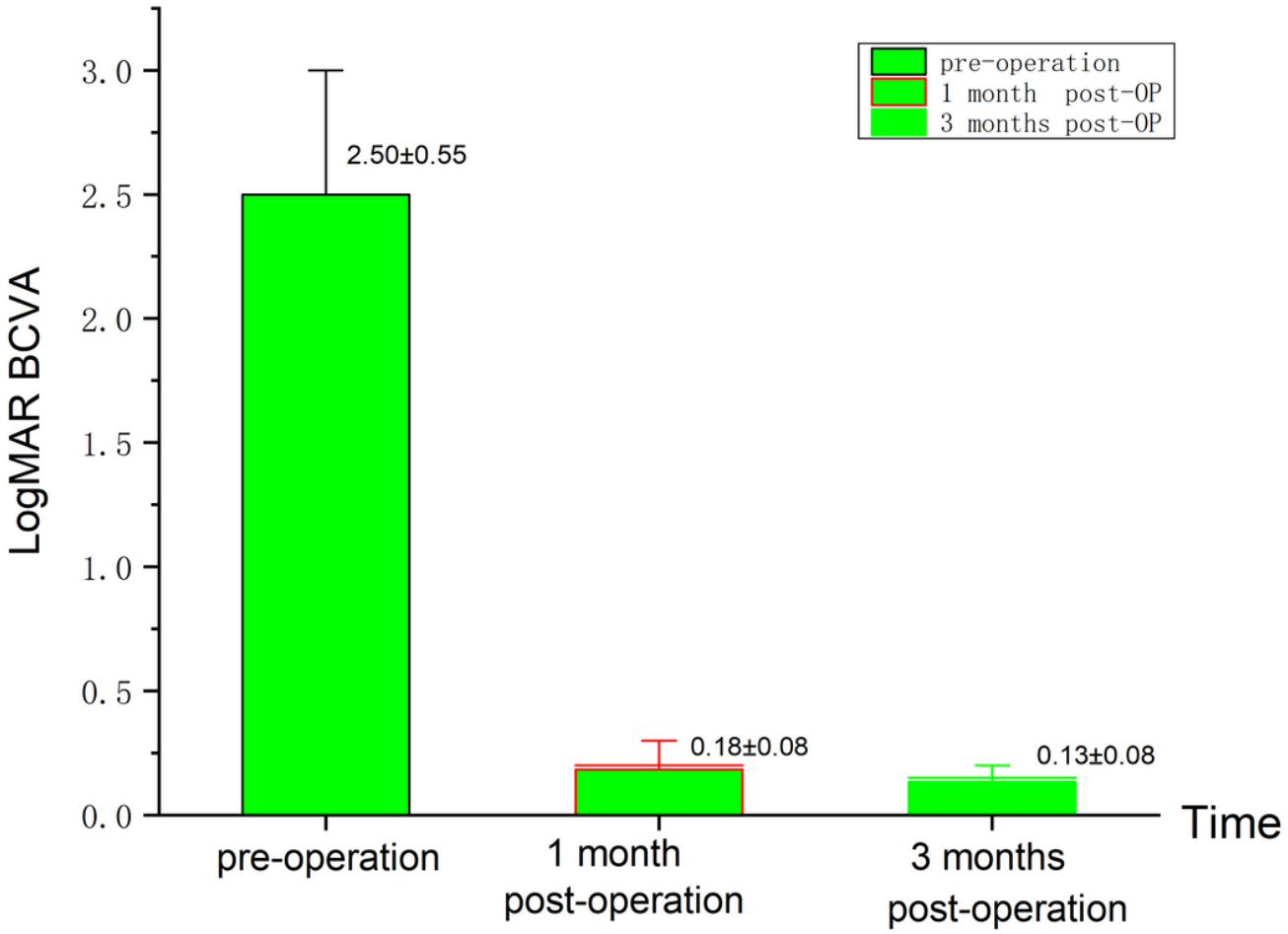

Figure 3

The contrast of the BCVA (Log Mar) between pre-operation and post-operation after 1 month. (t=10.617 P=0.000<0.01); and after 3 months (t=9.846 P=0.000<0.01) respectively. (t-test).