Safety and Clinical Efficacy of Double Posterolateral Coaxial Portals for Endoscopic Management of Posterior Ankle Impingement Syndrome

Cheng-song Yuan
Department of Orthopaedic Surgery, Southwest Hospital, The Army Military Medical University

Kang-lai Tang (tangkanglai@hotmail.com)
Department of Orthopaedic Surgery, Southwest Hospital, The Army Military Medical University

Yao Tang
Department of Orthopaedic Surgery, Southwest Hospital, The Army Military Medical University

Tao-tao liang
Department of Orthopaedic Surgery, Southwest Hospital, The Army Military Medical University

Lin Ma
Department of Orthopaedic Surgery, Southwest Hospital, The Army Military Medical University

Yong-hua Chen
Department of Orthopaedic Surgery, Southwest Hospital, The Army Military Medical University

Xu-Ting Bian
Department of Orthopaedic Surgery, Southwest Hospital, The Army Military Medical University

Cao Hu
Department of Orthopaedic Surgery, Southwest Hospital, The Army Military Medical University

Xuan Zhang
Department of Orthopaedic Surgery, Southwest Hospital, The Army Military Medical University

10. Jun-peng Liu
Department of Orthopaedic Surgery, Southwest Hospital, The Army Military Medical University

Li Wang
Department of Orthopaedic Surgery, Southwest Hospital, The Army Military Medical University

Mi-Duo Mu
Department of Orthopaedic Surgery, Southwest Hospital, The Army Military Medical University

---

Research Article

Keywords: Posterolateral Coaxial Portals, Endoscopic Management, Posterior Ankle Impingement

Posted Date: January 14th, 2021

DOI: https://doi.org/10.21203/rs.3.rs-135722/v1

Abstract

Double Posterolateral Coaxial Portals has been designed by us for Endoscopic Management of Posterior Ankle Impingement. This study's purpose was analyzed the safety and clinical efficacy of this new designed portals. Six fresh foot samples were randomly selected. The distances of two posterolateral portals to sural nerve in the neutral, dorsiflexion and plantar flexion positions were measured to evaluate the safety. The clinical efficacy of the operative approach for endoscopic management of posterior ankle impingement syndrome was prospectively analyzed, and its effectiveness and complications were evaluated. In 6 samples, the mean distances of the first and second portals to sural nerve were 2.26 ± 0.22 cm and 1.59 ± 0.12 cm in the neutral position,2.21 ± 0.21 cm and 1.55 ± 0.12 cm in the dorsiflexion 30°position, and 2.46 ± 0.29 cm and 1.73 ± 0.19 cm in the plantar flexion 30°position; thus, two portals had a big safety distance to sural nerve. Totally 38 patients received the endoscopic treatment of posterior ankle impingement syndrome with double posterolateral coaxial portals from January 2012 to December 2017. Such operative approach provided a full field of subtalar joint and posterior ankle during operation. The mean follow-up time was 28.2 (range, 24–72) months, the satisfaction rate was 94.7%; none of patients experienced complications; VAS score was decreased to 0.50 at the last visit from 5.82 before operation ($P < .001$), while AOFAS score was increased to 92.34 from 71.68, and the differences were both statistically significant ($P < .001$); the excellent/good rate was 97.3%. In treating posterior ankle impingement syndrome, double posterolateral coaxial portals have such advantages of good safety, miniature nerve injury, a good field of posterior ankle and subtalar joint, good clinical efficacy, and few complications, thus they are an operative approach which is reliable, effective, safe and worthy of being popularized.

Background

Posterior ankle impingement syndrome is defined as posterior ankle pain caused by repeated excessive plantar flexion or sudden acute plantar flexion of ankle, and it is mostly seen in ballet dancers, soccer and volleyball players.[1] The abnormal factors for impingement include soft tissue and bone abnormalities.[2] There are two types of treatment for posterior ankle impingement syndrome: conservative treatment and operative treatment. Conservative treatment includes taking a good rest, ice compress, oral administration of non-steroidal anti-inflammatory drugs (NSAIDs) and intra-articular injection of hyaluronate sodium.[3] Operative treatment includes open surgery and arthroscopic surgery. Open surgery has some shortcomings, e.g., exposure difficulty, big trauma, and easy injury to blood vessels and nerves.[4] Therefore, endoscopic surgery becomes a fashion and trend, and the reasonable selection of portals is important for operative operation and efficacy. The current arthroscopic portals include: 1) bilateral paratendinal portal, with such disadvantages as a demand for changing the body position during operation if requiring the treatment of anterior ankle lesions and a observation blind area of posterior ankle[5]; 2) lateral portal, with a defect of easy injury to sural nerve; 3) medial portal, with a defect of easy injury to tarsal tunnel[6]; 4) anterior portal, with some defects, e.g., operation difficulty, requiring full traction, and failure to observe subtalar joint synchronously[7]; 5) bilateral coaxial portal, with a defect of

easy injury to tarsal tunnel.[8] An operative approach is urgently needed which causes little injury to nerves and blood vessels, provides a good intraoperative field, and can manage anterior and posterior lesions. Therefore, we designed double posterolateral coaxial portals based on the considerations of avoiding peroneus longus tendon, peroneus brevis tendon and lateral collateral ligament, fully protecting sural nerve, full exposure and a clear field of posterior subtalar joint and posterior ankle articular cavity. In this study, we validated the safety of the designed portals using foot samples, and then by prospective investigation. In this study, we intend to verify the safety of this approach through foot specimen study. On this basis, we will further analyze the clinical efficacy of this approach in the treatment of posterior malleolus impingement syndrome through a prospective study.

Materials And Methods

1. Anatomic measurement

Six fresh frozen cadaver samples were selected, there were 4 males and 2 females. The first and second portals were established according to the operative operation methods and steps. Then, the trocar was dwelled in the joint, and two Kirschner wires were inserted along the direction of trocar and fixed, the diameters of the trocar and Kirschner wires is 1.5mm and 1.0mm. After the withdrawal of trocar, the samples were dissected to expose sural nerve. The distances of two Kirschner wires to sural nerve were measured with the precision of 0.01cm in the dorsiflexion 30°, neutral and plantar flexion 30° position of ankle, respectively (Fig. 1).

2. Clinical data

2.1 Study objects

Before operation, all patients received X-ray, CT and MRI examinations and completed AOFAS scoring, VAS scoring and routine admission assessment.The inclusion criteria were as follows: 1) severe posterior ankle impingement syndrome, i.e., posterior ankle pain, aggravated at plantar flexion, influencing the daily life; 2) failure of conservative treatment for ≥ 6 months, including drugs, local block, and physical rehabilitation. The exclusion criteria were described below: 1) severe medical diseases and 2) serious infection.

From January 2012 to December 2017, totally 38 patients with posterior ankle impingement syndrome received endoscopic management by double posterolateral coaxial portals after a failure of conservative treatment. The preoperative course of disease was 32 (range, 6-360) months, and the average age of patients was 36.4 (range, 18-62) years.

2.2 Ethical approval

This experiment is to study the "Safety and Clinical Efficacy of Double Posterolateral Coaxial Portals for Endoscopic Management of Posterior Ankle Impingement Syndrome". The study was permitted by the Ethics Committee of the Southwest Hospital Affiliated with the Third Military Medical University after enough discussion. The private disease information and imaging information of clinical patients, and the measurement of relevant foot specimen data have passed the informed consent of patients and their families. The experimental research team will strictly follow the principles of Helsinki Declaration and the international code of ethics for biomedical research involving human beings jointly formulated by the World Health Organization and the Council of international medical science organizations to ensure that the medical records (research medical records / X-ray imaging pictures, etc.) of the subjects will be completely preserved, and any public report on the research results will disclose the individual identity of the patients. We will make every effort to protect the privacy of the subjects' personal medical data, disease information, life information and genetic information within the scope permitted by law.

2.3 Operative methods

After satisfactory anesthetization, the patients were kept in a side-lying position, and then the routine disinfection and draping were finished. The first portal was established using the tourniquet with an inflation pressure of 270mmHg, and the specific procedures were as follows: a 3-4mm skin incision was made at the inferior border of apex capitis fibulae anterior to calcaneus fibular ligament(Fig. 2), and then the tissues were bluntly dissected with artery forceps avoiding the injury to tendons and cutaneous nerve; the blunt tip was flattened against the fibular border and then slid forward or backward and broken through the articular capsule after exploring calcaneofibular ligament; posterior ankle and posterior subtalar joint were explored by 30° arthroscopy. The second portal was established under arthroscope, and the procedures were below: a parallel line to planta pedis was marked at lateral ankle, and then a 3-4mm skin incision was made at 5-10mm beside lateral achilles tendon on the intersection of the parallel line and lateral achilles tendon and dilated with artery forceps; thereafter, the blunt tip was punctured vertically in the skin, and the trocar was inserted to establish the second portal. Two portals could be alternatively used as observation and operation portals. The lesion tissues were removed with planer, grinding drill, flat-nose pliers and blue pliers, a negative pressure drainage tube was dwelled in the wound after hemostasis by plasma radio-frequency ablation or the complete removal of lesions was confirmed by C-arm X-ray system for bony impingement, and then the wound was sutured layer by layer.

2.4 Preoperative and postoperative function follow-up

At 3month and the last visit after operation, the function assessment and satisfaction evaluation were performed using VAS pain scoring and AOFAS hindfoot function scoring. The ankle-hindfoot function scoring results were assessed as below: 90-100 scores, excellent; 72-89 scores, good; 41-71 scores, medium; 1-40 scores, poor. The excellent and good results were satisfactory, while the medium and poor

results were unsatisfactory. At 1d after operation, the complete removal of bony impingement was confirmed by X-ray examination; the postoperative complications were observed.

2.5 Statistical analysis

The measurement data were presented as $\bar{x} \pm s$. SPSS13.0 statistical software was used. The AOFAS score and VAS score before and after operation were analyzed by pair-wise t test. $P<.05$ suggested that a difference was statistically significant.

Results

Safety analysis

Two portals both had a safety distance to sural nerve and thus exhibited a low risk of injury to sural nerve in the neutral, dorsiflexion 30°and plantar flexion 30° positions for 6 samples. Generally, we think that the safe distance between the approach and the nerve is 5mm. In our tests, the maximum minimum and mean distances of two portals to sural nerve are More than 1.0cm in the neutral, dorsiflexion 30°and plantar flexion 30°positions. therefore, the Two portals are a big safety distance to sural nerve (Table1).

Table 1

the maximum and minimum distances of the first and second portals to sural nerve [a]

Neutral position				Dorsiflexion position			Plantar flexion position		
	A	B	C	A	B	C	A	B	C
1st portal (cm)	1.86	2.47	2.26±0.22	1.76	2.42	2.21±0.21	1.96	2.82	2.46±0.29
2nd portal (cm)	1.45	1.81	1.59±0.12	1.41	1.76	1.55±0.12	1.48	2.05	1.73±0.19

[a] A is minimum distances of two portals to sural nerve, B is maximum distances of two portals to sural nerve, C is mean distances of two portals to sural nerve, the unit of the distances is cm.

Effectiveness analysis

During operation, the whole field of posterior ankle was clearly observed, including medial flexor hallucis longus tendon and posterior talar bursa; when the ankle was under dorsiflexion, posterior talar apex was fully observed. With these portals, the whole field of posterior subtalar joint was obtained, and the

arthroscopic lens and operating devices could be deepened to medial subtalar joint for observation and operation (Fig. 3).

since January 2012, 38 patients were effectively followed up, including 22 males and 16 females, 20 cases of right ankle and 18 cases of left ankle. the average age of patients was 36.4 (range, 18-62) years. The mean follow-up time was 28.2 (range, 24-72) months. Thirty-six patients achieved satisfactory efficacy, with a satisfaction rate of 94.7%; two patient experienced residual walking pain postoperatively for traumatic subtalar arthritis, thus the efficacy was just acceptable. After operation, X-ray examination showed that all bony impingements were completely removed (Fig. 4).

VSA score was decreased to 0.51±0.44 after operation from 5.68±1.61 before operation, AOFAS score was increased to 92.34±5.30 from 71.68±6.10, and the differences were both statistically significant (P<.05). The excellent/good rate was 97.3%. None of the 38 patients developed complications.

Discussion

Posterior ankle impingement syndrome is a common clinical disease, which is caused by repeated subclinical trauma due to overuse.[9] Impingement pain localized at the posterolateral aspect of the ankle behind the peroneal tendon is the main symptom.[10] The abnormal factors for impingement include soft tissue and bone abnormalities: soft tissue abnormalities are posterior ankle soft tissue edema, posterior ankle bursa hyperplasia, posterior capsular hypertrophy, flexor hallucis longus tendinitis, posterior ankle ligament hypertrophy, and so on; bone abnormalities are posterior talar protuberance, os trigonum, posterior talar tubercle fracture, Tibialis posterior protuberance, calcification free body, Haglund's deformity, etc[11].

Nonoperative measures may yield good results in some patients without osseous pathology, but if there is a symptomatic osseous impingement, operative intervention has to be required in most cases. Traditional operative treatment through an open approach may achieve good clinical outcomes. Coetzee et al followed the clinical outcomes of the open approach for posterior impingement in 37 dancers and athletes for 46.1 months. They reported an initial slow return to full activity with 46% good to excellent results at 3 months that improved to 96% at 1 year. a low complication rate with 3 transient sural nerve injuries and 1 case of complex regional pain syndrome was reported in their study[12]. More recently posterior ankle arthroscopy has been employed. Comparing with traditional open operation, Endoscopic management has the advantages of less trauma, faster recovery, and lower morbidity, and provides good/excellent results at 2-5 years follow-up in 80% of patients.[4] Therefore, endoscopic surgery becomes a fashion and trend, but the correct selection of operative approaches plays a key role in clearly exposing posterior ankle, effectively protecting nerves and blood vessels, and reducing complications[13]. As the blood vessels and nerves in medial ankle have a complex structure, posteromedial ankle portal for arthroscopy will greatly injure medial blood vessels and nerves when being established medially.[6] Bilateral coaxial portal supports the entry into the articular cavity in back of Tibialis posterior muscle tendon[8], but only provides a limited space for operative operation due to the obstruction of the above

tendon yet which reduces the risk of vascular and nerve injury. Medial portal designed by Sim[14] and Allegra[15] offers a certain safe space, but enables the limited observation of subtalar joint. Double paratendinal portals designed by Van Dijk are a classic approach for posterior ankle arthroscopy, and its safety has been investigated in many studies.[16] Therefore, this operative approach is recognized by numerous investigators and widely applied in endoscopic posterior ankle surgery, but it only supports the limited observartion of posterior subtalar joint. Due to the anatomic obstrucation of calcaneus and talus, such double portals only enable the observation of partial posterior subtalar joint, require a change of body position during operation to manage anterior ankle lesions, and have an observation blind area of posterior ankle[5]. Based on the disadvantages of the above portals, we designed double posterolateral coaxial portals with the considerations of minature injury to nervers and blood vessles, a good intraoperative field, managing anteiror and posterior ankle lesions, avoiding peroneus longus tendon, peroneus brevis tendon and lateral collateral ligament, fully protecting sural nerve, full exposure and a clear field of posterior subtalar joint and posterior ankle articular cavity. Sitler et al[17] evaluated the safety of paratendinal portal for posterior ankle arthroscopy against small saphenous vein and proved that this portal had a certain safety distance to small saphenous vein. Therefore, we only measured the distances of double posterolateral coaxial portals to sural nerve to evaluate the safety against nerves; as shown by measurement, there was a certain safety distance between these portals and sural nerve. Our portals pass through upper edge of peroneus longus tendon, and the tendon can prevent sural nerve and small saphenous vein from the injury by operative operations as natural marker, thus these portals exhibit good safety against lateral blood vessles and nerves; besides, they provide a big space for safe operation because of no direct contact with lateral and medial ankle nerves and vascular bundles, and enable the effective observation of flexor pollicis longus muscle tendon as a warning marker of operation under endoscope to prevent the injury caused by the deep entry of operative instruments. We proved in the clinical application that none of patients using our designed portals experienced medial vascular and nerve injury. Furthermore, we chose a side-lying position. This position faciliates the arthroscopic operations of ankle and hindfoot, and can provide a good field and operating space of hindfoot and ankle, and enable the direct removal of anterior ankle lesions by the lateral rotation of lower limbs under the help of an assitant as necessary, without a change of body position during operation.

Guo et al compared open and arthroscopic os trigonum excision in 41 patients (16 open and 25 arthroscopic). Two operative groups showed similar clinical results that there was no significant difference in American Orthopaedic Foot and Ankle Society (AOFAS) and visual analog scale scores. However, the arthroscopic group returned to activity almost 6 weeks earlier than the open group (6 vs 11.9 weeks).[18] The similar results were found in study by Noguchi et al, who reported on the arthroscopic excision of an os trigonum in 12 soccer players. The average return to sports was 5.9 weeks with a 8.3% (one of 12) incidence of complications. They concluded arthroscopic treatment of posterior ankle impingement syndrome was recommended for athletes who wish to return to play earlier .[19]

Nickisch et al compared favorably to the Abramowitz et al, who reported a 20% (8 out of 41 cases) sural nerve neuropraxia incidence in the open treatment of posterior ankle impingement.[20] Ribbans et al

compared open and arthroscopic debridement. In their review paper, the incidences of nerve injury and wound complication in open cases were 4.2% and 2.8% compared to 3.7% and 0.96% in arthroscopic cases respectively.[13] Nickisch et al detailed the postoperative complications of posterior ankle and hindfoot arthroscopy in a retrospective study of 189 subjects. A total of 16 cases of complications were observed (7 cases of nerve, 2 cases of infection, 4 cases of Achilles tendon tightness, 1 case of portal cyst, 2 cases of complex regional pain syndrome). Five of the 7 patients (3.7% of the nerve injury rate) were completely resolved. The results showed posterior ankle and hindfoot arthroscopy was a safe procedure to diagnose and treat many intra-articular and extra-articular ankle disorders, which was consistent with our study. However, within their cohort of 189 subjects, 46 and 20 cases of subtalar and ankle arthritis, respectively, were treated. This is atypical in comparison to most other studies reporting outcomes and complications of operative treatment of PAIS.[21]

As proven by clinical efficacy, the improvement of symptoms was satisfactory during the follow-up of 38 patients with posterior ankle impingement syndrome who received endoscopic treatment by double posterolateral coaxial portals, but there was no case of injury to nerves, blood vessels and peroneus longus tendon, peroneus brevis tendon.

In summary, in treating posterior ankle impingement syndrome, double posterolateral coaxial portals have such advantages of good safety, miniature nerve injury, a good field of posterior ankle and subtalar joint, good clinical efficacy, and few complications, thus they are an operative approach which is reliable, effective, safe and worthy of being popularized.

Declarations

Acknowledgments

We acknowledge the assistance of investigators and all subjects for participation in this study.

Authors’ contributions

All operative procedures were carried out by K.L. Tang* and C.S. Yuan in this study. The Data measurement of cadaver specimens was performed by L. Ma and H.Y. Chen. X.T. Bian , M.D. Mu and C. Hu participated in the patient selection, investigation on the outpatient clinic and radiographic assessments, literature search, and data monitoring. Y. Tang*, T.T. Liang* and X. Zhang completed the statistical analysis and manuscript writing. All authors have read and approved the final manuscript.

Competing interests

All authors declare no competing interests.

Additional information

Supplementary Information:

The online version contains supplementary material available at https://doi. org/10.1038/s41598-020-79098-0.This study was supported by the Science Foundation of Southwest Hospital and Science and health joint technology innovation and application development project of Chongqing Health Committee (NO. 2020MSXM012) and Chongqing Science and Technology Bureau in 2020(NO. cstc2019jsyj-yzysbA0001).

Correspondence and requests

for materials should be addressed to T.K.L OR T.Y

Reprints and permissions information

Publisher's note

Open Access

References

1. Ogut, T., Ayhan, E., Irgit, K. & Sarikaya, A. I. Endoscopic treatment of posterior ankle pain. *Knee Surg Sports Traumatol Arthrosc* **19**, 1355-1361, (2011).

2. Russell, J. A., Kruse, D. W., Koutedakis, Y., McEwan, I. M. & Wyon, M. A. Pathoanatomy of posterior ankle impingement in ballet dancers. *Clin Anat* **23**, 613-621, (2010).
3. Roche, A. J., Calder, J. D. & Lloyd Williams, R. Posterior ankle impingement in dancers and athletes. *Foot Ankle Clin* **18**, 301-318, (2013).
4. Milos, R. I., Fritz, L. B. & Schueller-Weidekamm, C. [Impingement syndrome of the ankle]. *Radiologe* **57**, 309-326, (2017).
5. van Dijk, C. N., Scholten, P. E. & Krips, R. A 2-portal endoscopic approach for diagnosis and treatment of posterior ankle pathology. *Arthroscopy* **16**, 871-876, (2000).
6. Heck, J., Mendicino, R. W., Stasko, P., Shadrick, D. & Catanzariti, A. R. An anatomic safe zone for posterior ankle arthroscopy: a cadaver study. *J Foot Ankle Surg* **51**, 753-756, (2012).
7. Vilá, J., Vega, J., Mellado, M., Ramazzini, R. & Golanó, P. Hindfoot endoscopy for the treatment of posterior ankle impingement syndrome: a safe and reproducible technique. *Foot Ankle Surg* **20**, 174-179, (2014).
8. Wang, L. *et al.* Modified posterior portals for hindfoot arthroscopy. *Arthroscopy* **23**, 1116-1123, (2007).
9. Giannini, S., Buda, R., Mosca, M., Parma, A. & Di Caprio, F. Posterior ankle impingement. *Foot Ankle Int* **34**, 459-465, (2013).
10. Kudaş, S. *et al.* Posterior ankle impingement syndrome in football players: Case series of 26 elite athletes. *Acta Orthop Traumatol Turc* **50**, 649-654, (2016).
11. Hess, G. W. Ankle impingement syndromes: a review of etiology and related implications. *Foot Ankle Spec* **4**, 290-297, (2011).
12. Coetzee, J. C., Seybold, J. D., Moser, B. R. & Stone, R. M. Management of Posterior Impingement in the Ankle in Athletes and Dancers. *Foot Ankle Int* **36**, 988-994, (2015).
13. Ribbans, W. J., Ribbans, H. A., Cruickshank, J. A. & Wood, E. V. The management of posterior ankle impingement syndrome in sport: a review. *Foot Ankle Surg* **21**, 1-10, (2015).
14. Sim, J. A., Lee, B. K. & Kwak, J. H. New posteromedial portal for ankle arthroscopy. *Arthroscopy* **22**, 799.e791-792, (2006).
15. Allegra, F. & Maffulli, N. Double posteromedial portals for posterior ankle arthroscopy in supine position. *Clin Orthop Relat Res* **468**, 996-1001, (2010).
16. Tryfonidis, M. *et al.* Posterior ankle arthroscopy portal safety regarding proximity to the tibial and sural nerves. *Acta Orthop Belg* **74**, 370-373, (2008).
17. Sitler, D. F., Amendola, A., Bailey, C. S., Thain, L. M. & Spouge, A. Posterior ankle arthroscopy: an anatomic study. *J Bone Joint Surg Am* **84**, 763-769, (2002).
18. Guo, Q. W., Hu, Y. L., Jiao, C., Ao, Y. F. & Tian, D. X. Open versus endoscopic excision of a symptomatic os trigonum: a comparative study of 41 cases. *Arthroscopy* **26**, 384-390, (2010).
19. Noguchi, H. *et al.* Arthroscopic excision of posterior ankle bony impingement for early return to the field: short-term results. *Foot Ankle Int* **31**, 398-403, (2010).

20. Abramowitz, Y. *et al.* Outcome of resection of a symptomatic os trigonum. *J Bone Joint Surg Am* **85**, 1051-1057, (2003).
21. Nickisch, F. *et al.* Postoperative complications of posterior ankle and hindfoot arthroscopy. *J Bone Joint Surg Am* **94**, 439-946, (2012).

Figures

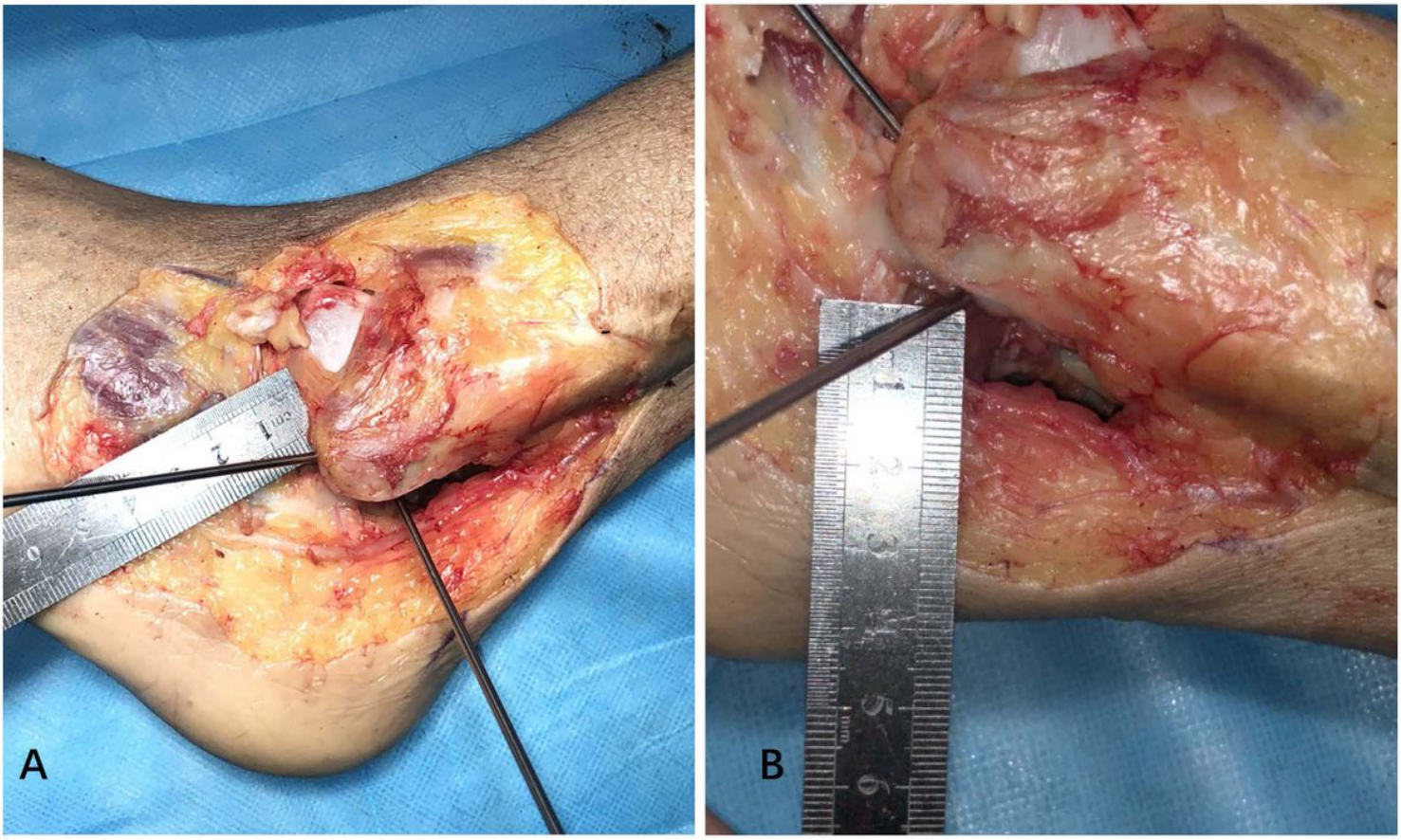

Figure 1

A. Distance of the first portal to sural nerve. B. Distance of the second portal to sural nerve.

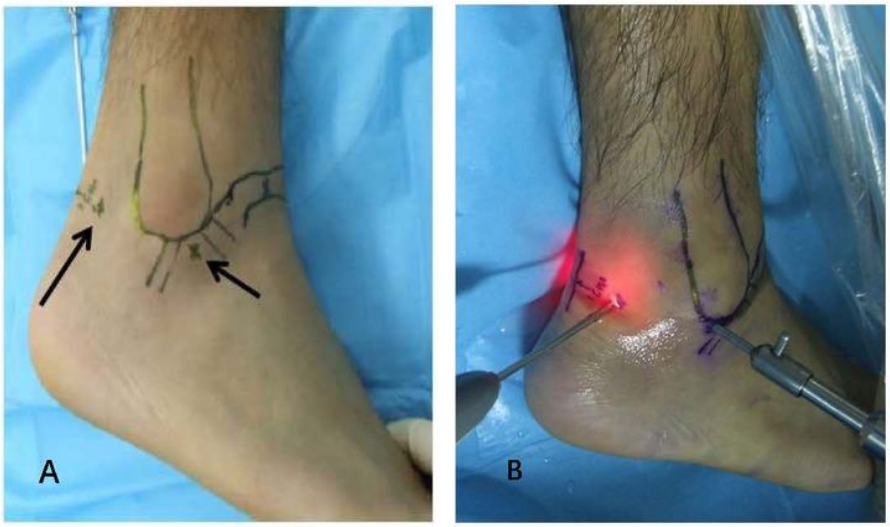

Figure 2

Double posterolateral coaxial portals.

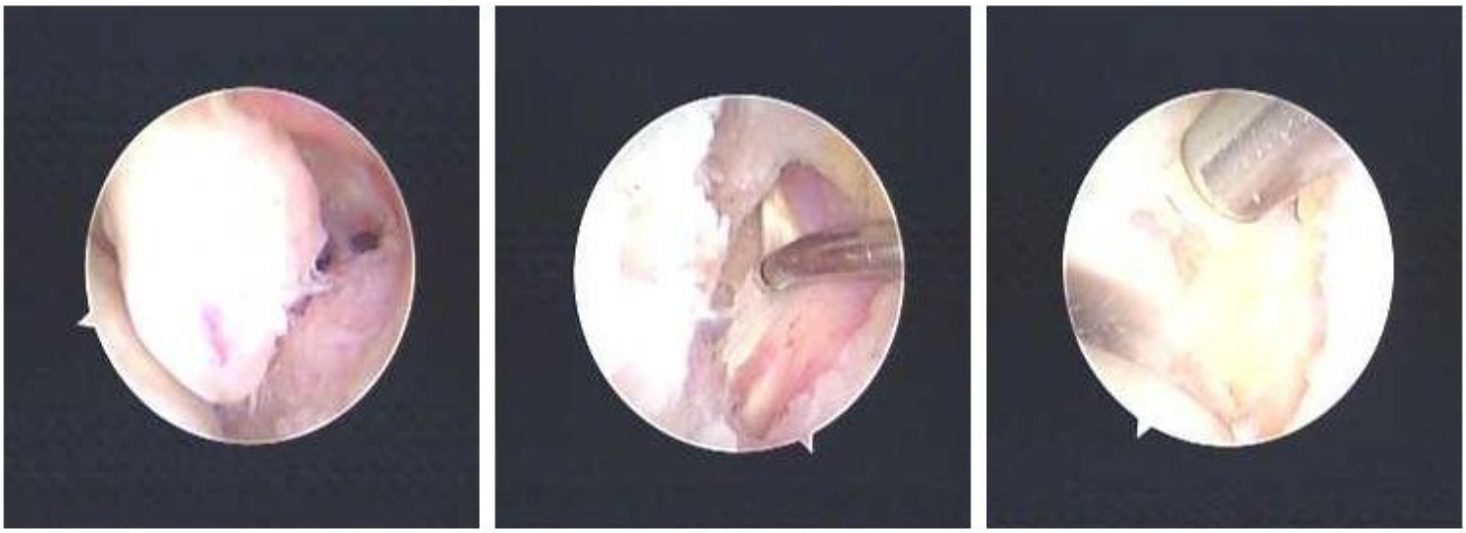

Figure 3

Intraoperative field of double posterolateral coaxial portals.

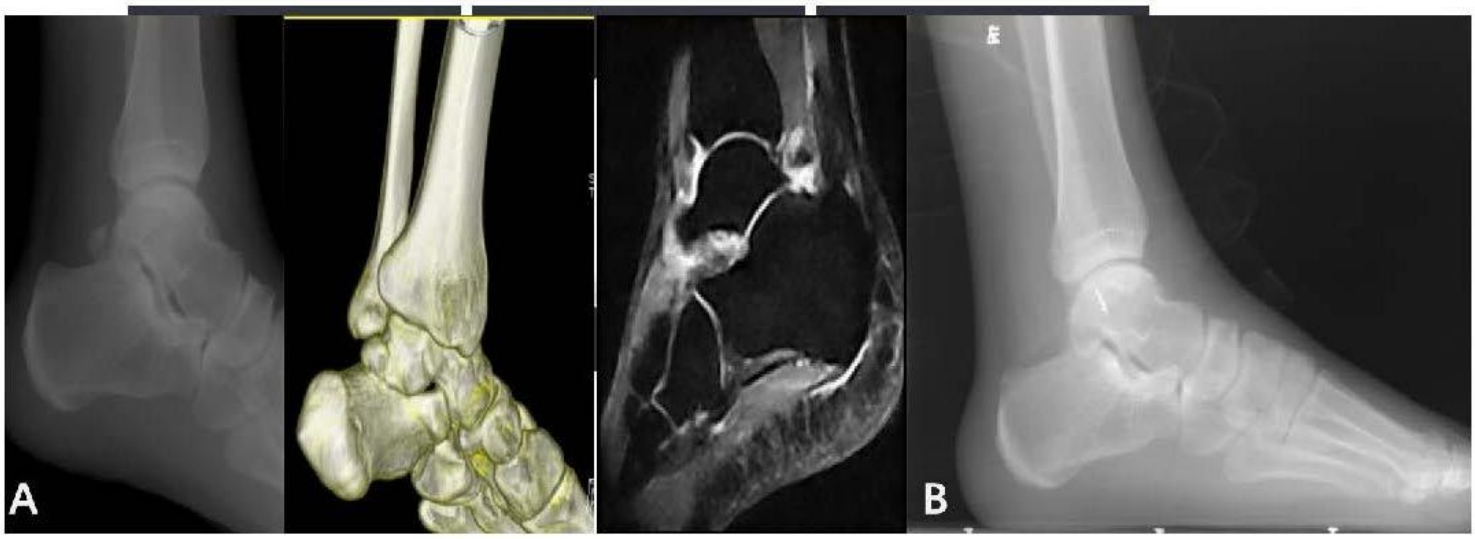

Figure 4

This was a typical case: A. Pre-operation X-ray CT and MRI examination showed that the patient was suffered posterior ankle impingement syndrome. B. After operation, X-ray examination showed that all bony impingements were completely removed.