The Effect of Pre-Incision Urethral Plate Width and Glanular Width on the Outcome of Tubularized Incised Urethral Plate Repair Surgery in Distal Penile Hypospadias, A Prospective Study

Tarek Abdelbaky
Kafrelsheikh University

Diaa El-din Taha (drdiaaeldin@gmail.com)
Kafrelsheikh University

Hossam Nabeeh
Kafrelsheikh University

Khaled Zein elabden
Kafrelsheikh University

Mohamed Galal
Kafrelsheikh University

Research Article

Keywords: Hypospadias, urethral plate, tubularized incised plate repair (TIP), hypospadias objective penile evaluation [HOPE].

Posted Date: January 28th, 2021

DOI: https://doi.org/10.21203/rs.3.rs-136050/v1

Title:

The effect of pre-incision urethral plate width and glanular width on the outcome of Tubularized Incised Urethral plate repair surgery in distal penile Hypospadias, A prospective study

Authors:

Mohamed Galal[1], Diaa-Eldin Taha[1], Khaled Zein elabden[1], Hossam Nabeeh[1], Tarek Abdelbaky[1].

Institutes:

[1] Urology department, Kafer Elsheikh University, Egypt

Corresponding author:

Diaa Eldin Taha

Lecturer of urology, Department of Urology

Faculty of medicine, 4 elgesh street Kafrelsheikh University, Kafrelsheikh, Egypt.

E-mail address: drdiaaeldin@gmail.com,

drdiaaeldin@med.kfs.edu.eg

Telephone: 0201008531384 – 0201205222323

Postal code: - 35511

Abstract

Background:

To determine the outcomes of hypospadias repair according to the width of the urethral plate & glanular width.

Materials and methods

A prospective evaluation of patients operated for hypospadias. The urethral plate width (UPW) & glans width (GW) of the patients were measured preoperatively using standard calipers. The urethral plate width was correlated to the cosmetic outcome (using hypospadias objective penile evaluation [HOPE]) and functional outcome (using the urinary stream) of repair.

All patients were managed via the same technique using Snodgrass tubularized incised plate repair (TIP). All intraoperative data were recorded. All patients were followed up for 1 year. Success was defined as slit shaped meatus at the tip of the glans without stenosis, fistula or diverticulum.

Results:

All 38 patients were evaluated at 6 months and 1 year follow up. The mean age at surgery was 4.5 ± 2.1 years.

We categorized the patients into two groups:-

(Group A) had a urethral plate width of less than 8 mm, they were 24 patients (63.15 %).

(Group B) had a urethral plate width greater or equal to 8 mm. (group B) had a urethral plate width greater or equal to 8 mm, they are 14 patients (36.8 %)

Overall, the mean ± of UPW was 10.92 ± 1.24 mm while the mean ± SD of GW was 9.52 ± 1.56 mm.

Success was documented in 36/38 patients (94.7%).

The documented complication was Fistula in two patient (5.2 %), glans dehiscensce in three patients (7.9%).

Success rate was not statistically different in correlation of UPW and GW (p=0.5).

The urinary stream was straight in 32 boys and sprayed in 6. Overall, mean ± SD HOPE score was 39.1 ± 8.83.

The only statistically significant difference between all patients was a longer operative time in the patients with deficient urethral plate compared to others with adequate urethral plate (p= 0.005).

A significant correlation found between the cosmetic outcome of the two groups and HOPE score (p = 0.06).

Conclusions:

The pre-incision urethral plate width and glanular width was not correlated with the TIP outcome. A better HOPE score is associated with wide urethral plate.

Key Words:

Hypospadias, urethral plate, tubularized incised plate repair (TIP), hypospadias objective penile evaluation [HOPE].

Background:

Recently, tabularized incised plate procedure (TIP) for repair of distal penile hypospadias is the foremost common method at numerous institutions. But numerous side effects of TIP repair as meatal and/or neourethral stenosis and importance of standard urethral dilatation have been recorded (1). Therefore; to obtain a better outcome the urethral plate must be preserved with increase the surface area with healthy epithelium give better outcome (2)

TIP repair outcome mostly dependent on urethral plate quality in comparison with other surgical procedures. The urethral plate quality is one of the intrinsic risk factors affecting the outcomes of hypospadias repairs. However, there is currently no clear agreement on the evaluation of the urethral plate (5).

The urethral plate width was classified based on an arbitrary 8-mm cut-off value, while groove depth was graded as deep, moderate and shallow. However, the arbitrary value of 8 mm suitable for all penis sizes (3). For the most part, urethral plate width increases with penis size, as the patient grows. It might be more suitable to evaluate urethral plate quality with a parameter scaled with penis size. In recent years, Glans–Urethral Meatus–Shaft score was proposed to classify the severity of hypospadias, a brief strategy for assessing urethral plate quality (4, 5).

There is a debate regarding the effect of UPW and GW on the postoperative complications post TIP surgery. Some reports have found that urethral plate (UP) widths <8 mm before TIP incision increased urethroplasty complications (6). While, The UP width before incision did not increase urethroplasty complications (7-9).

Glans size does not correlate with age in patients with hypospadias between 3 and 24 months old, supporting the decision to operate as early as 3 months in some centers (10). Small glans size, defined as width <14 mm, is an independent risk factor for urethra-cutanous fistula (8).

To address this void, we aimed to answer a question, Is the UPW and GW are a controlling factors for hypospadias outcome as regard the functional and cosmetic outcome?

Materials and methods

After approval from Institutional Review Board, we conducted a prospective study that was carried out in Urology department in kafr el Sheikh University, between November 2018 and November 2019. A total of 38 children diagnosed with distal penile hypospadias were included.

Inclusion criteria were, distal penile hypospadias, primary, uncircumcised, and no or mild chordee (less than 30°), aged < 10 years, No associated syndromes and boys able and willing to comply with follow up schedule.

We excluded boys who were recurrent, circumcised, with severe chordee. Written consent with detailed description of the operation and expected complications was explained and signed from the parents.

All operations were performed by single pediatric urologist. Preoperative IV antibiotic prophylaxis was given. A traction suture using a 5–0 polypropyleneis is placed in the glans just beyond the anticipated dorsal lip of the neomeatus **(Figure (1)** Then a circumferential subcoronal incision was made proximal to the hypospadiac urethral meatus **(Figure (2)** then degloving of the penile skin to the penoscrotal junction **(Figure (3).** A bilateral longitudinal incision were made along the urethral plate to prepare the glanular wings **(Figure (4).**

A relaxing incision is made in the midline by using scalpel or scissors from within the meatus to the end of the plate then TIP **(Figure (5).** The 2nd layer was obtained from the inner dartos muscle and sutured overlying the incision line with 6/0 vicryl **(Figure (6).** A 2nd layer using dartos fascia flap (button hole technique) was applied over the neourethra. The flap width and length were differing in every case according to the location of the meatus, urethral plate characteristics and depth of the midline incision. Urethroplasty was performed using 6/0 Vicryl continuous subcuticular then interrupted sutures and 2nd layer cover using dartos fascia flap.

Glanular wings approximation **(Figure (7)** was made by using interrupted 6/0 Vicryl sutures then closure of skin using 5/0 Monocryl sutures **(Figure (8).** Then dressings was apllied and the stent drips into diaper and kept for 7-10 days **(Figure (9).**

All patients were routinely followed up for cosmetic and functional results at 3 months intervals for a year **(Figure (10).** By routine examination of the external genitalia, evaluation of the voiding symptoms, uroflowmetery study was performed if possible and it was repeated when the voided volume was insufficient or when the result was inconsistent with the physical examination and history.

Overall acceptable cosmetic appearance of the penis was decided according to the slit like appearance of the neo-meatus, the straight position of the penis and this cosmetic aspect was judged by an independent blinded observer. Hypospadias Objective Penile Evaluation (HOPE) is considered a valuable tool for assessing the outcome (11). All methods were carried out in accordance with relevant guidelines and regulations.

Statistical analysis

Statistical analysis performed with IBM Statistical Package for Social Sciences (SPSS) for Windows version 25.0 (Armonk, NY). Quantitative data was expressed as mean & SD and qualitative data was expressed as number and percentage.

Chi squre test was used for comparison of qualitative data and independent t test and paired t test was used for quantitative data. Significance level was set to $p < 0.05$ for significant results and <0.001 for highly significant results.

RESULTS

All patients (38) were evaluated at 6 months and 1 year of follow up.

Mean age at surgery was 4.42 ± 1.86 years.

All 38 patients who had their distal hypospadias repaired using TIP, eight patients (21.1%) had glanular hypospadias, 15 patients (39.5%) had coronal hypospadias and 15 patients (39.5%) had distal penile hypospadias **(Table 1).**

Overall, the mean ± SD of UPW was 4.84 ± 1.27 mm.

We compared between two groups:

(Group A): a 24 patients (61.5%) had a urethral plate width of less than 8 mm.
(Group B): a 14 patients (35.9 %) had a urethral plate width greater or equal to 8 mm.
The mean ± SD of GW was 9.55 ± 1.54 mm.

There was a statistical significance decrease (P<0.001) in mean Hb level among all cases post-operative (11.2±0.7) compare to pre (11.73±0.79) **(Table 3).**

Functional outcome

The average urine flow rates (Qmax) of 38 patients was 7 ml/sec (5.3-10.3).

There was no significant relation between good urinary stream and the mean UPW of the studied groups (p >0.05) [that shown in **(Table 4)]** as:

A 20 (83.3 %) patients in group A have good urinary stream,while 12 patients (85.7%) in group B have good urinary stream.

Cosmetic outcome

The cosmetic outcome was evaluated sing Hypospadias Objective Penile Evaluation (HOPE) (11), **as shown in (Table 2).**

A significant relation found between the cosmetic outcome of the two groups (HOPE score) and UPW of the patients with increase score among cases had UPW ≥8mm (p = 0.02) as: (Overall, mean ± SD hypospadias objective penile evaluation (HOPE) score was 39.1 ± 8.83):-

The mean HOPE score of (group A) patients had of 37.2 ± 6.4 SD while Group B patients had a mean HOPE score of 42.4 ± 6.1 SD.

Post-operative complications

Three patients (7.9%) developed urethrocutanous fistula.

Three patients (7.9%) developed glanular dehiscence.

Four patients (16.7%) in group A developed complications while two patients (14.3%) in group B developed complications.

However, no statistical significance relation founded between the complications and to the mean UPW of the patients ($p>0.5$) as shown in **(Table 4).**

Discussion

Hypospadias is an extremely common congenital anomaly of the penis which results in an incomplete development of the anterior urethra which is characterized by atypical urethral opening anywhere along the shaft of the penis, scrotum, or perineum, abnormal ventral curvature of the penis (chordee) and abnormal ventrally deficient foreskin with hooded foreskin covering the dorsal half of the glans only (a deficient prepuce). There are different procedures that have been described for the repair of hypospadias since of the presence of various hypospadias presentations. Be that as it may, no single technique had 100% satisfactory result (12).

The aim of hypospadias repair surgery is the creation of a urethra of sufficient caliber and length, orthotopic meatus at the tip of the glans permitting the patient to void in a straight stream without maddening spreading with obtaining a conical glans providing a uniform ventral skin cover and correction of penile curvature just to achieve proper sexual intercourse and effectively inseminate (13).

Hypospadias surgery is continuously evolving, since its description by Galen in the first and second centuries AD, to improve the functional and cosmetic results.

The urethral plate is defined as the tissue distinct from the glans and penile skin that incorporated in hypospadias repair, an objective way of assessing the impact of urethral plate on outcome is yet to be established.

Snodgrass in 1994 reported his own technique of tubularized incised plate urethroplasty (TIP) repair for distal hypospadias that gained a widespread use for its perceived simplicity and good cosmetic outcomes in the majority of cases [11].

However, unfortunately, if the urethral plate is narrow the rate of urethrocutaneous fistula, meatal/neo-urethral stenosis is increased [12].In the current study, we evaluated the effect of width of the urethral

plate and glanular width on outcome of hypospadias repair. Most of our patients had coronal and mid-penile hypospadias (38.5 %), the same findings by Prat et al (14). The reason for this is not clear but might be explained by the geographical location.

Hypospadias Objective Penile Evaluation (HOPE) which assessed the cosmetic outcome, there was a statistical significance correlation (p = 0.06).

This finding agrees with the result from some previous studies (15). However, Aboutaleb et al (6) in their study said that an adequate urethral plate width (>8 mm) is essential for successful TIP repair. Lower success rates with flat plates may need buccal mucosal augmentation to improve the results.

As the 8mm UPW or greater is essential for creation of adequate neo-urethra and successful hypospadias repair, we standardized a urethral plate width 8 mm in our study (16), while, Da Silva et al (15) in their study used 10 mm as the dividing line between narrow and wide urethral plates. Nguyen et al (9) and Aboutaleb et al (6) in their studies also used 8 mm as the dividing line. Urethral plate of more than 8 mm is associated with good cosmetic outcome (16, 17).

On the assessment of the functional outcome, we found that narrow urethral plate is associated with poor functional outcome such as poor urinary stream and complications such as meatal stenosis and urethrocutanous fistula (17-19) as 20 (83.3 %) patients in group A had good urinary stream while 12 patients (85.7%) in group B had good urinary stream. Statistical analysis showed that there is a statistically significant difference between the 2 groups (p value of 0.05).

On the other side, Nguyen et al8 and Da Silva et al (15) in their study concluded that width of urethral plate do not affect the functional outcome of hypospadias repair. This is related to the fact that there were confounding variables in their study such as penile size, glans shape and vascularity of the prepuce which were not separately analyzed. We did not assess penile size, glans shape and vascularity of the prepuce in the current study.

There are a variation in the complications following hypospadias repair. It ranges from 6-30% (20, 21). The most common complication we recorded was urethra-cutanous fistula. These differences in complication rates may be explained by the differences in surgical expertise due to low volume of hypospadias repairs done per year in our setting. The rate of urethra-cutanous fistula in our study is not correlated with narrow urethral plate, a similar to (20). While, Aboutaleb reported higher

incidence in fistula in patients with narrow urethral plates when compared to those with wide urethral plate (6, 21).

Though this study was a prospective study, it was limited by a small sample size that hindered the significant statistical difference detection in complications. Moreover, single surgeon series cannot be generalized as the outcome of repair, including complications, may be related to the skill of the surgeon.

Conclusion

The pre-incision urethral plate width and glanular width was not correlated with the TIP outcome. A better HOPE score is associated with wide urethral plate. However, the width of the urethral plate and glanular width may predict the functional outcome (urinary stream).

Table 1. Demographics and clinical data of all patients:

Variable		*Distal hypospadias (N= 38)*
Age "years" (mean ± SD)		4.42 ± 1.86
Weight "Kg" (mean ± SD)		17.45 ± 3.94
BMI (Kg/m^2)		16.06 ± 1.64
Presentation	Abnormal EUM	38 (100%)
ASA score	1	38 (100%)
Circumcised	Yes	12 (31.6 %)
Congenital anomalies	Absent	38 (100%)
Testis	Palpable	38 (100%)
Nature	De novo	38 (100%)
Meatal location	Glanular	8 (21.1 %)
	Coronal	15 (39.5 %)
	Midpenile	15 (39.5 %)
Urethral plate width (UPW)		4.84 ± 1.29
Urethral plate width	<8mm	24 (63.2%)
	≥8mm	14 (36.8%)
Urethral plate adequacy	Adequate	30 (78.9 %)
	Deficient	8 (21.1%)
Glans length (mean ± SD)		7.29 ± 1.64
Glanular width (mean ± SD)		9.55 ± 1.54
GW	<14 mm	36 (94.7%)
	≥14 mm	2 (5.3%)
Chordea	Present	8 (21.1%)
	Absent	30 (78.9%)
Ventral curvature	10-30	2 (5.2 %)
	≤ 10	5 (18.1 %)

SD: Standard deviation

Table 2. Operation data among the studied cases:

Variable		*Distal hypospadias (N= 38)*
Type of operation	TIP	38 (100%)
Operation time “min” (mean ± SD)		133.82 ± 20.84
Type of threads	Vicryle 5/0	1 (2.6%)
	Vicryle 6/0	28 (73.7%)
	PDS 6/0	9 (23.7%)
New urethral tube	Yes	38 (100%)
Covering flap	Dartos flap	38 (100%)
Torniquite time “min” (mean ± SD)		79.61 ± 10.03
Nerve block	No	38 (100%)
Diathermy	No	7 (18.4%)
	Yes (Bipolar)	31 (81.6%)
Hospital stay “Days” (mean ± SD)		11.79 ± 1.73
Urine Cath	Yes	38 (100%)
Type	Nelton 6F	6 (15.8%)
	Nelton 8F	25 (65.8%)
	Nelton 10F	7 (18.4%)
Catheter duration “day” (mean ± SD)		11.79 ± 1.73

SD: Standard deviation

Table 3. Laboratory data of the studied cases:

		Distal hypospadias (N= 38)
Urine PH	Acidic	38 (100%)
UTI	No	26 (68.4%)
	Yes	12 (31.6%)
Organism	E coli	7 (18.4%)
	Proteus	2 (5.3%)
	Klebseilla	1 (2.6%)
	Othre	2 (5.3%)
Creatinine “mg/dl” (mean ± SD)		0.98 ± 0.17
Hb pre “gm/dl” (mean ± SD)		11.73 ± 0.79
Hb post “gm/dl” (mean ± SD)		11.22 ± 0.70
P		<0.001**
HCT pre “%” (mean ± SD)		32.99 ± 0.55
HCT post “%” (mean ± SD)		32.89 ± 0.49
P		0.34 NS

SD: Standard deviation P: Paired t test NS: non-significant (P>0.05) **: highly significant (P<0.001)

Table 4. Outcome in relation to UPW:

		UPW ≤ 8 mm (N= 24)	UPW ≥ 8 mm (N= 14)	χ^2/t	P
Success	Failure	3 (12.5%)	0 (0%)	1.9	0.17 NS
	Succeed	21 (87.5%)	14 (100%)		
Complication	No	20 (83.3%)	12 (85.7%)	2.9	0.23 NS
	Fistula	3 (12.5%)	0 (0%)		
	Skin infection	1 (4.25)	2 (14.3%)		
No of UC		0 (0%)	3 (12.3%)	5.58	0.02*
Glanular dehiscence		1 (4.2 %)	2 (14.3%)	1.25	0.27 NS
Meatal stenosis		2 (8.3%)	2 (14.3%)	0.33	0.56 NS
Slit like urethra		20 (83.3%)	12 (85.7%)	0.04	0.85 NS
Straight penis		20 (83.3%)	12 (85.7%)	0.04	0.85 NS
Skin shape	Normal	20 (83.3%)	12 (85.7%)	0.04	0.85 NS
	Slightly abnormal	4 (16.7%)	2 (14.3%)		
Glans shape	Normal	20 (83.3%)	12 (85.7%)	0.04	0.85 NS
	Slightly abnormal	4 (16.7%)	2 (14.3%)		
Meatal shape	Vertical slit	20 (83.3%)	12 (85.7%)	2.33	0.31 NS
	Cicular	4 (16.7%)	1 (7.1%)		
	Abnormal	0 (0%)	1 (7.1%)		
Meatus position	Distal glanular	20 (83.3%)	12 (85.7%)	5.77	0.06 NS
	Proximal glanular	4 (16.7%)	0 (0%)		
	Coronal	0 (0%)	2 (14.3)		
Urinary stream	Single stream	20 (83.3%)	12 (85.7%)	0.04	0.85 NS
	Spray	4 (16.7%)	2 (14.3%)		
Cosmetic out come	Good	20 (83.3%)	12 (85.7%)	0.04	0.85 NS
	Bad	4 (16.7%)	2 (14.3 %)		
Q max (mean ± SD)		8.4 ± 2.4	10.4 ± 3.1	1.98	0.05 NS
HOPE		37.2 ± 6.4	42.4 ± 6.1	2.46	0.02 *

SD: Standard deviation

t: Independent t test

χ^2: Chi square test

NS: non-significant (P>0.05)

*: Significant (P<0.05)

Declarations

Ethical approval:-

All experimental protocols were approved by the Institutional review board of Kafr el Sheikh University.

Consent for participation:

Informed consent was obtained from a parent and/or legal guardian.

Consent to publication:-

All patients' parents were informed about the study and accepted the publication

Availability of data & materials:-

The datasets used and/or analyzed during the current study available from the corresponding author on reasonable request.

Data were collected patient by patient with utmost accuracy. The data were collected in a paper form as we don't have electronic patient file system (PIS) or global health information system (HIS).

M.G and K.Z collect data of the article, D.T wrote the article & T.A and H.N revised the article

Competing interest: No Conflict of interest

Funding: None

Authers contributions:-

M.G and K.Z collect data of the article, D.T wrote the article & T.A and H.N revised the article.

Acknowledgments:-

We appreciate all the urology department members for their collaborative and enthusiastic attitude.

List of figures:-

List of abbreviations:-

UPW	Urethral plate width
GW	Glans width
HOPE	hypospadias objective penile evaluation
TIP	Snodgrass tubularized incised plate repair
SD	Standard of deviation
BMI	Body Masss Index
P	Paired t test
NS	Non-significant
T	Independent t test
χ^2	Chi square test

References

1. Silay MS, et al. "Snodgraft" technique for the treatment of primary distal hypospadias: pushing the envelope. J Urol.2012; 188(3):938-42.

2. Wilkinson DJ, Farrelly P, Kenny SE. Outcomes in distal hypospadias: a systematic review of the Mathieu and tubularized incised plate repairs. J pediatr urol.2012; 8(3):307-12.

3. Holland AJ, Smith GH. Effect of the depth and width of the urethral plate on tubularized incised plate urethroplasty. Urology. 2000; 164(2):489-91.

4. Merriman LS, et al. The GMS hypospadias score: assessment of inter-observer reliability and correlation with post-operative complications. J pediatr urol.2013; 9(6 Pt a):707-12.

5. Arlen AM, et al. Further analysis of the Glans-Urethral Meatus-Shaft (GMS) hypospadias score: correlation with postoperative complications. J pediatr urol.2015; 11(2):71.e1-5.

6. Aboutaleb H. Role of the urethral plate characters in the success of tubularized incised plate urethroplasty. Indian journal of plastic surgery: official publication of the Association of Plastic Surgeons of India. 2014; 47(2):227-31.

7. Bush NC, Snodgrass W. Pre-incision urethral plate width does not impact short-term Tubularized Incised Plate urethroplasty outcomes. J pediatr urol.2017; 13(6):625.e1-.e6.

8. Bush NC, Villanueva C, Snodgrass W. Glans size is an independent risk factor for urethroplasty complications after hypospadias repair. J pediatr urol.2015; 11(6):355.e1-5.

9. Nguyen MT, Snodgrass WT, Zaontz MR. Effect of urethral plate characteristics on tubularized incised plate urethroplasty. Urology. 2004; 171(3):1260-2; discussion 2.

10. Bush NC, DaJusta D, Snodgrass WT. Glans penis width in patients with hypospadias compared to healthy controls. J pediatr urol.2013; 9(6 Pt B):1188-91.

11. Van der Toorn F, et al. Introducing the HOPE (Hypospadias Objective Penile Evaluation)-score: a validation study of an objective scoring system for evaluating cosmetic appearance in hypospadias patients. J pediatr urol. 2013; 9(6 Pt B):1006-16.

12. Stein DM, Thum DJ, Barbagli G, Kulkarni S, Sansalone S, Pardeshi A, et al. A geographic analysis of male urethral stricture aetiology and location. BJU international. 2013; 112(6):830-4.

13. Moriya K, et al. Long-term cosmetic and sexual outcome of hypospadias surgery: norm related study in adolescence. Urology. 2006; 176(4 Pt 2):1889-93.

14. Eassa W, He X, El-Sherbiny M. How much does the midline incision add to urethral diameter after tubularized incised plate urethroplasty? An experimental animal study. Urology. 2011; 186(4 Suppl):1625-9.

15. Da Silva EA, et al. Role of penile biometric characteristics on surgical outcome of hypospadias repair. Pediatric surgery international. 2014; 30(3):339-44.

16. Chukwubuike KE, et al. Assessment of the effect of urethral plate width on outcome of hypospadias repair. J pediatr urol. 2019; 15(6):627.e1-.e6.

17. Mane S, Arlikar J, Dhende N. Modified tubularized incised plate urethroplasty. Journal of Indian Association of Pediatric Surgeons. 2013; 18(2):62-5.

18. Eliçevik M, et al. Tubularized incised plate urethroplasty for hypospadias reoperations in 100 patients. International urology and nephrology. 2007; 39(3):823-7.

19. Sarhan O, Saad M, Helmy T, Hafez A. Effect of suturing technique and urethral plate characteristics on complication rate following hypospadias repair: a prospective randomized study. Urology. 2009; 182(2):682-5; discussion 5-6.

20. Bhat A, Mandal AK. Acute postoperative complications of hypospadias repair. Indian journal of urology: IJU: journal of the Urological Society of India. 2008; 24(2):241-8.

21. Shapiro SR. Complications of hypospadias repair. Urology. 1984; 131(3):518-22.

Figures

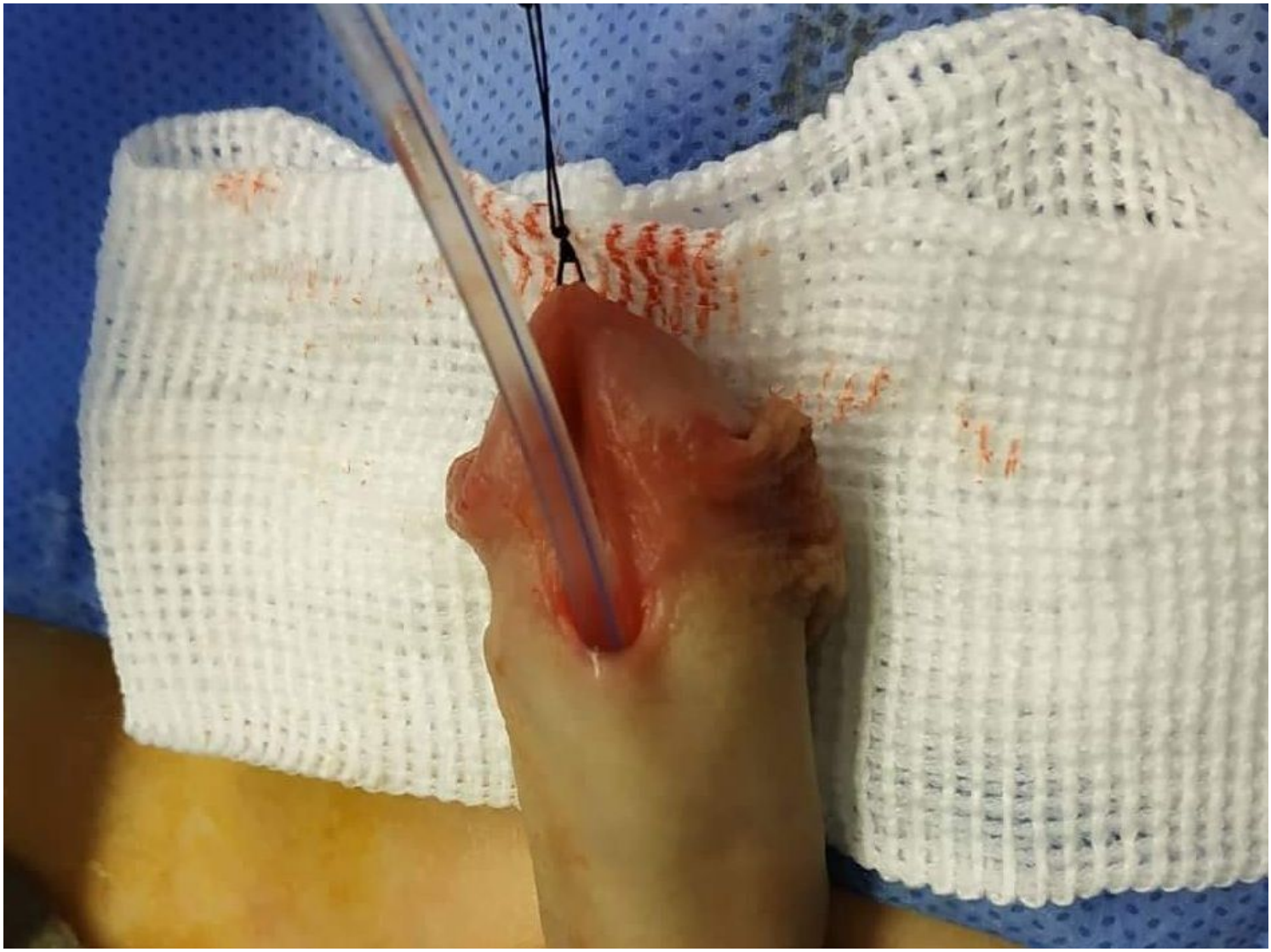

Figure 1

Traction suture (5–0 silk) is placed in the glans just beyond the neomeatus

Figure 2

Separate the urethral plate from the glans wings

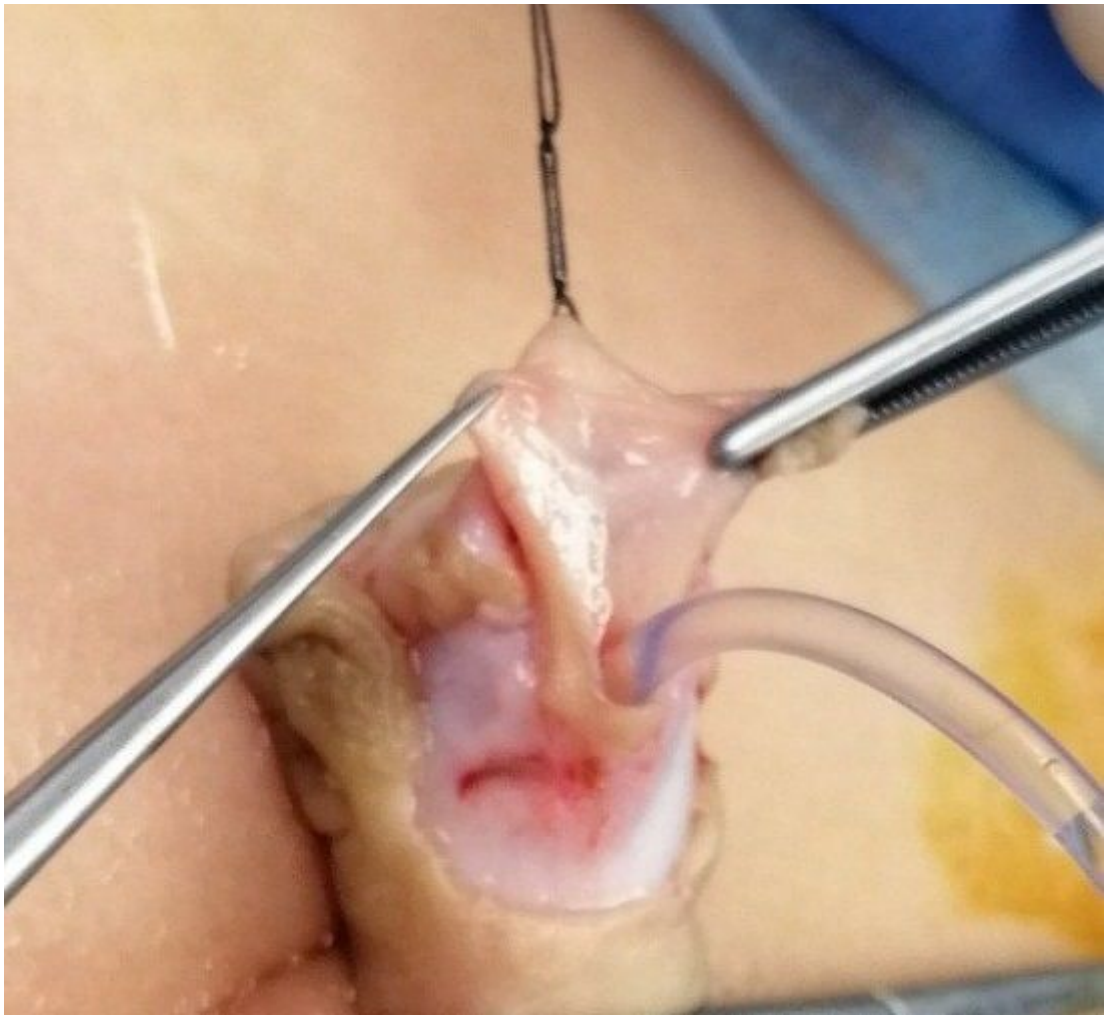

Figure 3

Circumferential subcoronal incision made proximal to the hypospadiac meatus then degloving of the penile skin.

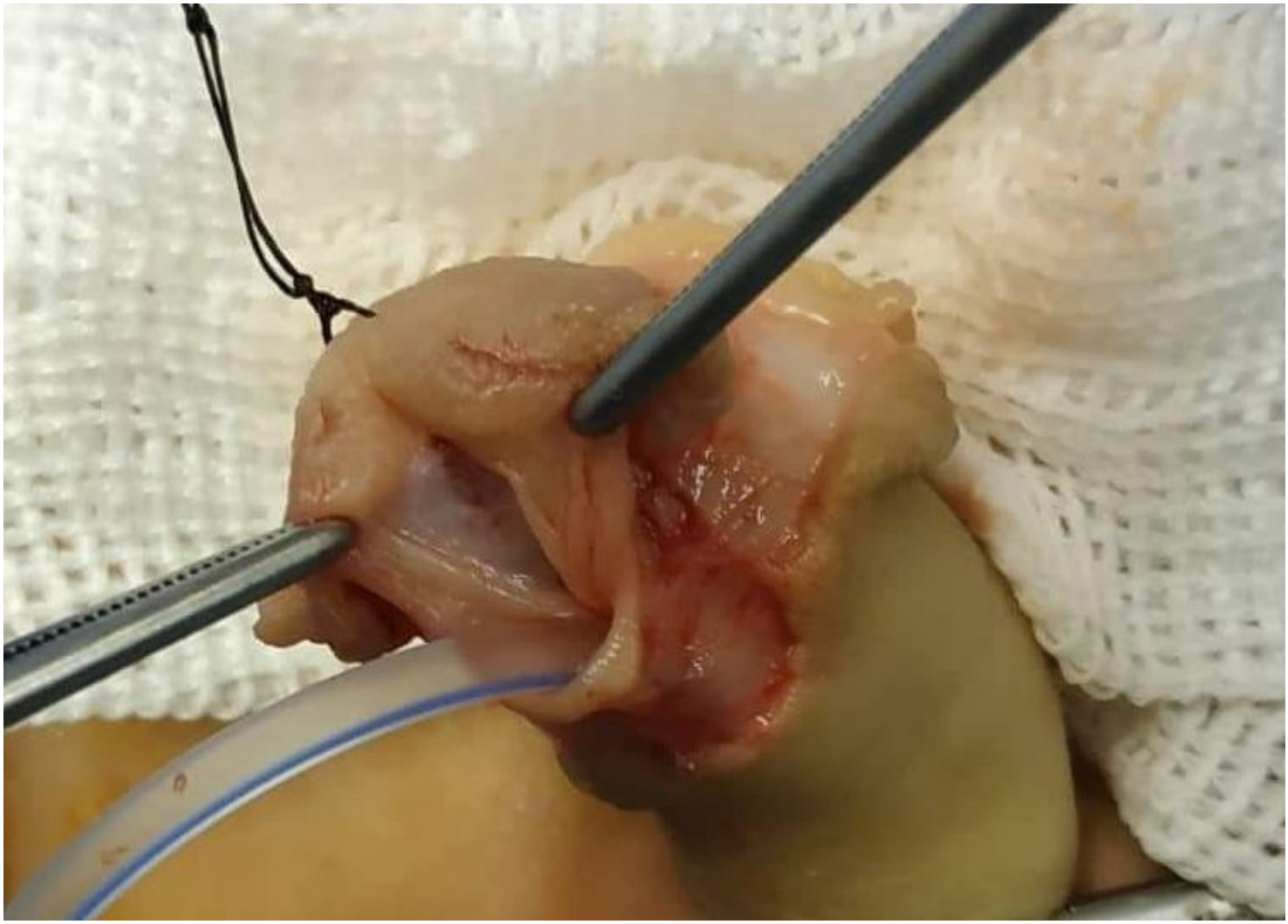

Figure 4

Urethral plate is incised longitudinally

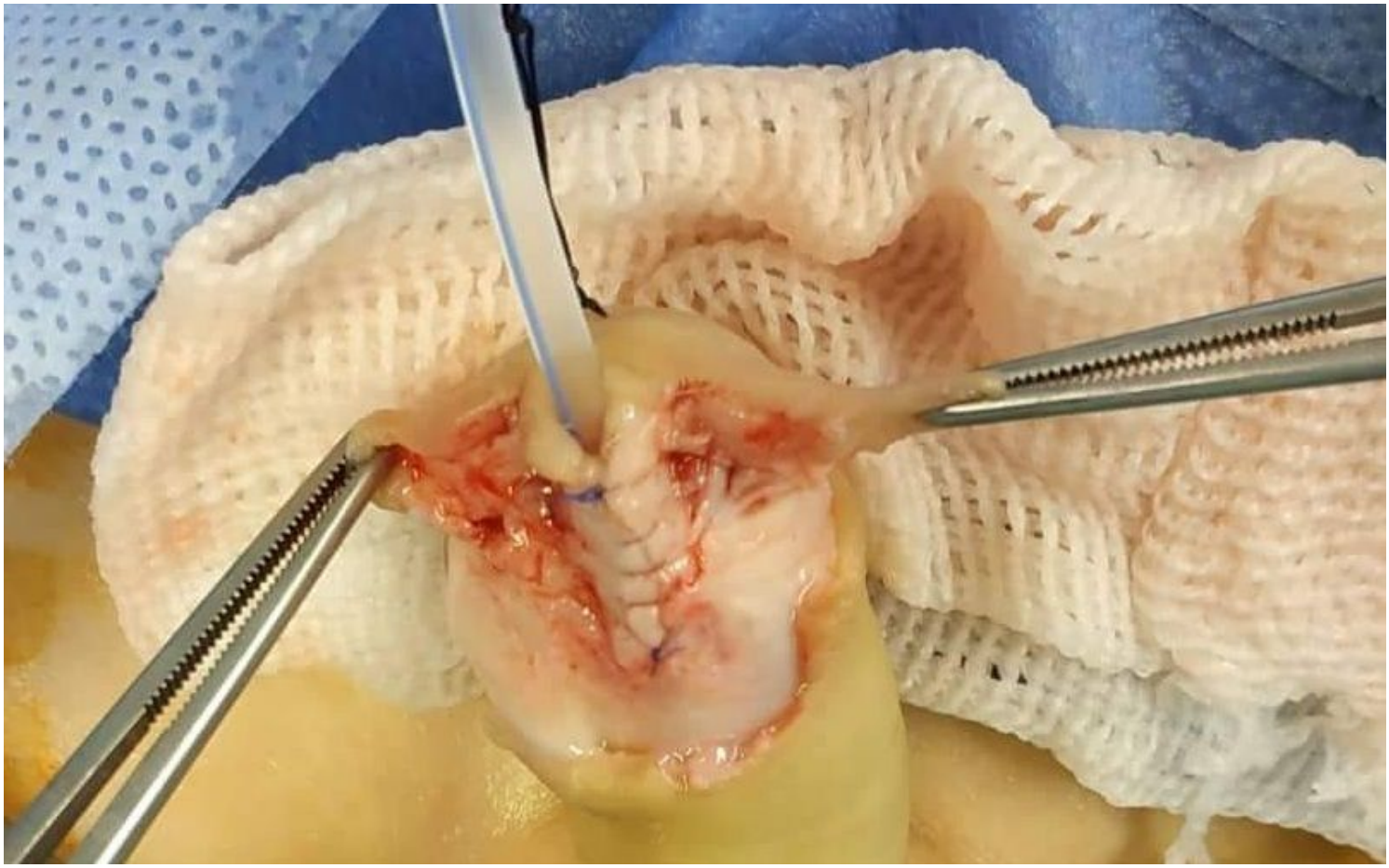

Figure 5

Neourethral tubularization

Figure 6

Dartos flap is transposed ventrally through button-holed and fixed to cover the entire neourethra

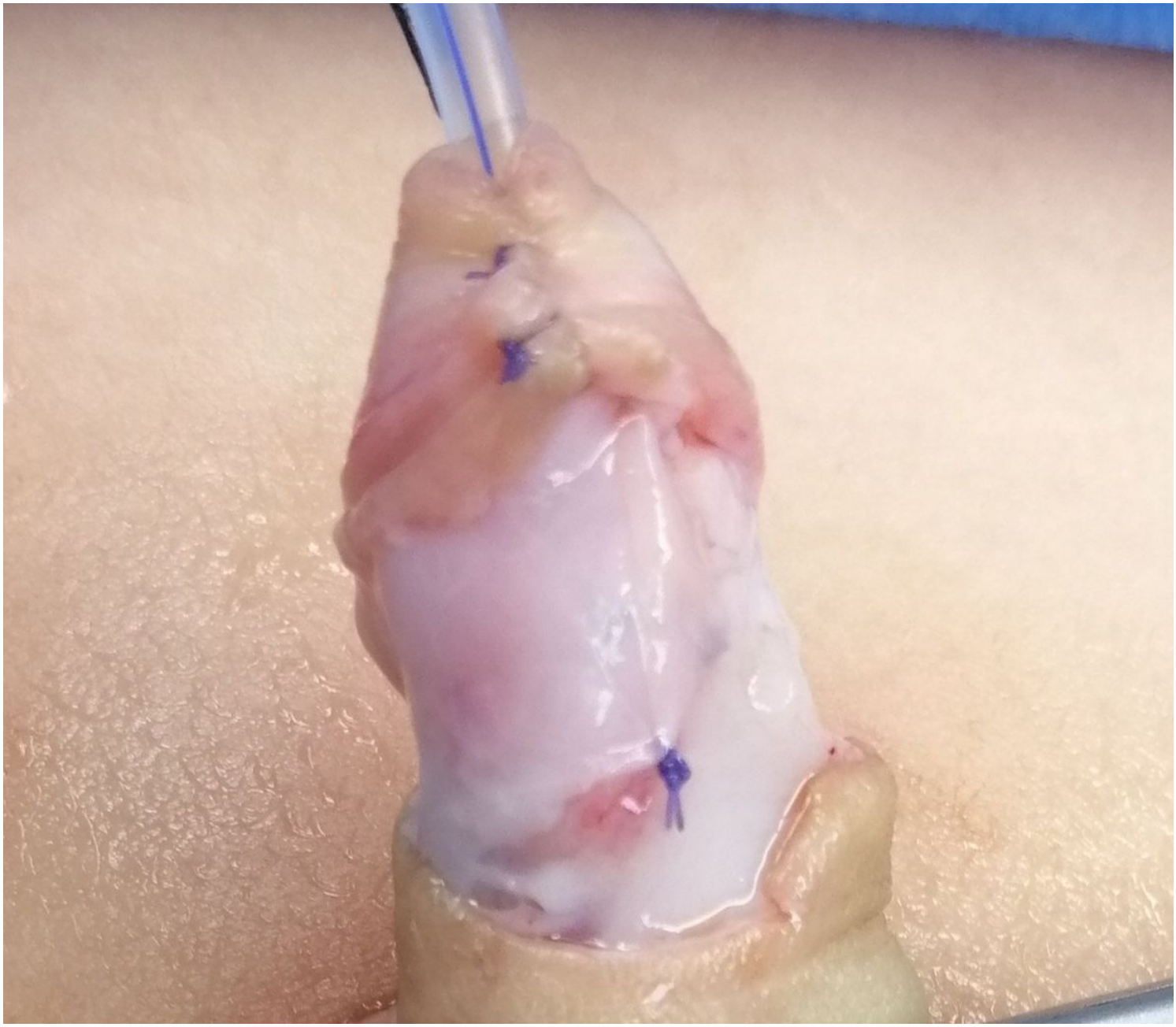

Figure 7

Glanular wings approximation

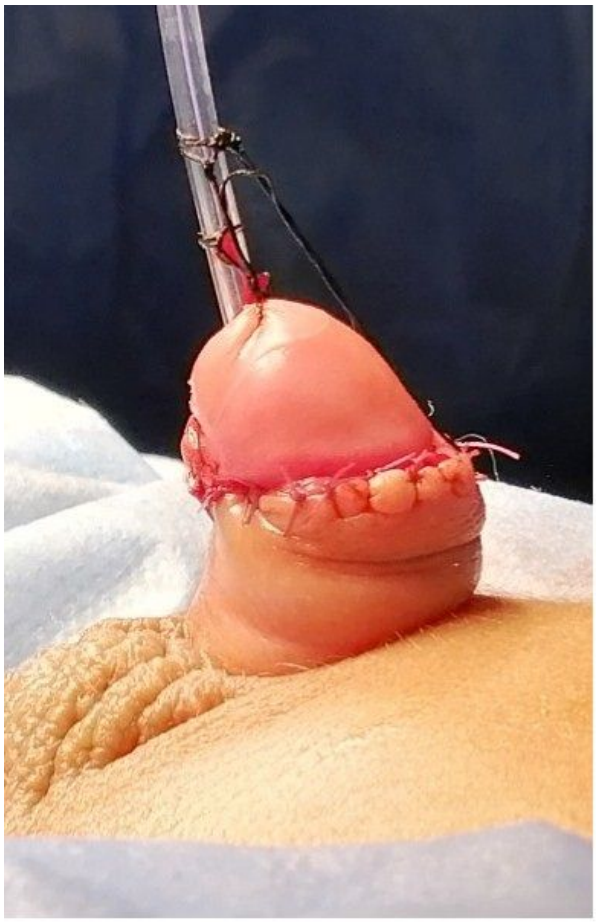

Figure 8

Closure of Penile skin

Figure 9

Dressings was apllied and the stent drips into diaper

Figure 10

Post-operative follow up of Snodgrass patient after 12 months