Comparison of Percutaneous Vertebroplasty and Percutaneous Curved Vertebroplasty for Osteoporotic Vertebral Compression Fractures: Distribution of Bone Cement and Complication

Li Fan Jie
Anhui Medical University
Li Yang
Anhui Medical University
Wang Yan Jie
Anhui Medical University
Du YiBin (lifanjie@stu.ahmu.edu.cn)
Anhui Medical University

Research article

Keywords: bone cement, osteoporotic fracture, percutaneous curved vertebroplasty, vertebral height, visual analogue scale score, Oswestry disability index

Posted Date: December 30th, 2020

DOI: https://doi.org/10.21203/rs.3.rs-136112/v1

Abstract

Purpose: To evaluate the clinical efficacy and complications of percutaneous curved vertebroplasty in treatment of osteoporotic vertebral compression fractures.

Methods: Patients with single vertebral osteoporotic vertebral compression fractures were selected. The patients were divided into Percutaneous curved vertebroplasty group and Percutaneous vertebroplasty group.Distribution and leakage of bone cement and recovery of the height of the anterior edge of the injured vertebra were observed. VAS and ODI were assessed preoperatively 1 day and 1 year postoperatively. Postoperative follow-up was conducted for 1 year to observe the occurrence of adjacent vertebral fractures. The trial was approved by the Ethics Committee of the Third Affiliated Hospital of Anhui Medical University.

Results: Compared with the percutaneous vertebroplasty group, distribution of bone cement was more uniform and satisfactory, the leakage rate of bone cement was lower in the percutaneous curved vertebroplasty group. Both the visual analogue scale score and Oswestry disability index of the two groups at 1 day and I year after surgery were significantly improved compared with those before surgery ($P < 0.05$). There was no significant difference in VAS and ODI. The height of the anterior edge of the injured vertebral body of the two groups improved significantly($P < 0.05$), and there was no significant difference between the two groups . There was no significant difference in the incidence of adjacent vertebral fractures between the two groups..

Conclusion: The results show that PCVP has beneficial to the uniform distribution of bone cement in the fracture vertebrae and reduce the leakage of bone cement.

Introduction

Osteoporotic vertebral compression fractures(OVCFs) has become a common disease among the middle-aged and elderly all over the world, and its global prevalence rate is gradually increasing with the aging of the population. Some studies had shown that it accounted for 30% -50% of the global population over the age of 50[1]. The clinical manifestations of osteoporotic vertebral compression fractures include pain, limited physiological function, decreased quality of life, increased mortality and so on[2, 3]. It will also increase the risk of adjacent vertebral c fractures in the future[4, 5].

Nowadays, the treatment of osteoporotic vertebral compression fractures includes :(1) Conservative treatment: rest, analgesia, brace support, and physiotherapy[3]; (2)Surgical treatment :percutaneous vertebroplasty (PVP) which was most commonly used; percutaneous balloon kyphoplasty(PKP) and percutaneous curved vertebroplasty(PCVP) which has not been widely used in clinic. Moroever, several studies have shown that minimally invasive surgery for OVCFs was a better choice than conservative treatment, because it could not only immediately relieve back pain, but also avoided many complications of patients lying in bed during conservative treatment[6].

PVP was introduced by Galibert et al in 1987. Since then, this minimally invasive treatment had been promoted as a stable treatment for osteoporotic vertebral compression fractures that can not be relieved by conservative treatment. As a routine method for the treatment of osteoporotic vertebral compression fractures, pvp can stabilize the spine and effectively relieve short-term pain[7–9]. However, its disadvantages as a common surgical method are still obvious: systemic complications of vertebroplasty are rare; fat embolism or arterial embolism may occur,;and epidural bleeding can also take place, but it is extremely infrequent[10, 11]. Due to the large amount of injected bone cement, the most common complication is bone cement leakage, and the uneven distribution of bone cement will also increase the risk of adjacent vertebral fractures[12–15].

As an improved method of PVP, PCVP makes use of the characteristics of its material to change the end of the conveying cannula from a flat to a bendable channel, punctured through the unilateral pedicle, make the bone cement dispersed to the

stele through the anterior column of the vertebral body. The injection point can be controlled with displacement and has strong maneuverability. The biggest characteristic of PCVP is that the bone cement can be symmetrically and evenly distributed which can solve the problem of poor pain relief in the bone fracture area caused by the uneven distribution of single point and single injection of bone cement in traditional vertebroplasty theoretically[16].

In this study, the clinical efficacy and postoperative complications of PCVP and unilateral PVP in the treatment of OCVFs were evaluated and statistically compared, so as to evaluate the clinical value of cPCVP compared with PVP.

Patients And Methods

study patients

One hundred patients with single vertebral osteoporotic vertebral compression fracture treated in the third affiliated Hospital of Anhui Medical University from June 2018 to June 2019 were randomly divided into PVP group (n = 50) and PCVP (n = 50).

Inclusion criteria included: (1) patients ≥ 50 years old;(2) patients with no or mild trauma history and back axial pain related to fracture, without symptoms of spinal cord nerve compression;(3) ineffective non-operative treatment, visual analogy score of low back pain ≥ 5;(4)imaging diagnosis of osteoporotic vertebral compression fracture with single vertebral body injury; (5) patients with bone mineral density T-2.5(6)could lie prone for more than 0.5 hours before operation, and tolerate the operation, whom agreed to take part in the trial.

Exclusion criteria: (1) systemic or local infection, or vertebral body tumor; (2) vertebral compression leading to intraspinal space occupation of more than 30%; (3) vertebral body was severely damaged, and MRI suggested that there were unstable fractures with posterior ligament complex injury; (4) abnormal blood coagulation; (5) poor basic condcitions, severe cardiopulmonary function and other diseases, unable to tolerate surgery;(6) pairs of bone cement or surgical instruments allergic; (7) refused to join the test.

We confirm that all methods were carried out in accordance with the relevant guidelines and regulations of the Ethics Committee of Hefei First people's Hospital. We confirmed that all experimental schemes had been approved by the Hospital Ethics Committee of Hefei first people's Hospital, and that all procedures carried out in this study, including human participants, comply with the ethical standards of the Institutional Research Committee, and comply with the 1964 Helsinki Declaration and its subsequent amendments or similar ethical standards. The informed consent of all patients was obtained in this study(Figure1).

surgical procedure

The PVP and PCVP was performed using specialized instruments (Vertebroplasty system; percutaneous curved vertebroplasty system; Hicren, Ningbo, China) to inject polymethylmethacrylate (PMMA) cement with unilateral transverse process-pedicle under local anesthesia(Table 1).The operations were performed by two different surgeons independently. After the bone cement was perfused, the catheter was pulled out in time, and the needle hole was sutured or pasted aseptically according to the size of the needle hole. The patients were observed for 5-10 minutes after operation, and were sent back to the ward after operation(Figure2).

postoperative management:

each patient was required to get out of bed under the protection of thoracolumbar brace 24 hours after operation. Functional exercise was carried out. Thoracolumbar brace was generally worn for 3 months. In addition, anti-osteoporosis drugs were used.

clinical and radiographic evaluation

General condition of patients: the age, gender, segment of injured vertebral body, the time of operation, the times of intraoperative fluoroscopy and the amount of bone cement were recorded in operation.

Clinical efficacy: the height of the anterior edge of the injured vertebral body was recorded before operation and 1 day after operation; and the Visual analogy score (VAS) and Oswestry dysfunction Index (ODI; excluding the section of sex life) were recorded before operation , 1 day after operation and 1 year after operation.

The vertebral body injected with bone cement was observed before discharge, and the vertebral body was scanned along the axial direction by CT to observe the diffusion of bone cement, which was divided into unilateral distribution that did not cross the midline of vertebral body, unilateral filling that reached the midline of vertebral body, bilateral filling that crossed the midline of vertebral body, bilateral filling that crossed the midline of vertebral body and reached bilateral filling 3/5of vertebral body. During the operation, orthopedic surgeons will try their best to make the bone cement disperse to the level beyond the midline of the vertebral body, but the dispersion of bone cement is not artificially controlled, so in fact, the diffusion results of bone cement are more changeable in clinic.

Incidence of re-fracture: the recurrence of brittle fracture of vertebral body after operation includes fractures of injured vertebrae, adjacent vertebrae and non-adjacent vertebrae (the diagnosis of fractures needs to be confirmed by MRI). All the data were evaluated and calculated by 2 spinal surgeons who were not involved in the operation. The follow-up period was 1 year.

statistical analysis

Continuous data are presented as mean±SD and categorial data are presented as n prevalence. Between-group differences, paired t-test and independent samples t-test were performed. Chi-squared test was performed to compare the incidence of re-fracture level and gender. The statistical analyses were conducted using SPSS version 24.0 (SPSS Inc., Chicago, IL, USA). P,0.05 was considered statistically significant, and all P-values presented were two-tailed.

Results

Baseline data

From June 2018 to June 2019, a total of 100 patients with OVCFs were included in the study. There were 50 cases in PVP group and 50 cases in PCVP group. All the patients were followed up. There were 18 males and 82 females, aged (81.48 ±2.27) years.There was no significant difference in sex and age between the two groups (P > 0.05). There was no significant difference in injured vertebral body between the two groups (P >0.05) (Table 2).

Intraoperative condition

The operations in both groups were completed successfully and no intraoperative complications occurred. There was no significant difference in operation time, intraoperative fluoroscopy times and bone cement dosage between the two groups(Table 3).

Postoperative condition

All patients completed X-ray and CT examination 1 day postsurgery. There were 6 cases of bone cement leakage in PCVP group and 17 cases in PVP group. Bone cement leakage was located in intervertebral space, anterior edge of vertebral body, or lateral position, but there were no neurological symptoms in all cases. The leakage in PCVP group was significantly lower than that in PVP group, and there was significant difference in bone cement leakage between the two groups (P < 0.05).

The distribution of bone cement was observed in two groups, including unilateral distribution that did not cross the midline of vertebral body 1 case, unilateral filling that reached the midline of vertebral body 1 case, bilateral filling that crossed the

midline of vertebral body 28 case, bilateral filling that crossed the midline of vertebral body and reached bilateral filling 3/5of vertebral body 20 case, and in the PVP group, they were respectively 11 case , 12 case, 21 case, 6 case. There was significant difference in the distribution of bone cement between the two groups (P<0.05).

The height of the anterior edge of the vertebral body of the two groups was collected presurgery and 1 day postsurgery. The average height of anterior edge of vertebral body in PCVP group presurgery was 13.72±3.57mm, PVP group was 13.36±3.52. The average height of anterior edge of vertebral body in PCVP group 1 day postsurgery was 20.29±3.61mm, PVP group was 20.53±3.16; There was no significant difference in the height of the anterior edge of the injured vertebral body between the two groups before and after operation. The height of the anterior edge of the vertebral body recovered significantly in both groups before and after operation(Figure 3 and 4).

The vertebral re-fracture and adjacent vertebral fracture were collected in the two groups during the follow-up period. There was no re-fracture of vertebral body in both groups. However, 5 cases of adjacent vertebral body re-fracture occurred in PCVP group during the follow-up period, and 2 cases were found by PVP. There was no significant difference between the two groups（P>0.05）（Table 4）.

Comparison of score scale

There was no significant difference in VAS score and ODI score between the two groups presurgery, but VAS score and ODI score were significantly improved in both groups at 1 day and 1 year postsurgery, and postoperative pain was significantly improved in both groups. There was no significant difference in VAS score and ODI score between the two groups at each time point（Table 5）.

Discussion

With the aging of the world population, the incidence of osteoporotic vertebral compression fractures is increasing year by year. Conservative treatment and vertebroplasty are the two most common methods for the treatment of osteoporotic vertebral compression fracture. At present, conservative treatment of osteoporotic vertebral compression fracture will further lose bone mass, and osteoporosis will be more serious, which lead to a vicious circle of more prone to fracture and seriously affect the quality of life of patients[17]. Some studies had pointed out that surgical treatment may be a better way to solve osteoporotic vertebral compression fractures[18].However, unilateral vertebroplasty will cause uneven distribution of bone cement due to the influence of surgeons, and if it intend to achieve a more ideal distribution pattern in the process of injection, it is bound to increase the angle of puncture needle, which will inevitably increase the risk of operation. Bilateral puncture will also lead to corresponding puncture injury and operation cost. Therefore, how to obtain better dispersion of bone cement will greatly affect the curative effect of vertebroplasty.

Through this study, we concluded that there was no significant difference in the operation time, the number of intraoperative fluoroscopy and the amount of bone cement between the two groups. That was, PCVP would not increase the prone time of the patients during the operation, and could ensure the smooth operation. It also shown that the performance of the improved method of PCVP is no less than that of PVP which has been skillfully mastered in clinic. The postoperative VAS score and ODI score of the two groups were significantly improved. Although it could not be ruled out whether it was caused by the operator, it was sufficient to show that PCVP was not inferior to PVP in postoperative pain relief. Our study also collected the changes of the height of the anterior edge of the injured vertebra before and after operation. The height of the anterior edge of the cone increased significantly in both methods, and the degree of recovery of vertebral height obtained by the two methods was similar, which suggested that the effect of PCVP in restoring vertebral height was similar to that of PVP.

The biggest difference in this study was the distribution of bone cement, which was in line with our previous conjecture. Including unilateral distribution that did not cross the midline of vertebral body 1 case, unilateral filling that reached the

midline of vertebral body 1 case, bilateral filling that crossed the midline of vertebral body 28 case, bilateral filling that crossed the midline of vertebral body and reached bilateral filling 3/5of vertebral body 20 case, and in the PVP group, they were respectively 11 case , 12 case, 21 case, 6 case. There was no doubt that the reason for this difference lied in the different working channels adopted. PCVP used the curved channel to realize unilateral puncture and inject bone cement into the opposite side of the vertebral body, which could realize the filling of the whole vertebral body. Due to the characteristics of this channel, when the rigid needle tube or working casing is held straight into the vertebral body, the memory alloy returns to the original angle. In this way, the uneven dispersion of bone cement in the vertebral body caused by various uncertain factors such as puncture position, vertebral bone condition and bone cement dispersion can be avoided. Thus,the distribution of bone cement is one of the important factors affecting the prognosis in many studies, and it is more likely to affect the complications after vertebroplasty.

Firstly was bone cement leakage. Previous studies had shown that cortical rupture, excessive cement volume and low bone mineral density were the three major predictors of cement leakage[19]. Thus bone cement leakage was a strong evidence of risk factors for new OVCFs[20]. Clinically, complex osteoporotic vertebral compression fractures such as incomplete posterior wall of vertebral body and vertebral compression more than 75% are contraindications for vertebroplasty. In vertebroplasty, because it can not cross the sagittal midline of the vertebral body, and whether the bone cement approaches the middle of the vertebral body is closely related to the internal inclination angle. In order to obtain a good effect of bone cement diffusion, clinicians are bound to increase the introversion angle or increase the amount of bone cement perfusion or even choose bilateral vertebroplasty. Which a study had shown that the maximum distance between the safety line of the vertebral body between the C3-L5 and the posterior vertebral line on the lateral X-ray film was (5.22 ±0.62) mm, which gradually decreases from L1 to L5 to (1.05 ±0.64) mm. The leakage rate of bone cement in the experimental group without crossing the safety line was significantly lower than that in the control group[21]. Therefore, it is undoubtedly difficult to control bone cement in clinic, not only to achieve good diffusion effect, but also to reduce the occurrence of bone cement leakage. In this study, we believed that the difference of bone cement leakage between the PVP group and PCVP group was due to the difference in the distribution of bone cement between the two groups. And there was study had confirmed our conjecture. HeCJ et al confirmed that the inadequate distribution of bone cement was related to the leakage of bone cement, because in the process of bone cement injection, the pressure in the vertebral body will gradually increase with the increase of the amount of bone cement injection, which may increase the risk of leakage during the injection process, especially in unilateral vertebroplasty[22]. However, the bendable working channel used in PCVP could squeeze the cancellous bone when entering the vertebral body, achieve the effect of low pressure injection, and achieve the effect of multi-point injection when reversing the working channel, so that the bone cement can be better dispersed.

The second was the occurrence of recurrent vertebral fracture. There was no recurrent vertebral fracture in both groups in our study. This was different from some recent studies. The effect of the distribution of bone cement on recurrent vertebral fractures had also been described in a number of studies. Among them, Liebschner et al found that symmetrically distributed bone cement could obtain greater stiffness. In addition, there was a close relationship between bone cement leakage and vertebral re-fracture. This may be reflected in (1) the uneven distribution of bone cement in the diseased vertebral body, resulting in an uneven increase in the strength and stiffness of various parts of the vertebral body; (2) the relative strength and stiffness of the injured vertebral body is significantly higher than that of the adjacent vertebral body after injection of bone cement[23]. Rho YJ et al also confirmed that the distribution pattern of bone cement was related to the occurrence of new compression fractures in adjacent vertebrae[24]. Subsequently, many experts had discussed the distribution pattern of bone cement. According to the study of BaekSW et al., theoretically, the circular distribution of bone cement along the edge of the vertebral body could reduce the uneven stress of the adjacent vertebral body, thus reducing the risk of re-fracture[25]. And another study had shown that no matter whether the bone cement was in full contact with the upper and lower endplate, it could have a good immediate analgesic effect. However, if the bone cement was in full contact with the upper and lower endplate, it could better restore the vertebral body strength. Thus better maintain the vertebral body height and reduce the risk of vertebral recompression, and its long-term effect is better[26].

The impact of a better distribution pattern of bone cement on clinical efficacy is also obvious. In Liu's study, the fused bilateral bone cement distribution group achieved a better short-term analgesic effect than the separated bilateral bone cement distribution group. It was believed that due to the uneven distribution of bone cement, the vertebral body was still stimulated by nerve endings under unilateral load, and the instability of the vertebral body will still lead to low back pain after operation[27]. In our study, PCVP was able to obtain better cement distribution due to the design of bendable channels. It could easily cross the midline of the vertebral body and achieved the effect of bilateral distribution. However, in our study, PCVP did not show better short-term postoperative pain relief and a reduction in the incidence of adjacent vertebral fractures. The possible reasons we consider were:(1) In order to obtain better results during the operation, the surgeon artificially increased the introverted angle during the PVP operation; (2) The use of postoperative analgesics and braces affects the patient's judgment of postoperative treatment;(3)1-year follow-up period was not enough to reflect the long-term low back pain and adjacent vertebral fractures.

In our study, PCVP already had clinical advantages for PVP, but it still had its shortcomings. Although some studies had shown that PVP and PKP as minimally invasive surgery for the treatment of OVCF will not increase the incidence of new vertebral fractures[28]. However, some studies had shown that vertebroplasty itself became a risk factor for new fractures when vertebroplasty was chosen[29]. In percutaneous balloon kyphoplasty (PKP) surgery, bone cement is easy to spread to non-fracture area and endplate bone tissue through trabecular space, which will make bone cement spread to non-fracture area and endplate bone tissue more easily. The wider the range of bone cement support, the closer the fusion with the surrounding cancellous bone. Balloon dilatation in kyphosis can better expand the cavity to infuse bone cement, and the dispersion of bone cement will be disturbed by the tight barrier formed by the formation of cancellous bone driven by balloon. Compared with the patients treated with PVP, to a large extent, the destruction of the microstructure of cancellous trabeculae by PKPleads to secondary fractures of adjacent vertebrae due to their uneven stress[30]. Due to the rotation of the conveying catheter during the PCVP, the cancellous bone is broken and squeezed through the curved segment in front of it, although it can obtain a better diffusion effect of bone cement. It may increase the risk of new adjacent vertebral fractures in patients with osteoporotic vertebral compression fractures. Although our study shown that PCVP does not increase the risk of adjacent vertebral fractures, we believed that longer follow-up was needed to verify this conclusion.

Meanwhile, studies had noted the relationship between bone cement injection and the clinical outcome of OVCFs treatment. Previous study had shown that the amount of bone cement injection was the key factor to improve mechanical stability by filling bone trabecula. The ideal value of bone cement significantly affects the relief of pain and the prevention of cement-related complications[31]. The appropriate amount of bone cement is helpful to directly improve the stiffness and strength of the surgical vertebral body, and stabilize the vertebral body. Increasing the amount of bone cement perfusion helps to maximize the recovery of compressed vertebrae and effectively reduce the degree of pain; low-dose bone cement may not provide enough support to restore compressed vertebrae and correct kyphosis. Therefore, a reasonable range of high-dose bone cement can reduce the risk of vertebral re-fracture, but it is not the more cement the better. Many clinicians have found that too much bone cement can cause cement leakage and damage the nerve root of the spinal cord. Liebschner et al believed that 3.5mL (15% of the fracture vertebral volume) bone cement can fully restore the strength of the fractured vertebral body[32]. More detailed reports indicated that the upper thoracic vertebrae need 2.5-3.0mL bone cement, the thoracolumbar vertebrae need 3.0-4.0mL bone cement, and the lumbar vertebrae need 6.0-8.0mL bone cement[33]. More study had established a reliable biomechanical model of lumbar fracture through the numerical simulation of CT scan data. In that model, spinal fractures and vertebroplasty may cause biomechanical changes in adjacent vertebrae. With the increased of the amount of bone cement injection, the influence of biomechanical changes may increase significantly. In which study, the best injection amount for PVP was 4mL[34]. However, in our study, the amount of bone cement perfusion was not strictly controlled according to the different injured vertebrae of the patients, so it was impossible to analyze the effects of the two treatment methods after accurate infusion of bone cement in different vertebral bodies. this may also be one of the reasons that affect bone cement leakage or long-term complications such as adjacent vertebral fractures. But, it was certain that PCVP can theoretically obtain a larger injection volume of bone cement than PVP, but its safe range of injection volume still needs more in-depth study.

There are several limitations in our study. Firstly, the main deficiency of the study was that the number of cases is insufficient, the bone cement leakage can not be classified, and the relationship between bone cement perfusion mode and various types of bone cement leakage could not be analyzed. Secondly, the follow-up to only 1 year after operation might not be sufficient to inquiry the long-term complications of PCVP. Finally, although the area of bone cement observed by X-ray is always measured by the same experienced radiologist, the distribution of bone cement in the fracture vertebral body is not calculated accurately, because it does not seem to be rigorous to rely solely on X-rays to evaluate the distribution of bone cement. A new evaluation methods and calculation methods need be applied to our further clinical exploration.

Conclusion

In summary, The results show that PCVP has beneficial to the uniform distribution of bone cement in the fracture vertebrae and reduce the leakage of bone cement, and the curative effect is not inferior to that of PVP. This is a successful exploration of the improvement of surgical methods.

Declarations

Compliance with Ethical Standards

None disclosure of potential conflicts of interest

Funding

This research was supported by Special funds of municipal finance "Hefei Health Applied Medical Research Project" of Anhui Province, China, (Grant No.172).

Conflict of Interest

The authors declare no competing financial interests

Ethical approval

We confirm that all methods were carried out in accordance with the relevant guidelines and regulations of the Ethics Committee of Hefei First people's Hospital. We confirmed that all experimental schemes had been approved by the Hospital Ethics Committee of Hefei first people's Hospital, and that all procedures carried out in this study, including human participants, comply with the ethical standards of the Institutional Research Committee, and comply with the 1964 Helsinki Declaration and its subsequent amendments or similar ethical standards.

Informed consent

All patients signed an informed consent before participating in this study.

References

1. Ballane G, Cauley JA, Luckey MM, El-Hajj FG (2017) Worldwide prevalence and incidence of osteoporotic vertebral fractures. Osteoporos Int 28:1531-1542
2. Kan SL, Yuan ZF, Chen LX, Sun JC, Ning GZ, Feng SQ (2017) Which is best for osteoporotic vertebral compression fractures: balloon kyphoplasty, percutaneous vertebroplasty or non-surgical treatment? A study protocol for a Bayesian network meta-analysis. BMJ Open 7:e12937
3. Feng L, Feng C, Chen J, Wu Y, Shen JM (2018) The risk factors of vertebral refracture after kyphoplasty in patients with osteoporotic vertebral compression fractures: a study protocol for a prospective cohort study. BMC Musculoskelet

Disord 19:195

4. Shi C, Zhang M, Cheng AY, Huang ZF (2018) Percutaneous kyphoplasty combined with zoledronic acid infusion in the treatment of osteoporotic thoracolumbar fractures in the elderly. Clin Interv Aging 13:853-861
5. Zhao WT, Qin DP, Zhang XG, Wang ZP, Tong Z (2018) Biomechanical effects of different vertebral heights after augmentation of osteoporotic vertebral compression fracture: a three-dimensional finite element analysis. J Orthop Surg Res 13:32
6. Zhang H, Xu C, Zhang T, Gao Z, Zhang T (2017) Does Percutaneous Vertebroplasty or Balloon Kyphoplasty for Osteoporotic Vertebral Compression Fractures Increase the Incidence of New Vertebral Fractures? A Meta-Analysis. Pain Physician 20:E13-E28
7. Zhou T, Lin H, Wang H, Chen X, He F (2017) Comparative study on the biomechanics between improved PVP and traditional PKP in the treatment of vertebral peripheral wall damage-type OVCF. Exp Ther Med 14:575-580
8. Yu WB, Jiang XB, Liang D, Xu WX, Ye LQ, Wang J (2019) Risk factors and score for recollapse of the augmented vertebrae after percutaneous vertebroplasty in osteoporotic vertebral compression fractures. Osteoporos Int 30:423-430
9. Mansour A, Abdel-Razeq N, Abuali H, Makoseh M, Shaikh-Salem N, Abushalha K, Salah S (2018) Cement pulmonary embolism as a complication of percutaneous vertebroplasty in cancer patients. Cancer Imaging 18:5
10. Yi HJ, Jeong JH, Im SB, Lee JK (2016) Percutaneous Vertebroplasty versus Conservative Treatment for One Level Thoracolumbar Osteoporotic Compression Fracture: Results of an Over 2-Year Follow-up. Pain Physician 19:E743-E750
11. Saracen A, Kotwica Z (2016) Complications of percutaneous vertebroplasty: An analysis of 1100 procedures performed in 616 patients. Medicine (Baltimore) 95:e3850
12. Grasso G (2018) Does Optimal Volume Fraction in Percutaneous Vertebroplasty Prevent Cement Leakage? World Neurosurg 116:489-490
13. Takura T, Yoshimatsu M, Sugimori H, Takizawa K, Furumatsu Y, Ikeda H, Kato H, Ogawa Y, Hamaguchi S, Fujikawa A, Satoh T, Nakajima Y (2017) Cost-Effectiveness Analysis of Percutaneous Vertebroplasty for Osteoporotic Compression Fractures. Clin Spine Surg 30:E205-E210
14. Sun H, Lu PP, Liu YJ, Yang X, Zhou PH, Shen XF, Sun SW, Yang H (2016) Can Unilateral Kyphoplasty Replace Bilateral Kyphoplasty in Treatment of Osteoporotic Vertebral Compression Fractures? A Systematic Review and Meta-analysis. Pain Physician 19:551-563
15. Firanescu CE, de Vries J, Lodder P, Schoemaker MC, Smeets AJ, Donga E, Juttmann JR, Klazen C, Elgersma O, Jansen FH, van der Horst I, Blonk M, Venmans A, Lohle P (2019) Percutaneous Vertebroplasty is no Risk Factor for New Vertebral Fractures and Protects Against Further Height Loss (VERTOS IV). Cardiovasc Intervent Radiol 42:991-1000
16. Soon WC, Mathew RK, Timothy J (2015) Comparison of vertebroplasty using directional versus straight needle. Acta Radiol Open 4:525084300
17. Zhou X, Meng X, Zhu H, Zhu Y, Yuan W (2019) Early versus late percutaneous kyphoplasty for treating osteoporotic vertebral compression fracture: A retrospective study. Clin Neurol Neurosurg 180:101-105
18. Chang M, Zhang C, Shi J, Liang J, Yuan X, Huang H, Li D, Yang B, Tang S (2020) Comparison Between 7 Osteoporotic Vertebral Compression Fractures Treatments: Systematic Review and Network Meta-analysis. World Neurosurg
19. Gao C, Zong M, Wang WT, Xu L, Cao D, Zou YF (2018) Analysis of risk factors causing short-term cement leakages and long-term complications after percutaneous kyphoplasty for osteoporotic vertebral compression fractures. Acta Radiol 59:577-585
20. Ma X, Xing D, Ma J, Wang J, Chen Y, Xu W, Yang Y, Ma B, Zhu S (2013) Risk factors for new vertebral compression fractures after percutaneous vertebroplasty: qualitative evidence synthesized from a systematic review. Spine (Phila Pa 1976) 38:E713-E722
21. Zhang H, Xuan J, Chen TH, Chen ZX, Sun LJ, Tian NF, Zhang XL, Wang XY, Lin Y, Wu YS (2020) Projection of the Most Anterior Line of the Spinal Canal on Lateral Radiograph: An Anatomic Study for Percutaneous Kyphoplasty and

Percutaneous Vertebroplasty. J Invest Surg 33:134-140
22. He CJ, Liu GD (2018) Comparison of the Efficacy and Safety of Bone-filling Mesh Container and Simple Percutaneous Balloon Kyphoplasty in the Treatment of Osteoporotic Vertebral Compression Fractures. Pain Physician 21:259-268
23. Liebschner MA, Rosenberg WS, Keaveny TM (2001) Effects of bone cement volume and distribution on vertebral stiffness after vertebroplasty. Spine (Phila Pa 1976) 26:1547-1554
24. Rho YJ, Choe WJ, Chun YI (2012) Risk factors predicting the new symptomatic vertebral compression fractures after percutaneous vertebroplasty or kyphoplasty. Eur Spine J 21:905-911
25. Baek SW, Kim C, Chang H (2015) The relationship between the spinopelvic balance and the incidence of adjacent vertebral fractures following percutaneous vertebroplasty. Osteoporos Int 26:1507-1513
26. Tan L, Wen B, Guo Z, Chen Z (2020) The effect of bone cement distribution on the outcome of percutaneous Vertebroplasty: a case cohort study. BMC Musculoskelet Disord 21:541
27. Liu H, Zhang J, Liang X, Qian Z, Zhou Z, Lu H, Bou EH, Meng B, Mao H, Yang H, Liu T (2019) Distribution Pattern Making Sense: Patients Achieve Rapider Pain Relief with Confluent Rather Than Separated Bilateral Cement in Percutaneous Kyphoplasty for Osteoporotic Vertebral Compression Fractures. World Neurosurg 126:e1190-e1196
28. Zhang H, Xu C, Zhang T, Gao Z, Zhang T (2017) Does Percutaneous Vertebroplasty or Balloon Kyphoplasty for Osteoporotic Vertebral Compression Fractures Increase the Incidence of New Vertebral Fractures? A Meta-Analysis. Pain Physician 20:E13-E28
29. Lee BG, Choi JH, Kim DY, Choi WR, Lee SG, Kang CN (2019) Risk factors for newly developed osteoporotic vertebral compression fractures following treatment for osteoporotic vertebral compression fractures. Spine J 19:301-305
30. Li YX, Guo DQ, Zhang SC, Liang, Yuan K, Mo GY, Li DX, Guo HZ, Tang Y, Luo PJ (2018) Risk factor analysis for re-collapse of cemented vertebrae after percutaneous vertebroplasty (PVP) or percutaneous kyphoplasty (PKP). Int Orthop 42:2131-2139
31. Fu Z, Hu X, Wu Y, Zhou Z (2016) Is There a Dose-Response Relationship of Cement Volume With Cement Leakage and Pain Relief After Vertebroplasty? Dose Response 14:714835597
32. Liebschner MA, Rosenberg WS, Keaveny TM (2001) Effects of bone cement volume and distribution on vertebral stiffness after vertebroplasty. Spine (Phila Pa 1976) 26:1547-1554
33. Belkoff SM, Mathis JM, Jasper LE, Deramond H (2001) The biomechanics of vertebroplasty. The effect of cement volume on mechanical behavior. Spine (Phila Pa 1976) 26:1537-1541
34. Wang D, Li Y, Yin H, Li J, Qu J, Jiang M, Tian J (2020) Three-dimensional finite element analysis of optimal distribution model of vertebroplasty. Ann Palliat Med 9:1062-1072

Tables

Table 1 Material characteristics of implants

Project	Mendec Spine Resin and Kit
Production enterprise	Tecres S.P.A
Approval number	National Food and Drug Administration (Import) word 2010 No. 3650613
Constituent component	Polymethyl methacrylate; methyl methacrylate monomer; hydroquinone; N-dimethyl polymerized toluidine; barium sulfate; benzoyl peroxide; liquid
Material appearance	Contains powder containers and liquid vials
Indication	It is suitable for pathological vertebral body filling related to vertebral compression fracture, tumor bone metastasis and myeloma.
Biocompatibility	Easy to shape, fast curing at room temperature, exothermic in the curing process, good compatibility with bone tissue
Adverse reaction	Cardiac arrest, pulmonary embolism, temporary hypotension, hemorrhage and hematoma, infection, bone cement leakage

Table 2 The relevant data of patients

Group	Age(years)	Sex(male/female)	Injured vertebral body*		
			Thoracic segment	Thoracolumbar segment	Lumbar segment
PCVP (n=50)	74.80±9.16	6/44	8	37	5
PVP (n=50)	75.56±8.47	12/38	4	37	9
P-Value	0.668	0.118	0.290		

Data shown as mean ± sD or number. Injured vertebral body was divided into thoracic segment, lumbar segment, thoracolumbar segment.

Table 3 Comparison of surgical conditions between the two groups

Group	Operation time (min)	Intraoperative fluoroscopy	Amount of bone cement（ml）
PCVP(n=50)	36.22±11.98	30.36±6.76	5.53±1.53
PVP (n=50)	38.72±10.71	32.96±10.54	5.83±1.50
P-Value	0.274	0.145	0.340

Data shown as mean ± sD or number.

Table 4 Radiological results between the two groups

Group	bone cement leakage	The distribution of bone cement			
		A	B	C	D
PCVP(n=50)	6	1	1	28	20
PVP (n=50)	17	11	12	21	6
P-Value	0.09	0.000			

Table 5 Radiological results between the two groups (Continued)

Group	Height of anterior edge of injured vertebral body		Adjacent vertebral body re-fracture
	presurgery	1 day postsurgery	
PCVP(n=50)	13.72±3.57	20.29±3.61*	5
PVP (n=50)	13.36±3.52	20.53±3.16*	2
P-Value	0.617	0.731	0.145

Data shown as mean ± sD or number.

A:unilateral distribution that did not cross the midline of vertebral body ; B:unilateral filling that reached the midline of vertebral body ; C:bilateral filling that crossed the midline of vertebral body ; D: bilateral filling that crossed the midline of vertebral body and reached bilateral filling 3/5of vertebral body.

*:The height of the anterior edge of the vertebral body recovered significantly in both groups before and after operation. P<0.05.

Table 6 Comparison of VAS and ODI between the two groups

Group	VAS			ODI		
	presurgery	1 day postsurgery	1 year postsurgery	presurgery	1 day postsurgery	1 year postsurgery
PCVP(n=50)	7.13±0.89	2.92±0.81*	2.06±0.79*	74.54±5.37	32.12±4.66*	32.20±10.18*
PVP (n=50)	7.22±0.74	2.58±1.05*	2.26±1.03*	72.70±5.21±	33.44±2.70*	28.96±1.81*
P-Value	0.582	0.072	0.278	0.085	0.086	0.164

Data shown as mean ± sD or number.

*: VAS score and ODI score were significantly improved in both groups at 1 day and 1 year postsurgery,P<0.05.

Figures

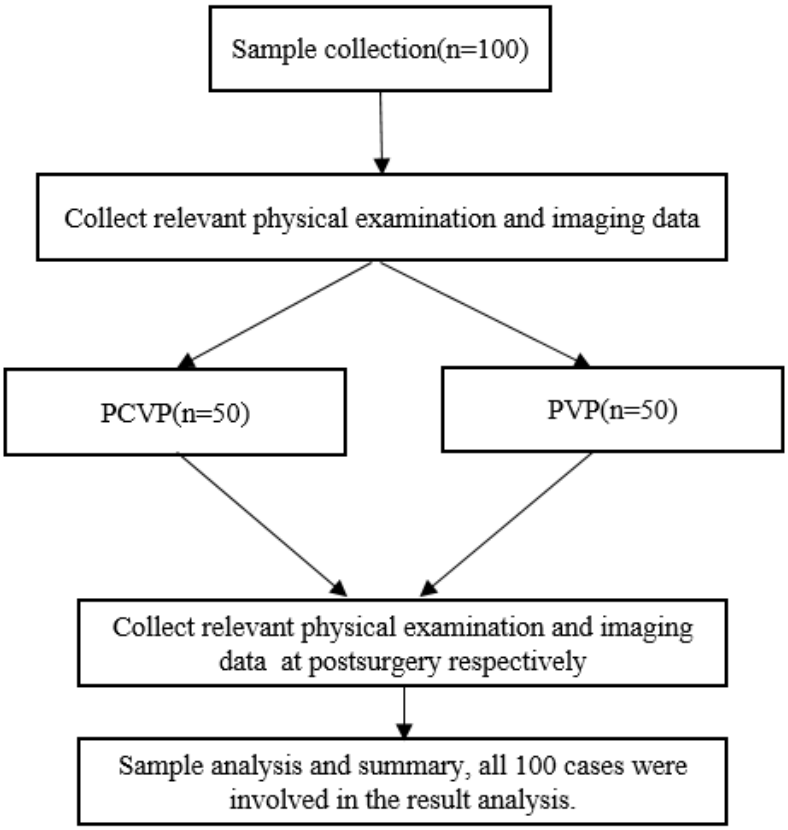

Figure 1

Research process

Figure 2

Representative images of surgical instruments using in percutaneous curved vertebroplasty, showing: (a) from left to right:Conveying conduit; Mixing and injection device; Sleeve; Puncture needle; (b) Preoperative instrument preparation;

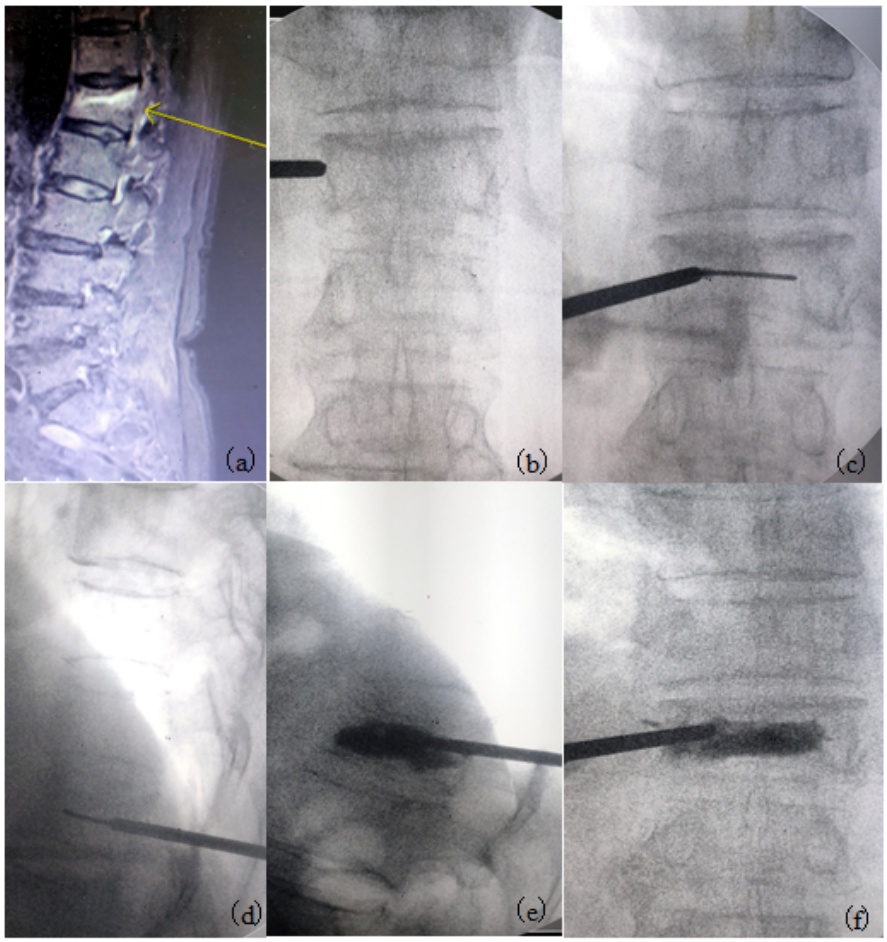

Figure 3

Representative post-treatment images from a 74-year-old female patient in the PCVP group: (a) MRI shows lumbar fracture; (b) ~(d) Intraoperative localized puncture□□e)~(f):In the positive and lateral position postsurgery, the filling of bone cement was satisfactory, and there was no obvious bone cement leakage.

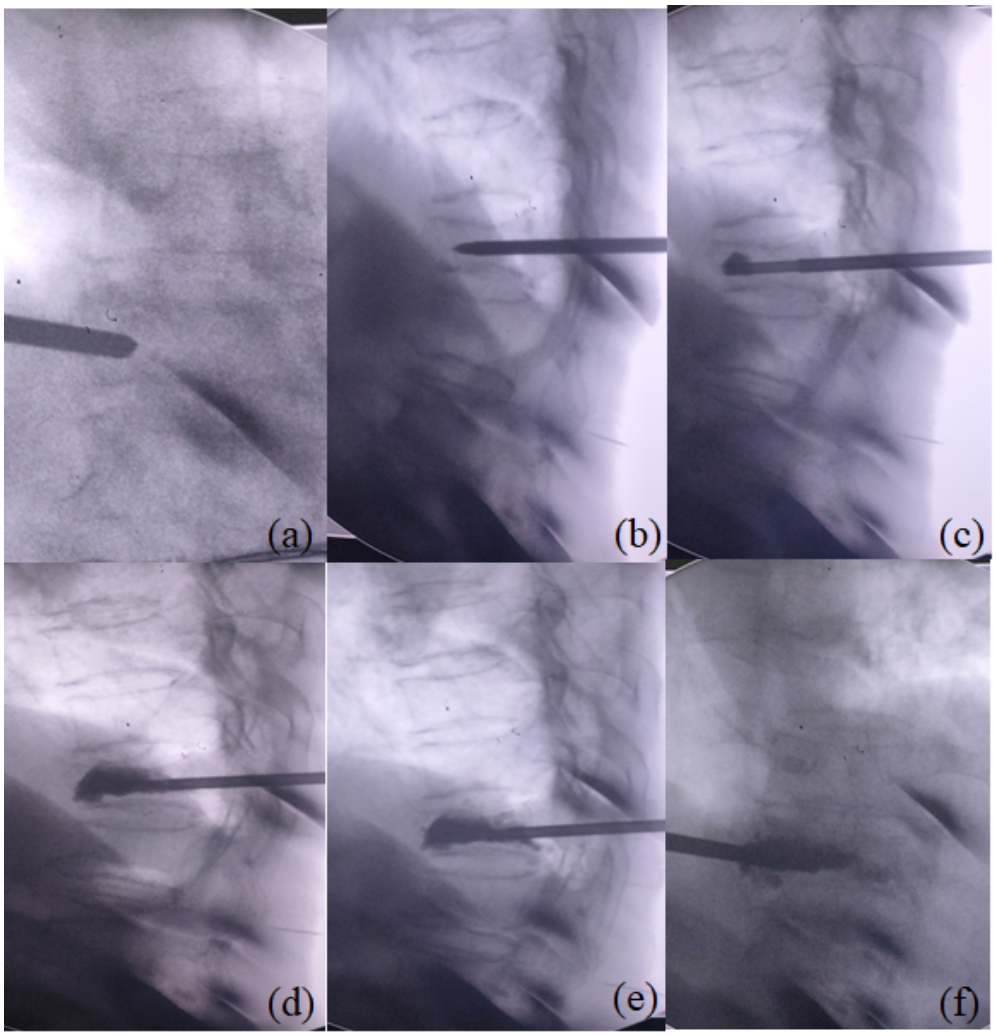

Figure 4

Representative post-treatment images from a 89-year-old female patient in the PVP group: (a)~(b) Intraoperative localized puncture; (c)~(d) : Transchannel injection of bone cement;(e)~(f):In the positive and lateral position postsurgery, there was no obvious bone cement leakage, but the filling of bone cement was not satisfactory.