

A biomechanical analysis of four anterior cervical techniques to treating multilevel cervical spondylotic myelopathy: a finite element study

Zhonghai Li (✉ lizhonghaispine@126.com)

First Affiliated Hospital of Dalian Medical University

Hui Liu

Seventh Medical Center of PLA General Hospital

Ming Yang

First Affiliated Hospital of Dalian Medical University

Wentao Zhang

First Affiliated Hospital of Dalian Medical University

Research Article

Keywords: Multilevel cervical spondylotic myelopathy, Anterior cervical corpectomy and fusion, Anterior cervical discectomy and fusion, Biomechanics, Finite element analysis

Posted Date: January 4th, 2021

DOI: <https://doi.org/10.21203/rs.3.rs-136245/v1>

License:  This work is licensed under a Creative Commons Attribution 4.0 International License.

[Read Full License](#)

Version of Record: A version of this preprint was published on March 15th, 2021. See the published version at <https://doi.org/10.1186/s12891-021-04150-7>.

A biomechanical analysis of four anterior cervical techniques to treating multilevel cervical spondylotic myelopathy: a finite element study

Zhonghai Li MD^{1,2*#}, Hui Liu^{3#}, Ming Yang^{1,2}, Wentao Zhang^{1,2}

¹ Department of Orthopaedics, First Affiliated Hospital of Dalian Medical University, Dalian, the People's Republic of China

² Key Laboratory of Molecular Mechanism for Repair and Remodeling of Orthopaedic Diseases, Liaoning Province, the People's Republic of China

³ Seventh Medical Center of PLA General Hospital, Beijing, the People's Republic of China

Zhonghai and Hui Liu contributed equally to the manuscript and should be considered co-first authors.

* Corresponding Author: Zhonghai Li MD

Tel: 86-18098876419 Fax: 86-411-83635963 E-mail: lizhonghaispine@126.com

Abstract

Background: The decision to treat multilevel cervical spondylotic myelopathy (MCSM) remains controversial. The purpose of this study is to compare the biomechanical characteristics of the intervertebral discs at the adjacent segments and internal fixation, and to provide scientific experimental evidence for surgical treatment of MCSM.

Methods: An intact C2-C7 cervical spine model was developed and validated. Four additional models were developed from the fusion model, including multilevel anterior cervical discectomy and fusion (mACDF), anterior cervical corpectomy and fusion (ACCF), hybrid decompression and fusion (HDF), and mACDF with cage alone (mACDF-CA). Biomechanical characteristics on the plate and the disc of adjacent levels (C2/3, C6/7) were comparatively analyzed.

Results: Of the four models, stress on the upper (C2/3) adjacent intervertebral disc was the lowest in the mACDF-CA group and highest in the ACCF group. Stress on the intervertebral discs at adjacent segments was higher for the upper C2/3 than the lower C6/7 intervertebral disc. In all models, the mACDF-CA group had the lowest stress on the intervertebral disc, while the ACCF group had the highest stress. In the three surgical models with titanium plate fixation (mACDF, ACCF, and HDF), the ACCF group had the highest stress at the titanium plate-screw interface, while the mACDF group had the lowest stress.

Conclusion: Among the four anterior cervical reconstructive techniques for MCSM, mACDF-CA makes little effect on the adjacent disc stress, which might reduce the incidence of adjacent segment degeneration (ASD) after fusion. However, the accompanying risk of the increased incidence of cage subsidence should never be neglected.

Keywords: Multilevel cervical spondylotic myelopathy; Anterior cervical corpectomy and fusion, Anterior cervical discectomy and fusion; Biomechanics; Finite element analysis

Background

Multilevel cervical spondylotic myelopathy (MCSM) refers to cervical spondylosis diagnosed by imaging with three or more levels of contiguous or noncontiguous cervical intervertebral disc degeneration and secondary changes, which causes compression on the dural sac and spinal cord, and which results in corresponding clinical manifestations. Owing to severe spinal cord compression in most cases, MCSM often requires surgery to relieve the compression. Consensus has currently been reached on the surgical management of CSM involving one or two mobile segments; however, controversy remains regarding the selection of surgical procedures for treatment of MCSM.[1-3]

An anterior, posterior, or combined anterior-posterior approach can be employed according to the clinical situation and the experience of surgeons, and each approach has its unique advantages and disadvantages.[3-12] The anterior techniques such as multilevel anterior cervical discectomy and fusion (mACDF), anterior cervical corpectomy and fusion (ACCF), and hybrid decompression and fusion (HDF) have been proved to be reliable and effective in spinal cord decompression, and sagittal alignment restoration and maintenance thus achieved a good clinical outcome. To increase the stability of cervical vertebrae and the fusion rate of bone graft after surgery, anterior cervical titanium plate fixation is widely used. Nevertheless, the anterior titanium plate protrudes from the anterior margin of the cervical vertebral body, causing relatively strong friction with soft tissue in the anterior cervical region. As a result, complications such as foreign body sensation in the anterior cervical region, dysphagia, and esophageal injury have been found after long-term follow-up.[13-15] Meanwhile, some researchers argue that the use of anterior cervical titanium plate increases the incidence of adjacent segment degeneration (ASD).[16-18]

To prevent complications associated with anterior cervical titanium plates and maintain the benefits of interbody cages with anterior plating system, a new zero-profile, stand-alone device (Fidji cervical cage,

Abbott Spine, Bordeaux, France) has been designed and used clinically.[19] In recent years, we performed mACDF using Fidji cervical cages alone (mACDF-CA) for the treatment of MCSM. In these studies, we found that mACDF-CA was associated with shorter operation time, less blood loss and cost of index surgery, and lower dysphagia incidence, and satisfactory results were achieved in preliminary clinical applications.[8, 9, 20] Despite these findings, biomechanical studies assessing anterior techniques for the treatment of MCSM appear only rarely in the literature, and no one compares mACDF-CA to other anterior techniques in multilevel constructs. A biomechanical study using finite element (FE) analysis can help to elucidate the complex biomechanical properties of the cervical spine, including stresses, strains, and loads under different conditions.[21-23] This study was a biomechanical comparative analysis of four anterior cervical techniques based on FE model. The biomechanical characteristics of the intervertebral discs at the adjacent segments and internal fixation were analyzed to provide scientific experimental evidence for surgical treatment of MCSM.

Methods

Development of FE model (C2-C7)

A 3-dimensional FE model of a normal C2-C7 segment was created in this study. Geometric details of the human cervical spine (C2-C7) were obtained from a high-resolution computed tomographic scan of a healthy Chinese male volunteer (age, 30 yrs; height, 182 cm; weight, 76 kg) in our simulation. This study was approved by the medical ethics committee of First Affiliated Hospital of Dalian Medical University (PJ-KS-KY-2020-55). All procedures were followed in accordance with relevant guidelines. The subject's skull and vertical spine were scanned using a CT scanner (Brilliance 64, Philips Electronics, Netherlands). The final CT images had a resolution of 0.54 mm × 0.54 mm and the slice interval of 0.625 mm.

Within the software Mimics 17.0 (Materialise Inc., Leuven, Belgium), these images were segmented

and translated to various 3D solid volumes of all vertebrae. Then, the solid volumes were created to fill the spaces between the vertebrae to create intervertebral discs. The final constructs were exported as STL format files. The solid volume was then, respectively, imported into the software Geomagic Studio 12.0 (Geomagic Inc., USA), in which it was converted into a non-uniform rational B-spline surface geometry structure. The model components included cortical bone, cancellous bone, bony posterior elements, annulus fibrosus, nucleus pulposus, posterior facets, end plates, anterior longitudinal ligament, posterior longitudinal ligament, ligamentum flavum, interspinous ligament, and capsular ligaments (Fig. 1). To reduce the resources required for creating a mesh of the complex spinal geometry, ABAQUS 6.13 (Abaqus Inc., USA) was used to generate a tetrahedral mesh on the vertebrae and a hexahedral mesh on the discs. The material properties were assumed to be homogeneous and isotropic according to the published literature.[23-25] The initial material properties were based on previous studies as shown in Table 1.

Validation of model

Three-dimensional surface contact elements were used for the contact and sliding effect between the articular facets. Statistical analysis was performed by applying 1.0 Nm of flexion, extension, axial rotation, and lateral bending moments with 73.6 N of axial compression superior to C2. The boundary condition was simulated by fixing the inferior surface of the C7 vertebra under constraint of different degrees of freedom. The validity of the FE model was verified by comparing the predicted data with the results reported in the literature.[26-28]

Surgery simulation

First, a graphic of the titanium plates, screws, and PEEK interbody cages was drawn using the pre-processor modeling function of the FE software, ABAQUS/CAE. Small portions of the curved surfaces and threads were removed because these were considered not to affect the mechanical performance analysis,

and rough models were constructed according to the structures of the titanium plates, screws, and cages.

mACDF model: The C3/4, C4/5, and C5/6 intervertebral discs were resected and a PEEK interbody cage was placed into each intervertebral disc space. A common node was used to define the constraint relationship between the cage and the upper and lower endplates, to simulate bony fusion. A titanium plate of the appropriate length was placed on the anterior C3-C6 vertebral bodies, and both ends of the plate were fixed with two monocortical screws.

ACCF model: The C3/4, C4/5, and C5/6 intervertebral discs were resected followed by corpectomy of the C4 and C5 vertebral bodies. A bone graft with a cross-sectional area accounting for 50% of the vertebral endplate area was placed on the midline between the C3 and C6 vertebral bodies. The anterior margin of the bone graft was set 1 mm from the anterior margin of the vertebral bodies. Rigid fixation was applied between the bone graft and the upper and lower endplates to simulate postoperative bony fusion. A titanium plate of the appropriate length was placed on the anterior C3-C6 vertebral bodies, with both ends of the plate fixed by two monocortical screws.

HDF model: The C3/4, C4/5, and C5/6 intervertebral discs were resected, followed by corpectomy of the C4 vertebral body with both sides retained. A bone graft of the appropriate length was placed between the C3 and C5 vertebral bodies, 1 mm from the anterior margin of the vertebral bodies and centered between the left and right vertebral bodies. A PEEK interbody cage was placed in the C5/6 intervertebral disc space, and an anterior titanium plate of the appropriate length was placed on the anterior C3-C5 vertebral bodies. Both ends of the titanium plate were fixed with two monocortical screws.

mACDF-CA model: The C3/4, C4/5, and C5/6 intervertebral discs were resected and a PEEK interbody cage was placed in each intervertebral disc space. This technique did not require auxiliary anterior titanium plate fixation (Fig. 2).

Results

Model validation

The comparison between in vitro data and predicted value in the FE model are shown in Fig 3. All the predicted responses were consistent with the results of in vitro experiments reported in the literature.

Stress on the C2/3 intervertebral disc

Of the four anterior cervical approaches, stress on the upper (C2/3) adjacent intervertebral disc was

the lowest in the mACDF-CA group and highest in the ACCF group during flexion, extension, lateral bending, and rotation. Compared with the mACDF-CA group, stress on the C2/3 intervertebral disc in the mACDF, ACCF, and HDF groups increased by 23%, 77%, and 72% during extension; by 42%, 49%, and 46% during lateral bending; and by 18%, 104%, and 105% during rotation, respectively (Fig. 4).

Stress on the C6/7 intervertebral disc

With the four anterior cervical approaches, stress on the intervertebral discs at adjacent segments was higher for the upper C2/3 than the lower C6/7 intervertebral disc during flexion, extension, lateral bending, and rotation. In all models, the mACDF-CA group had the lowest stress on the intervertebral disc, while the ACCF group had the highest stress. Compared with the mACDF-CA group, stress on the lower (C6/7) adjacent intervertebral disc in the mACDF, ACCF, and HDF groups increased by 17%, 71%, and 22% during flexion; by 5%, 68%, and 16% during extension; by 10%, 72%, and 44% during lateral bending; and by 9%, 15%, and 10% during rotation, respectively (Fig. 5).

Stress at the titanium plate–screw interface

In the three surgical models with titanium plate fixation (mACDF, ACCF, and HDF), stress at the titanium plate–screw interface was highest under flexion load and lowest under extension load. Of the three models, the ACCF group had the highest stress at the interface, while the mACDF group had the lowest stress (Fig. 6).

Discussion

Cervical spondylosis is a common disease in middle-aged and older people, for which surgery is a major treatment. Anterior cervical decompression and bone graft fusion is considered the standard surgical procedure for one- or two-level cervical spondylosis. However, for multilevel (three or more level) cervical spondylosis, controversy remains over the surgical approach.[3-10] As the etiological factors of MCSM usually arise from anterior degenerated intervertebral discs and osteophytes, it is challenging to remove the anterior compressive material through a simple posterior surgery, which cannot achieve effective

decompression. Furthermore, posterior surgery cannot fully restore the physiological curvature of the cervical spine. Therefore, many researchers choose anterior surgery rather than posterior surgery.[29] More often than not, multiple levels are involved and complicate the surgical management. Anterior, posterior, and circumferential procedures have all been advocated. Even when the discussion is limited to anterior procedures, there is no agreement as to which reconstruction technique is best after multilevel anterior cervical decompression.[1, 3, 4, 8, 9, 11, 16, 29-35]

Anterior surgical approaches mainly include ACCF, ACDF, and HDF. Among the several anterior surgical approaches for MCSM, each has advantages and disadvantages.[1-4, 8, 9, 11, 16, 29-40] In conventional ACDF surgery, osteophytes and degenerated intervertebral discs are removed from the posterior upper and lower margins of the vertebral body through an intervertebral space approach. This approach effectively removes the direct compression factors and provides good stability as well as multipoint expansion for better recovery and preservation of the physiological curvature of the cervical spine. Therefore, this approach is especially suitable for patients with straight or kyphotic curvature of the cervical spine.[11, 30, 41] However, this surgery involves a long operation time, has a limited field of view, and requires high surgical skills, making it difficult to ensure complete decompression in most cases.[13-15]

ACCF involves long-segment decompression with slotting followed by long titanium mesh or autogenous bone grafting. The advantage of this approach is that it can be performed under direct vision, with a wider intraoperative view and larger operative field, and that it allows more extensive and thorough decompression.[10, 32, 34, 36-38, 42, 43] The resected vertebral body can be used as a bone autograft, thus preventing the risk associated with bone allografts and complications, such as pain in the bone removal area. Moreover, the size of the graft–host bone interface requiring postoperative healing is reduced compared with that in ACDF, which is beneficial to improve the fusion rate after surgery. The

disadvantage of ACCF is that it results in considerable damage to the structural stability of the anterior and middle columns.[1, 4, 8, 16, 30, 44] Furthermore, iliac bone autografts collapse easily, and may become displaced or form a false joint. Long titanium mesh or fibular autografts are not conducive to restoring physiological lordosis of the cervical spine. In addition, owing to the multiple fixed segments and long moment arm, the monocortically-fixed screws at both ends of the titanium plate bear considerable stress, which may lead to postoperative complications, such as loosening and displacement. If the implanted bone is too long, surgical difficulty increases. Moreover, the fusion rate of long-segment bone grafting is substantially reduced, and the complication rate increases. ACCF surgery is mainly suitable for cases with lesions extending to the posterior vertebral body, extensive and severe osteophyte formation and vertebral body deformity in the anterior spinal cord, and contiguous stenosis of adjacent intervertebral spaces causing spinal cord compression.

Another anterior surgical approach is HDF, namely ACCF combined with ACDF.[3, 12] Generally, the most severely compressed vertebral body is removed in HDF, and discectomy is performed only at the less compressed sites, which reduces the number of resected vertebral bodies. While achieving full decompression, this approach also reduces damage to the anterior vertebral column, which shortens the length of the bone graft, reduces the graft–host bone interface, and theoretically, lowers the probability of upper false joint formation. However, this approach is also associated with loss of cervical lordosis and bone graft–titanium plate-related complications.

Anterior titanium plating is required with conventional mACDF, ACCF, and HDF to treat MCSM. The application of an anterior locking titanium plate can effectively improve the stability and firmness of the fused cervical spine and greatly increase the fusion rate. In addition, using a plate prevents loss of intervertebral height, while the physiological curvature of the cervical spine is maintained, to some extent.

However, with increasing plate length, stress at the plate–screw interface increases correspondingly, which increases the risk of implant loosening, displacement, and fracture. Moreover, following the application of a long-segment titanium plate, patients are prone to foreign body sensation, dysphagia, and even esophageal fistula, while the incidence of ASD is also increased.[13-18] In the present study, our biomechanical results showed that among the three surgical models involving titanium plate fixation (mACDF, ACCF, and HDF groups), the ACCF group had the highest stress at the plate–screw interface, the HDF group had higher stress than the mACDF group, and the mACDF group had the lowest stress. These results revealed that the risk of titanium plate or screw loosening, displacement, and fracture was the highest following ACCF, which is similar to clinical results. Furthermore, we found that stress in the intervertebral fusion cage also differed substantially between the mACDF and mACDF-CA groups. The mACDF-CA group showed markedly higher stress than the mACDF group, which may indicate a higher risk of fusion cage subsidence in the mACDF-CA group compared with the mACDF group. However, this speculation must be verified with long-term follow-up results from controlled clinical trials with large sample sizes.

To overcome the problems associated with anterior cervical titanium plating, a novel intervertebral fusion system that integrates support, fixation, and fusion; does not protrude from the anterior margin of the vertebral body; and effectively reduces surgical complications has been designed and applied clinically. This system can be independently applied in ACDF surgery without requiring anterior titanium plate fixation. The system highlights establishing cervical stability while minimizing interference with adjacent tissues by the implant, and considerably reduces the incidence and severity of associated complications after surgery. The system has achieved satisfactory results in its preliminary clinical applications.[9, 19, 20, 45-49] The currently available self-stabilizing zero-profile anterior cervical interbody fusion and internal fixation

systems are the Zero-P system (Synthes, Switzerland) and the Fidji cage system (Zimmer, France). Strong evidence from basic research and clinical use have demonstrated the effectiveness of these systems.[9, 19, 20, 45-50]

ASD has always been a potential long-term complication following anterior cervical fusion, and the incidence of ASD is even higher following long-segment fusion, which has attracted increasing attention. The incidence of ASD within 10 years after primary anterior cervical surgery is 25%, and more than 15% of patients require secondary surgery owing to ASD.[16-18, 51-54] The mechanisms underpinning the development of ASD are still unclear, and the widely accepted mechanisms are local biomechanical changes in the cervical spine and natural degeneration of adjacent segments. Other risk factors are advanced age, multilevel fusion, postoperative cervical alignment change, an excessively long titanium plate, surgical injury to the adjacent intervertebral discs, and preoperative degeneration of adjacent segments. Controversy continues regarding whether differences exist in the impact of anterior cervical fusion on adjacent segments. Based on a 2-year follow-up of 218 patients undergoing single- or two-level ACCF, Park et al.[51] found that the incidence of ASD in the upper adjacent segment was markedly higher than that in the lower adjacent segment following ACCF (58% vs. 28%, respectively). In addition, Yang et al.[52] conducted a 5-year follow-up of 370 patients who underwent anterior cervical fusion without titanium plate implantation, and found that the incidence of ASD in the upper adjacent segment was considerably higher than that in the lower adjacent segment (5% vs. 1%, respectively). However, in a 5.6-year follow-up study, Koller et al.[53] found no significant difference in the incidence of ASD between the upper and lower segments adjacent to the fused segment following anterior cervical fusion (41.2% vs. 50.0%, respectively). Similarly, Goffin et al.[54] followed 25 patients for an average of 7 years and found that 24% of the patients had ASD in the upper adjacent segment, while 28% had ASD in the lower adjacent segment; the difference

between the two groups was not significant. In the present study, we found that with all four anterior cervical approaches, stress on the intervertebral discs at the adjacent segments was always higher for the upper disc compared with the lower disc under different conditions (flexion, extension, lateral bending, and rotation). This result suggests that after fusion, the upper adjacent segment was subjected to higher stress, which may accelerate dehydration and degeneration of the adjacent intervertebral disc, leading easily to ASD at this segment. A plausible reason for this difference is that the lower segment has greater mobility, which is conducive to stress load sharing; however, this hypothesis requires further clinical verification. Furthermore, we found that stress on the intervertebral discs at the adjacent segments was lowest in the mACDF-CA group and highest in the ACCF group. Biomechanically, this result revealed that mACDF-CA had the least impact on the adjacent segments compared with mACDF, HDF, and ACCF. However, whether mACDF-CA effectively prevents ASD remains to be clinically verified.

Conclusions

In summary, our biomechanical analysis indicated that among the four surgical approaches to anterior cervical fusion and internal fixation to treat MCSM, mACDF-CA had the least impact on the biomechanics of adjacent segments, and theoretically could reduce the incidence of ASD. However, this approach is associated with increased risk of fusion cage subsidence. In addition, stress at the titanium plate–screw interface was highest in the ACCF group and lowest in the mACDF group, which indicates the highest risk of titanium plate screw loosening, displacement, and fracture after ACCF. This study presented biomechanical evidence for the surgical treatment of MCSM and also provided strategies for preventing or reducing associated complications. However, further experiments and prospective clinical trials must be conducted to verify our findings.

Abbreviations

ACDF: Anterior cervical discectomy and fusion; ALL: Anterior longitudinal ligament; ASD: Adjacent segment disease; CSM: Cervical spondylotic myelopathy; CT: Computed tomography; FE: Finite element; HDF: Hybrid decompression and fusion; mACDF: Multilevel anterior cervical discectomy and fusion; mACDF-CA: Multilevel anterior cervical discectomy and fusion with cage alone; MCSM: Multilevel cervical spondylotic myelopathy; PLL: Posterior longitudinal ligament; ROM: Range of motion.

Acknowledgements

We would like to thank the person who gave assistance to this study.

Funding

This study was supported by Liaoning Revitalization Talents Program (XLYC1807131) and the Science and Technology Innovation Foundation of Dalian (2020JJ27SN070) for analysis and interpretation of data. The funders had no role in the study design, data collection and analysis, decision to publish, or preparation of the manuscript.

Availability of data and materials

Summarized data have been presented in this manuscript. The raw data for this study are located and protected at First Affiliated Hospital of Dalian Medical University. Sharing of the raw data is not suggested, because a secondary analysis is planned.

Authors' contributions

ZHL contributed to the design of the study. ZHL drafted the manuscript with the help from HL, MY and WTZ. HL and YM helped in the statistical analyses. Statistical analyses were discussed with MY and WTZ. ZHL and HL contributed to the revision. All authors have read and approved the final manuscript.

Competing interest

The authors declare that they have no competing interests.

Ethics approval and consent to participate

This study was approved by the medical ethics committee of First Affiliated Hospital of Dalian Medical University (PJ-

KS-KY-2020-55), and informed written consent was obtained.

Consent for publication

Not applicable.

Reference

1. Lin Q, Zhou X, Wang X, Cao P, Tsai N, Yuan W: A comparison of anterior cervical discectomy and corpectomy in patients with multilevel cervical spondylotic myelopathy. *European spine journal : official publication of the European Spine Society, the European Spinal Deformity Society, and the European Section of the Cervical Spine Research Society* 2012, 21(3):474-481.
2. Wei-bing X, Wun-Jer S, Gang L, Yue Z, Ming-xi J, Lian-shun J: Reconstructive techniques study after anterior decompression of multilevel cervical spondylotic myelopathy. *Journal of spinal disorders & techniques* 2009, 22(7):511-515.
3. Ryu WHA, Platt A, Deutsch H: Hybrid decompression and reconstruction technique for cervical spondylotic myelopathy: case series and review of the literature. *Journal of spine surgery* 2020, 6(1):181-195.
4. Li Z, Huang J, Zhang Z, Li F, Hou T, Hou S: A Comparison of Multilevel Anterior Cervical Discectomy and Corpectomy in Patients With 4-level Cervical Spondylotic Myelopathy: a Minimum 2-year Follow-up Study: Multilevel Anterior Cervical Discectomy. *Clinical spine surgery* 2017, 30(5):E540-E546.
5. Manzano GR, Casella G, Wang MY, Vanni S, Levi AD: A Prospective, Randomized Trial Comparing Expansile Cervical Laminoplasty and Cervical Laminectomy and Fusion for Multilevel Cervical Myelopathy. *Neurosurgery* 2012, 70(2):264-277.
6. Martin-Benlloch JA, Maruenda-Paulino JI, Barra-Pla A, Laguia-Garzarán M: Expansive laminoplasty as a method for managing cervical multilevel spondylotic myelopathy. *Spine (Phila Pa 1976)* 2003, 28(7):680-684.
7. Huang RC, Girardi FP, Poynton AR, Cammisa Jr FP: Treatment of multilevel cervical spondylotic myeloradiculopathy with posterior decompression and fusion with lateral mass plate fixation and local bone graft. *Journal of spinal disorders & techniques* 2003, 16(2):123-129.
8. Li Z, Wang H, Tang J, Ren D, Li L, Hou S, Zhang H, Hou T: Comparison of Three Reconstructive Techniques in the Surgical Management of Patients With Four-Level Cervical Spondylotic Myelopathy. *Spine (Phila Pa 1976)* 2017, 42(10):E575-E583.
9. Li Z, Zhao Y, Tang J, Ren D, Guo J, Wang H, Li L, Hou S: A comparison of a new zero-profile, stand-alone Fidji cervical cage and anterior cervical plate for single and multilevel ACDF: a minimum 2-year follow-up study. *European spine journal : official publication of the European Spine Society, the European Spinal Deformity Society, and the European Section of the Cervical Spine Research Society* 2017, 26(4):1129-1139.
10. Li Z, Guo Z, Hou S, Zhao Y, Zhong H, Yu S, Hou T: Segmental anterior cervical corpectomy and fusion with preservation of middle vertebrae in the surgical management of 4-level cervical spondylotic myelopathy. *European spine journal : official publication of the European Spine Society, the European Spinal Deformity Society, and the European Section of the Cervical Spine Research Society* 2014, 23(7):1472-1479.
11. Yue WM, Brodner W, Highland TR: Long-term results after anterior cervical discectomy and fusion with allograft and plating: a 5- to 11-year radiologic and clinical follow-up study. *Spine (Phila Pa 1976)* 2005, 30(19):2138-2144.
12. Zhou J, Li X, Zhou X, Lin H, Dong J: Anterior decompression and hybrid reconstruction with titanium mesh

- cage plus plate and self-locking stand-alone cage for the treatment of three-level cervical spondylotic myelopathy. *Journal of clinical neuroscience : official journal of the Neurosurgical Society of Australasia* 2017, 43:196-201.
13. Yee TJ, Swong K, Park P: Complications of anterior cervical spine surgery: a systematic review of the literature. *Journal of spine surgery* 2020, 6(1):302-322.
 14. Jung A, Schramm J: How to reduce recurrent laryngeal nerve palsy in anterior cervical spine surgery: a prospective observational study. *Neurosurgery* 2010, 67(1):10-15; discussion 15.
 15. Fountas KN, Kapsalaki EZ, Nikolakakos LG, Smisson HF, Johnston KW, Grigorian AA, Lee GP, Robinson JS, Jr.: Anterior cervical discectomy and fusion associated complications. *Spine (Phila Pa 1976)* 2007, 32(21):2310-2317.
 16. Lau D, Chou D, Mummaneni PV: Two-level corpectomy versus three-level discectomy for cervical spondylotic myelopathy: a comparison of perioperative, radiographic, and clinical outcomes. *Journal of neurosurgery Spine* 2015, 23(3):280-289.
 17. Chung JY, Park JB, Seo HY, Kim SK: Adjacent Segment Pathology after Anterior Cervical Fusion. *Asian spine journal* 2016, 10(3):582-592.
 18. Butler JS, Morrissey PB, Wagner SC, Kaye ID, Sebastian AS, Schroeder GD, Vaccaro AR, Hilibrand AS: Surgical Strategies to Prevent Adjacent Segment Disease in the Cervical Spine. *Clinical spine surgery* 2019, 32(3):91-97.
 19. Huang SL, Yan HW, Wang KZ: Use of Fidji cervical cage in the treatment of cervical spinal cord injury without radiographic abnormality. *BioMed research international* 2013, 2013:810172.
 20. Li Z, Wang H, Li L, Tang J, Ren D, Hou S: A new zero-profile, stand-alone Fidji cervical cage for the treatment of the single and multilevel cervical degenerative disc disease. *Journal of clinical neuroscience : official journal of the Neurosurgical Society of Australasia* 2017, 41:115-122.
 21. Brolin K, Halldin P: Development of a finite element model of the upper cervical spine and a parameter study of ligament characteristics. *Spine (Phila Pa 1976)* 2004, 29(4):376-385.
 22. Dong L, Li G, Mao H, Marek S, Yang KH: Development and validation of a 10-year-old child ligamentous cervical spine finite element model. *Annals of biomedical engineering* 2013, 41(12):2538-2552.
 23. Faizan A, Goel VK, Garfin SR, Bono CM, Serhan H, Biyani A, Elgafy H, Krishna M, Friesem T: Do design variations in the artificial disc influence cervical spine biomechanics? A finite element investigation. *European spine journal : official publication of the European Spine Society, the European Spinal Deformity Society, and the European Section of the Cervical Spine Research Society* 2012, 21 Suppl 5:S653-662.
 24. Gilad I, Nissan M: A study of vertebra and disc geometric relations of the human cervical and lumbar spine. *Spine (Phila Pa 1976)* 1986, 11(2):154-157.
 25. Kallemeyn N, Gandhi A, Kode S, Shivanna K, Smucker J, Grosland N: Validation of a C2-C7 cervical spine finite element model using specimen-specific flexibility data. *Medical engineering & physics* 2010, 32(5):482-489.
 26. Panjabi MM, Crisco JJ, Vasavada A, Oda T, Cholewicki J, Nibu K, Shin E: Mechanical properties of the human cervical spine as shown by three-dimensional load-displacement curves. *Spine (Phila Pa 1976)* 2001, 26(24):2692-2700.
 27. Zhang QH, Teo EC, Ng HW, Lee VS: Finite element analysis of moment-rotation relationships for human cervical spine. *Journal of biomechanics* 2006, 39(1):189-193.
 28. Li Y, Lewis G: Influence of surgical treatment for disc degeneration disease at C5-C6 on changes in some biomechanical parameters of the cervical spine. *Medical engineering & physics* 2010, 32(6):595-603.
 29. Huang JJ, Niu CC, Chen LH, Lai PL, Fu TS, Chen WJ: Anterior cervical spinal surgery for multilevel cervical myelopathy. *Chang Gung medical journal* 2004, 27(7):531-541.
 30. Shamji MF, Massicotte EM, Traynelis VC, Norvell DC, Hermsmeyer JT, Fehlings MG: Comparison of anterior

- surgical options for the treatment of multilevel cervical spondylotic myelopathy: a systematic review. *Spine (Phila Pa 1976)* 2013, 38(22 Suppl 1):S195-209.
31. Liu Y, Hou Y, Yang L, Chen H, Wang X, Wu X, Gao R, Wang C, Yuan W: Comparison of 3 reconstructive techniques in the surgical management of multilevel cervical spondylotic myelopathy. *Spine (Phila Pa 1976)* 2012, 37(23):E1450-1458.
 32. Dalbayrak S, Yilmaz M, Naderi S: "Skip" corpectomy in the treatment of multilevel cervical spondylotic myelopathy and ossified posterior longitudinal ligament. *Journal of neurosurgery Spine* 2010, 12(1):33-38.
 33. Chibbaro S, Mirone G, Makiese O, George B: Multilevel oblique corpectomy without fusion in managing cervical myelopathy: long-term outcome and stability evaluation in 268 patients. *Journal of neurosurgery Spine* 2009, 10(5):458-465.
 34. Ikenaga M, Shikata J, Tanaka C: Anterior corpectomy and fusion with fibular strut grafts for multilevel cervical myelopathy. *Journal of neurosurgery Spine* 2005, 3(2):79-85.
 35. Ashkenazi E, Smorgick Y, Rand N, Millgram MA, Mirovsky Y, Floman Y: Anterior decompression combined with corpectomies and discectomies in the management of multilevel cervical myelopathy: a hybrid decompression and fixation technique. *Journal of neurosurgery Spine* 2005, 3(3):205-209.
 36. Ikenaga M, Shikata J, Tanaka C: Long-term results over 10 years of anterior corpectomy and fusion for multilevel cervical myelopathy. *Spine (Phila Pa 1976)* 2006, 31(14):1568-1574; discussion 1575.
 37. Hackel M, Stejskal L, Kramar F: [Anterior cervical corpectomy in the treatment of multilevel degenerative stenoses with spondylotic myelopathy. Personal experience with therapy and a literature review]. *Rozhledy v chirurgii : mesicnik Ceskoslovenske chirurgicke spolecnosti* 2001, 80(4):163-169.
 38. Macdonald RL, Fehlings MG, Tator CH, Lozano A, Fleming JR, Gentili F, Bernstein M, Wallace MC, Tasker RR: Multilevel anterior cervical corpectomy and fibular allograft fusion for cervical myelopathy. *Journal of neurosurgery* 1997, 86(6):990-997.
 39. Yang KQ, Lu XS, Cai QL, Ye LX, Lu WQ: Anterior multilevel decompression and fusion for cervical spondylotic myelopathy. Report of 214 cases. *Chinese medical journal* 1985, 98(1):1-6.
 40. Mann KS, Khosla VK, Gulati DR: Cervical spondylotic myelopathy treated by single-stage multilevel anterior decompression. A prospective study. *Journal of neurosurgery* 1984, 60(1):81-87.
 41. Hillard VH, Apfelbaum RI: Surgical management of cervical myelopathy: indications and techniques for multilevel cervical discectomy. *The spine journal : official journal of the North American Spine Society* 2006, 6(6 Suppl):242S-251S.
 42. Chacko AG, Joseph M, Turel MK, Prabhu K, Daniel RT, Jacob KS: Multilevel oblique corpectomy for cervical spondylotic myelopathy preserves segmental motion. *European spine journal : official publication of the European Spine Society, the European Spinal Deformity Society, and the European Section of the Cervical Spine Research Society* 2012, 21(7):1360-1367.
 43. George B, Gauthier N, Lot G: Multisegmental cervical spondylotic myelopathy and radiculopathy treated by multilevel oblique corpectomies without fusion. *Neurosurgery* 1999, 44(1):81-90.
 44. Liu Y, Qi M, Chen H, Yang L, Wang X, Shi G, Gao R, Wang C, Yuan W: Comparative analysis of complications of different reconstructive techniques following anterior decompression for multilevel cervical spondylotic myelopathy. *European spine journal : official publication of the European Spine Society, the European Spinal Deformity Society, and the European Section of the Cervical Spine Research Society* 2012, 21(12):2428-2435.
 45. Wang Z, Jiang W, Li X, Wang H, Shi J, Chen J, Meng B, Yang H: The application of zero-profile anchored spacer in anterior cervical discectomy and fusion. *European spine journal : official publication of the European Spine Society, the European Spinal Deformity Society, and the European Section of the Cervical Spine Research Society* 2015, 24(1):148-154.

46. Shao H, Chen J, Ru B, Yan F, Zhang J, Xu S, Huang Y: Zero-profile implant versus conventional cage-plate implant in anterior cervical discectomy and fusion for the treatment of degenerative cervical spondylosis: a meta-analysis. *Journal of orthopaedic surgery and research* 2015, 10:148.
47. Hofstetter CP, Kesavabhotla K, Boockvar JA: Zero-profile Anchored Spacer Reduces Rate of Dysphagia Compared With ACDF With Anterior Plating. *Journal of spinal disorders & techniques* 2015, 28(5):E284-290.
48. Miao J, Shen Y, Kuang Y, Yang L, Wang X, Chen Y, Chen D: Early follow-up outcomes of a new zero-profile implant used in anterior cervical discectomy and fusion. *Journal of spinal disorders & techniques* 2013, 26(5):E193-197.
49. Barbagallo GM, Romano D, Certo F, Milone P, Albanese V: Zero-P: a new zero-profile cage-plate device for single and multilevel ACDF. A single institution series with four years maximum follow-up and review of the literature on zero-profile devices. *European spine journal : official publication of the European Spine Society, the European Spinal Deformity Society, and the European Section of the Cervical Spine Research Society* 2013, 22 Suppl 6:S868-878.
50. Scholz M, Reyes PM, Schleicher P, Sawa AG, Baek S, Kandziora F, Marciano FF, Crawford NR: A new stand-alone cervical anterior interbody fusion device: biomechanical comparison with established anterior cervical fixation devices. *Spine (Phila Pa 1976)* 2009, 34(2):156-160.
51. Park DH, Ramakrishnan P, Cho TH, Lorenz E, Eck JC, Humphreys SC, Lim TH: Effect of lower two-level anterior cervical fusion on the superior adjacent level. *Journal of neurosurgery Spine* 2007, 7(3):336-340.
52. Yang JY, Song HS, Lee M, Bohlman HH, Riew KD: Adjacent level ossification development after anterior cervical fusion without plate fixation. *Spine (Phila Pa 1976)* 2009, 34(1):30-33.
53. Koller H, Reynolds J, Zenner J, Forstner R, Hempfing A, Maislinger I, Kolb K, Tauber M, Resch H, Mayer M *et al*: Mid- to long-term outcome of instrumented anterior cervical fusion for subaxial injuries. *European spine journal : official publication of the European Spine Society, the European Spinal Deformity Society, and the European Section of the Cervical Spine Research Society* 2009, 18(5):630-653.
54. Goffin J, van Loon J, Van Calenbergh F, Plets C: Long-term results after anterior cervical fusion and osteosynthetic stabilization for fractures and/or dislocations of the cervical spine. *Journal of spinal disorders* 1995, 8(6):500-508; discussion 499.

Figure Legends

Fig. 1. A three-dimensional finite element model of intact cervical vertebra (C2–C7). (A) Front view, (B) Lateral view.

Fig. 2. A three-dimensional finite element model of four anterior cervical techniques. (A) multilevel anterior cervical discectomy and fusion (mACDF), (B) anterior cervical corpectomy and fusion (ACCF), (C) hybrid decompression and fusion (HDF), (D) multilevel anterior cervical discectomy and fusion with cage alone (mACDF-CA).

Fig. 3. Comparison of finite element analysis results with in vitro experimental data in flexion-extension, lateral bending and axial rotation (C3–C7).^{24–26} (A) C3–C4, (B) C4–C5, (C) C5–C6, (D) C6–C7

Fig. 4. Von Mises stress at C2/3 disc in different conditions in the four models of anterior anterior cervical techniques. mACDF, multilevel anterior cervical discectomy and fusion; ACCF, anterior cervical corpectomy and fusion; HDF, hybrid decompression and fusion; mACDF-CA, multilevel anterior cervical discectomy and fusion with cage alone.

Fig. 5. Von Mises stress at C6/7 disc in different conditions in the four models of anterior anterior cervical techniques. mACDF, multilevel anterior cervical discectomy and fusion; ACCF, anterior cervical corpectomy and fusion; HDF, hybrid decompression and fusion; mACDF-CA, multilevel anterior cervical discectomy and fusion with cage alone.

Fig. 6. Von Mises stress at the plate-screw interface in different conditions in the three models of anterior anterior cervical techniques. mACDF, multilevel anterior cervical discectomy and fusion; ACCF, anterior cervical corpectomy and fusion; HDF, hybrid decompression and fusion.

Figures

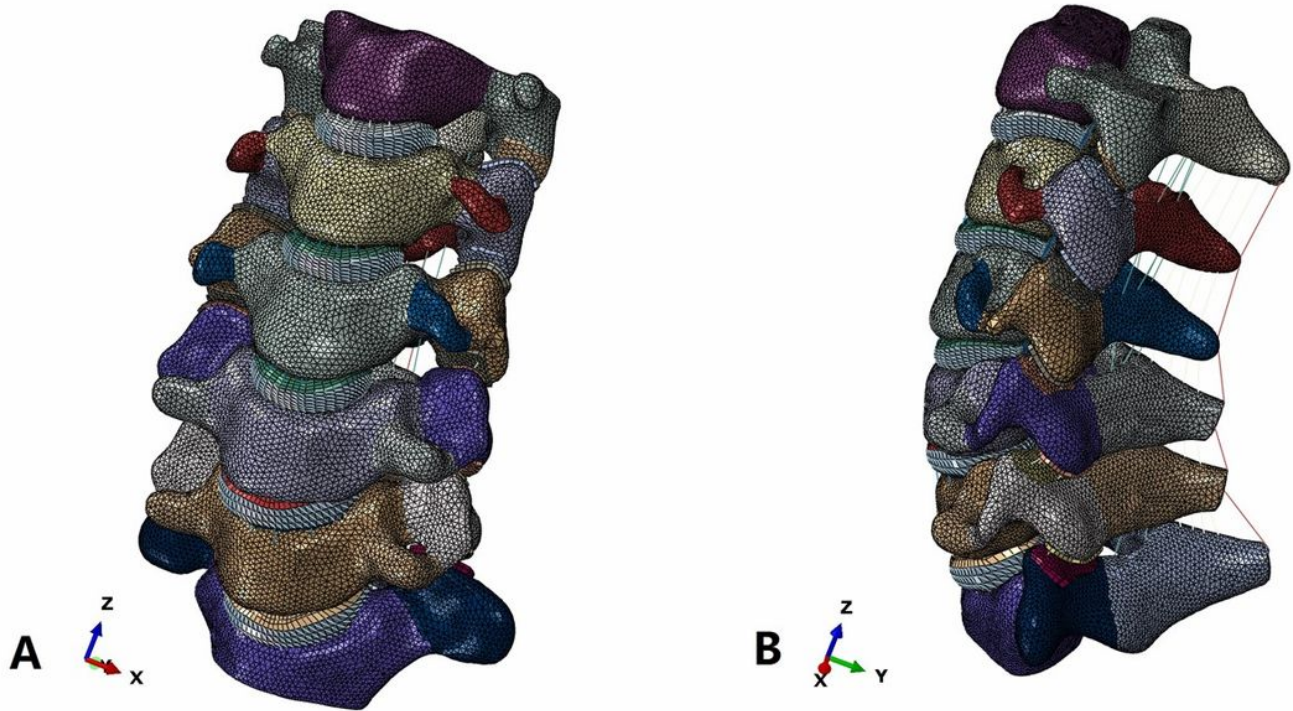


Figure 1

A three-dimensional finite element model of intact cervical vertebra (C2–C7). (A) Front view, (B) Lateral view.

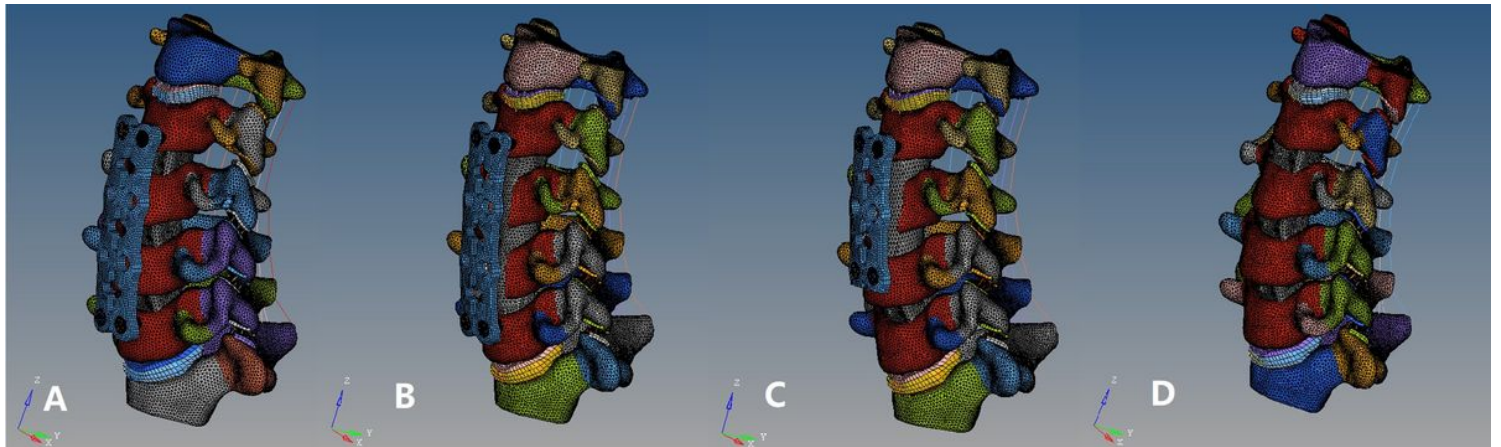


Figure 2

A three-dimensional finite element model of our anterior cervical techniques. (A) multilevel anterior cervical discectomy and fusion (mACDF), (B) anterior cervical corpectomy and fusion (ACCF), (C) hybrid decompression and fusion (HDF), (D) multilevel anterior cervical discectomy and fusion with cage alone (mACDF-CA).

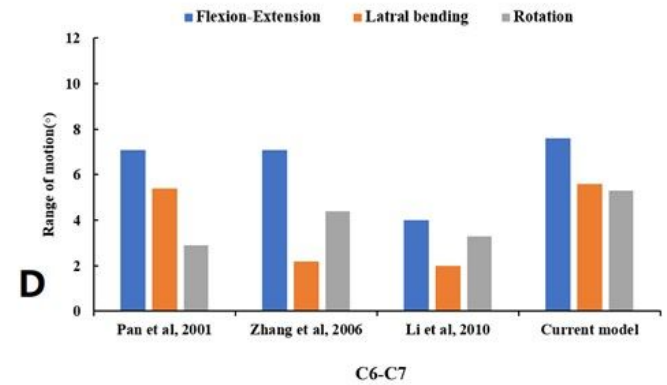
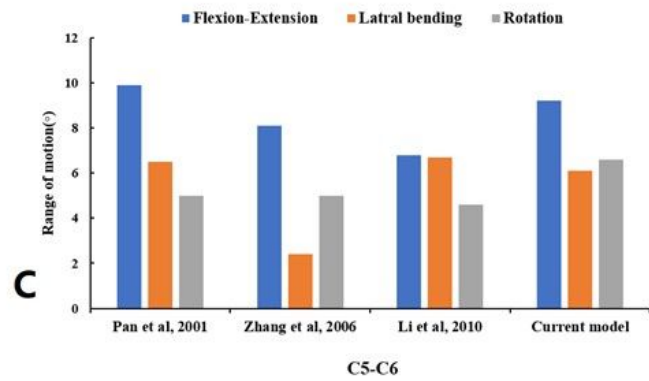
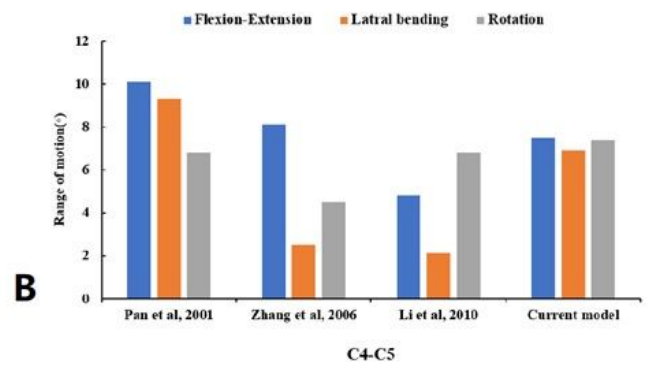
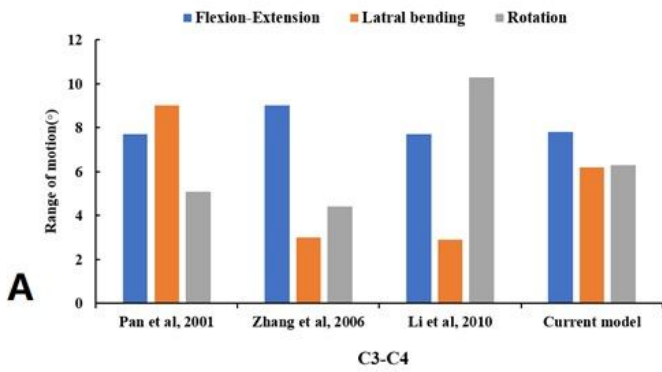


Figure 3

Comparison of finite element analysis results with in vitro experimental data in flexion-extension, lateral bending and axial rotation (C3–C7). (A) C3–C4, (B) C4–05, (C) C5–C6, (D) C6–C7

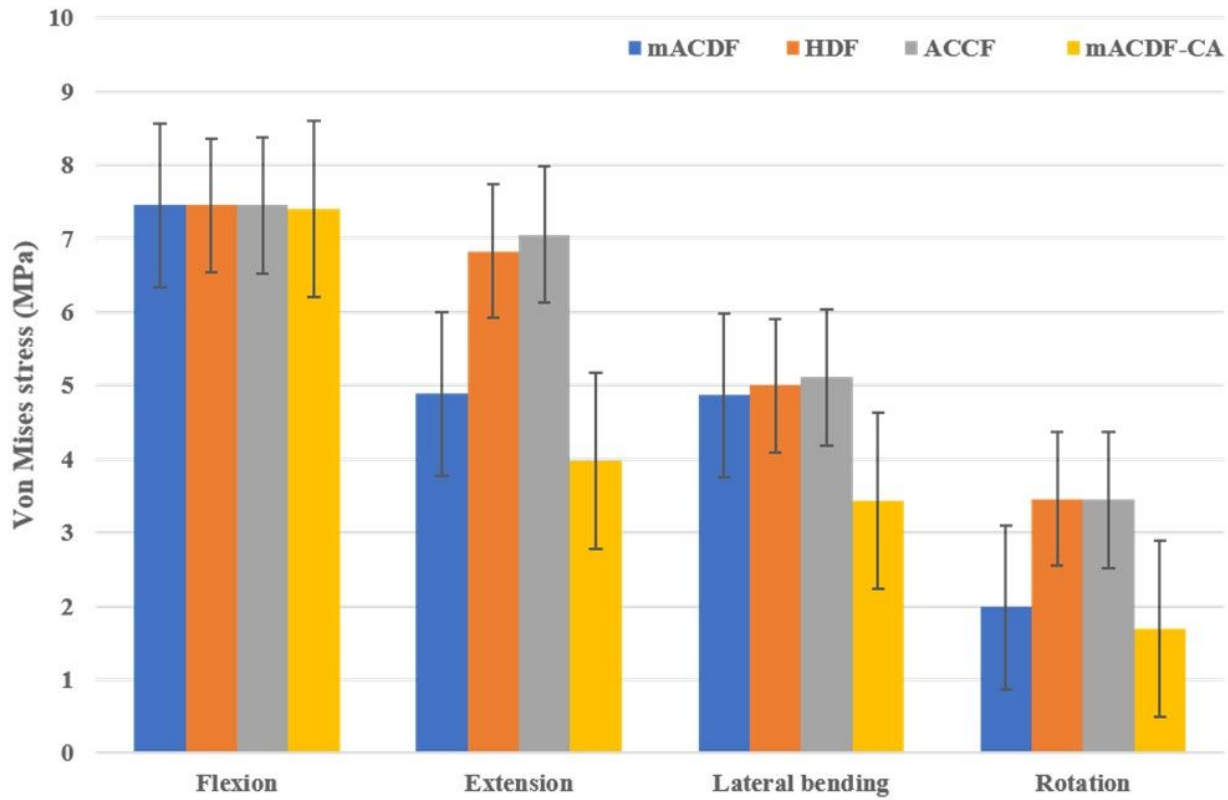


Figure 4

Von Mises stress at C2/3 disc in different conditions in the four models of anterior cervical techniques. mACDF, multilevel anterior cervical discectomy and fusion; ACCF, anterior cervical corpectomy and fusion; HDF, hybrid decompression and fusion; mACDF-CA, multilevel anterior cervical discectomy and fusion with cage alone.

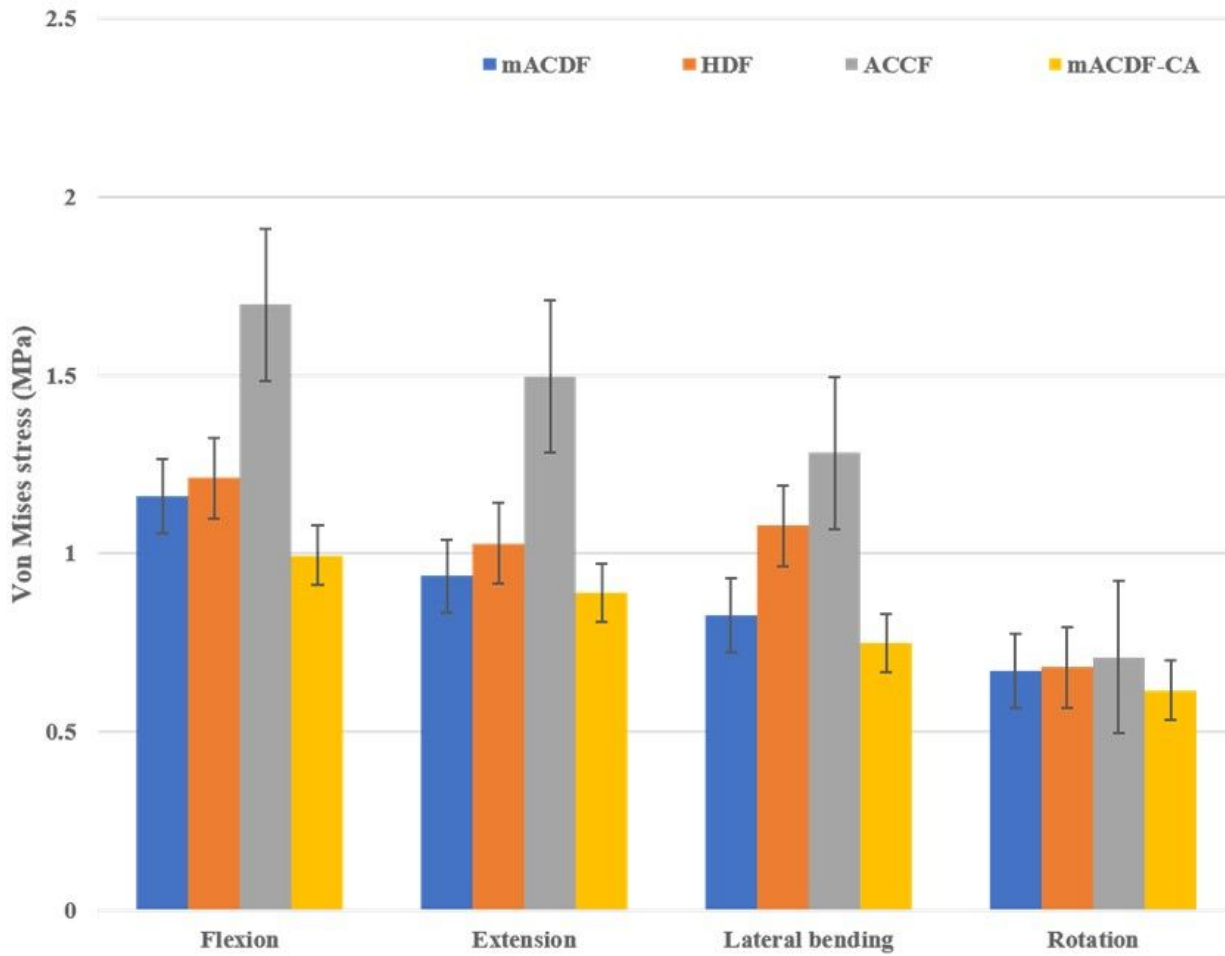


Figure 5

Von Mises stress at C6/7 disc in different conditions in the four models of anterior anterior cervical techniques. mACDF, multilevel anterior cervical discectomy and fusion; ACCF, anterior cervical corpectomy and fusion; HDF, hybrid decompression and fusion; mACDF-CA, multilevel anterior cervical discectomy and fusion with cage alone.

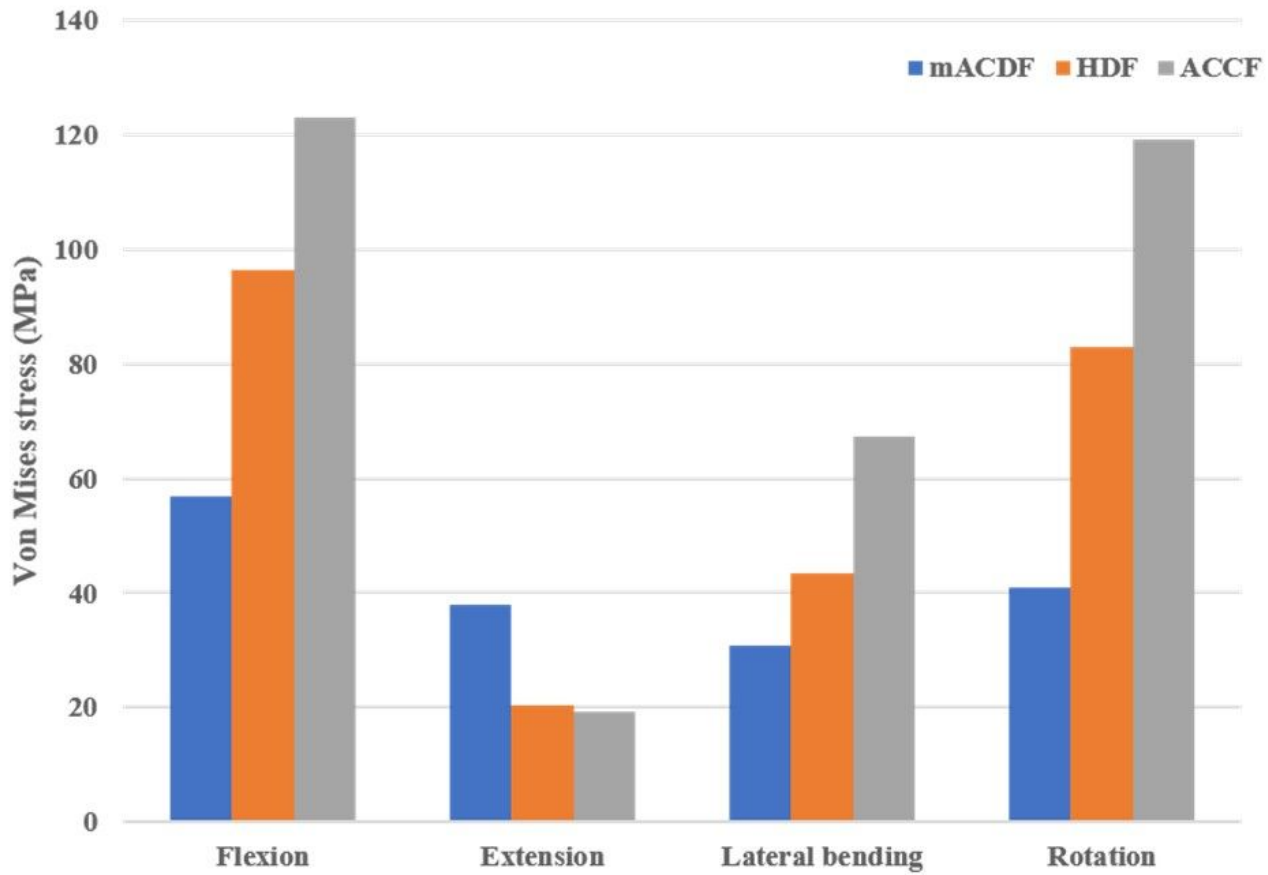


Figure 6

Von Mises stress at the plate-screw interface in different conditions in the three models of anterior anterior cervical techniques. mACDF, multilevel anterior cervical discectomy and fusion; ACCF, anterior cervical corpectomy and fusion; HDF, hybrid decompression and fusion.