Reconstruction of Paprosky III defects with double-trabecular metal cups in acetabular revision at five-year follow-up

Xianghong Zhang
Second Xiangya Hospital
Jia Wan
Second Xiangya Hospital
Wanchun Wang
Second Xiangya Hospital
Fuming Li
Guangxi Medical University
Libiao Qiu
Guangxi Medical University
Weiqiu Peng
Guangxi Medical University
Tang Liu (liutang1204@csu.edu.cn)
the 2nd Xiangya Hospital of Central South University https://orcid.org/0000-0002-0040-4270

Research article

Keywords: Revision hip arthroplasty, Acetabular defects, Paprosky Ⅲ, Double-cup technique, Impacting bone grafting

Posted Date: February 11th, 2020

DOI: https://doi.org/10.21203/rs.2.23126/v1

Abstract

Background: Acetabular revision is often difficult to manage because of severe bone loss, especially for Paprosky type Ⅲ defects. Our present study aimed to assess the strategy of double-trabecular metal cups in acetabular revision.

Methods: Fifteen patients (15 hips) underwent acetabular revision using double-cup technique alone or in combination with impacting bone grafting between January 2008 and May 2015. Preoperative and the latest follow-up clinical and radiographic scores were recorded and compared.

Results: No patients were lost to follow up, and no patients underwent re-revision for loosening or any other reasons at the mean follow-up duration of 66 (range 55-105) months. We discovered 3 patients (3/15) with the early dislocation within the first year after the surgery and 2 patients (2/15) with delayed wound healing. The comparison between preoperative and the latest follow-up results showed the records of modified Harris Hip Score, University of California, Los Angeles activity score, Short Form 36, limb-length discrepancy and hip center of rotation were significantly improved.

Conclusions: The application of double-cup technique alone or in combination with impacting bone grafting is an effective and reliable treatment option for Paprosky type Ⅲ acetabular defects without pelvic discontinuity.

Background

Because of good to excellent prognosis, primary total hip arthroplasty (THA) is an effective management of hip degenerative pathologies [1]. Failure rate requiring reoperation after THA is higher (8.9%-24.1%) at 5-year follow-up [1]. With the younger tendency and rising life expectancy of patients, the number of revision surgery following THA is expected to increase in the near future [2]. Multiple treatment options and various special implants for the reconstruction of acetabular defects have been developed [1, 3]. However, acetabular revision for severe bone defects is still a challenging surgery because of the high incidence of complications [4, 5]. The main complication is dislocation after revision hip arthroplasty [3], and it is more common in revision hip arthroplasty than primary THA [1]. Restoration of the native hip center of rotation (COR) is crucial in primary THA and revision hip arthroplasty [6]. On account of advantages in biomechanics and biocompatibility, trabecular metal augments and trabecular metal-coated cups were increasingly applied in the revision hip arthroplasty [7]. Whatever revision implants were applied, proper anchoring would be hindered in severe acetabular defects [8]. In these instances, in order to gain surface contact as much as possible and attain biologic ingrowth, alternative options and implants should be applied to gain surface contact as much as possible and attain biologic ingrowth.

Bone grafting was required to reconstruct the severe acetabular defects [9]. The technique of impacting bone grafting would take the place of the bulk grafts gradually because of low osseointegration potential of bulk grafts [8]. However, poor results in revision hip arthroplasty using structural bone grafts without reinforcement devices have been reported [5]. Recently, some studies consider the technique of using

custom-made implants in combination with trabecular metal prosthetic component was a reliable option to deal with severe acetabular defects [3, 10]. However, to increase the function results, new strategy of using impacting bone grafting and other revision devices was recommended [11]. To our knowledge, there are a few studies about using double-trabecular metal cups in combination with impacting bone grafting in acetabular revision.

We hypothesize that using double-trabecular metal cup alone or in combination with impacting bone grafting is a dependable technique to manage Paprosky type ⅢB acetabular defects without pelvic discontinuity. Furthermore, we hypothesize that our results would have equivalent or favorable levels of efficacy with the researches of double-cup technique for similar acetabular defects.

Patients And Methods

Patients

This retrospective study was conducted between January 1, 2008 and May 31, 2015 in our institutions. The inclusion criteria were as follow: patients were treated by revision hip arthroplasty. Study exclusion criteria included: (i) the revision hip arthroplasty were conducted without using double-cup technique; (ii) patients with bone tumor; (iii) patients with Paprosky ⅢB acetabular defects and pelvic discontinuity. Fifteen patients (15 hips) met the criteria in this retrospective study. Clinical and radiographic data (**Fig.1**) about enrolled patients were collected under the same criteria. Aseptic loosening was diagnosed by the uniform standard of clinical and radiological, including existence of radiolucent lines, migration of implant, or disruption of screw [3]. Musculoskeletal Infection Society (MSIS) was used to diagnose periprosthetic joint infection [12], and these patients were all managed with two-stage revision strategy. Acetabular defects were classified based on radiographic findings and confirmed intra-operatively by the senior orthopaedic surgeons (TL and WQP) in accordance with the Paprosky classification [13]. Chronic instability was defined by Sayac G et al [2]. The present study was ethically approved by our hospital committee (No.2010-S043) and written informed consent was obtained from the patients or their legal guardians.

Surgical technique

Surgeries were carried out by posterolateral approach after laying patients in lateral decubitus position. All reconstructions were performed by the senior surgeons (TL and WQP) who are experienced in the surgical technique for revision THA. We cleared away the underlying fibrous membrane down to the working bone after removing the failed components. Hemispherical reamers were applied to eliminate sclerotic acetabular bone carefully, and we assessed the appropriate suitability by dull reamers. The acetabular defects were classified and confirmed during operation (**Fig.2A**). In order to gain the appropriate size and position of prosthesis, we placed the trial shell with or without augment into the acetabulum and chose another optimal trial shell based on the remaining defects (**Fig.3B**). Aiming to reconstruct acetabular defects adequately and biologically [4], we applied allograft (OsteoRad, Shanxi, China) to fill bottom and bone stock defects by impacting thoroughly with reverse rotating reamer in

patients who have severe bone defects [14]. When a partial stability was obtained with the desired positioning, we placed the trabecular metal revision cup as the 2nd cup (Zimmer, Warsaw, IN) with or without augment in the superior defects to stabilize the 1st cup as the base of support (**Fig.3**). Then screws (Zimmer, Warsaw, IN) were applied to increase primary stability of the 2nd cup with or without augment. Before impacting the 1st cup, the location of the cup was tried again by hemispherical reamer. We assessed the final anatomic center cup position through intra-operative plain radiographs. The 1st cup was desired to be oriented at 40°±10° inclination and 15°±10° anteversion [15]. Then the 1st trabecular metal revision cup was implanted with press-fit technique (**Fig.3**). Finally, we typically used screws to fix the anatomic cup to the acetabulum. After the components were fixed, the clindamycin and gentamicin polymethyl methacrylate bone cement (Copal G+C, Berlin, Germany) was applied to create one monolithic construct (**Fig.2B, Fig.3**). We cleansed the trabecular metal cup and inserted the polyethylene liner into the 1st cup (**Fig.3**). If the stem was loosening, we would perform a complete revision including acetabular and femoral stem.

Postoperatively, all patients were given oral celecoxib (200mg/day) prophylactically for anti-inflammation. For aseptic revision surgery, a second generation cephalosporin was transfused at least 30 minutes before skin incision and continued less than 48 hours after operation. For patients with the second-stage procedure of reimplantation after periprosthetic joint infection, we applied the conventional smear test and bacterial cultures of the joint fluid during operation. Targeted prophylactic antibiotic of these patients was transfused at least 30 minutes before skin incision and continued 7-10 days until the negative results of bacterial culture [16]. Early postoperative mobilization was allowed on the first or second day after operation, and part weight-bearing was permitted at early stage of 6-8 weeks after surgery. Full weight-bearing was permitted gradually after the clinical and radiological results were reviewed two months after revision surgery. Patients were assessed radiologically and clinically after four weeks, two months, six months, one year, and then annually during the follow-up period (**Fig.4**).

Clinical and radiological assessments

All patients were evaluated clinically and radiologically before operation and at the latest available follow-up. Trendelenburg sign was applied to evaluated abduction strength. We applied the modified Harris Hip Score (mHHS) for the clinical and functional evaluation, and the mHHS was considered as the primary outcome parameter and classified as previous described [17]. In addition, measurements like University of California, Los Angeles (UCLA) activity score [18] and Short Form 36 (SF-36) [8] were recorded. The distance from the anterior superior iliac spine to the medial maleolus was measured as the leg length, and the difference between both lower extremities was calculated and defined as limb-length discrepancy (LLD) [17, 18].

Standard anteroposterior radiographs of the pelvis and later radiographs of the affected hip were performed at each clinical interval, and two independent observers (TL and WQP) reviewed and evaluated the radiological outcomes. Radiolucent lines surrounding the implanted components were assessed in accordance with the previous method [17], and loosening of acetabular prosthesis was defined as Spore

SM et al. [19]. The criteria about osseointegration [4] and the Oswestry classification [2] were separately applied to evaluate ingrowth of uncemented component and the integration of allograft, and any heterotopic ossifications were noted and evaluated based on the system of Brooker et al. [20]. We recorded and calculated the change of the hip center of rotation through measuring preoperative and the latest follow-up radiographs [3]. We measured the acetabular cup inclinations directly [21] and calculated the acetabular cup antevesion using the method suggested by Pradhan [22] on anteroposterior radiographs.

Statistical analysis

All the data were analyzed by SPSS 21.0 software (SPSS Inc., Chicago, IL, USA). We described measurement data as the mean±standard deviation and the enumeration data as the count and rate, and *t* test was used to analyze difference between preoperative and the latest follow-up values of mHHS, UCLA, SF-36, LLD, and COR. We considered it statistically significant when the *p* value was less than 0.05 for all tests.

Results

Patient demographics

We retrospectively reviewed 15 patients (15 hips) who underwent acetabular revision with double-cup technique from January 1, 2008 to May 31, 2015 (**Table 1**). Nine (9/15) female and six (6/15) male patients were enrolled with an average body-mass index (BMI) of 25.3 kg/m^2 (range 21.4-30.5), and an average age of 68.5 years (range 58-79). Patients' major preoperative comorbidities included hypertension (n=8; 8/15), chronic obstructive pulmonary disease (n=2; 2/15), diabetes mellitus (n=3; 3/15), asthma (n=1; 1/15), hyperthyroidism (n=1; 1/15) and coronary artery disease (n=1; 1/15). Our study enrolled 9 (9/15) Paprosky type ⅡA defects and 6 (6/15) Paprosky type ⅡB defects without pelvic discontinuity. Indication for revision of all patients was aseptic loosening in present study. 7 (7/15) patients underwent both socket and stem revision, and 8 (8/15) patients underwent impacting bone grafting. The median number of previous affected hip surgeries is 1.4 (range 1-3).

Clinical and radiological results

No patients were lost to follow up, and the average follow-up period was 66 months (range 55-105). No patients experienced infection and nerve palsy after the index procedure. Complications occurred in five (5/15) patients, including 3 (3/15) dislocation treated with closed reduction and bracing, and 2 (2/15) delayed wound healing treated with prolonged wound dressing. Overall, no patients underwent re-revision surgery for any reasons. Trendelenburg-positive was discovered in 2 (2/15) hips. Results measured by mHHS, UCLA and SF-36 were reported in **Table 2**. At the time of the latest follow-up, the mHHS was significantly improved from a mean preoperative value of 44.4 (rang 35-50) to 74.2 (rang 68-85) ($p<0.01$), and mHHS was good in 2 (2/15) hips, fair in 12 (12/15) hips, and poor in 1 (1/15) hip. The average preoperative UCLA score was 2.7 (rang 2-4), which was improved significantly to 7.3 (range 7-8) at the

latest follow-up (p<0.01). The mean SF-36 scores at the latest follow-up were improved significantly than preoperative scores, especially in bodily pain category.

The mean limb-length discrepancy of patients decreased from 24.3 mm (range 20-32 mm) preoperatively to 6.1 mm (range 3-9 mm) postoperatively. Postoperative radiographic evaluation showed the average hip center of rotation was decreased significantly from 47.3 mm (range 33-68 mm) preoperatively to 25.5 mm (range 16-35 mm) postoperatively (p<0.01) (**Table 2**). No hips were outside the Lewinnek [15] acetabular cup inclination and anterversion safe range. In the latest follow-up examination, we discovered bone graft incorporation in all hips 1 year after the revision operation. Asymptomatic grade–1 heterotopic ossifications were found in 3 (3/15) patients who received no advanced treatment. No failure for acetabular loosening or metal failure was found at the latest follow-up.

Discussion

Due to complex bone defects and different fixation methods of implants, revision hip arthroplasty is technically challenging, especially in Paprosky type Ⅲ defects. The goals of the revision hip arthroplasty on the acetabular side include providing stable initial fixation, achieving reliable and long-term results, promoting eventual biologic ingrowth, and restoring the normal anatomical structure and the lower limb length [2]. Multiple treatment options for acetabular reconstruction had been described, including the application of bulk autograft or allograft alone or in combination with prosthesis, ranging from jumbo cup construct, mechanical and biologic cup-cage construct, trabecular metal augment and shell, dual mobility cup, and some others [1, 3]. Trabecular metal and dual mobility cup were widely used to construct complex acetabular defects in revision surgery [1, 3]. Using jumbo cup is a straightforward method to reconstruct Paprosky type Ⅲ acetabular defects, and this technique has a good survival rate of 96% at 15 years of follow-up [9]. However, host bone would be widely removed if jumbo cups were used, and it would difficult to reconstruct with the residual bone stock at last. Aiming to fill the bone defects adequately and maximize the contact with the host bone, modular systems were widely used as a pragmatic tool by revision surgeons [10]. Though severe acetabular defects were handled in combination methods as literature reported, some special patients were difficult to handle with these existent combination techniques [3, 10]. Therefore, it is still a challenging and controversial issue to handle severe uncontained defects. Alternative techniques and implants should be considered to handle large and complex acetabular defects in the future. In recent years, a few studies have been carried out to evaluate the effects of a novel treatment strategy of double-cup technique applied to deal with Paprosky type Ⅲ acetabular defects without pelvic discontinuity, and the technique of double-cup reconstruction was considered as a credible way for acetabular revision based on their short-term results [3, 10].

In present study, we found no patients underwent re-revision surgery for any reasons over the follow-up period (**Table 3**). There is no significant difference about cup survival in comparison with literatures at the latest follow-up [3, 10]. Clinically, we found a significant and enduring improvement of the mHHS in our cohort at minimum 55months follow-up. Though the average score of 74.2 points at the latest follow-up is higher than previously described [3, 10], it is lower than the mean score of 81 points of revision hip

arthroplasty described by Löchel J et al. [4]. After comparison the number of previous affected hip surgeries, we demonstrated that previous surgery is an important factor for mHHS score and Trendelenburg sign results. Restoring the normal anatomy hip center of rotation would help to regain normal biomechanics and decrease joint reactive force, and help to improve the wear resistance and longevity of the acetabular reconstruction [6]. Radiographically, we measured and calculated the hip center of rotation as reported by Nunn et al. [23]. In our series, we had restored the normal anatomic hip center of rotation efficiently as some other researches described [3, 10]. Despite the large and complex of acetabular defects, we have done our best to regain the optimal position of hip center of rotation. We didn't find radiolucent lines, osteolysis and lossening of implants at the latest follow-up. However, we discovered the dislocation rate of 20% (3/15) in our study, as comparison with other revision hip arthroplasty studies with double-cup technique (**Table 3**) whose dislocation rates were 0% [10] and 30% [3] respectively. The dislocation rate of revision hip arthroplaty ranged from 14% to 21% as literature reported [24]. Our dislocation rate is similar to the technique with augment for bone defects described by Gaizo et al. [25]. For socket-only revisions, dislocation rate (2/8) in present study is similar to the previous study [3]. We discovered that dislocation rate for socket-only revision is higher than that for both-side revisions. In our opinions, while it is impossible to prevent postoperative complications, we should take some measures to decrease the dislocation events after revision hip arthroplasty as reported before [26].

Due to the large and complex of acetabular bone defects, a gap exists between the socket and host bone during revision hip arthroplasy. Therefore, poor quality of acetabular bone bed would cause reconstruction failure. Several studies demonstrated that impacting bone grafting in combination with acetabular components was widely used in revision hip arthroplasy when significant bone defects exists [14]. The technique of impacting bone grafting would take the place of the bulk grafts gradually because of low osseointegration potential of bulk grafts [8]. Garcia CT et al.[27] had reported impacting grafting contributed to restore acetabular bone stock and anatomic hip center of rotation, and had good results in the latest follow-up. However, autografts were difficult to widely use because of donor shortage and donor site morbidity. By the technique of creeping substitution, vascularization and incorporation occurred in impacting allografts like studies reported [28]. But some reports showed poor outcomes in revision hip arthroplasty with structural bone grafts without reinforcement devices [5]. Therefore, many authors recommended the combined application of other revision devices to gain good to excellent clinic and radiographic outcomes [11]. In the present study, some patients underwent reconstruction with double-cup technique in combination with compacting bone grafting technique, and we found bone graft incorporation in all hips 1 year after the revision operation.

Furthermore, the cost of revision hip arthroplasty is usually an important issue, especially in patients of large and complex bony defects. Usage of trabecular metal augments, cup-cage, or custom triflange implant brings great financial burden to patients, particularly in developing countries. The cost of revision hip arthroplasty is different among different institutions and countries. At our institution, the cost of double-cup technique without additional augment (RMB 30,000-40,000) is less than the use of one trabecular metal cup with two augments (RMB 50,000-60,000), the cup-cage implant (RMB 50,000-60,000), or custom triflange construct (RMB 70,000-80,000). We reconstructed Paprosky type ⅢB acetabular

defects with double-cup technique alone or in combination with impacting bone grafting in our present study, and achieved good to excellent short-term results with less cost finally.

We acknowledge limitations of our study. First, our present study was retrospectively designed with relatively small sample size. Although we carried out the study in two institutions, it was hard to get a larger number of patients who underwent rare and uncommon acetabular reconstruction with double-cup technique. Second, the mixed pathology of patients and non-blinded radiographic analysis could contribute to inconsistent results. Likewise, the implants of femur revision in this series were not identical. We chose implants according to the anatomy and requisite during the operation. Finally, the short to middle-term follow-up also could contribute to inferior results. Our lack of blindness in physical examination may have introduced bias.

Conclusion

In conclusion, revision hip arthroplasty using double-cup technique achieved good to excellent results for 15 selected Paprosky type Ⅲ acetabular defects with an average follow-up of 66 months, but further researches are still needed for long follow-up. We consider the application of double-cup technique alone or in combination with bone graft as an effective and reliable management reconstruction of Paprosky type Ⅲ acetabular defects without pelvic discontinuity.

Abbreviations

THA: total hip arthroplasty; **COR**: center of rotation; **MSIS**: Musculoskeletal Infection Society; **mHHS**: modified Harris Hip Score; **UCLA**: University of California, Los Angeles; **SF-36**: Short Form 36; **LLD**: limb-length discrepancy.

Declarations

Ethics approval and consent to participate

This study was ethically approved by the Second Xiangya Hospital committee for clinical research (No.2010-S043). Patients' data obtained in the course of the study were reserved confidential and used only for this study.

Consent for publication

Written informed consent was obtained from all the patients for publication of this article and any accompanying images.

Availability of data and materials

The datasets used and/or analyzed during the present study are available from the corresponding authors on reasonable request.

Competing of interests

The authors declare that they have no competing interests. No benefits in any form have been received or will be received from a commercial party related directly or indirectly to the subject of this article.

Funding

The study was supported by National Natural Science Foundation of China (81000821, 81672176, and 81871783).

Authors' contributions

XH Z and TL were conceptualized and designed the study, collected the data, analyzed the statistics, wrote and edited the manuscript. WQ P, WC W and FM L were conceptualized and designed the study, supervised the statistical analysis. JW and LB Q were analyzed and collected the data. All authors have read and approved the manuscript.

Acknowledgements

We would like to thank all participating patients, as well as the study nurses, co-investigators, and colleagues who made this trial possible.

Author details

[1]Department of Orthopedics, the Second Xiangya Hospital of Central South University, Changsha, Hunan, 410011, China. [2]Department of Orthopedics, Liuzhou General Hospital of Guangxi Medical University, Liuzhou, Guangxi, 545000, China.

Authors' information

TL and WQ P are co-corresponding authors.

References

1. Schmidt A, Batailler C, Fary C, Servien E, Lustig S: **Dual Mobility Cups in Revision Total Hip Arthroplasty: Efficient Strategy to Decrease Dislocation Risk**. *J Arthroplasty* 2019.
2. Sayac G, Neri T, Schneider L, Philippot R, Farizon F, Boyer B: **Low Revision Rates at More Than 10 Years for Dual-Mobility Cups Cemented Into Cages in Complex Revision Total Hip Arthroplasty**. *J Arthroplasty* 2019.
3. Webb JE, McGill RJ, Palumbo BT, Moschetti WE, Estok DM: **The Double-Cup Construct: A Novel Treatment Strategy for the Management of Paprosky IIIA and IIIB Acetabular Defects**. *J Arthroplasty* 2017, **32**(9S):S225-S231.

4. Lochel J, Janz V, Hipfl C, Perka C, Wassilew GI: **Reconstruction of acetabular defects with porous tantalum shells and augments in revision total hip arthroplasty at ten-year follow-up**. *The bone & joint journal* 2019, **101-b**(3):311-316.
5. Masumoto Y, Fukunishi S, Fukui T, Takeda Y, Nishio S, Fujihara Y, Okahisa S, Okada T, Yoshiya S: **Acetabular reconstruction for primary and revision total hip arthroplasty using Kerboull-type acetabular reinforcement devices-case-control study with factors related to poor outcomes of surgery**. *Medicine* 2019, **98**(27):e16090.
6. Watts CD, Abdel MP, Hanssen AD, Pagnano MW: **Anatomic Hip Center Decreases Aseptic Loosening Rates After Total Hip Arthroplasty with Cement in Patients with Crowe Type-II Dysplasia: A Concise Follow-up Report at a Mean of Thirty-six Years**. *The Journal of bone and joint surgery American volume* 2016, **98**(11):910-915.
7. Meneghini RM, Meyer C, Buckley CA, Hanssen AD, Lewallen DG: **Mechanical stability of novel highly porous metal acetabular components in revision total hip arthroplasty**. *J Arthroplasty* 2010, **25**(3):337-341.
8. Roessler PP, Jaenisch M, Kuhlmann M, Wacker M, Johannes Wagenhauser P, Gravius S, Wirtz DC: **The augment-and-modular-cage revision system for reconstruction of severe acetabular defects-two-year clinical and radiographic results**. *International orthopaedics* 2019, **43**(10):2269-2278.
9. Yoshino K, Tsukeoka T, Tsuneizumi Y, Lee TH, Nakamura J, Suzuki M, Ohtori S: **Revision Total Hip Arthroplasty Using a Cementless Cup Supporter and Iliac Autograft: A Minimum of 15-Year Follow-Up**. *J Arthroplasty* 2017, **32**(11):3495-3501.
10. Loppini M, Schiavi P, Rocca AD, Traverso F, Rocca FD, Mazziotta G, Astore F, Grappiolo G: **Double-trabecular metal cup technique for the management of Paprosky type III defects without pelvic discontinuity**. *Hip Int* 2018, **28**(2_suppl):66-72.
11. Somers JF, Timperley AJ, Norton M, Taylor R, Gie GA: **Block allografts in revision total hip arthroplasty**. *J Arthroplasty* 2002, **17**(5):562-568.
12. Parvizi J, Zmistowski B, Berbari EF, Bauer TW, Springer BD, Della Valle CJ, Garvin KL, Mont MA, Wongworawat MD, Zalavras CG: **New definition for periprosthetic joint infection: from the Workgroup of the Musculoskeletal Infection Society**. *Clinical orthopaedics and related research* 2011, **469**(11):2992-2994.
13. Paprosky WG, Perona PG, Lawrence JM: **Acetabular defect classification and surgical reconstruction in revision arthroplasty. A 6-year follow-up evaluation**. *J Arthroplasty* 1994, **9**(1):33-44.
14. Schreurs BW, Keurentjes JC, Gardeniers JW, Verdonschot N, Slooff TJ, Veth RP: **Acetabular revision with impacted morsellised cancellous bone grafting and a cemented acetabular component: a 20- to 25-year follow-up**. *The Journal of bone and joint surgery British volume* 2009, **91**(9):1148-1153.
15. Lewinnek GE, Lewis JL, Tarr R, Compere CL, Zimmerman JR: **Dislocations after total hip-replacement arthroplasties**. *The Journal of bone and joint surgery American volume* 1978, **60**(2):217-220.
16. Corro S, Vicente M, Rodriguez-Pardo D, Pigrau C, Lung M, Corona PS: **Vancomycin-Gentamicin Prefabricated Spacers in 2-Stage Revision Arthroplasty for Chronic Hip and Knee Periprosthetic Joint**

Infection: Insights Into Reimplantation Microbiology and Outcomes. *J Arthroplasty* 2019.

17. Li X, Lu Y, Sun J, Lin X, Tang T: **Treatment of Crowe Type-IV Hip Dysplasia Using Cementless Total Hip Arthroplasty and Double Chevron Subtrochanteric Shortening Osteotomy: A 5- to 10-Year Follow-Up Study**. *J Arthroplasty* 2017, **32**(2):475-479.
18. Liu T, Wang S, Huang G, Wang W: **Treatment of Crowe IV developmental dysplasia of the hip with cementless total hip arthroplasty and shortening subtrochanteric osteotomy**. *J Int Med Res* 2019, **47**(7):3223-3233.
19. Sporer SM, Paprosky WG: **The use of a trabecular metal acetabular component and trabecular metal augment for severe acetabular defects**. *J Arthroplasty* 2006, **21**(6 Suppl 2):83-86.
20. Brooker AF, Bowerman JW, Robinson RA, Riley LH, Jr.: **Ectopic ossification following total hip replacement. Incidence and a method of classification**. *The Journal of bone and joint surgery American volume* 1973, **55**(8):1629-1632.
21. Wang W, Huang G, Huang T, Wu R: **Bilaterally primary cementless total hip arthroplasty in patients with ankylosing spondylitis**. *BMC musculoskeletal disorders* 2014, **15**:344.
22. Pradhan R: **Planar anteversion of the acetabular cup as determined from plain anteroposterior radiographs**. *The Journal of bone and joint surgery British volume* 1999, **81**(3):431-435.
23. Nunn D, Freeman MA, Hill PF, Evans SJ: **The measurement of migration of the acetabular component of hip prostheses**. *The Journal of bone and joint surgery British volume* 1989, **71**(4):629-631.
24. Phillips CB, Barrett JA, Losina E, Mahomed NN, Lingard EA, Guadagnoli E, Baron JA, Harris WH, Poss R, Katz JN: **Incidence rates of dislocation, pulmonary embolism, and deep infection during the first six months after elective total hip replacement**. *The Journal of bone and joint surgery American volume* 2003, **85**(1):20-26.
25. Del Gaizo DJ, Kancherla V, Sporer SM, Paprosky WG: **Tantalum augments for Paprosky IIIA defects remain stable at midterm followup**. *Clinical orthopaedics and related research* 2012, **470**(2):395-401.
26. De Martino I, Strigelli V, Cacciola G, Gu A, Bostrom MP, Sculco PK: **Survivorship and Clinical Outcomes of Custom Triflange Acetabular Components in Revision Total Hip Arthroplasty: A Systematic Review**. *J Arthroplasty* 2019, **34**(10):2511-2518.
27. Garcia-Cimbrelo E, Cruz-Pardos A, Garcia-Rey E, Ortega-Chamarro J: **The survival and fate of acetabular reconstruction with impaction grafting for large defects**. *Clinical orthopaedics and related research* 2010, **468**(12):3304-3313.
28. van der Donk S, Buma P, Slooff TJ, Gardeniers JW, Schreurs BW: **Incorporation of morselized bone grafts: a study of 24 acetabular biopsy specimens**. *Clinical orthopaedics and related research* 2002(396):131-141.

Tables

Table 1: Demographic characteristics

Items	value
Total patients (hips)	15 (15)
Male/female (rate.)	6/9
Median age at operation (year)	68.5±5.6 (58-79)
Median body mass index (kg/m^2)	25.3±2.2 (21.4-30.5)
Median number of previous affected hip surgeries	1.4±0.6 (1-3)
Indication for acetabular revision (no. rate)	
Aseptic loosening	15 (15/15)
Type of surgery (no.rate)	
Acetabular revision	8 (8/15)
THA revision	7 (7/15)
Number of using impacting bone grafting (no. rate)	7 (7/15)
Paprosky Type (no. rate)	
a	9 (9/15)
b	6(6/15)
Median follow-up (months)	66±12.6 (55-105)

Table 2: Comparison of preoperative and the latest follow-up results

Measure	Pre-op	Post-op	Improvement
mHHS	44.4±4.3	74.2±4. 5	29.8±5.4**
UCLA	2.7±0.7	7.3±0.5	4.7±0.5**
SF-36			
Physical functioning	35.9±3.8	42.1±3.7	6.1±1.9*
Role-physical	21.3±3.7	40.7±3.4	19.4±2.8*
Bodily pain	31.7±3.4	66.9±3.4	35.1±3.4**
General health	50.3±2.8	57.9±1.9	7.6±2.7*
Vitality	45.9±2.3	57.4±1.6	11.5±2.6*
Social functioning	63.3±4.4	71.9±2.9	8.7±3.0*
Role-emotional	54.8±4.2	65.1±2.7	10.3±3.9*
Mental health	62.2±2.7	68.4±2.5	6.2±3.0*
LLD (mm)	24.3±2.9	6.1±1.8	18.2±2.8**
COR (mm)	47.3±8.2	25.5±4.6	21.8±5.0**

*: $p<0.05$; **: $p<0.01$; mHHS: Modified Harris Hip Score; UCLA: University of California, Los Angeles activity score; SF-36: 36-item Short Form Health Survey; LLD Limb-length discrepancy; COR: center of rotation, Pre-op: pre-operation; Post-op: post-operation.

Table 3: Review the literature of Paprosky acetabular defects revision using double-cup technique

Author	Cases	Male /Female	Age (years)	Indications	Paprosky Classification	Follow-up	HHS (points) of last follow-up	Complications	Survivorship
Webb JE et al.[3]	20	9/11	67	Osteolysis (50%); aseptic loosening (30%); reimplantation (10%); acetabular defect (5%); tumor (5%)	Paprosky Type 3a (55%); type 3b (40%)	2.4 years	68.7	Complication incidence (40%,8/20); dislocation (30%;6/20); deep infection (20%;4/20); delayed wound healing (15%; 3/20)	No failures at a mean follow-up of 2.36 years; 100% survivorship for aseptic loosening.
Loppini M et al. [10]	16	5/11	68	Aseptic loosening (100%)	Paprosky type 3a (44%); type 3b (56%)	34 months	77.2	Complication incidence (18.8%,3/16); deep venous thrombosis (6.3%;1/16); femoral artery occlusion (6.3%;1/16); postoperative haematoma (6.3%;1/16)	No failures at a mean follow-up of 34 months.
Current series	15	6/9	68.5	Aseptic loosening (100%)	Paprosky type 3a (60%); type 3b (40%)	66 months	74.2	Complication incidence (33.3%,5/15); dislocation (20.0%;3/15); delay wound healing (13.3%;2/15)	No failures at a mean follow-up of 66 months.

Figures

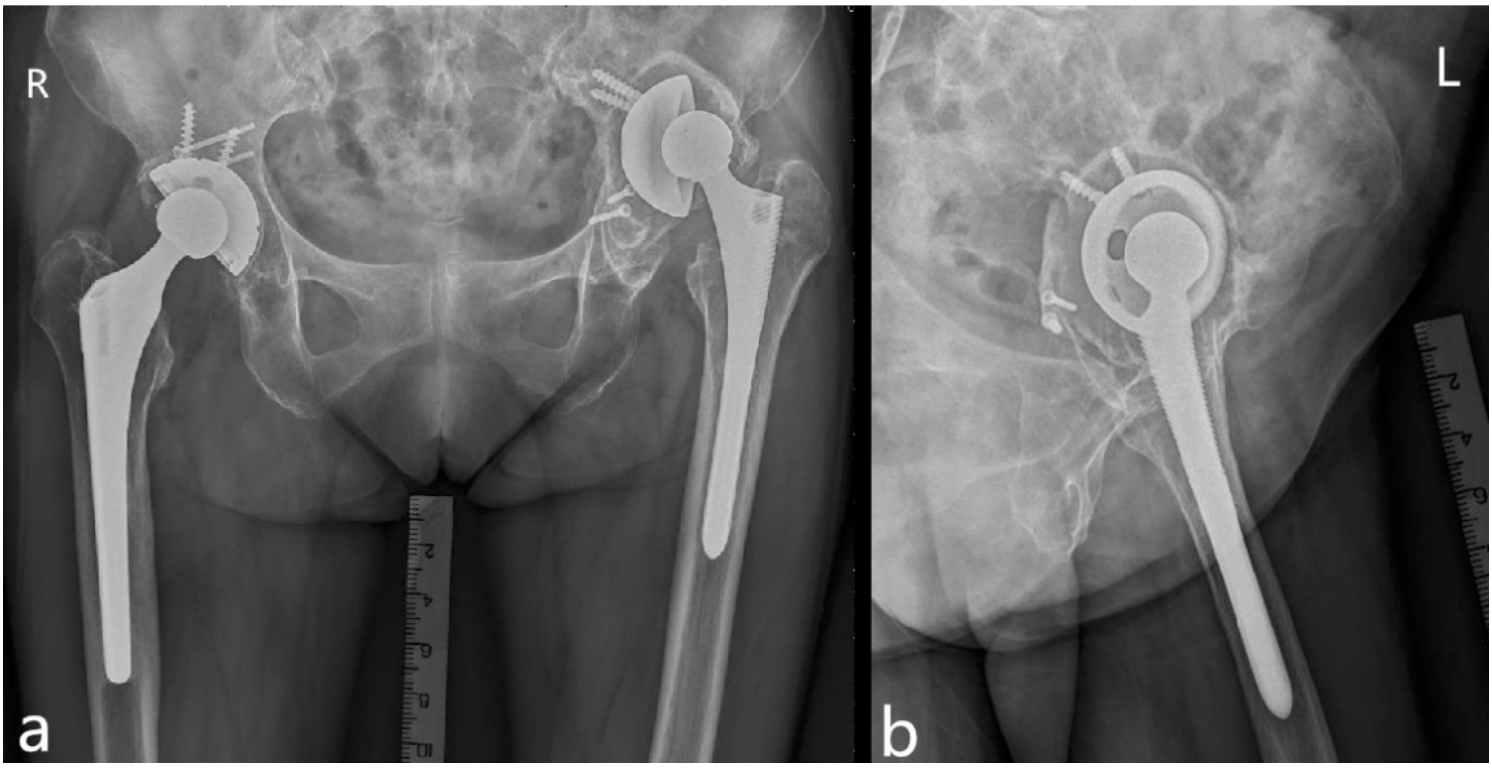

Figure 1

Preoperative radiographs of a 74-year-old female presented with aseptic loosening. Anteroposterior (a) and lateral (b) radiographs showed the failure of both acetabular socket and stem after primary THA, and demonstrated Paprosky type ⅢA acetabular defects.

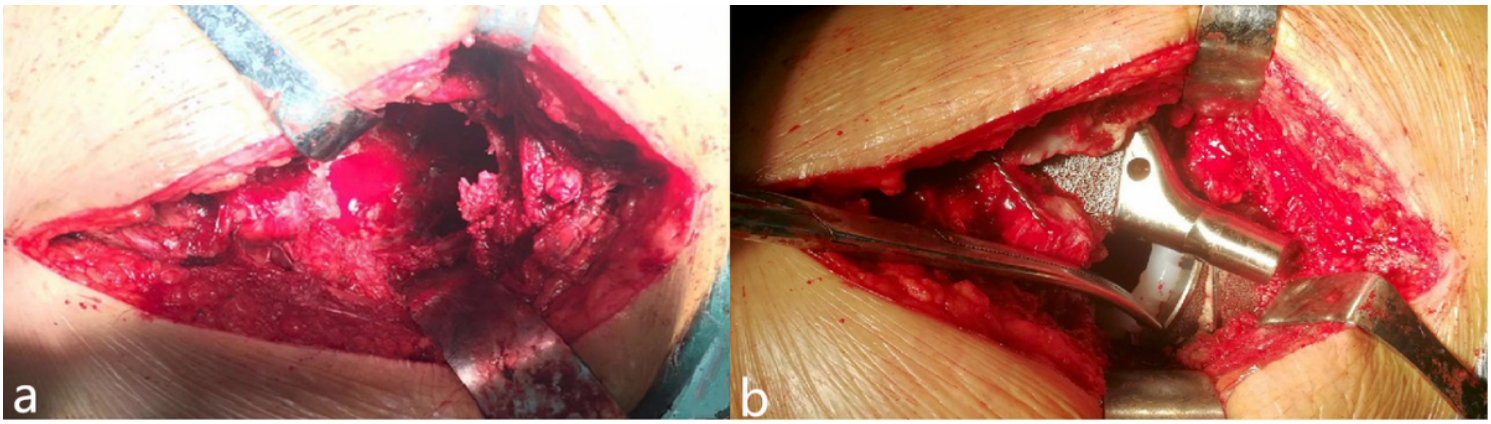

Figure 2

Intra-operative photograph showed the technique of “double-cup” in revision arthroplasty. The acetabular defect was classified and confirmed during operation (a). Intra-operative photograph (b) showed the “double-cup” technique and one monolithic construction after using bone cement between the two cups.

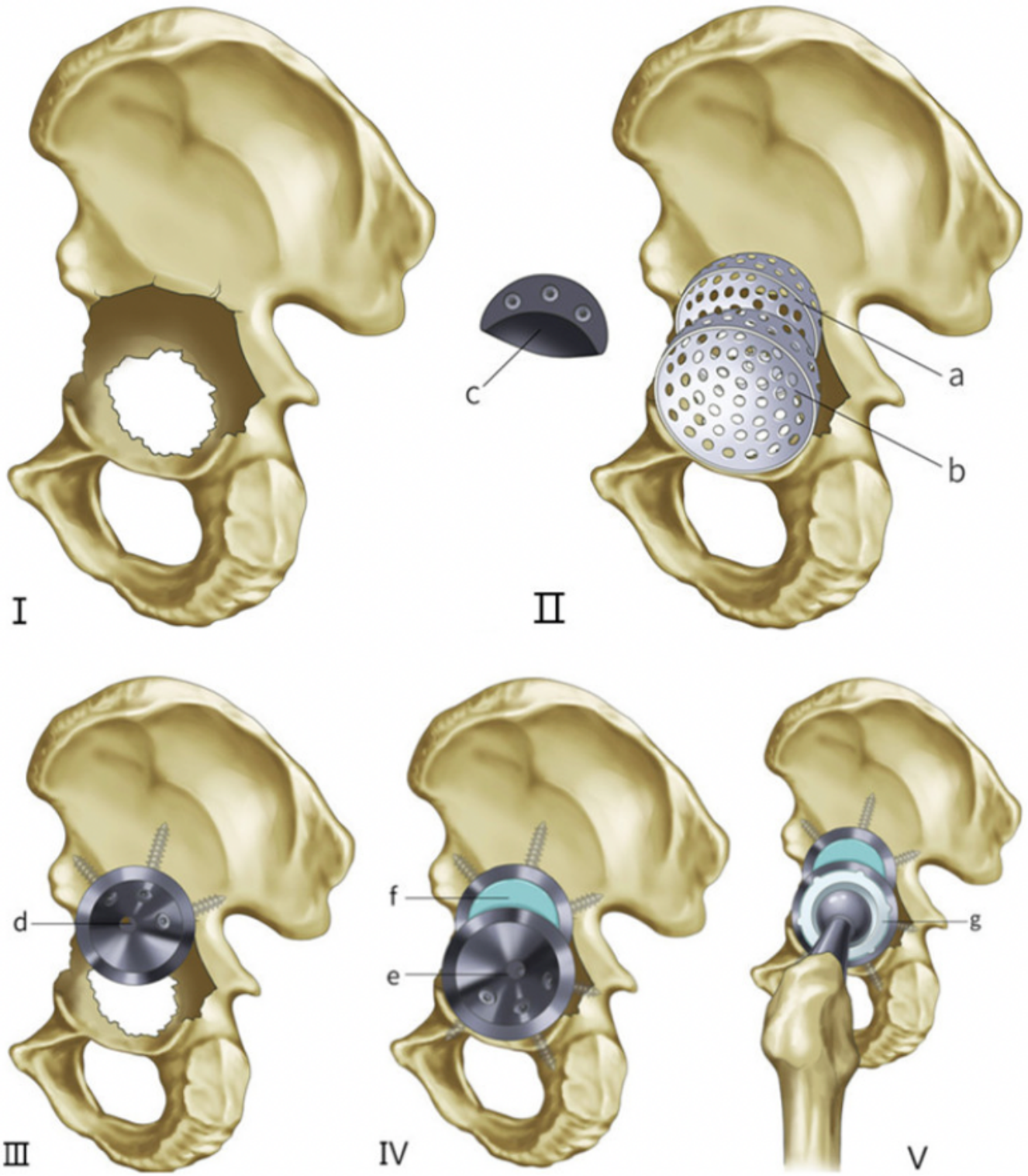

Figure 3

The schematic of the surgical technique of “double-cup”. (▯) The acetabular defect was classified and confirmed during operation. (▯) We gain the appropriate size (a, b, c) and position of prosthesis by trials. (▯) We placed the 2nd cup (d) with or without augment in the superior defect. (▯) We placed the 1st cup (e) with press-fit technique, and used bone cement (f) to create one monolithic construct. (▯) We inserted the polyethylene liner (g) into the 1st cup after cleansing the cement.

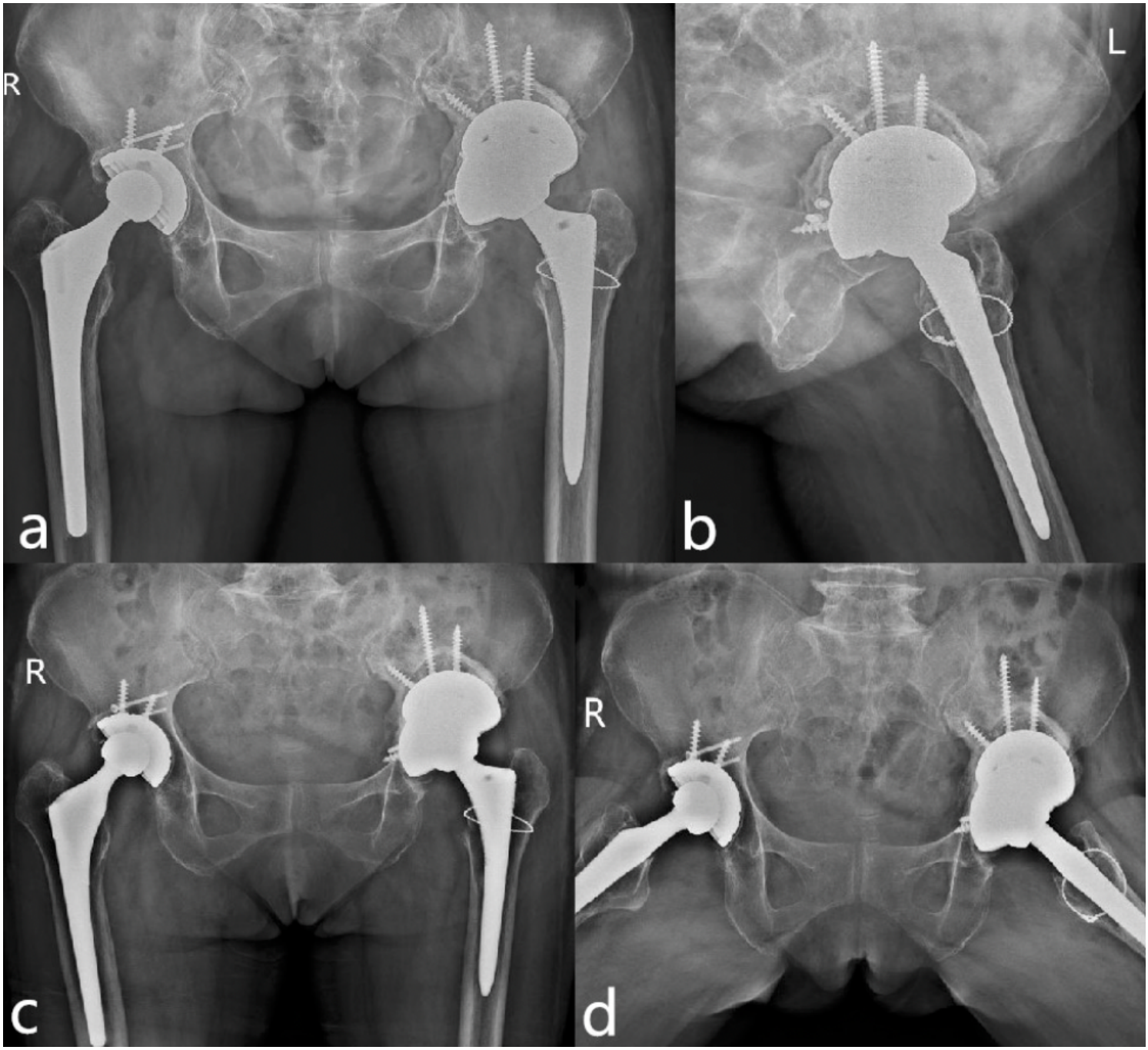

Figure 4

Postoperative radiographs of the same patient after revision hip arthroplasty. Anteroposterior (a) and lateral (b) radiographs showed that “double-cup” buttress bring the hip center of rotation to an anatomic position after operation. Postoperative radiographs (c and d) showed no prosthesis loosening or dislocating at the 1 year follow-up after revision surgery.