Rare, Fatal Pulmonary Fat Embolism after Acupuncture Therapy: A Case Report and Literature Review

Luyao Xu
Southern Medical University
Xiaohui Tan
Southern Medical University
Xuebing Chen
Southern Medical University
Sihao Du
Southern Medical University
Xia Yue
Southern Medical University
Dongfang Qiao
qiaodf@smu.edu.cn

Southern Medical University https://orcid.org/0000-0003-2527-9039

Case Report

Keywords: cause of death, autopsy, pulmonary fat embolism, stress, silver-needle acupuncture

Posted Date: December 31st, 2020

DOI: https://doi.org/10.21203/rs.3.rs-137392/v1

Version of Record: A version of this preprint was published at Forensic Science International on April 1st, 2023. See the published version at https://doi.org/10.1016/j.forsciint.2023.111619.

Abstract

Background: In the clinic, death from nontraumatic pulmonary fat embolism associated with minor soft tissue contusion, surgery, cancer chemotherapy, hematologic disorders and so on has been reported. Patients often present with atypical manifestations and rapid deterioration, making diagnosis and treatment difficult. However, there are no reported cases of death from pulmonary fat embolism after acupuncture therapy. This case aims to emphasize that awareness of nontraumatic pulmonary fat embolism as a complication of acupuncture therapy needs to be improved. In addition, it suggests that in such cases, autopsy should be used to identify the source of fat emboli.

Case presentation: The patient, a 72-year-old woman, experienced symptoms of dizziness and fatigue after silver-needle acupuncture therapy. She experienced a significant drop in blood pressure and died 2 hours later despite treatment and resuscitation. A systematic autopsy and histopathology examination (H&E and Sudan staining) were performed. More than 30 pinholes were observed on the surface of the lower back. Focal hemorrhages were seen surrounding the pinholes in the subcutaneous fatty tissue. Microscopically, numerous fat emboli were observed in the interstitial pulmonary artery and a large number of alveolar wall capillaries, in addition to the vessels of the heart, liver, spleen and thyroid gland. The lungs showed congestion and edema. However, the cause of death was identified as pulmonary fat embolism.

Conclusion: This article suggests that high vigilance for risk factors and the complication of pulmonary fat embolism following silver-needle acupuncture therapy should be exercised. In postmortem examinations, examining the peripheral arterial system and the venous system draining from noninjured sites for the formation of fat emboli is helpful to differentiate posttraumatic and nontraumatic pulmonary fat embolism.

Background

Fat embolism is the partial, subtotal, or total blockage of vessels in multiple organs, such as the lungs and brain, due to the presence of lipid droplets[1]. It is most frequently observed following severe trauma, particularly long bone fractures and contusions in soft tissue rich in adipose tissue. Nontraumatic pulmonary fat embolism associated with minor soft tissue contusion[2, 3], surgery, cancer chemotherapy, hematologic disorders and so on has also been reported[4–18]. Intrinsic or extrinsic stimuli evokes a biological response, known as stress[19]; stress can be induced by trauma, blood loss, hypoxia, pain, heat and cold, fear, infection, surgery, and anesthesia. It should be noted that pulmonary fat embolism caused by stress is sometimes associated with mild tissue damage, but some stress-related factors, such as strong external stimuli and mental stimulation, are essential. Additionally, subclinical conditions, such as obesity, multiple organ adipose hyperplasia and other conditions, may be risk factors for nontraumatic fat embolism[3].

PubMed was searched with different combinations of the following keywords: “fat embolism”, “nontraumatic”, “death”, “autopsy”, and “case report”. Table 1 lists 18 case reports[3–18] (including this case report) of nontraumatic fat embolism caused by stress, summarized by year, PMID, author age, sex, underlying disease, stress factors, early clinical manifestations, diagnosis tool, affected organs and deterioration. None of these cases had severe fatty tissue damage or long bone fractures, and those with surgical trauma had only minor adipose tissue damage. This article reports a case of fat embolism after acupuncture therapy that resulted in death, which has not been reported previously.

Table 1
Nontraumatic Fat Embolism Case Review

Year	PMID	Author	Age (y)	Sex	Underlying diseases	Stress factor	Early clinical manifestations	Diagnosis tool	Organs with fat emboli
-	-	Xu LY, et al.	72	M	Obesity; multiorgan adipose tissue hyperplasia	Acupuncture therapy	Dizziness and fatigue	Autopsy	Lung, liver, heart, spleen, thyroid gland
2018	32379096	Meng YL, et al.	88	F	Hypertension; hyperlipidemia	Hit by a car	No obvious abnormalities	Autopsy	Lung, brain, kidneys, liver, and pancreas
2017	28667706	Sakashita M, et al.	81	M	Hepatocellular carcinoma; alcoholic liver cirrhosis; previous transcatheter arterial chemoembolization treatment	Unclear	No obvious abnormalities	Autopsy	Lung and kidneys
2016	27772594	Scarpino, et al.	64	F	Empyema	Video-assisted thoracic surgery	No obvious abnormalities	BCT and MRI	Brain
2016	27296331	May J, et al.	57	F	Sickle-b + thalassemia, bone marrow necrosis	Unclear	Unclear	CT and MRI	Brain
2016	26704422	Mendoza-Morales RC, et al.	24	F	Unknown	Repetitive gluteal injections of vitamin E (for cosmetic enhancement)	Nausea, vomiting and neurological deficit	Autopsy	Lung and kidney
2016	26701328	Kammeyer R, et al.	54	M	Hemoglobin SC disease	Unclear	Weakness, shortness of breath and lower back pain	MRI	Brain
2015	26413358	Graff DM, et al.	18	F	Hemoglobin SC disease; bone marrow necrosis	Elective erythrocytapheresis and severe pain	Severe pelvic pain and bilateral leg pain	Autopsy	Lung and brain
2015	26252271	Celik SU, wt al.	33	F	Renal angiomyolipoma	Unclear	Shortness of breath, chest pain and tachypnea	CT	Lung
2015	26199788	Schrufer-Poland T, et al.	29	F	Arnold-Chiari malformation, hydrocephalus, spina bifida with tethered cord syndrome, neurogenic bladder	Cesarean delivery	No obvious abnormalities	Autopsy	Lung
2015	25583740	Alobeidi F, et al.	8	F	Sick cell disease; bone marrow necrosis	Unclear	Fever and back pain	MRI	Brain
2009	19457788	Sandstorm, et al.	31	M	Renal angiomyolipoma	Unclear	Heart palpitations, tachycardia and chest pain	MRI	Lung

None of these cases had severe fatty tissue damage or long bone fractures, and those with surgical trauma had only minor adipose tissue damage. The patient presented atypical clinical manifestations and had no obvious abnormalities in the early stage. BCT: Brain computed tomography; MRI: Magnetic resonance imaging; CT: Computed tomography; SC: Sickle cell.

Year	PMID	Author	Age (y)	Sex	Underlying diseases	Stress factor	Early clinical manifestations	Diagnosis tool	Organs with fat emboli
2005	16225231	Karayel, et al.	28	F	Unknown	Vaginal delivery	Loss of conciousness and respiratory distress	Autopsy	Lung
1999	9988613	Bilgrami S, et al.	54	M	Diffuse large-cell lymphoma	Unclear	Diffuse skeletal pain	Autopsy	Lung, kidney, brain and skeletal muscles
1999	9988613	Bilgrami S, et al.	59	F	Diffuse large-cell lymphoma	Unclear	Diffuse skeletal pain	Autopsy	Lung, kidney, and brain
1996	8870880	Schulz F, et al.	46	M	Acute hepatic necrosis caused by fulminant viral hepatitis	Suspected mushroom poisoning	Shock symptoms	Autopsy	Lung, kidney, heart, and brain
1996	8870880	Schulz F, et al.	63	F	Acute hepatic necrosis with steatosis	unclear	unclear	Autopsy	Lung, kidney, heart, brain, and thyroid gland
1995	7748367	Horton, et al.	14	F	Sickle cell anemia and nephrotic syndrome	Unclear	Bone pain, pulmonary edema, seizures, coma, and bilateral flaccid paralysis	MRI	Lung and brain
1986	3767133	Rosen JM, et al.	40	M	Diffuse mixed cellularity lymphoma	Unclear	Hypoxemia	Biopsy and autopsy	Lung

None of these cases had severe fatty tissue damage or long bone fractures, and those with surgical trauma had only minor adipose tissue damage. The patient presented atypical clinical manifestations and had no obvious abnormalities in the early stage. BCT: Brain computed tomography; MRI: Magnetic resonance imaging; CT: Computed tomography; SC: Sickle cell.

Case Presentation

Medical history

The patient, a 72-year-old woman, received silver-needle acupuncture therapy lasting for 2 hours for back pain. The silver needles used for acupuncture were 1.1 mm in diameter. Immediately after the therapy session, the patient showed symptoms of dizziness and fatigue. The symptoms gradually worsened, and she developed an altered mental status, a pale complexion, and pale lips. The physical examination showed the following: T: 36.8°C, R: 20 t/min, P: 124 t/min, and BP: 159/131 mmHg. The bilateral pupils were equal in size and round, and she had light reflex sensitivity, clear respiratory sounds in both lungs and a regular heart rhythm. Her lower back region was swollen, and multiple pinholes oozing blood were observed. The preliminary diagnosis was heart disease and heart failure. Then, 1.5 hours later, the patient's blood pressure dropped to 53/35 mmHg, and she died 2 hours later after treatment and resuscitation. The cause of death was heart disease, heart failure, and respiratory arrest. She had a history of hypertension for more than 20 years; however, any additional medical history was unknown.

Autopsy And Histopathology Findings

An autopsy was performed the next day. The corpse was 168 cm long, and the patient was obese (Fig. 1A). The abdominal wall was 5 cm thick, with fatty hyperplasia of the omentum and mesentery (Fig. 1B). Systematic congestion was observed. The heart weighed 545 g, with epicardial subepicardial adipose tissue hyperplasia (Fig. 1C) and right ventricular wall adipose tissue infiltration. The right atrium and ventricle

were overfilled. There were more than 30 pinholes in the lower back, focal hemorrhages in the subcutaneous fatty tissue surrounding the pinholes and massive hemorrhage in the deep musculature (Fig. 1D-F). No spinal cord injury was found on autopsy. The anterior descending wall of the left coronary artery was notably thickened, with atherosclerotic plaque formation. Level II luminal stenosis was observed, and the lumen was unobstructed. There were no abnormalities in the left circumflex branch of coronary artery or the right coronary artery. Both lungs weighed 1055 g, with substantial congestion and edema. Microscopically, the arterial and interstitial capillaries of the alveolar walls in both lungs near the hilus pulmonis and the marginal tissue were embolized, with smooth-margin vacuoles of varying sizes (Fig. 2A, 2B) that were positive by Sudan staining (Fig. 2C, 2D). The fat emboli were visible in all parts of both lungs under 10 × magnification, with antler-like configurations. Furthermore, similar vacuoles were also observed in the interstitial vessels of the liver, heart, spleen and thyroid (Fig. 3). No other fatal diseases were found, except for diffuse hepatocellular fatty degeneration.

Discussion

Cause of death and mechanism of pulmonary fat embolism

It was clear that the patient died from pulmonary fat embolism according to the diagnostic criteria of pulmonary fat embolism, with samples evaluated at 100 × magnification[1]. There were fat emboli with antler-like configurations that were clearly visible and abundant in all regions of the lungs. There was no sample without fat emboli, indicating degree embolism (massive fat embolism)[1]. The author believes that the specific cause and mechanism of fat embolism warrant attention in this patient. There were more than 30 pinholes in her lower back, and we calculated that the silver needle used for acupuncture was 1.1 mm in diameter; thus, the total area of damaged fat tissue was approximately 0.2851 cm^2. However, fat components in some blood vessels of various organs besides the lungs, such as the liver, heart, spleen and thyroid gland, indicated that there was a substantial amount of circulating fat. Hence, it is believed that the cause of death in this case was severe nontraumatic pulmonary fat embolism, which was made on the basis of the pathology findings, including obesity, multiorgan adipose tissue hyperplasia and stress triggered by silver-needle acupuncture. The mechanism of nontraumatic pulmonary fat embolism is a neuroendocrine effect that leads to an increase in catecholamine secretion, which releases a large amount of peripheral fat into the blood, resulting in an unstable lipid emulsification state, chylomicron agglutination and finally blockage of the interstitial vessels in the lungs[20–22].

Prevention of pulmonary fat embolism as a complication

The adipose tissue damage caused by silver-needle acupuncture was not a risk factor for pulmonary fat embolism. In practice, acupuncture is part of the healing system of traditional Chinese medicine (TCM) and is widely used in many countries throughout the world for pain relief in the neck, shoulders and lower back[23, 24]. Silver-needle acupuncture, as a kind of complementary and alternative medicine (CAM), is a unique branch of acupuncture[25, 26] and has not previously been associated with pulmonary fat embolism. In the clinic, death from fat embolism is not uncommon, as it is a complication of minor trauma, surgery, or other treatments, and thus should be given adequate attention. However, in the event of pulmonary fat embolism, patients present with atypical manifestations (Table 1), making diagnosis and treatment difficult. For example, in this case, the patient developed dizziness immediately after silver-needle acupuncture treatment and heart failure 2 hours later, without a series of manifestations associated with pulmonary fat embolism, such as dyspnea, chest pain and hemoptysis. It should be noted that the patient had signs of respiratory insufficiency, cerebral dysfunction, and skin ecchymosis[20, 21, 27]. Evidently, ageing, obesity, underlying diseases, mental status and irritation due to treatment protocols may be risk factors for stress-induced pulmonary fat embolism, so the choice of treatment must be in strict accordance with the indications and contraindications, and the patient should be closely observed for any related clinical manifestations to reduce the occurrence of complications and adverse events[23]. This case suggests that when the patient's condition suddenly deteriorates or respiratory insufficiency develops after physiotherapy to relieve pain, such as acupuncture, the possibility of pulmonary fat embolism should be considered, and a prompt diagnosis and treatment should be provided.

Differential diagnosis of fat embolism source

This was a very interesting case of pulmonary fat embolism that was suspected to be due to stress. In fatal posttraumatic pulmonary fat embolism caused by subcutaneous soft tissue contusion, there are no uniform criteria regarding the area of the damage or the extent of the injury.

Moreover, in fatal pulmonary fat embolism cases, the soft tissue contusion area generally affects 30–35% of the body surface[27, 28]. Some studies have also shown that fat compression in different body regions can range from 20 cm^2 to 21–70 cm^2[2]. In this case, based on the isolated puncture injuries on the skin, the nature of the adipose tissue injury was wounds formed by needle pricks and peripheral bleeding due to ruptured vessels and blood infiltration, not soft tissue contusions. In addition, the degree (about 0.2851 cm^2 by 30 pinholes) of adipose tissue damage in this case was very low and far from the degree of adipose tissue damage noted in previous reports.

Those performing postmortem autopsy and histopathology examinations of patients who died of suspected of pulmonary fat embolism should take into account whether there was a history of trauma, and the degree of adipose tissue damage should be assessed. Significantly

minor adipose tissue injury in the presence of trauma is an indication of death from nontraumatic pulmonary fat embolism. Examinations of sites for fat emboli should include each major organ[3] as well as the peripheral arterial system and the venous system draining from noninjured sites to identify the possible source of the fat embolus. It has been reported that biochemical testing of the deceased's cardiac blood should be performed, with attention to abnormal changes in VLDL, cholesterol, TG, FFA, and CRP[3]. Lipid analysis of fat emboli, if necessary, may also be performed, which may suggest a possible mechanism of pulmonary fat embolism formation[4]. Moreover, attention should be paid to individual factors and subclinical conditions, such as obesity, multiple organ adipose hyperplasia and other condition, that may be risk factors for nontraumatic fat embolism[3].

There are some limitations in this report, including the availability of clinical examination results for the patient before and after silver-needle acupuncture; this prevented us from knowing the full extent of the patient’s underlying diseases and collecting fresh tissue from additional organs for Sudan III staining. We report a case of nontraumatic pulmonary fat embolism resulting in death following acupuncture, which has not been reported previously. Despite this case, acupuncture therapy is not considered to be a dangerous; however, the major risk factors for nontraumatic pulmonary fat embolism need to be emphasized in relation to similar treatments.

Conclusions

The patient developed dizziness immediately after treatment with silver-needle acupuncture and died 2 hours later, without a series of manifestations indicative of pulmonary fat embolism. In the early stage of nontraumatic pulmonary fat embolism, clinical symptoms were atypical, and deterioration was rapid. Consequently, it is suggested that when a patient's condition suddenly deteriorates or respiratory insufficiency develops after physiotherapy, the possibility of pulmonary fat embolism should be considered, and a differential diagnosis should be provided.

In the presence of risk factors, such as obesity and multiorgan adipose tissue hyperplasia, stress caused by silver-needle acupuncture can lead to fatal pulmonary fat embolism.

In forensic pathology practice, it is essential to identify the fat emboli source by autopsy and histology examination when the case involves fat embolism.

Abbreviations

H&E
Hematoxylin and eosin
TCM
Traditional Chinese medicine
CAM
Complementary and alternative medicine
VLDL
Very low-density lipoprotein
TG
Triglyceride
FFA
Free fatty acid
CRP
C-reactive protein

Declarations

Ethics approval and consent to participate

This article does not contain any studies with human participants or animals. Ethics approval is not applicable. Informed consent was given by the family of the deceased.

Consent for publication

All authors approve the submission of this paper.

Availability of data and materials

The datasets used and/or analyzed during the current study are available from the corresponding author upon reasonable request.

Competing interests

The authors declare that they have no competing interests.

Funding

None.

Authors' contributions

XL analyzed the patient data regarding pulmonary fat embolism, reviewed the literature and was a major contributor in writing the original manuscript. QD made substantial contributions to the conception and design of the work and evaluation of the patient data. QD, TX, DS, CX and YX performed the autopsy and histology examinations of important organs and revised the manuscript. All authors read and approved the final manuscript.

Acknowledgements

We sincerely appreciate the School of Forensic Medicine, Southern Medical University for the use of instruments, equipment and relevant experimental materials.

Authors' information

Affiliations

Department of Forensic Pathology, School of Forensic Medicine, Southern Medical University, 510515, Guangzhou, Guangdong, China.

Luyao Xu, Xiaohui Tan, Xuebing Chen, Sihao Du, Xia Yue, Dongfang Qiao

References

1. Dettmeyer RB. Forensic Histopathology – Fundamentals and Perspectives. Springer-Verlag Berlin Heidelberg 2011; 2011.
2. Bolliger SA, Muehlematter K, Thali MJ, Ampanozi G. Correlation of fat embolism severity and subcutaneous fatty tissue crushing and bone fractures. INT J LEGAL MED. 2011;125(3):453–8. doi:10.1007/s00414-011-0563-8.
3. Meng Y, Zhang M, Ling H, Huang S, Miao Q, Yu Y, et al. Nontraumatic Multiple-Organ Fat Embolism: An Autopsy Case and Review of Literature. Am J Forensic Med Pathol. 2020;41(2):131–4. doi:10.1097/PAF.0000000000000544.
4. Sakashita M, Sakashita S, Sakata A, Uesugi N, Ishige K, Hyodo I, et al. An autopsy case of non-traumatic fat embolism syndrome. PATHOL INT. 2017;67(9):477–82. doi:10.1111/pin.12556.
5. Scarpino M, Lanzo G, Cappelli F, Moretti M, Misuri G, Voltolini L, et al. Cerebral Fat Embolism After Video-Assisted Thoracic Surgery. ANN THORAC SURG. 2016;102(5):e409–11. doi:10.1016/j.athoracsur.2016.04.073.
6. May J, Sullivan JC, LaVie D, LaVie K, Marques MB. Inside Out: Bone Marrow Necrosis and Fat Embolism Complicating Sickle-beta + Thalassemia. AM J MED. 2016;129(12):e321–4. doi:10.1016/j.amjmed.2016.05.027.
7. Mendoza-Morales RC, Camberos-Nava EV, Luna-Rosas A, Garces-Ramirez L, De la Cruz F, Garcia-Dolores F. A fatal case of systemic fat embolism resulting from gluteal injections of vitamin e for cosmetic enhancement. FORENSIC SCI INT. 2016;259:e1–4. doi:10.1016/j.forsciint.2015.11.012.
8. Kammeyer R, Devnani R, Mehta R. Cerebral fat embolism syndrome mimicking thrombotic thrombocytopenic purpura in a patient with hemoglobin SC disease. AM J HEMATOL. 2016;91(5):539–42. doi:10.1002/ajh.24286.
9. Graff DM, Owen E, Bendon R, Bertolone S, Raj A. Distinctive Acellular Lipid Emboli in Hemoglobin SC Disease following Bone Marrow Infarction with Parvovirus Infection. Case Rep Hematol 2015, 2015:328065. doi:10.1155/2015/328065.
10. Celik SU, Kocaay AF, Sevim Y, Cetinkaya OA, Atman ED, Alacayir I. Renal Angiomyolipoma With Caval Extension and Pulmonary Fat Embolism: A Case Report. Med (Baltim). 2015;94(31):e1078. doi:10.1097/MD.0000000000001078.
11. Schrufer-Poland T, Singh P, Jodicke C, Reynolds S, Maulik D. Nontraumatic Fat Embolism Found Following Maternal Death after Cesarean Delivery. AJP Rep. 2015;5(1):e1–5. doi:10.1055/s-0034-1394153.
12. Alobeidi F, Inusa BP, Singh RR, U-King-Im JM. Cerebral microhaemorrhages secondary to fat embolus syndrome in sickle cell disease. POSTGRAD MED J. 2015;91(1071):55–6. doi:10.1136/postgradmedj-2014-132984.

13. Sandstrom CK, Pugsley J, Mitsumori LM. Renal angiomyolipoma with nontraumatic pulmonary fat embolus. AJR Am J Roentgenol. 2009;192(6):W275–6. doi:10.2214/AJR.08.2041.
14. Karayel F, Arican N, Kavas G, Turan AA, Pakis I. Maternal death due to non-traumatic fat embolism. J FORENSIC SCI. 2005;50(5):1201–3. https://pubmed.ncbi.nlm.nih.gov/16225231/.
15. Bilgrami S, Hasson J, Tutschka PJ. Case 23-1998: fat embolism. N Engl J Med. 1999;340(5):393–4. doi:10.1056/NEJM199902043400516.
16. Schulz F, Trubner K, Hildebrand E. Fatal fat embolism in acute hepatic necrosis with associated fatty liver. Am J Forensic Med Pathol. 1996;17(3):264–8. doi:10.1097/00000433-199609000-00016.
17. Horton DP, Ferriero DM, Mentzer WC. Nontraumatic fat embolism syndrome in sickle cell anemia. PEDIATR NEUROL. 1995;12(1):77–80. doi:10.1016/0887-8994(94)00108-e.
18. Rosen JM, Braman SS, Hasan FM, Teplitz C. Nontraumatic fat embolization. A rare cause of new pulmonary infiltrates in an immunocompromised patient. Am Rev Respir Dis. 1986;134(4):805–8. doi:10.1164/arrd.1986.134.4.805.
19. Yaribeygi H, Panahi Y, Sahraei H, Johnston TP, Sahebkar A. The impact of stress on body function: A review. EXCLI J. 2017;16:1057–72. doi:10.17179/excli2017-480.
20. Hulman G. Pathogenesis of non-traumatic fat embolism. LANCET. 1988;1(8599):1366–7. doi:10.1016/s0140-6736(88)92182-4.
21. Nixon JR, Brock-Utne JG. Free fatty acid and arterial oxygen changes following major injury: a correlation between hypoxemia and increased free fatty acid levels. J Trauma. 1978;18(1):23–6. doi:10.1097/00005373-197801000-00004.
22. Geoffrey H. PATHOGENESIS OF NON-TRAUMATIC FAT, EMBOLISM. The Lancet 1988, 331(8599). doi:10.1016-S0140-6736(88)92182-4.
23. Lim TK, Ma Y, Berger F, Litscher G. Acupuncture and Neural Mechanism in the Management of Low Back Pain-An Update. Medicines (Basel) 2018, 5(3). doi:10.3390/medicines5030063.
24. Sierpina VS, Frenkel MA. Acupuncture: a clinical review. SOUTH MED J. 2005;98(3):330–7. doi:10.1097/01.SMJ.0000140834.30654.0F.
25. Li T, Wang S, Zhang S, Shen X, Song Y, Yang Z, et al. Evaluation of clinical efficacy of silver-needle warm acupuncture in treating adults with acute low back pain due to lumbosacral disc herniation: study protocol for a randomized controlled trial. TRIALS. 2019;20(1):470. doi:10.1186/s13063-019-3566-2.
26. Wang F. Silver-needle therapy for clinical pain management. Chinese J Pain Med. 2003;9(3):173–81.
27. Shiying L, Donghua Z, Zhiqiang Q, Ningguo L, Jianhua Z, Zhengdong L, et al. Nonfracture-Associated Pulmonary Fat Embolism After Blunt Force Fatality: Case Report and Review of the Literature. The American Journal of Forensic Medicine Pathology 2015, 36(2). doi:10.1097/PAF.0000000000000142.
28. Danica C, Vladimir I, Slobodan N. An unusual case of pulmonary fat embolism following blunt trauma. Forensic Sci Med Pathol 2019, 15(2). doi:10.1007/s12024-018-0053-0.

Figures

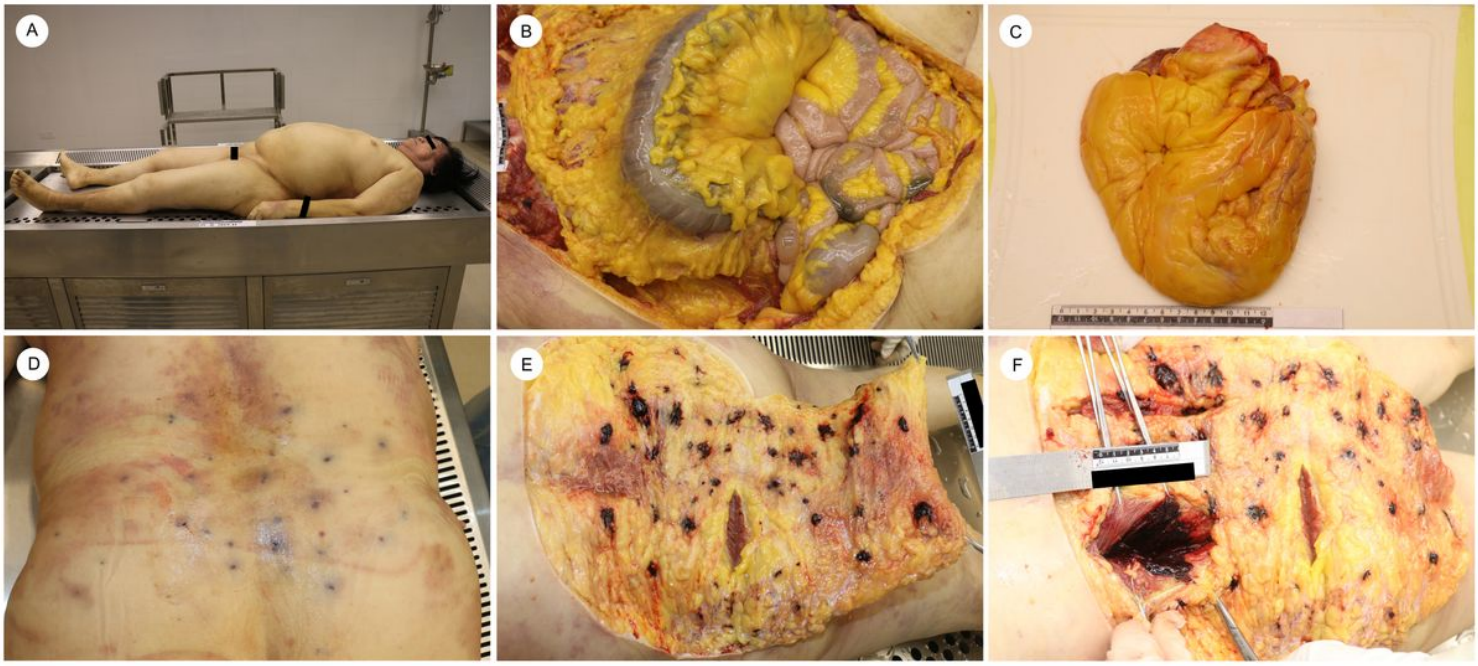

Figure 1

Gross examination and autopsy showing obesity and pinholes on the lower back. (A, B and C) The body of the deceased indicated central obesity and hyperplasia of adipose tissue in the abdominal wall, peritoneum and omentum majus. The epicardium also contained abundant fatty tissue. (D) There were more than 30 dot-shaped pinholes on the surface of the lower back, with slightly more on the right side than on the left side. (E) Focal hemorrhage around each pinhole were observed in the subcutaneous fat layer. (F) Some of the pinholes corresponded to severe hemorrhages in deep muscle tissue.

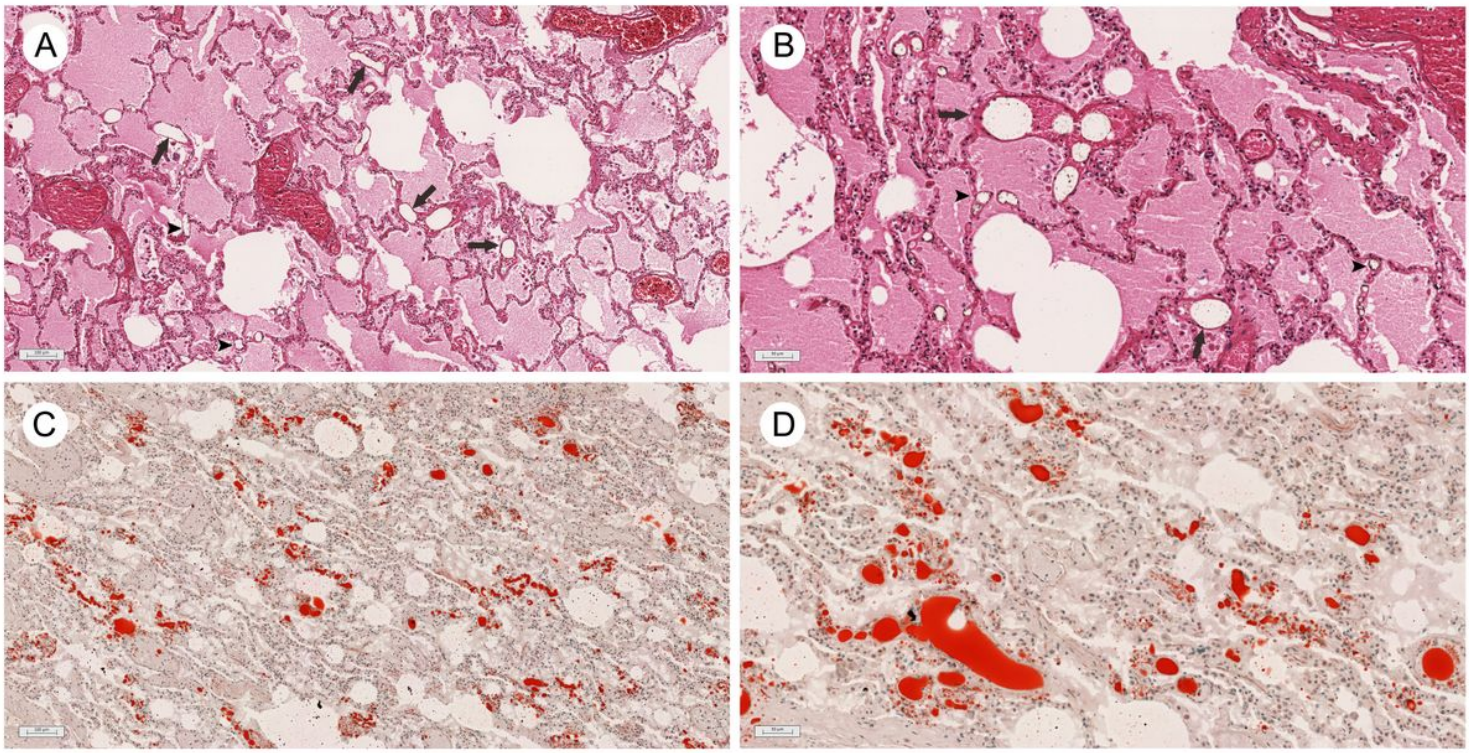

Figure 2

H&E staining and Sudan III staining of lung tissue. (A and B) H&E staining showed diffuse alveolar edema. There were numerous rounded vacuoles in the interstitial blood vessels with brown floc-like substances distributed on the edges or inside the vacuoles (larger diameter

vessels →; smaller diameter vessels) (A H&E, ×5; B H&E ×10). (C and D) Sudan III staining revealing numerous vacuoles of alveolar wall vessels. Severe pulmonary fat embolism was identified (C Sudan III ×5; D Sudan III ×10).

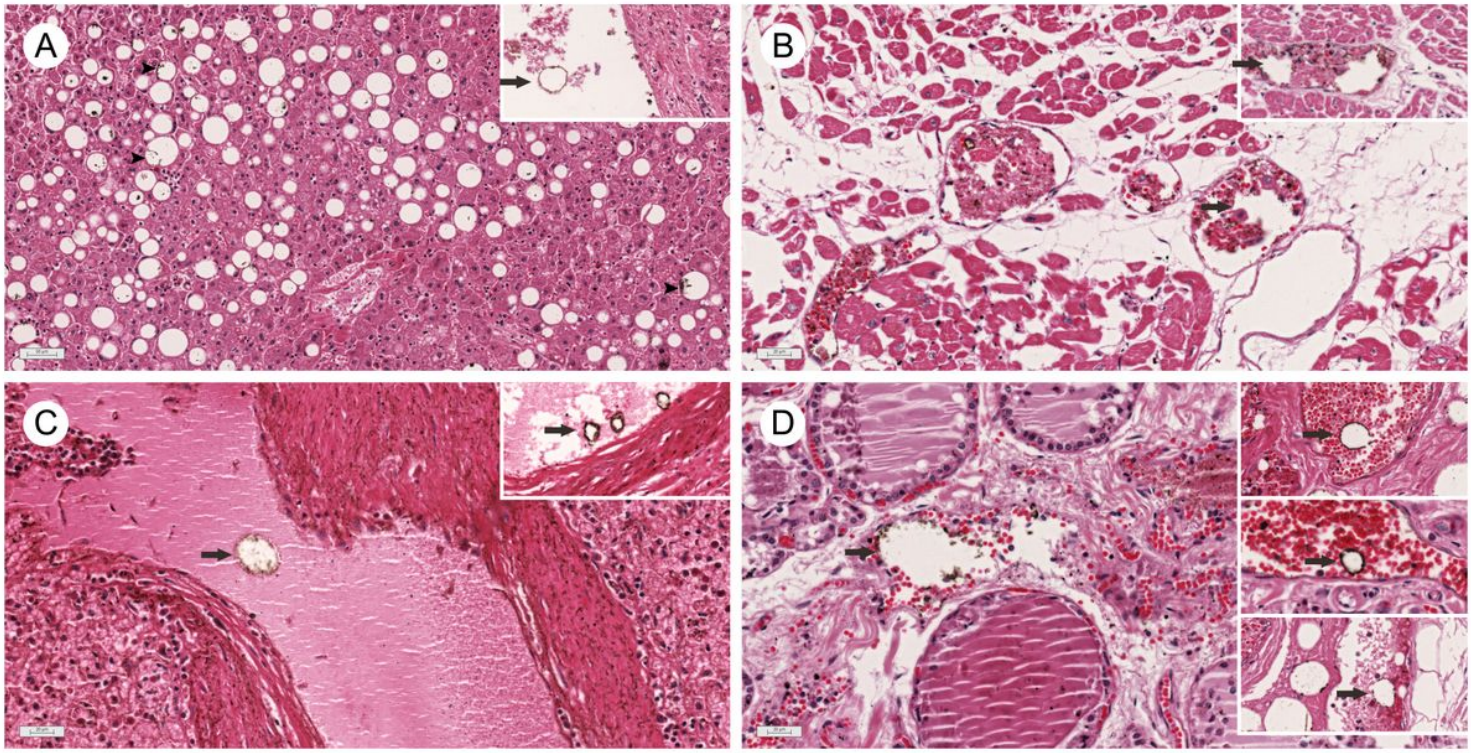

Figure 3

H&E staining showed fat emboli in tissues of various organs, in the arterial system, and in the venous system draining from noninjured sites. The rounded vacuoles indicated by the arrows had a brownish flocculent or granular distribution of a substance that was considered fat emboli. (A) Hepatic tissue: hepatic lobular structures were recognizable, with diffuse fatty degeneration of hepatocytes around the central vein ( ); the fat emboli described above in the portal vein in the portal area (→) (H&E ×10). (B) Myocardial tissue: the same brown-edged fat emboli in the interstitial myocardial vessels (→) (H&E ×20). (C) Splenic tissue: the same brown-edged fatty vacuoles in the splenic artery (→) (H&E ×20). (D) Thyroid gland: the same brown-edged fatty vacuoles in the interstitial tissue of the thyroid gland and in the interstitial arteries and veins of the surrounding soft tissues (→) (H&E ×20).