New Classification Based on CT and Its Value Evaluation for Fractures of the Lateral Process of the Talus

Yuchuan Wang
Third Hospital of Hebei Medical University
Xiangtian Deng
Nankai University
Yanbin Zhu
Third Hospital of Hebei Medical University
Zhongzheng Wang
Third Hospital of Hebei Medical University
Lei Fu
Third Hospital of Hebei Medical University
Wei Chen
Third Hospital of Hebei Medical University
Yingze Zhang (yzzhang2020@126.com)
Third Hospital of Hebei Medical University

Research Article

Keywords: CT scan classification, Interobserver agreement, LTPF, Reliability

Posted Date: May 12th, 2021

DOI: https://doi.org/10.21203/rs.3.rs-138940/v2

Abstract

Background : The common classifications of the fractures of the lateral process of the talus LTPFs are based on radiographs and may underestimate the complexity of LTPF, therefore. The aim of this study was to propose a comprehensive CT-based classification system, and to evaluate its prognostic value, reliability and reproducibility.

Material and Methods: We retrospectively reviewed 42 patients involving LTPF and clinical and radiographic evaluations were performed at an average follow-up of 35.9 months. In order to create a comprehensive classification, a panel of experienced orthopedic surgeons discussed the cases. All fractures were classified according to Hawkins, McCrory-Bladin and new proposed classification system by four surgeons. The analysis of interobserver and intraobserver agreements was done using kappa statistics.

Results: This new classification included two types based on presence of concomitant injuries or not, with type I consisting of three subtypes and type II of five subtypes. Average AOFAS score was 91.5 in the type Ia of new classification proposed, 86 in type Ib, 90.5 in type Ic, 89 in type IIa, 76.7 in type IIb, 76.6 in type IIc, 91.3 in type IId, and 83.5 in type IIe. Interobserver and intraobserver reliability of the new classification system were almost perfect (κ=0.846 and 0.823, respectively) showing a higher interobserver and intraobserver reliability compared to the Hawkins classification (κ=0.737 and 0.689, respectively) as well as McCrory-Bladin classification (κ=0.748 and 0.714, respectively).

Conclusion: The new classification system is a comprehensive one that takes into account concomitant injuries and it shows good prognostic value with clinical outcomes. It is more reliable and reproducible and could be a useful tool for decision-making on treatment options for LTPFs.

Introduction

Fracture of the lateral process of the talus (LTPF) occurs infrequently, accounting for 20% of talar fractures and 0.02% to 0.17% of all fractures in human body[1-4]. Due to the progressive expansion in recreational sport activities, mainly snowboard, their incidence has markedly increased[5, 6]. For this reason, the LTPF has been termed a ‘snowboarder's fracture’[7]. Despite its increasing incidence, the LTPF is difficult to diagnose and commonly overlooked on initial plain radiographs, as it may be subtle and difficult to visualize, with a misdiagnosis rate of 15% and up to 21% by radiographs alone[8]. Therefore, CT scan can be used to verify the LTPF and should be considered when more accurately diagnosing the LTPF[9, 10].

In 1965, Hawkins initially classified LTPF into three types, simple fractures (Type I), comminuted fractures (Type II) and chip fractures (Type III)[11]. Based on Hawkins’ classification, McCrory and Bladin reorganized and proposed a similar fracture classification system, but just in a different order[12]. After then, Tinner and Sommer subdivided type III of McCrory-Bladin classification into three subtypes, but didn't consider the concomitant injuries of LTPF[13]. All of the above classification systems are based on

radiographs and possibly that they might underestimate the complexity of LTPF. It was estimated that, LTPF were associated with 19.6% of talar neck fractures and 24% of all talar body fractures[14, 15]. LTPF may also be combined with fractures of talar head and posterior process[3]. However, by far as we know, these concomitant injuries have not been considered in any classification system regarding LTPF. Prompt and accurate diagnosis and classification of LTPF are crucial for optimized perioperative management[16]; moreover, detailed and extensive knowledge of concomitant injuries are conductive in surgical scheme making and contributed to obtaining of a better surgical outcomes. Sadly, up to date we are missing a comprehensive classification for the LTPF, which should include evaluation of LTPF and their concomitant injuries based on CT scan[17].

The objective of this study was to propose a comprehensive classification system for the LTPF based on CT and to evaluate its prognostic value, reliability and repeatability, which will help surgeons to develop treatment plans for patients with LTPFs.

Methods

Patients

The study was approved by the Ethics Committee of the Third Hospital of Hebei Medical University (K2015-001-12), according to the Helsinki Declaration. Written informed consent was obtained from all participants. We retrospectively reviewed 370 patients with talus fractures treated at the Third Hospital of Hebei Medical University between 2014 and 2020. Inclusion criteria to the study were: (1) older than 18 years; (2) fractures involving the lateral process of the talus; (3) preoperative and postoperative ankle plain radiographs available and (4) a preoperative CT scan available for review. Cases were excluded if they involved age less than 18 years, incomplete medical records or radiologic images, and lost to follow-up. A total of 42 consecutive patients (43 cases of LTPF, including one patient with bilateral fractures) were finally enrolled in our study. Demographical and clinical data such as sex, age, affected side, and accompanying injuries were collected from the electronic medical record, and the radiographs were evaluated by the Picture Archiving and Communication System. On plain radiograph the presence of complications like, non-union arthrosis, or malunion were assessed and clinical evaluation using AOFAS (The American Orthopaedic Foot and Ankle Society) score were performed at last follow-up. Based on this, we examined the localization and conformation of each fracture. Furthermore, the description of the fracture mentioned in the operative report was analyzed. In this context, fracture size, location, number, and comorbidities were documented. These cases were discussed jointly by three orthopedic surgeons, who are experienced in orthopedic trauma surgery. Within the scope of this case discussion, we arrived at a new classification and treatment recommendations.

Investigators and Survey

After fully understanding the classification system, four senior orthopaedic surgeons classified independently the chosen fractures (n=43) according to the Hawkins classification, the McCrory-Bladin classification and the new classification proposed. Among the four surgeons, two had more than 5 years

of experience in orthopedic trauma surgery and two were senior residents. A second round of classifying was performed two weeks later, and the case order was scrambled using a random number generator.

Statistical analysis

The Spearman correlation coefficients between the AOFAS scores and the new classification, Hawkins classification and McCrory-Bladin classification were used to assess the prognostic value of each types of fracture we evaluated. Multivariate regression analysis was used to detect factors (age, sex, type of surgery, etc.) other than classifications to predict AOFAS. Finally, the Generalized Linear Model (GLM) was developed with AOFAS as the dependent variable and classifications as the covariate to compare the prediction strength of each classification. The partial ETA square was used to measure the prediction strength.

Interobserver reliability was evaluated to determine the reliability of the opinions of different observers for each case. By contrast, intraobserver reliability was evaluated to determine the reliability of individual observers by comparing the first and second-round surveys for each case.

To determine the reliability of the classification systems we evaluated the interobserver agreement for each classification system using the Fleiss Kappa coefficient[18]. In order to evaluate the reproducibility of the classification system we calculated the intraobserver agreement using the Cohen Kappa coefficient[19]. Data analysis was conducted with IBM SPSS Statistics 21.0. The coefficients are interpreted using the Landis and Koch grading system[20], which defines the reliability or reproducibility of κ values 0.2 as slight, between 0.2 and 0.4 as fair, between 0.4 and 0.6 as moderate, between 0.6 and 0.8 as substantial, and values > 0.8 as perfect.

Results

Proposed Classification System

The new classification includes two types according to whether the LTPF is an isolated fracture or not.

Type I is an isolated fracture. This type is further divided into three subtypes (Fig.1):

Ia: chip fracture without inclusion of the talofibular joint.

Ib: simple fracture with involvement of the talofibular joint.

Ic: multiple fragment fracture with joint involvement.

Type II is a fracture of the lateral process of the talus combined with other parts of the ipsilateral talus, whether or not the articular surface is involved. This type is divided into five subtypes (Fig.2):

IIa: lateral process fracture combined with talar head fracture.

IIb: lateral process fracture combined with talar neck fracture.

IIc: lateral process fracture with extension into the remainder of the talar body.

IId: lateral process fracture combined with talar posterior process fracture.

IIe: lateral process fracture combined with any two or more other fractures of the ipsilateral talus.

Baseline characteristics

A total of 42 patients were included in this study, of whom 37 were male and 5 were female, with a mean age of 34.9 years (range 18-65). Baseline data for all patients included are shown in Table 1. Among all 43 cases of LTPF, there were 9 fractures that were visible on CT but not on radiographs and the overall missed diagnosis rate was 20.9% (9/43). All the fractures were classified according Hawkins, McCrory-Bladin and new classification system (Table 1).

Clinical results

Average ± standard deviation AOFAS score was 91.5±1.5 in the type Ia of new classification proposed, 86.0±0 in type Ib, 90.5±9.5 in type Ic, 89.0±0 in type IIa, 76.7±15.6 in type IIb, 76.6±24.4 in type IIc, 91.3±6.6 in type IId, and 83.5±11.0 in type IIe. Complications like nonunion and arthritis were observed in 7 cases (16.3%). (Table 2)

Classification-related therapeutic recommendations

In order to create classification-related therapeutic recommendations, all relevant cases were evaluated according to the new classification and appropriate treatment recommendations were made. These recommendations are based on expert knowledge and analysis of the current literature. Type Ia is best treated with open reduction and internal fixation (ORIF), type Ib with excision and type Ic with casting. Fractures presenting late that are un-united should be excised if small and internally fixed if large. For all patients with type II, we recommend ORIF and fractures presenting late that are not united should be excised if small or fixed internally if large.

Prognostic value

Compared with Hawkins classification and McCrory-Bladin classification, a higher ordinal correlation was found between the new classification and AOFAS score. Spearman correlation coefficient was -0.115 for new classification system, 0.067 for Hawkins classification and -0.048 for McCrory-Bladin classification. The results of multivariate analysis showed that factors besides classification did not influenced the AOFAS score. Finally, the GLM was used to compare the prediction strength of each classification and the results show that the new classification has a higher partial ETA square. The new classification system had a partial eta squared of 0.018, McCrory-Bladin classification of 0.003, and Hawkins classification <0.001.

Interobserver agreement

The average κ value among the three reviewers was 0.737 when classifying LTPFs using the Hawkins classification system, 0.748 when using McCrory-Bladin classification and 0.846 when using the new classification system (Table 3). As can be seen, the new classification showed the highest interobserver reliability.

Intraobserver agreement

The κ value was 0.689 when classifying LTPFs using the Hawkins classification system, 0.714 when using the McCrory-Bladin classification and 0.823 when using the new classification proposed (Table 4). Similarly, the new classification system has a higher intraobserver agreement than the other two classifications.

Discussion

In this study, we proposed a new and comprehensive classification for LTPF based on CT scan. It was divided into two types according to whether the LTPF was an isolated fracture or not: type I was further divided into three subtypes and type II was divided into five subtypes. This proposed new classification system is simple, comprehensive and easy to remember, and has higher prediction strength, inter-observer reliability, and intra-observer reliability, which we believe will provide useful information on treatment scheme making.

An ideal fracture classification system should be simple, comprehensive, reliable and reproducible[21]. Although various foot classification systems, such as the AO/OTA classification or Sneppen classification[22], do include LTPF, Hawkins as well as McCrory and Bladin are the only two classifications specifically focusing on LTPF[11, 12, 17]. Unfortunately, both classifications are based on plain radiographs. The diagnosis may be difficult and underestimate the extent of such fractures, and the radiographs may be normal[23]. The main objective of the radiology report should be to convey the full range of fracture patterns rather than attempting to fit complex LTPF into a limited classification scheme. Additional CT scan must be employed in every patient in whom clinical doubts exist, providing additional information on concomitant injuries or associated fractures[24], which is possibly beneficial for operative program making. Our study showed that although the currently used LTPF classification system (Hawkins and McCrory-Bladin) is simple enough, its main limitations are demonstrated by its lack of comprehensiveness, failure to take into account concomitant injuries, and exhibiting moderate to substantial reliability and reproducibility. Thus, it appears that an establishment of a classification based on CT scanning, which relates in particular to the concomitant injuries or associated fractures, is necessary.

Therefore, we proposed a new CT-based classification system for comprehensive typing of LTPF and evaluated the correlation between different types of fractures and clinical prognosis using the AOFAS score to check the prognostic value of the proposed classification. Not only did the new classification

comprehensively cover the types of LTPFs, but our study also demonstrated the new classification system had a higher prognostic value. Furthermore, consistent with our hypothesis, the analysis results showed higher reliability and reproducibility of the new classification than currently used classification systems. While the Hawkins and McCrory-Bladin classification showed considerable substantial reliability and reproducibility, but the new classification showed a perfect reliability and reproducibility. This difference may be due to the use of a CT scan as a preoperative imaging modality, which permits a better identification of all fragments, their displacements and the areas of comminution.

LTPF is an injury that is often missed because most cases are considered trivial ankle sprains due to nonvisualization of fracture on radiographs, with a resultant overall misdiagnosis rate of 15% and up to 21% by radiographs alone[25, 26]. In our study, there were 9 cases of LTPF that were visible on CT but not on radiographs and the overall missed diagnosis rate was 20.9%（9/43）, which was in line with previous literature. Missed or untreated LTPFs can potentially lead to permanent pain, healing in malposition, impingement syndrome, pseudoarthrosis development and also, due to joint instability, induced a potential development of severe subtalar arthritis[27]. The presence of normal radiographs creates difficulty assessing the progress of the fracture. Jonathan recommended that both skeletal scintigraphy and CT scanning should be used in the resistant ankle sprain[9], and we believe that CT examinations are at least required for such injuries.

If an early and accurate diagnosis of the fracture pattern is made and adequate treatment is undertaken, the prognosis of LTPF would be favorable[28, 29]. The lateral process of the talus possesses large articulations for both the distal fibula and the posterior facet of the calcaneus. Fixation of LTPF is essential to restore the native architecture of these joint surfaces[30]. An attempt on open reduction and internal fixation can potentially improve outcome and delay development of arthritis. For the small avulsion fracture or severe comminuted fracture which cannot be treated by open reduction and internal fixation, conservative treatment or resection should be reserved[31]. Patients with type Ia and Ic of the proposed classification usually fall into this category. In our study, three patients with type Ia received non-operative treatment and one patient with type Ic underwent surgical excision of the fragment. The rest of the patients (including all type II patients) were treated with ORIF. The LTPFs of type II frequently extend into the midportion of talar body and neck of talus, and are often comminuted. Excision of a large number of fragments may result in an uneven joint surface or joint instability and is not recommended. Vallier suggested the fragments can be temporarily stabilized with Kirschner wires and then fixed with mini-fragment screw and/or plate[32]. In patients with type II, it is usually most effective to reposition and stabilize the neck, body, and other fragments before incorporating the lateral process into the internal fixation. The new classification provides a more comprehensive and practical method for classifying the LTPF, which can improve preoperative planning and subsequently the surgical treatment outcome.

Some possible limitations to this study should be acknowledged. First, the sample size of our study was improved compared to previous studies, however, due to the low incidence of LTPF, the available sample size remained small and the overall sample size was less than 50 patients. Second, this study has the intrinsic weakness of retrospective studies. A prospective study including clinical data of relatively large

sample is necessitated to evaluate its clinical relevance. Third, in a clinical setting, it is critical to recognize LTPFs complicating soft tissue injuries, as they may require different treatment strategies. Due to the inadequate magnetic resonance imaging (MRI) in these patients, our study was too underpowered to determine the relationship between LTPFs and soft tissue injuries. This leaves room for further research.

Conclusions

CT scanning is an important adjunct in characterizing LTPFs to determine the most effective treatment. The new classification system is prognostic, reliable and reproducible and could be a useful instrument to well assist surgeons in selecting appropriate treatment strategies. Further studies on the evaluation of the classification are warranted.

Declarations

Consent for publication

Not applicable.

Availability of data and materials

The datasets used and/or analyzed during the current study are available from the corresponding author on reasonable request.

Conflict of interest

Yuchuan Wang, Xiangtian Deng, Yanbin Zhu, Zhongzheng Wang, Lei Fu, Wei Chen, and Yingze Zhang declare that they have no conflict of interest.

Ethics approval and consent to participate

This study was approved by the ethics committee of the 3rd Hospital of Hebei Medical University (K2015-001-12). All patients of our study gave their written consent for participation and publication of their anonymized data.

Funding

This study was supported by the Innovation Project for Postgraduates of Hebei Province Education Department (grant number: CXZZBS2021083).

Contributions

Yingze Zhang conceived the idea for the study; Yuchuan Wang and Xiangtian Deng designed the study. Zhongzheng Wang, Yanbin Zhu, Xiangtian Deng and Wei Chen collected the relevant data and classified

the fractures. Yuchuan Wang performed the statistical analyses and prepared the tables. Lei Fu did the drawings. All the authors interpreted the data and contributed to preparation of the manuscript.

Acknowledgements

Not applicable.

References

1. Majeed H, McBride D: **Talar process fractures: An overview and update of the literature**. *EFORT open reviews* 2018, **3**(3):85-92.
2. Vallier HA, Reichard SG, Boyd AJ, Moore TA: **A new look at the Hawkins classification for talar neck fractures: which features of injury and treatment are predictive of osteonecrosis?***Journal of Bone & Joint Surgery-american Volume* 2014, **96**(3):192-197.
3. Hood C, Miller J, Hollinger J: **Defining Talar Head and Neck Pathology: The Malvern Classification System**. *The Journal of foot and ankle surgery : official publication of the American College of Foot and Ankle Surgeons* 2018, **57**(1):131-139.
4. Bladin C, Giddings P, Robinson M: **Australian snowboard injury data base study. A four-year prospective study**. *The American journal of sports medicine* 1993, **21**(5):701-704.
5. Mills H, Horne G: **Fractures of the lateral process of the talus**. *The Australian and New Zealand journal of surgery* 1987, **57**(9):643-646.
6. Kirkpatrick, Douglas, P., Hunter, Robert, E., Janes, Peter, C., Mastrangelo: **The snowboarder's foot and ankle**. *Am J Sports Med* 1998, **26**(2):271-271.
7. Kirkpatrick D, Hunter R, Janes P, Mastrangelo J, Nicholas R: **The snowboarder's foot and ankle**. *The American journal of sports medicine* 1998, **26**(2):271-277.
8. Buza J, Leucht P: **Fractures of the talus: Current concepts and new developments**. *Foot and ankle surgery : official journal of the European Society of Foot and Ankle Surgeons* 2018, **24**(4):282-290.
9. Noble J, Royle S: **Fracture of the lateral process of the talus: computed tomographic scan diagnosis**. *Br J Sports Med* 1992, **26**(4):245-246.
10. Hillerer C, Waldt S, Woertler K: **["Snowboarders ankle": fractures of the lateral processus tali]**. *Rofo* 2006, **178**(1):1-4.
11. HAWKINS L: **FRACTURE OF THE LATERAL PROCESS OF THE TALUS**. *The Journal of bone and joint surgery American volume* 1965, **47**:1170-1175.
12. McCrory P, Bladin C: **Fractures of the lateral process of the talus: a clinical review. "Snowboarder's ankle"**. *Clinical journal of sport medicine : official journal of the Canadian Academy of Sport Medicine* 1996, **6**(2):124-128.
13. Tinner C, Sommer C: **Fractures of the Lateral Process of the Talus**. *Foot and ankle clinics* 2018, **23**(3):375-395.

14. Dale J, Ha A, Chew F: **Update on talar fracture patterns: a large level I trauma center study**. *AJR American journal of roentgenology* 2013, **201**(5):1087-1092.
15. Vallier H, Nork S, Barei D, Benirschke S, Sangeorzan B: **Talar neck fractures: results and outcomes**. *The Journal of bone and joint surgery American volume* 2004, **86**(8):1616-1624.
16. Klein S, Varner K, Marymont J: **Lateral talar process fracture and peroneal tendon dislocation: a previously unrecognized injury complex**. *Foot Ankle Int* 2008, **29**(10):1020-1024.
17. Hörterer H, Baumbach S, Lemperle S, Altenberger S, Gottschalk O, Mehlhorn A, Röser A, Walther M: **Clinical outcome and concomitant injuries in operatively treated fractures of the lateral process of the talus**. *BMC Musculoskelet Disord* 2019, **20**(1):219.
18. Fleiss JL: **Measuring aormal scale agreements among many raters**. 1971.
19. Cohen, J.: **A Coefficient of Agreement for Nominal Scales**. *Educ Psychol Meas* 1960, **20**(1):37-46.
20. Landis J, Koch G: **The measurement of observer agreement for categorical data**. *Biometrics* 1977, **33**(1):159-174.
21. Leonetti D, Tigani D: **Pilon fractures: A new classification system based on CT-scan**. *Injury* 2017, **48**(10):2311-2317.
22. Sneppen O, Christensen S, Krogsoe O, Lorentzen J: **Fracture of the body of the talus**. *Acta Orthop Scand* 1977, **48**(3):317-324.
23. Bonvin F, Montet X, Copercini M, Martinoli C, Bianchi S: **Imaging of fractures of the lateral process of the talus, a frequently missed diagnosis**. *Eur J Radiol* 2003, **47**(1):64-70.
24. Chan G, Yoshida D: **Fracture of the lateral process of the talus associated with snowboarding**. *Ann Emerg Med* 2003, **41**(6):854-858.
25. Romeo N, Benirschke S, Firoozabadi R: **Technique for Open Reduction and Internal Fixation of Lateral Process Talus Fractures**. *J Orthop Trauma* 2020:S9-S13.
26. Mui T, Sugimoto K, Sugioka S, Yamasaki T, Tanaka K, Isomoto S, Tanaka Y: **Accessory Anterolateral Talar Facet Syndrome After Treatment of Neglected Fracture of the Lateral Process of the Talus: A Case Report**. *The Journal of foot and ankle surgery : official publication of the American College of Foot and Ankle Surgeons* 2020, **59**(4):826-828.
27. Peml M, Kálal P, Kopačka P, Kloub M: **[Peripheral Factures of the Talus. Mid-Term Results]**. *Acta Chir Orthop Traumatol Cech* 2016, **83**(6):399-404.
28. Mayo, Keith A: **Fractures of the talus: Principles of management and techniques of treatment**. *Techniques in Orthopaedics* 1987, **2**(3):42-54.
29. Knoch FV, Reckord U, Knoch MV, Sommer C: **Fracture of the lateral process of the talus in snowboarders**. *Journal of Bone & Joint Surgery-british Volume* 2007, **89**(6):772-777.
30. Berkowitz, MJ, Kim, DH: **Process and tubercle fractures of the hindfoot**. *J Am Acad Orthop Surg* 2005.
31. Shank JR, Benirschke SK, Swords MP: **Treatment of Peripheral Talus Fractures**. *Foot & Ankle Clinics* 2017, **22**(1):181-192.

32. Vallier H: **Fractures of the Talus: State of the Art**. *J Orthop Trauma* 2015, **29**(9):385-392.

Tables

Table 1

Clinical details of 43 Fractures of the lateral process of the talus.

Male	37
Female	5
Average Age at the time of injury	34.9
(Range; SD)	(18-65 ±11.6)
Left	20
Right	21
Bilateral	1
Mechanism of Injury	
Fall from large height	30
Motor vehicle collision	6
Fall from low height	3
Sprain of ankle joint	2
Crush injury	1
Nonoperative	3
ORIF	38
Fracture excision	1
Hawkins classification	
I	15
II	22
III	6
McCrory-Bladin classification	
I	6

II	15
III	22
New classification	
Ia	2
Ib	1
Ic	2
IIa	1
IIb	6
IIc	18
IId	3
IIe	10

SD standard deviation, ORIF open reduction and internal fixation

Table 2.

Clinical results and complications for each classification systems.

Type	Cases	AOFAS score	Complications
Hawkins classification			
I	15	80.73	2 Arthritis
II	22	80.36	1 Nonunion
			3 Arthritis
III	6	84.67	1 Nonunion
McCrory-Bladin classification			
I	6	84.67	1 Nonunion
II	15	80.73	2 Arthritis
III	22	80.36	1 Nonunion
			3 Arthritis
New classification			
Ia	2	91.5	No
Ib	1	86	No
Ic	2	90.5	No
IIa	1	89	No
IIb	6	76.7	1 Nonunion
			2 Arthritis
IIc	18	76.6	1 Nonunion
			1 Arthritis
IId	3	91.3	
IIe	10	83.5	2 Arthritis

AOFAS: The American Orthopaedic Foot and Ankle Society

Table 3

Interobserver agreement

	Hawkins classification	McCrory-Bladin classification	New classification
Group1	0.721	0.763	0.874
Group2	0.792	0.788	0.875
Group3	0.697	0.692	0.788
average κ value	0.737	0.748	0.846

Table 4

Intraobserver agreement

	Hawkins classification	McCrory-Bladin classification	New classification
First round	0.757	0.781	0.814
Second round	0.621	0.647	0.832
average κ value	0.689	0.714	0.823

Figures

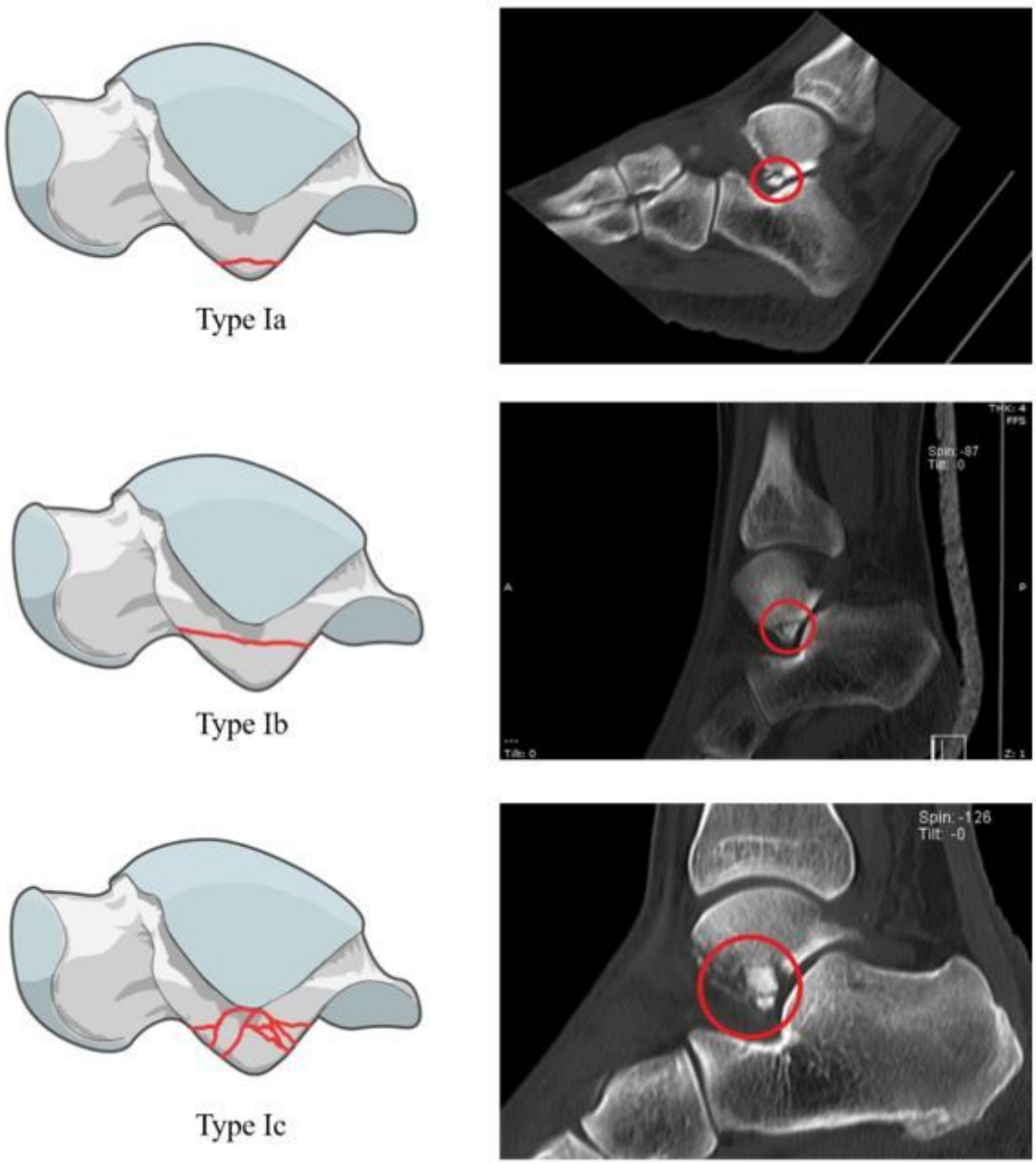

Figure 1

Isolated fracture: Ia: chip fracture without inclusion of the talofibular joint; Ib: simple fracture with involvement of the talofibular joint; Ic: multiple fragment fracture with joint involvement

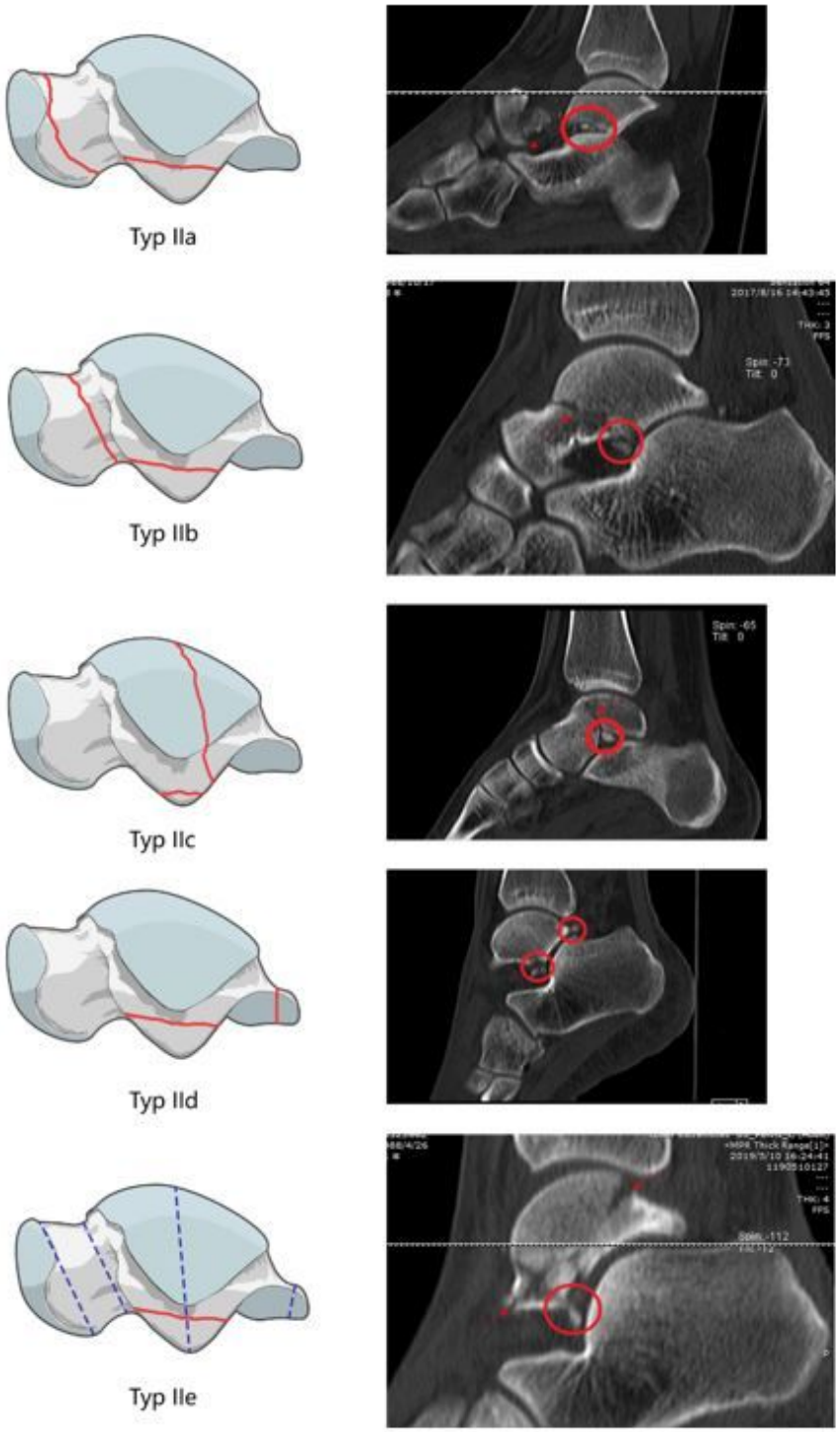

Figure 2

Lateral process fracture in combination with other fractures of the ipsilateral talus: IIa: lateral process fracture combined with talar head fracture; IIb: lateral process fracture combined with talar neck fracture; IIc: lateral process fracture with extension into the remainder of the talar body; IId: lateral process fracture combined with talar posterior process fracture; IIe: lateral process fracture combined with any two or more other fractures of the ipsilateral talus