Interpeduncular cistern intrathecal targeted drug delivery for Intractable Postherpetic Neuralgia: a case report

Feng Fu
Characteristic Medical Center of PAP
Xianfeng Jiang
Characteristic Medical Center of PAP
Lei Gong
Characteristic Medical Center of PAP
Chen Yun
Characteristic Medical Center of PAP
Fengwu Tang (doctang@126.com)
Characteristic Medical Center of PAP

Case Report

Keywords: Postherpetic neuralgia, Intrathecal drug delivery, Interpeduncular cistern, Craniofacial pain, Opioids

Posted Date: March 21st, 2022

DOI: https://doi.org/10.21203/rs.3.rs-1408412/v2

Abstract

Background

Intractable Postherpetic Neuralgia(PHN) can be difficult to manage though receiving aggressive multimodal therapies. Patients who experience uncontrolled refractory PHN on head despite conservative treatment may benefit greatly from intrathecal drug delivery system IDDS. For craniofacial neuropathic pain the traditional approach has been to place the intrathecal catheter tip usually below the level of cranial nerve root entry zones, which may lead to an insufficient analgesic effect.

Case presentation

Herein, we describe a 69-year-old male had a one-year history of PHN after developing a vesicular rash in the ophthalmic division of cranial nerve V (trigeminal nerve) distribution. The pain was rated 7-8 at rest and 9-10 of breakthrough pain(BTP) on an numeric rating scale(NRS). Despite receiving aggressive multimodal therapies including large doses of oral analgesics and Sphenopalatine Ganglion Block (SGB), with no relief of his pain, and subsequently the patient elected to pursue an implantable IDDS with the catheter tip placed at the interpeduncular cistern. The frequency of BTP episodes was also decreased. The patient's continuous daily dose was adjusted to 0.032 mg/day after 3 months of follow-up and stop 5 months later.

Conclusion

The use of interpeduncular cistern intrathecal infusion with low dose of opioids by IDDS may present an effective alternative in the management of severe PHN and other forms of neuropathic-associated craniofacial pain.

Introduction

Postherpetic neuralgia (PHN) is defined as persistent pain with dermatomal distribution in patients who have recovered from herpes zoster (HZ). Additionally, patients with PHN frequently experience physical and mental pain and sleep disorders, severely affect a patient's quality of life. Generally, approximately 20% of patients with HZ will experience PHN and more than 50% of PHN occurs in patients who are ≥ 60 years of age[1, 2]. Similarly, a cross-sectional study conducted in 24 hospitals in seven cities in China, found that 29.8% of HZ patients developed PHN and that 66.3% of those patients were > 60 years of age[3].

Currently, first-stage treatments for PHN is medication, followed by the interventional therapies such as subcutaneous injection, ganglion block, pulsed radiofrequency, nerve or spinal cord stimulation, as second- stage therapies. However, patients who experience uncontrolled refractory pain despite conservative treatment may benefit greatly from intrathecal drug delivery system (IDDS), which is referred to as third-stage therapy by the Polyanalgesic Consensus Conference (PACC) [4].

The traditional teaching of many Best Practices and Guidelines has reasonably recommended that the catheter tip optimal placement nearest the site of pain[4]. However, for craniofacial neuropathic pain, the traditional approach has been to place the intrathecal catheter tip usually below the level of cranial nerve root entry zones, which may lead to an insufficient analgesic effect[5].

Limited data exist as to appropriate and best catheter tip placement. To provide reference for clinical treatment, the present manuscript aims to briefly describe a case of intrathecal targeted drug delivery by placing the catheter tip near the interpeduncular cistern for the treatment of PHN patient with refractory pain.

Case Presentation

A 69-year-old male had a one-year history of PHN after developing a vesicular rash in the ophthalmic division of cranial nerve V (trigeminal nerve) distribution. The patient was originally treated with antiviral medication, and the rash subsequently resolved. The patient, however, develop PHN with sharp, burning, and electrical type of pain in the distribution of his prior rash. The pain was rated 7–8 at rest and 9–10 of breakthrough pain(BTP) on an numeric rating scale(NRS), which at first responded to gabapentin, oxycodone, and lidocaine patches, but then became refractory to these treatments. The patient also tried twice Sphenopalatine Ganglion Block (SGB), with no relief of his pain.

The patient with anxiety and insomnia were getting worse due to the severity of pain, and the patient agreed to proceed with the IDDS implantation procedure. After the success of general anesthesia, the patient was placed in a left lateral decubitus position. Intraoperative fluoroscopy was mandatory to confirm access to the C3-4 intrathecal space and the catheter tip(SP-10210, Soph-A-Port, Sophysa, France) was carefully placed within the interpeduncular cistern (Fig. 1, A and B). The intrathecal catheter was then tunneled to the upper chest subcutaneous pocket where the subcutaneous port was implanted (Fig. 1, C and D). An external drug delivery system was connected to the port using a nondestructive needle. No procedural complications were encountered while inserting the pump.

A continuous daily hydromorphone hydrochloride(Yichang Human

-well Pharmaceutical Co.,Ltd, China) dose was started at 0.064mg/day and gradually titrated up to 0.128mg/day for improved pain control. For more efficient control of BTP, a bolus was added with 0.0003 mg each time and a 1 hour lockout interval. The patient developed nausea and vomiting at the beginning of medication, which was gradually controlled after drug treatment. No sedation, confusion, nor respiratory depression occurred. He was discharged from the hospital with pain reduction had been well maintained at the NRS pain score of 3/10 at rest and 5/10 at worst during breakthrough pain. The frequency of BTP episodes was also decreased. The patient’s continuous daily dose was adjusted to 0.032 mg/day after 3 months of follow-up and stop 5 months later.

Discussion

With the increasing understanding of pain pathophysiology and intrathecal analgesia, implanted IDDS has been widely recognized worldwide for the treatment of various types of chronic intractable pain. IDDS can directly inject drugs into the cerebrospinal fluid, which has the advantages of higher selectivity, significantly lesser doses of drugs and fewer adverse effects (AEs) [6]. However, in order to take advantage of this, proper patient selection and careful application of the therapy needs to be exercised.

This patient had severe unrelenting PHN in the cranial nerve V (trigeminal nerve) distribution, which greatly impacted his quality of life. Despite receiving aggressive multimodal therapies including large doses of oral analgesics and SGB nerve blocks, with no relief of his pain, and subsequently the patient elected to pursue an implantable IDDS with the catheter tip placed at the interpeduncular cistern. After pump placement and initiation of intrathecal hydromorphone, his pain was significantly improved, demonstrating interpeduncular cistern intrathecal targeted drug delivery may be an effective method of treating a plethora of PHN in the trigeminal nerve area.

This case proves that it is particularly important to place the catheter tip in the corresponding position according to the patient's pain level in order to achieve better analgesic effect. Current concepts of Cerebrospinal Fluid (CSF) flow dynamics emphasize pulsatile flow with oscillatory bidirectional craniocaudad CSF movement[7, 8]. Pulsatile flow patterns of CSF have been shown to imposes significant limitations on intrathecal targeted medications delivery via an IDDS, which involves a continuous low-flow intrathecal infusion through a small catheter, such that drugs was limited to a few centimeters of the catheter tip (2–3 vertebrae)[9, 10].

The trigeminal nerve is a mixed nerve, which contains general somatosensory and special visceral movement of two kinds of fibers. Sensory fibers into the pons continue forward to the sensory nucleus, spinal trigeminal nucleus or midbrain nucleus[11–12]. According to clinical experience, the spinal trigeminal nucleus is second order neuron to transmits the pain signal centrally. In spite of this, the catheter tip is always placed far away from the trigeminal nerve root entry zone (where the target receptors are located) in the traditional way, thus possibly leading to insufficient analgesia. Its effect is attributed to the dense concentration of opioid receptors surrounding the brainstem and the CSF flow dynamics theory, the interpeduncular cistern intrathecal targeted drug delivery method for intractable PHN in the trigeminal nerve area could be more effective compared with the traditional approach.

Based on our previous experience, it is difficult to reach the high cervical region by entering the catheter from the relatively safe L2 level due to the lack of a suitable catheter, let alone the intracranial region. Cisterna magna puncture was considered because of its safety, but was abandoned result of difficulty in fixation.Therefore, we chose to puncture through C3-4 and place the catheter tip slowly upwards. The catheter must be advanced slowly into cervical subarachnoid space under continuous X-ray to avoid damage to the tissues. Angle adjustment is very important in the placement process. If the catheter encountered resistance, it was withdrawn and adjust the angle to attempted again. The catheter tip must be exceptionally slow and careful to pass through the C1 level, after which the catheter was easily advanced to this level in our case.

The difficulties of the case mentioned above highlights the need of advancing in intrathecal catheter design, access techniques, imaging, and greater understanding of pain pathway. Technical innovations include new catheters, its tip is soft and the body is strong for easier placement. Ultrasound-guided puncture appears to be a safety technique for the puncture of catheter, while providing better visualization and no radiation exposure.We anticipate that this will occur in several concurrent phases, which will usher in an era where the intracisternal space is recognized as a highly valued therapeutic target.

Conclusion

In conclusion, interpeduncular cistern intrathecal infusion with low dose of opioids by IDDS is an effective and safe way to alleviate severe PHN and other forms of neuropathic-associated craniofacial pain with few adverse effects.

Declarations

Acknowledgments

We are very grateful to Xiao Hong Li for editing the English text of a draft of this manuscript.

Authors' contributions

Design of the work-F F, XF J, FW T; data collection and analysis-F F, L G; interpretation of data-F F, C Y, FW T; drafting and revision of the manuscript-F F, XF J, C Y, FW T. All authors approved the final version of the manuscript.

Funding

This study was funded by the Key project of Chinese Academy of Sciences (No. ZDRW-ZS-2016-2-1).

Availability of data and method

The data used and/or method during the current case is available from the corresponding author upon reasonable request.

Ethics approval and consent to participate

We confirm that we have read the journal's position on issues involved in ethical publication and affirm that this report is consistent with these guidelines. As this is a case report describing clinical observations, ethics approval was waived.

Consent for publication

Written informed consent was obtained from the patient for publication of this case report and accompanying images.

Competing interests

All authors declare that they have no conflict of interests in this study.

References

1. Johnson RW, Rice ASC. Clinical practice postherpetic neuralgia. N Engl J Med 2014;371(16):1526–33.
2. Massengill JS, Kittredge JL. Practical considerations in the pharmacological treatment of postherpetic neuralgia for the primary care provider. J Pain Res 2014;7:125–32.
3. Yang F, Yu S, Fan B, Liu Y, Chen YX, Kudel I, Concialdi K, DiBonaventura M, Hopps M, Hlavacek P, Cappelleri JC, Sadosky A, Parsons B, Udall M. The Epidemiology of Herpes Zoster and Postherpetic Neuralgia in China: Results from a Cross-Sectional Study. Pain Ther 2019;8(2):249–259.
4. The Polyanalgesic Consensus Conference (PACC): Recommendations on Intrathecal Drug Infusion Systems Best Practices and Guidelines. Neuromodulation 2017 Jun;20(4):405–406.
5. Zou D, Zhang W, Wang Y. Prepontine Cistern Intrathecal Targeted Drug Delivery for Cancer-Related Craniofacial Pain. Pain Med 2021;22(12):3112–3114.
6. Hayek SM, Hanes MC. Intrathecal therapy for chronic pain: current trends and future needs. Curr Pain Headache Rep 2014;18(1):388.
7. Henry-Feugeas MC, Idy-Peretti I, Baledent O, Poncelet-Didon A, Zannoli G, Bittoun J, Schouman-Claeys E. Origin of subarachnoid cerebrospinal fluid pulsations:a phase-contrast MR analysis. Magn Reson Imaging 2000;18:387–95.
8. Friese S, Hamhaber U, Erb M, Kueker W, Klose U. The influence of pulse and respiration on spinal cerebrospinal fluid pulsation. Invest Radiol 2004;39:120–30.
9. Bernards CM. Cerebrospinal fluid and spinal cord distribution of baclofen and bupivacaine during slow intrathecal infusion in pigs. Anesthesiology 2006;105:169–78.
10. Flack SH, Anderson CM, Bernards C. Morphine distribution in the spinal cord after chronic infusion in pigs[J]. Anesth Analg 2011;112(2):460–4.
11. Okada S, Katagiri A, Saito H, Lee J, Ohara K, Iinuma T, Bereiter DA, Iwata K. Differential activation of ascending noxious pathways associated with trigeminal nerve injury. Pain 2019;160(6):1342–1360.
12. Reske-Nielsen E, Oster S, Pedersen B. Herpes zoster ophthalmicus and the mesencephalic nucleus: A neuropathological Study[J]. Acta Pathol Microbiol Immunol Scand A 1986;94(4):263–269.

Figures

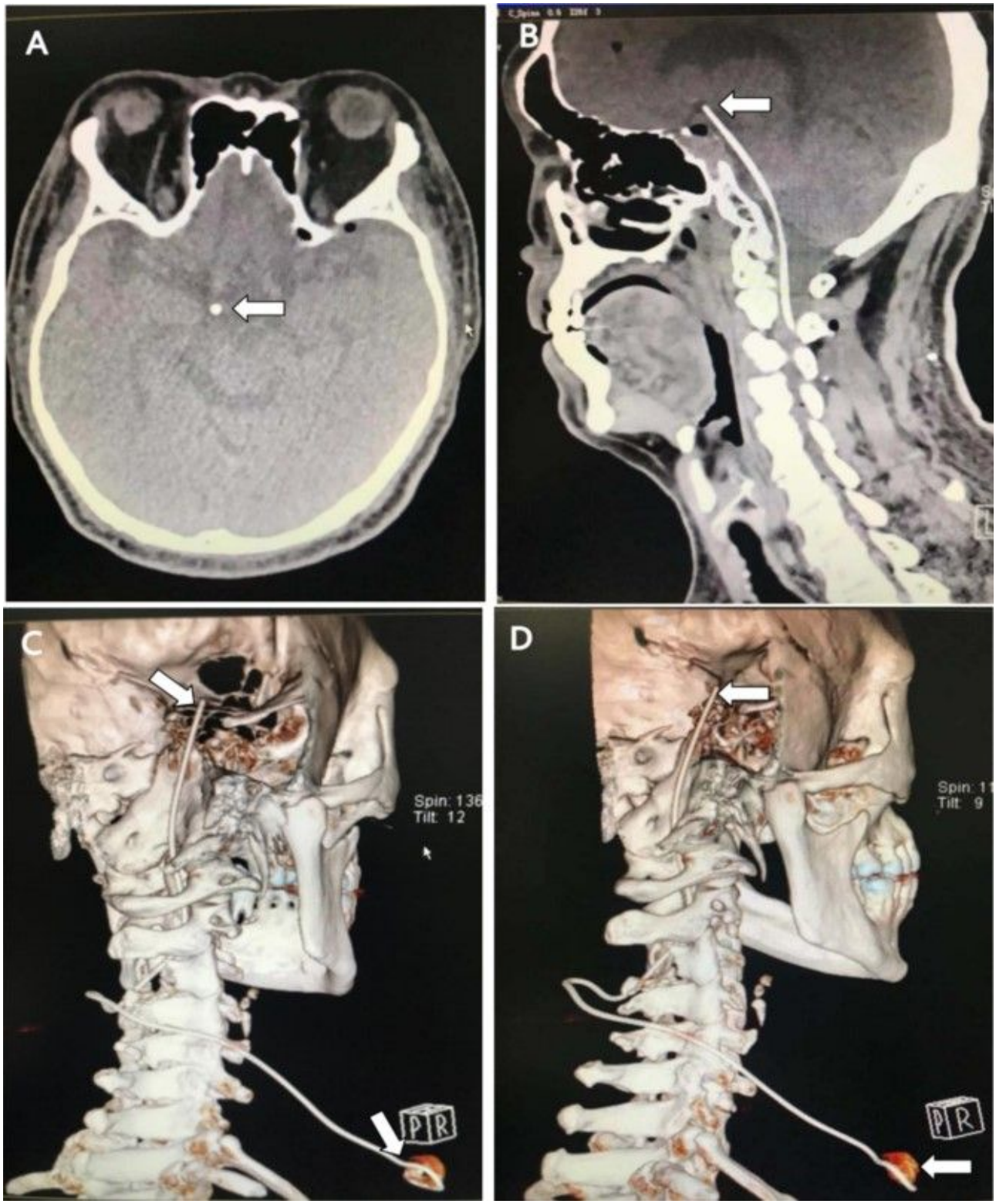

Figure 1

Head CT and 3D reconstruction taken after the procedure. The arrowhead indicates the catheter tip, and the arrow indicates the pump. Horizontal bitmap (A), Sagittal bitmap (B) and 3D reconstruction (C,D).