Prevalence and correlation of C-shaped root canals of mandibular premolars and molars in Eastern Chinese individuals

Cheng Chen
The Affiliated Stomatological Hospital of Nanjing Medical University
Lianfeng Yang
The Affiliated Stomatological Hospital of Nanjing Medical University
Tingting Zhu
The Affiliated Stomatological Hospital of Nanjing Medical University
Huili Wu
The Affiliated Stomatological Hospital of Nanjing Medical University
Xiao Zhao
The Affiliated Stomatological Hospital of Nanjing Medical University
Daming Wu (wdming@njmu.edu.cn)
The Affiliated Stomatological Hospital of Nanjing Medical University

---

Research Article

Keywords: Cone-beam computed tomography, C shaped root canals, Radicular grooves, Anatomy

Posted Date: March 23rd, 2022

DOI: https://doi.org/10.21203/rs.3.rs-1410751/v1

Abstract

Background

To investigate the prevalence, correlation, and differences of C-shaped root canals (CSRCs) morphology in permanent mandibular premolars and molars in Eastern Chinese individuals using cone-beam computed tomography (CBCT).

Methods

A total of 8000 mandibular premolars and molars CBCT images from 1000 patients (692 females and 308 males) were collected. The prevalence, correlation, bilateral/unilateral presence, morphology of CSRCs, level of canal bifurcation, sex differences, and location of radicular grooves (RGs) were evaluated. The correlation between the prevalence of CSRCs and RGs in different tooth positions and age groups was analyzed.

Results

The prevalence of CSRCs in mandibular first premolars (MFPs), mandibular second premolars (MSPs), mandibular first molars (MFMs) and mandibular second molars (MSMs) were 10.25%, 0.25%, 0.55% and 47.05%, respectively. There was no correlation between the presence of CSRCs in mandibular premolars and molars. The prevalence of CSRCs in MFPs of males was higher than that in females, while CSRCs in MSMs of females were higher than that in males ($P < 0.05$). The bilateral symmetry presence of CSRCs in MSMs was significant but not in MFPs. RGs were predominantly found on the mesiolingual surface of premolars and the lingual surface of molars. There was no significant difference in the prevalence of CSRCs in different types of RGs in premolars. The incidence of CSRCs was significantly lower in the non-bifurcation group.

Conclusions

There was a high prevalence of CSRCs in MFPs and MSMs in the Eastern Chinese population, but there was no correlation. The symmetry of CSRCs was significant in MSMs but not in MFPs. The prevalence of CSRCs in MFPs of males was higher than that in females, while the prevalence of CSRCs in MSMs of females was higher than that in males. In the process of RCT of teeth with CSRCs, CBCT should be taken if necessary, and the treatment should be carried out with the aid of a microscope. Clinicians should pay special attention to CSRCs.

Introduction

Successful root canal treatment (RCT) requires adequate debridement, shaping, and complement obturation of all root canals in three dimensions(3D), so a thorough knowledge of the anatomy and morphology of the root canals is necessary [1]. There are numerous types of research on root canal morphology, which mainly focus on: (1) root canal morphology in different teeth from different regions and populations, (2) differences in root canal morphology of race, sex, and age, (3) symmetry of root canal morphology on the left and right sides, and (4) case reports of unique root canal morphology [2–7]. There are currently recognized variances in root canal morphology based on race, sex, and age.

In 1979, Cooke and Cox [8] reported CSRCs in mandibular molars and discussed their clinical implications firstly. Then CSRCs were also identified in mandibular premolars [1] and maxillary molars [9]. The inability of Hertwig's epithelial root sheath to fuse on the lingual or buccal root surface and the cementum deposition over time may be the leading causes of CSRCs [10]. A fin or web connecting the individual root canals is the primary anatomical feature of CSRCs [11]. Therefore, thorough debridement of these anatomical structures is a big challenge [12]. In1991, Milton and his coworkers were the first to put forward principles of the CSRCs in molars[10], and a modified classification based on Milton’s principle was proposed by Fan et al. in 2004, which classified CSRCs into five categories, described the differences between them, and made up for the shortcomings of the initial categorization [11].

The CSRCs in MSMs have been extensively studied in the past. The prevalence of CSRCs in MSMs is much higher in the Asian population than in other races [13]. The canal shapes in most teeth with CSRCs could vary along the root length [11]. The 3D morphology of the CSRCs system is divided into three types: (a) Merging type, (b) symmetrical type, (c) asymmetrical type [14]. There is currently a scarcity of large-sample research on the prevalence of the CSRCs in mandibular premolars [1, 15]. RGs can occur on the mesial and distal root surfaces of MFPs. The RGs on the root surface increase the difficulty of oral hygiene and the management of periodontal disease, and there will be an increase in the difficulty of RCT [16]. The prevalence of CSRCs in MFPs and MSMs was high in the Chinese population [13, 16], while there has been no published research on the relationship between each other. There was just one investigation investigating the relationship between the incidence of complicated root canals in the posterior mandibular teeth in China. The study [17] revealed that the prevalence of CSRCs in MFPs will increase when the distolingual root is found in permanent MFMs in the Taiwanese population.

Many approaches were employed to examine human teeth' internal and exterior structure, such as radiography techniques, cleaning techniques, modeling techniques, and Micro-CT in vitro [16, 18]. These approaches used extracted teeth as samples for in vitro research, but it is not easy to collect many extracted teeth to match the experiment's requirements. In addition, extracted teeth often lack information about left and right tooth positions and sex [1, 19]. Cone-beam computed tomography (CBCT) provides a non-invasive 3D confirmatory diagnosis to complement conventional radiography [20]. For endodontists, CBCT is critical in the event of a treatment-related mishap, such as medullary floor perforation, root canal perforation, or instrument separation. Over the last three decades, the use of CBCT in endodontics has gradually increased and confirmed the values of CBCT on diagnosis, treatment planning, and decision making [21].

The purpose of this study is to investigate the prevalence, correlation, and differences of CSRCs morphology in permanent mandibular premolars and molars in Eastern Chinese individuals utilizing CBCT.

Methods And Materials

Image Acquisition

The Ethical Committee Department of the Affiliated Stomatological Hospital of Nanjing Medical University approval was obtained (PJ2021-116-001). All images were obtained from a CBCT database from the Department of Oral & Maxillofacial Imaging, the Affiliated Stomatological Hospital of Nanjing Medical University. Images were gathered from the patients who required CBCT imaging as part of their dental evaluation for orthodontics, implants, trauma, temporomandibular joint diseases, and other reasons between January and October 2021.

The CBCT images were obtained using a CBCT scanner (NewTom 5G, QR s.r.l., Italy) at 110 kV and 4-14 mA with an exposure time of 3-5 secondsand field of view (FOV) of 16 × 18 cm or 15 × 12 cm.The voxel size of the images and axial thickness was 0.30mm. According to the manufacturer's recommended protocol, an experienced radiologist performed the acquisition process.

CBCT images with MFPs, MSPs, MFMs, and MSMs with completely grown roots were collected. The presence of unclear images, posts or crowns, periapical lesions, and endodontic treatments were excluded. A total of 8000 mandibular premolars and molars CBCT images from 1000 patients (692 females and 308 males) were collected [Table 1].

Image Evaluation

Two endodontists independently evaluated the images twice using NNT 10.0.0 software (QR s.r.l., Verona, Italy). A radiologist with endodontic experience was invited to perform a third evaluation and reach a final consensus when existing disagreements. Their measurements were calibrated before the experiment by reading 20 CBCT images of CSRCs in premolars and molars chosen to ensure the accuracy of the results. Cohen's kappa statistical analysis was used to assess the intra- examiner and inter-examiner reliability. Intra-examiner and inter-examiner agreements had kappa values of 0.87 to 0.902, respectively.

The cross-sectional configurations were analyzed to determine the frequency of CSRCs at different axial levels in premolars and molars: “A,” the coronal-third point (1/3 the distance between the orifice and the anatomical apex), “B,” the middle of the roots (mid-point from orifice to apex distance-wise); “C,” the apical-third point (junction between the middle and apical thirds of the root distance-wise); “D,” 2 mm from the anatomical apex. The mandibular molars were defined as CSRCs when exhibiting all the characteristics: fused roots, a longitudinal groove on the root’s lingual or buccal surface, and at least one cross-section of the canal belonging to the C1, C2, or C3 configuration according to Fan’s classification [11]. All mandibular premolars were defined as CSRCs when exhibiting all the characteristics: fused roots,

a radicular groove on the root's surface, and at least one cross-section of the canal belonging to the C1 or C2 configuration [16,22].

Age, sex, tooth position (left or right side), the morphology of CSRCs, and location of RGs were recorded.

Statistical analysis

The Chi-square test and Fisher's exact test were used to analyze the correlation between the prevalence of CSRCs and RGs in different tooth positions and age groups by SPSS 25.0 software (SPSS Inc, Chicago, IL). Differences were statistically significant when P was <0.05.

Results

Mandibular first premolars

The prevalence of CSRCs in the MFPs was 10.25% (205/2000), of which were 16.23% (100/616) in males and 7.59% (105/1384) in females. The prevalence of RGs in the MFPs was 21.10% (422/2000), of which were 26.95% (166/616) in males and 18.50% (256/1384) in females [Table 2]. The prevalence of CSRCs and RGs in males was higher than in females (P<0.05). There was no statistical difference in the prevalence of CSRCs and RGs in different tooth positions.

RGs were mainly located on the mesiolingual surface of the root [Table 3], and there was no significant difference in the incidence of CSRCs in different types of RGs (P>0.05). Root canal bifurcations were primarily located in the middle third [Table 4], and the incidence of CSRCs was significantly lower in the non-bifurcation group than that in the other group(P<0.05). The canal shape in CSRCs could vary along the length of the root [Table 5]. C4(77.07%,158/205) prevailed on the axial of A. C3 (52.20%,107/205) dominated the axial of B. C2(54.63%,112/205) played the most crucial role on the axis of C, followed by C3 (25.37%,52/205). C3 (60.00%,123/205) dominated the axial of D.

According to Vertucci classification, Type V (72.68%, 149/205) was the primary morphology of MFPs presenting CSRCs, followed by type III (15.61%, 32/205), type I (10.24%,21/205), and type VII (0.49%, 1/205). Regarding the symmetry presence of CSRCs, 850 patients (85%) did not present this condition in any of the teeth, 95 patients (9.5%) showed CSRCs on only one side, and 55 patients (5.5%) presented CSRCs on both sides [Fig.1(a)]. Of the patients presenting CSRCs, 36.67% (55/150) had a bilateral condition, and 63.33% (95/150) had a unilateral condition. The bilateral symmetry presence of CSRCs was not significant in MFPs. As to RGs in MFPs, 740 patients (74%) did not present this condition in any of the teeth, 98 patients (9.8%) presented RGs on only one side, and 162 patients (16.2%) presented RGs on both sides. Of patients presenting RGs, 62.31% (162/260) had a bilateral condition, and 37.69% (98/260) had a unilateral condition. The bilateral symmetry presence of RGs was significant in MFPs. The prevalence of CSRCs in the contralateral tooth increased when presented on one side. The chi-square test revealed inter-group disparities in the prevalence of CSRCs across age groups [Table 6].

Mandibular second premolars

The prevalence of CSRCs in the MSPs was 0.25% (5/2000), of which were 0.49% (3/616) in males and 0.14% (2/1384) in females. The prevalence of RGs in the MSPs was 0.40% (8/2000), of which were 0.65% (4/616) in males and 0.29% (4/1384) in females [Table 2]. There was no statistical difference between males and females in the prevalence of CSRCs and RGs in MSPs (P>0.05). There was no statistical difference in the prevalence of CSRCs and RGs in different positions (P>0.05).

RGs were mainly located on the lingual surface of the root [Table 3], and there was no significant difference in the incidence of CSRCs in different types of RGs (P>0.05). Root canal bifurcations were primarily located in the middle third [Table 4], and there was no difference in the incidence of CSRCs in different canal bifurcations. Detailed morphology of different axials in CSRCs was presented in [Table 5]. According to Vertucci's criteria, type I (40%,2/5) and type III (40%,2/5) were the primary morphologies in MSPs presenting CSRCs, followed by type V (20%,1/5).Regarding the symmetry presence of CSRCs and RGs in MSPs, no one presented this condition in any teeth. Fisher's exact test revealed no difference in the prevalence of CSRCs across age groups [Table 6].

Several examples of root canal system configurations anddifferent CSRCs and RGsin mandibular premolars were shown in [Fig. 2] and [Fig. 3].

Mandibular first molars

The prevalence of CSRCs in the MFMs was 0.55% (11/2000), of which were 0.32% (2/616) in males and 0.65% (9/1384) in females [Table 2]. There was no difference in the prevalence of CSRCs in sex and dental position (P>0.05).

RGs were mainly located on the root's lingual surface (54.55%,6/11), followed by buccolingual (45.45%,5/11). A detailed analysis of different axials in CSRCs was presented in [Table 5]. Regarding the symmetry presence, CSRCs in MFMs occurred bilaterally in 0.20% (2/1000) of patients [Fig. 1(b)], unilaterally in 0.70% (7/1000), or on neither side in 99.10% (991/1000). The bilateral symmetry presence of CSRCs was not significant in MFMs (P>0.05). Fisher's exact test revealed no difference in prevalence across age groups (P>0.05) [Table 6].

Mandibular second molars

Of 2000 MSMs evaluated, 941(47.05%) were classified as CSRCs, with 732 in females (52.89%,732/1384) and 209 in males (33.92%, 209/616) [Table 2]. The Chi-square test showed a higher chance of CSRCs occurring in females than males (P<0.05). There was no difference in the incidence of CSRCs in dental positions (P>0.05).

Most of the grooves were located on the lingual surface (64.72%,609/941) of the root, followed by the buccolingual (35.07%,330/941) and the buccal (0.21%,2/941). The canal shape in C-shaped root canals could vary along the root length [Table 5]. C1 (55.04 %,518/941) and C2 (35.92 %,338/941) prevailed on the axial of A.C2 (53.24 %,501/941) dominated the axial of B. C2 (42.72 %,402/941) and C1 (28.06

%,264/941) played the most critical roles on the axis of C, followed by C3 (18.92%,178/941).C4 (50.90%,479/941) dominated the axial of D.

Regarding symmetry, CSRCs in MSMs occurred bilaterally in 38.9% (389/1000) of patients, unilaterally in 16.3% (163/1000), or on neither side in 44.80% (448/1000). In patients presenting CSRCs, 70.47% (389/552) had a bilateral condition [Fig. 1(a)], and 29.52% (163/552) had a unilateral condition. The bilateral symmetry presence of CSRCs in MSMs was significant.The Chi-square test revealed no inter-group disparities in the prevalence of CSRCs across age groups (P>0.05) [Table 6].

Different CSRCs and RGs in mandibular molars were presented in [Fig 4].

Discussion

Mandibular first premolars

The prevalence of CSRCs in MFPs ranged from 1% [23] to 28.94% [24]. Of the observed prevalence of CSRCs in MFPs worldwide,1% in India [23], 1.5% in Saudi [19], 2.3% in Portugal [1], 3.72% [25], 23.70% [26] in Thailand , 4.58% in Turkish [27], 10% in Argentina [28], 28% in Emirati [29], 28.94% in Venezuela [24], 10.9% in Chilean and Belgian [30]. Of the observed prevalence of CSRCs in MFPs in Chinese individuals, 12.5% [17], 18% [31] in Taiwan, 1.1% [32] in Western China, 1.14% [7] in Shandong, and 19.6% [33] in Jiangsu. Interestingly, studies from the same country had significant differences in the prevalence of CSRCs, and the main reason was that the country is a multi-ethnic country. In this study, the prevalence of CSRCs in MFPs was 10.25%, and the prevalence of RGs was 21.10%. The incidence of CSRCs in teeth with RGs was 48.57%, lower than the results in some research [17,18,22,33] but higher than in other studies [1,27]. The reasons for this difference may be different methods adopted, sample size, the definition of CSRCs, and ethnic differences.

This study found a significantly higher prevalence of MFPs with CSRCs in males. This finding was consistent with other studies [1,25], suggesting that sex difference exists in the prevalence of CSRCs in the MFPs. We did not find an effect of left or right sides on the prevalence of CSRCs in MFPs, which was consistent with the conclusions of other studies [1,7,17,19,25,28], indicating that there was no statistical difference in the prevalence of CSRCs in different positions.

RGs were mainly located on the mesiolingual surface of the root. This finding was consistent with earlier studies [1,17-19,22,26-28,31,33] but different from another study from Thailand [25], which reported that RGs were mainly located on the lingual side of the root in Thai population. Root canal bifurcations were mainly located in the middle of the root, consistent with other studies [18,24-26,33]. Interestingly, we found no significant difference in the incidence of CSRCs in different types of RGs, and the incidence of CSRCs was significantly lower in the non-bifurcation group. There have been no relevant studies reported so far. Type V was the main configuration in MFPs, which was consistent with other studies [1,16,17,21,25,26,33].

The canal shape in most teeth with RGs could be seen to vary along the root length. The most common root canal configuration was C3. This result was consistent with Wu et al. [17] and Fan et al. [16] but contradicted Martins et al. [1]. The main reason for this difference was the diverse axials selected, apart from race and sample size disparities. C1 was mainly found in the middle of the root, and this result was consistent with Fan et al. [16] and Martins et al. [1]. C4 was mainly located in the coronal third, and C5 was found primarily in the apical third, like the findings in other studies [1,16].

In this study, the bilateral symmetry presence of CSRCs was not significant in MFPs. This result was consistent with some studies [1,28] but contradicted other studies [17,26]. The main reason for the difference was ethnic variation.

Mandibular second premolars

The prevalence of CSRCs in MSPs ranged from 0% [34] to 7.14% [24] globally. Of the observed prevalence of CSRCs in MSPs worldwide, 0% in South Korea [34], 0.48% in Thailand [25], 2% in Argentina [28], 7.14% in Venezuela [24], 2.24% in Taiwan [35], and 0.80% in Saudi Arabia [19]. In our study, the prevalence of CSRCs in the MSPs was 0.25% (5/2000). The incidence of CSRCs in teeth with RGs is 62.50%, higher than the results in other studies [1,27]. The main reasons for these differences may be the sample size, the definition of CSRCs, and ethnic diversity. No significant differences were found between sex, age, left and right side concerning the presence of CSRCs in MSPs, consistent with other studies [1,24-28,30,32,35].

Type III (40%,2/5) and type I (40%,2/5) were the primary morphologies of MSPs presenting CSRCs, which contradicted other studies [25-27]. Most of the RGs (87.20%) were located on the mesiolingual surface of the root. This finding was consistent with some studies [1,24,28] but contradicted other studies [28,35]. We did not find patients with bilateral CSRCs or RGs. This result was similar to a study from Argentina [28]. The distribution of bifurcations was consistent with other studies [25,26]. C1 and C2 were most common in the middle of the root, consistent with the study of Chen et al. [35] and Büyükbayram et al. [27]. The main reasons for these differences may be the low prevalence of CSRCs in MSPs, different methods adopted, sample size, the definition of CSRCs, and ethnic differences.

Mandibular first molars

The prevalence of CSRCs in MFMs ranged from 0% [19,20,36-41] to 24.01 % [42] globally. In our study, CSRCs of MFMs were relatively rare, with an incidence of 0.55%.The incidence of CSRCs in the MFMs reported in other studies was also low, such as 0.16% in Israel [20], 1.7% [47]24.01% [42]2.39% in Brazil [43], 0% in Sudan [36], 0% in Jordan [37], 0.49% [44], 0.85% [45] in Turkish, 0 % in Burmese [38], 5.08% in Thai [46] , 0% in Chinese [39], 0% in Malaysian [40], 0% in Sri Lankan [41], and 0% [19], 0.19% [48] in Saudi Arabia. In this study, the prevalence of CSRCs in MFMs showed no difference in sex or tooth position. This finding was consistent with some studies [20,44,45] but contradicted other studies [42,43].

Nine patients (0.9% of the study sample) had CSRCs in their MFMs, and 2 (22.22%) of them had bilateral CSRCs. Patients with unilateral presence of the CSRCs were more common than those with bilateral presence. This result contradicted a study from Brazil [42]. In the other two studies [20,48], only one patient presented CSRCs, leading to an underestimation of whether symmetry occurred.

54.55% (6/11) of the grooves were located on the lingual surface of the root. There was currently no large sample of RGs in the MFMs reported. In this study, C3 was the most prevalent configuration in CSRCs, contradicting a Brazil study [42]. C1 and C2 were mainly located at the coronal third. C2 and C3 prevailed in the middle third, and C3 was the leading configuration in the apical third. There were no more detailed reports on the CSRCs of MFMs. We attributed these differences regarding incidence, symmetry, sex, and tooth position among these studies to ethnic variations.

Mandibular second molars

The prevalence of CSRCs in MSMs ranged from 1.9% [44] to 48.70% [40] globally. Chinese population presented the highest prevalence of CSRCs in MSMs compared with other regions [13]. In this study, the prevalence of CSRCs in MSMs was 47.95%, CSRCs in MSMs were more common in women, consistent with other recent studies worldwide [13,42,43,48,49]. Tooth position did not affect the prevalence of CSRCs in MSMs, and this finding was consistent with other studies [20,45,49-51].

Most of the RGs (64.93%) were located on the lingual surface of the root. This finding was consistent with some studies [19,48,50]**.**Patients with bilateral presence of the CSRCs in MSMs were more common than those with unilateral presence. This result was consistent with some studies [19,49-51] but contradicted others [20,42,48]. The main reasons for these differences were ethnic differences and sample size.

In this research, C1 was the primary canal morphology at the coronal third, consistent with the studies in Korea [51] and Brazil [42]. C1, C2, and C3 prevailed in the middle third. C2 and C4 were the main configurations in the apical third. This finding was also consistent with the study in Brazilian [43] but contradicted the study in Korea [51]. Ethnic differences may be a prominent cause.

Age

The Chi-square test revealed inter-group disparities in the prevalence of CSRCs in MFPs across age groups. So far, few reports about the prevalence of CSRCs in MFPs showed significant differences between age groups. Only one study reported that the higher prevalence of CSRCs in molars was found among the 45-54 years group with 11.1%, while the lowest rate was found in the 65-74 years group with a prevalence of 5.3% [52]. There are two reasons to explain the disparities. Firstly, there was a significant difference in the proportion of gender among age groups. Secondly, the prevalence of CSRCs in males of first premolars is significantly higher than that in females.

According to previous assumptions, cementum deposition may lead to C-shaped roots [10]. Compare the CBCT images of the same patient in young and old age stages to confirm the validity of this hypothesis,

which will be an exciting direction for future research.

Correlations between the prevalence of CSRCs in mandibular premolars and molars

In this study, the correlations between the prevalence of the CSRCs in mandibular premolars and molars were investigated. The results showed that the prevalence of CSRCs in MFPs was significantly higher than that of MSPs, and the prevalence of CSRCs in MSMs was considerably higher than that of MFMs. There was no relationship between CSRCs in MFPs and MSMs, consistent with MH Mashyakhy's research [19].

Advantages and limitation

In this study, we eliminated patients who had any missing mandibular posterior teeth to understand the relationship existing with each other. With large numbers of specimens identified, it is convenient to understand the relationship of this anatomic condition with other factors such as sex, location (left or right side), tooth group, and bilaterality and to perform any statistical analysis [1]. CBCT must be justified, like any other radiographic examination, and the potential benefits must balance the risk of ionizing radiation exposure [53]. Each examination should be tailored to the specific patient and their diagnostic requirements [54].The principle of ALARA (as low as reasonably achievable) must be followed.

One limitation of our work was that it was a retrospective study. We cannot control for characteristics such as FOV and voxel size. A voxel size of 0.250mm or 0.200mm was effective in recognizing C-shaped morphologies in earlier research [1,9,13,19,30,40,42,43,54], and 0.3mm voxel has only been used in one study [44]. Most CBCT images investigated in this study came from CBCT images taken for temporomandibular joint diseases diagnosis and standard pre-orthodontic examinations. The 0.3mm voxel can meet the needs of orthodontic and temporomandibular joint surgeons.

Conclusions

There was a high prevalence of CSRCs in MFPs and MSMs in the Eastern Chinese population, but there was no correlation. The symmetry of CSRCs was significant in MSMs but not in MFPs. The prevalence of CSRCs in MFPs of males was higher than that in females, while the incidence of CSRCs in MSMs of females was higher than that in males. In the process of RCT of teeth with CSRCs, CBCT should be taken if necessary, and the treatment should be carried out with the aid of a microscope. Clinicians should pay special attention to CSRCs.

Abbreviations

CSRCs
C-shaped root canals
RGs
radicular grooves

CBCT
Cone Beam Computed Tomography
MFPs
mandibular first premolars
MSPs
mandibular second premolars
MFMs
mandibular first molars
MSMs
mandibular second molars
3D
Three Dimension
SPSS
Statistical Package for the Social Sciences
RCT
Root canal treatment
FOV
Field of View

Declarations

Ethics approval and consent to participate

This study was performed in line with the principles of the Declaration of Helsinki. Approval was granted by the Ethical Committee Department of the Affiliated Stomatological Hospital of Nanjing Medical University (PJ2021-116-001). Through this approval, the research team had the required administrative permissions to access the data used in this research. For this type of retrospective study, and as recommended by the Research and Ethics Committee, formal consent is not required. The data used in this study were anonymized before its use.

Consent for publication

Not applicable

Availability of data and materials

The datasets used and analyzed during the current study are available from the corresponding author on reasonable request. All data analysed during the current study are included in its supplementary information files.

Competing interests

The authors declare that they have no competing interests.

Funding

The work was supported by the scientific research project of health care for cadres of Jiangsu Province (BJ21034).

Authors' contributions

CC, Conceptualization, Data curation, Formal analysis, Writing - original draft. LfY, Methodology, Data curation review & editing. TtZ,
Investigation, Validation, Visualization. HlW, Investigation, Validation, Visualization.
XZ, Investigation, Validation, Visualization. DmW, Supervision, review & editing, Project administration.

Acknowledgments

The authors are grateful to the study participants.

References

1. Martins, J.N.R., H. Francisco, and R. Ordinola-Zapata. Prevalence of C-shaped Configurations in the Mandibular First and Second Premolars: A Cone-beam Computed Tomographic In Vivo Study. J Endod. 2017; 43(6):890–895.
2. Martins, J.N.R., D. Marques, A. Mata, and J. Carames. Root and root canal morphology of the permanent dentition in a Caucasian population: a cone-beam computed tomography study. Int Endod J. 2017; 50(11):1013–1026.
3. Martins, J.N.R., R. Ordinola-Zapata, D. Marques, H. Francisco, and J. Carames. Differences in root canal system configuration in human permanent teeth within different age groups. Int Endod J. 2018; 51(8):931–941.
4. Pawar, A.M., M. Pawar, A. Kfir, S. Singh, P. Salve, B. Thakur, and P. Neelakantan. Root canal morphology and variations in mandibular second molar teeth of an Indian population: an in vivo cone-beam computed tomography analysis. Clin Oral Investig. 2017; 21(9):2801–2809.
5. Tan, X., L. Zhang, W. Zhou, Y. Li, J. Ning, X. Chen, D. Song, X. Zhou, and D. Huang. Palatal Radicular Groove Morphology of the Maxillary Incisors: A Case Series Report. J Endod. 2017; 43(5):827–833.
6. Yang, H., C. Tian, G. Li, L. Yang, X. Han, and Y. Wang. A cone-beam computed tomography study of the root canal morphology of mandibular first premolars and the location of root canal orifices and apical foramina in a Chinese subpopulation. J Endod. 2013; 39(4):435–8.
7. Sert, S., V. Aslanalp, and J. Tanalp. Investigation of the root canal configurations of mandibular permanent teeth in the Turkish population. Int Endod J. 2004; 37(7):494–9.
8. Cooke, H.G., 3rd and F.L. Cox. C-shaped canal configurations in mandibular molars. J Am Dent Assoc. 1979; 99(5):836–9.

9. Martins, J.N., A. Mata, D. Marques, C. Anderson, and J. Carames. Prevalence and Characteristics of the Maxillary C-shaped Molar. J Endod. 2016; 42(3):383–9.
10. Manning, S.A. Root canal anatomy of mandibular second molars. Part II. C-shaped canals. Int Endod J. 1990; 23(1):40–5.
11. Fan, B., G.S. Cheung, M. Fan, J.L. Gutmann, and Z. Bian. C-shaped canal system in mandibular second molars: Part I–Anatomical features. J Endod. 2004; 30(12):899–903.
12. von Zuben, M., J.N.R. Martins, L. Berti, I. Cassim, D. Flynn, J.A. Gonzalez, Y. Gu, J. Kottoor, A. Monroe, R. Rosas Aguilar, M.S. Marques, and A. Ginjeira. Worldwide Prevalence of Mandibular Second Molar C-Shaped Morphologies Evaluated by Cone-Beam Computed Tomography. J Endod. 2017; 43(9):1442–1447.
13. Gao, Y., B. Fan, G.S. Cheung, J.L. Gutmann, and M. Fan. C-shaped canal system in mandibular second molars part IV: 3-D morphological analysis and transverse measurement. J Endod. 2006; 32(11):1062–5.
14. Martins, J.N.R., D. Marques, E. Silva, J. Carames, A. Mata, and M.A. Versiani. Prevalence of C-shaped canal morphology using cone beam computed tomography - a systematic review with meta-analysis. Int Endod J. 2019; 52(11):1556–1572.
15. Fan, B., J. Yang, J.L. Gutmann, and M. Fan. Root canal systems in mandibular first premolars with C-shaped root configurations. Part I: Microcomputed tomography mapping of the radicular groove and associated root canal cross-sections. J Endod. 2008; 34(11):1337–1341.
16. Wu, Y.C., Y.W. Cathy Tsai, W.C. Cheng, P.W. Weng, C.C. Su, H.S. Chiang, M.P. Chung, C.H. Chung, Y.S. Shieh, and R.Y. Huang. Relationship of the Incidence of C-shaped Root Canal Configurations of Mandibular First Premolars with Distolingual Roots in Mandibular First Molars in a Taiwanese Population: A Cone-beam Computed Tomographic Study. J Endod. 2018; 44(10):1492–1499 e1.
17. Ordinola-Zapata, R., C. Monteiro Bramante, P. Gagliardi Minotti, B. Cavalini Cavenago, J.L. Gutmann, B.I. Moldauer, M.A. Versiani, and M.A. Hungaro Duarte. Micro-CT evaluation of C-shaped mandibular first premolars in a Brazilian subpopulation. Int Endod J. 2015; 48(8):807–13.
18. Mashyakhy, M.H., H.R. Chourasia, A.H. Jabali, H.A. Bajawi, H. Jamal, L. Testarelli, and G. Gambarini. C-shaped canal configuration in mandibular premolars and molars: Prevalence, correlation, and differences: An In Vivo study using cone-beam computed tomography. Niger J Clin Pract. 2020; 23(2):232–239.
19. Shemesh, A., A. Levin, V. Katzenell, J.B. Itzhak, O. Levinson, Z. Avraham, and M. Solomonov. C-shaped canals-prevalence and root canal configuration by cone beam computed tomography evaluation in first and second mandibular molars-a cross-sectional study. Clin Oral Investig. 2017; 21(6):2039–2044.
20. Patel, S. and S. Harvey. Guidelines for reporting on CBCT scans. Int Endod J. 2021; 54(4):628–633.
21. Fan, B., W. Ye, E. Xie, H. Wu, and J.L. Gutmann. Three-dimensional morphological analysis of C-shaped canals in mandibular first premolars in a Chinese population. Int Endod J. 2012; 45(11):1035–41.

22. Velmurugan, N. and R. Sandhya. Root canal morphology of mandibular first premolars in an Indian population: a laboratory study. Int Endod J. 2009; 42(1):54–8.
23. Brea, G., F. Gomez, and J.F. Gomez-Sosa. Cone-beam computed tomography evaluation of C-shaped root and canal morphology of mandibular premolars. BMC Oral Health. 2021; 21(1):236.
24. Arayasantiparb, R. and D. Banomyong. Prevalence and morphology of multiple roots, root canals and C-shaped canals in mandibular premolars from cone-beam computed tomography images in a Thai population. J Dent Sci. 2021; 16(1):201–207.
25. Thanaruengrong, P., S. Kulvitit, M. Navachinda, and P. Charoenlarp. Prevalence of complex root canal morphology in the mandibular first and second premolars in Thai population: CBCT analysis. BMC Oral Health. 2021; 21(1):449.
26. Kaya Buyukbayram, I., R.K. Subay, G. Colakoglu, M.A. Elcin, and M. Ordulu Subay. Investigation using cone beam computed tomography analysis, of radicular grooves and canal configurations of mandibular premolars in a Turkish subpopulation. Arch Oral Biol. 2019; 107:104517.
27. Chaintiou Piorno, R., E.P. Consoli Lizzi, A.F. Gualtieri, and P.A. Rodriguez. C-Shaped canal system in mandibular premolars evaluated by cone-beam computed tomography in a population of the Autonomous City of Buenos Aires, Argentina. Arch Oral Biol. 2021; 123:105040.
28. Alkaabi, W., E. AlShwaimi, I. Farooq, H.E. Goodis, and S.M. Chogle. A Micro-Computed Tomography Study of the Root Canal Morphology of Mandibular First Premolars in an Emirati Population. Med Princ Pract. 2017; 26(2):118–124.
29. Pedemonte, E., C. Cabrera, A. Torres, R. Jacobs, A. Harnisch, V. Ramirez, G. Concha, A. Briner, and C. Brizuela. Root and canal morphology of mandibular premolars using cone-beam computed tomography in a Chilean and Belgian subpopulation: a cross-sectional study. Oral Radiol. 2018; 34(2):143–150.
30. Lu, T.Y., S.F. Yang, and S.F. Pai. Complicated root canal morphology of mandibular first premolar in a Chinese population using the cross section method. J Endod. 2006; 32(10):932–6.
31. Yu, X., B. Guo, K.Z. Li, R. Zhang, Y.Y. Tian, H. Wang, and D.S.T. D. Cone-beam computed tomography study of root and canal morphology of mandibular premolars in a western Chinese population. BMC Med Imaging. 2012; 12:18.
32. Gu, Y., Y. Zhang, and Z. Liao. Root and canal morphology of mandibular first premolars with radicular grooves. Arch Oral Biol. 2013; 58(11):1609–17.
33. Chen, J., X. Li, Y. Su, D. Zhang, X. Wen, X. Nie, J. An, L. Liu, and M. Deng. A micro-computed tomography study of the relationship between radicular grooves and root canal morphology in mandibular first premolars. Clin Oral Investig. 2015; 19(2):329–34.
34. Jang, Y.E., Y. Kim, B. Kim, S.Y. Kim, and H.J. Kim. Frequency of non-single canals in mandibular premolars and correlations with other anatomical variants: an in vivo cone beam computed tomography study. BMC Oral Health. 2019; 19(1):272.
35. Chen, Y.C., C.L. Tsai, Y.C. Chen, G. Chen, and S.F. Yang. A cone-beam computed tomography study of C-shaped root canal systems in mandibular second premolars in a Taiwan Chinese subpopulation. J

Formos Med Assoc. 2018; 117(12):1086–1092.

36. Ahmed, H.A., N.H. Abu-bakr, N.A. Yahia, and Y.E. Ibrahim. Root and canal morphology of permanent mandibular molars in a Sudanese population. International Endodontic Journal. 2007; 40(10):766–771.
37. Al-Qudah, A.A. and L.A. Awawdeh. Root and canal morphology of mandibular first and second molar teeth in a Jordanian population. Int Endod J. 2009; 42(9):775–84.
38. Zhang, R., H. Wang, Y.Y. Tian, X. Yu, T. Hu, and P.M. Dummer. Use of cone-beam computed tomography to evaluate root and canal morphology of mandibular molars in Chinese individuals. Int Endod J. 2011; 44(11):990–9.
39. Pan, J.Y.Y., A. Parolia, S.R. Chuah, S. Bhatia, S. Mutalik, and A. Pau. Root canal morphology of permanent teeth in a Malaysian subpopulation using cone-beam computed tomography. BMC Oral Health. 2019; 19(1):14.
40. Peiris, R., M. Takahashi, K. Sasaki, and E. Kanazawa. Root and canal morphology of permanent mandibular molars in a Sri Lankan population. Odontology. 2007; 95(1):16–23.
41. Gulabivala, K., T.H. Aung, A. Alavi, and Y.L. Ng. Root and canal morphology of Burmese mandibular molars. Int Endod J. 2001; 34(5):359–70.
42. Vaz de Azevedo, K.R., C.B. Lopes, R. Andrade, F.F.N. Pacheco da Costa, L.S. Goncalves, R. Medeiros Dos Santos, and F.R.F. Alves. C-shaped canals in first and second mandibular molars from Brazilian individuals: A prevalence study using cone-beam computed tomography. PLoS One. 2019; 14(2):e0211948.
43. Alfawaz, H., A. Alqedairi, A.K. Alkhayyal, A.A. Almobarak, M.F. Alhusain, and J.N.R. Martins. Prevalence of C-shaped canal system in mandibular first and second molars in a Saudi population assessed via cone beam computed tomography: a retrospective study. Clin Oral Investig. 2019; 23(1):107–112.
44. Silva, E.J., Y. Nejaim, A.V. Silva, F. Haiter-Neto, and N. Cohenca. Evaluation of root canal configuration of mandibular molars in a Brazilian population by using cone-beam computed tomography: an in vivo study. J Endod. 2013; 39(7):849–52.
45. Nejaim, Y., A.F. Gomes, L.P.L. Rosado, D.Q. Freitas, J.N.R. Martins, and E. da Silva. C-shaped canals in mandibular molars of a Brazilian subpopulation: prevalence and root canal configuration using cone-beam computed tomography. Clin Oral Investig. 2020; 24(9):3299–3305.
46. Celikten, B., P. Tufenkci, U. Aksoy, A. Kalender, F. Kermeoglu, P. Dabaj, and K. Orhan. Cone beam CT evaluation of mandibular molar root canal morphology in a Turkish Cypriot population. Clin Oral Investig. 2016; 20(8):2221–2226.
47. Demirbuga, S., A.E. Sekerci, A.N. Dincer, M. Cayabatmaz, and Y.O. Zorba. Use of cone-beam computed tomography to evaluate root and canal morphology of mandibular first and second molars in Turkish individuals. Med Oral Patol Oral Cir Bucal. 2013; 18(4):e737-44.
48. Gulabivala, K., A. Opasanon, Y.L. Ng, and A. Alavi. Root and canal morphology of Thai mandibular molars. Int Endod J. 2002; 35(1):56–62.

49. Khawaja, S., N. Alharbi, J. Chaudhry, A.H. Khamis, R.E. Abed, A. Ghoneima, and M. Jamal. The C-shaped root canal systems in mandibular second molars in an Emirati population. Sci Rep. 2021; 11(1):23863.
50. Zheng, Q., L. Zhang, X. Zhou, Q. Wang, Y. Wang, L. Tang, F. Song, and D. Huang. C-shaped root canal system in mandibular second molars in a Chinese population evaluated by cone-beam computed tomography. Int Endod J. 2011; 44(9):857–62.
51. Kim, S.Y., B.S. Kim, and Y. Kim. Mandibular second molar root canal morphology and variants in a Korean subpopulation. Int Endod J. 2016; 49(2):136–44.
52. Martins, J.N.R., A. Mata, D. Marques, and J. Carames. Prevalence of C-shaped mandibular molars in the Portuguese population evaluated by cone-beam computed tomography. Eur J Dent. 2016; 10(4):529–535.
53. Patel, S., C. Durack, F. Abella, H. Shemesh, M. Roig, and K. Lemberg. Cone beam computed tomography in Endodontics - a review. Int Endod J. 2015; 48(1):3–15.
54. Patel, S., J. Brown, T. Pimentel, R.D. Kelly, F. Abella, and C. Durack. Cone beam computed tomography in Endodontics - a review of the literature. Int Endod J. 2019; 52(8):1138–1152.

Tables

Table 1 Distribution of males and females in different age groups

Age	Males	Females	sum
≤20	88(40.55%)	129(59.45%)	217
21-30	156(29.83%)	367(70.17%)	523
31-40	46(23.71%)	148(76.29%)	194
41-50	15(30.61%)	34(69.39%)	49
≥51	3(17.65%)	14(82.35%)	17
sum	308(30.80%)	692(69.20%)	1000
P value	0.003		

There was a significant difference in the proportion of gender among age groups

Table 2 Distribution of CSRCs and RGs in different tooth positions and sex

		CSRCs			RGs		
		Males (308)	Females (692)	*P* value	Males (308)	Females (692)	*P* value
Left	MFPs*	49(15.90%)	53(7.65%)	0.000	81(26.29%)	130(18.78%)	0.007
	MSPs	1(0.32%)	2(0.28%)	1	2(0.64%)	4(0.57%)	1
	MFMs	1(0.32%)	3(0.43%)	1	1(0.32%)	3(0.43%)	1
	MSMs*	99(32.14%)	369(53.32%)	0.000	99(32.14%)	369(53.32%)	0.000
Right	MFPs*	51(16.55%)	52(7.51%)	0.000	85(27.59%)	126(18.20%)	0.001
	MSPs	0	2(0.28%)	1	2(0.64%)	0	0.095
	MFMs	1(0.32%)	6(0.86%)	0.683	1(0.32%)	6(0.86%)	0.683
	MSMs*	110(35.71%)	363(52.45%)	0.000	110(35.71%)	363(52.45%)	0.000

***** The incidence of CSRCs in MFPs of males was higher than that in females, while the incidence of CSRCs in MSMs of females was higher than that in males

Table 3 The incidence of CSRCs in different types of RGs

	RGs (CSRCs)							
	ML	Misal	Distal	Buccal	Lingual	ML and Buccal	Buccal and Lingual	*P* value
MFPs	368(175)	1(0)		3(3)	37(20)	12(6)	1(1)	0.338
MSPs	2(1)		1(1)		5(3)			1

Table 4 The incidence of CSRCs in different types of canal bifurcations

	Non	Coronal	Middle	Apical	*P* value
MFPs	98(23) *	79(47)	214(122)	31(13)	0.000
MSPs	5(2)	1(1)	2(2)		0.643

* The incidence of CSRCs in Non-group was significantly lower than that in the other group

Table 5 Configurations of different axials in mandibular premolars and molars

	MFPs				MSPs				MFMs				MSMs			
	A	B	C	D	A	B	C	D	A	B	C	D	A	B	C	D
C1	0	37	25	6	0	3	0	0	4	1	1	0	518	229	264	56
C2	0	48	112	0	0	1	2	0	4	4	5	1	338	501	402	222
C3	47	107	52	123	0	1	1	1	1	6	5	8	32	205	178	152
C4	158	13	15	56	5	0	2	3	2	0	0	2	53	5	79	479
C5	0	0	1	20	0	0	0	1	0	0	0	0	0	1	18	32

Table 6 Prevalence of CSRCs in different tooth positions among different age groups

Age	MFPs	MSPs	MFMs	MSMs
≤20(434)	67(15.44%)	1(0.23%)	2(0.46%)	214(49.31%)
21-30(1046)	109(10.42%)	2(0.19%)	6(0.57%)	500(47.80%)
31-40(388)	17(4.38%)	1(0.26%)	0	179(46.13%)
41-50(98)	8(8.16%)	1(1.02%)	0	38(38.78%)
≥51(34)	4(11.76%)	0	1(2.94%)	10 (29.41%)
P value	0.000	0.423	0.158	0.085

There was a significant difference in the prevalence of CSRCs in MFPs among age groups

Figures

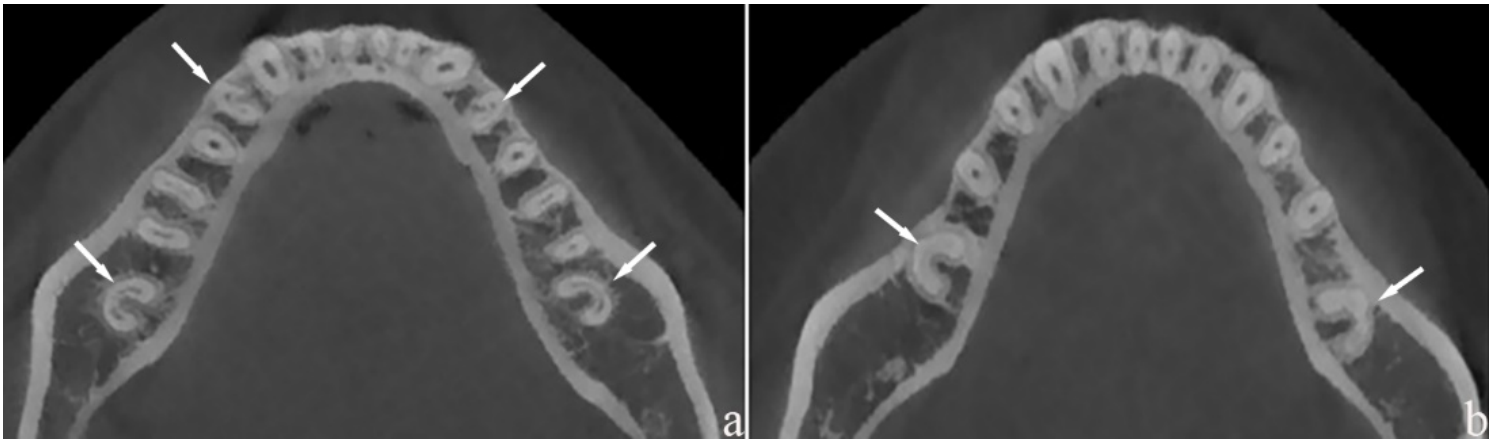

Figure 1

(a) Bil-CSRCs in MFPs and MSMs (arrows), (b) Bil-CSRCs in MFMs (arrows).

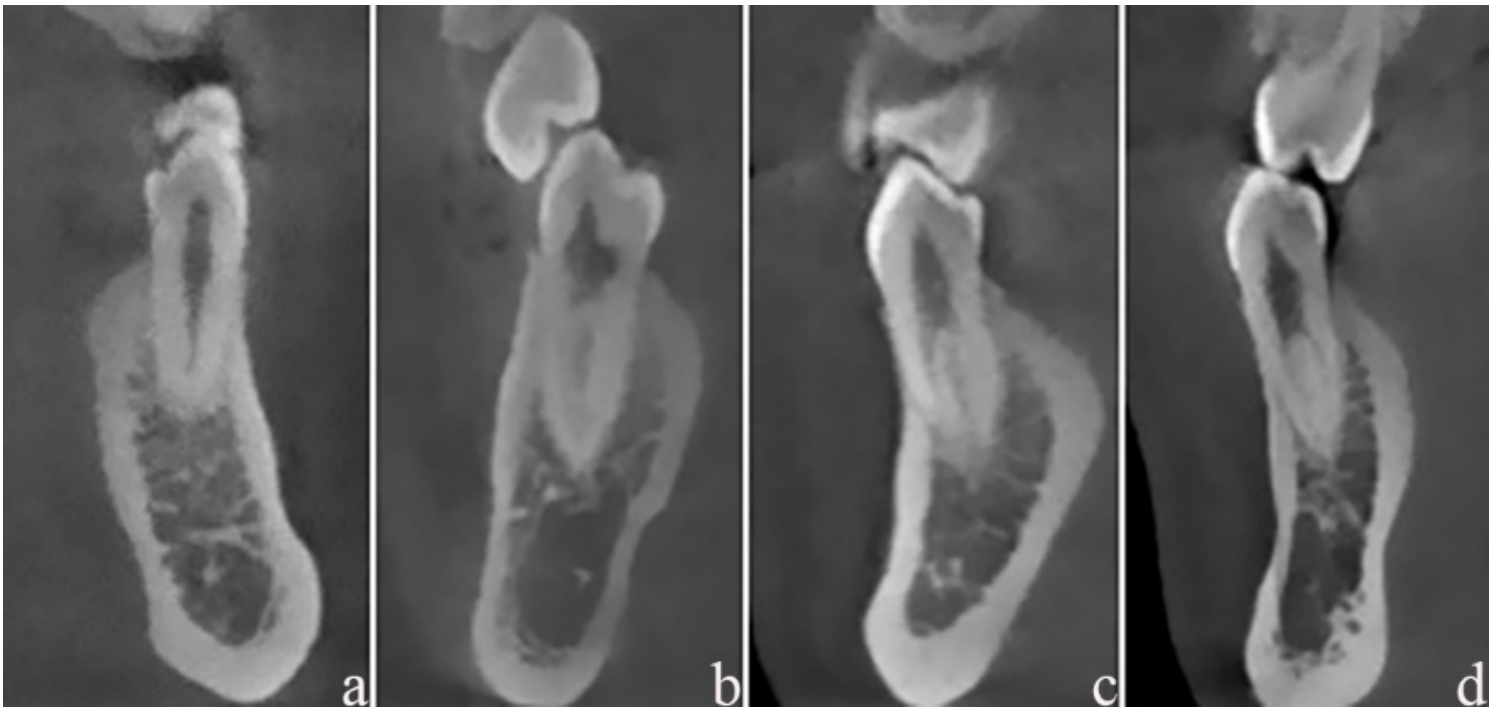

Figure 2

Several examples of root canal system configurations in mandibular premolars according to Vertucci classification (a: I; b: III; c: V; d: VII).

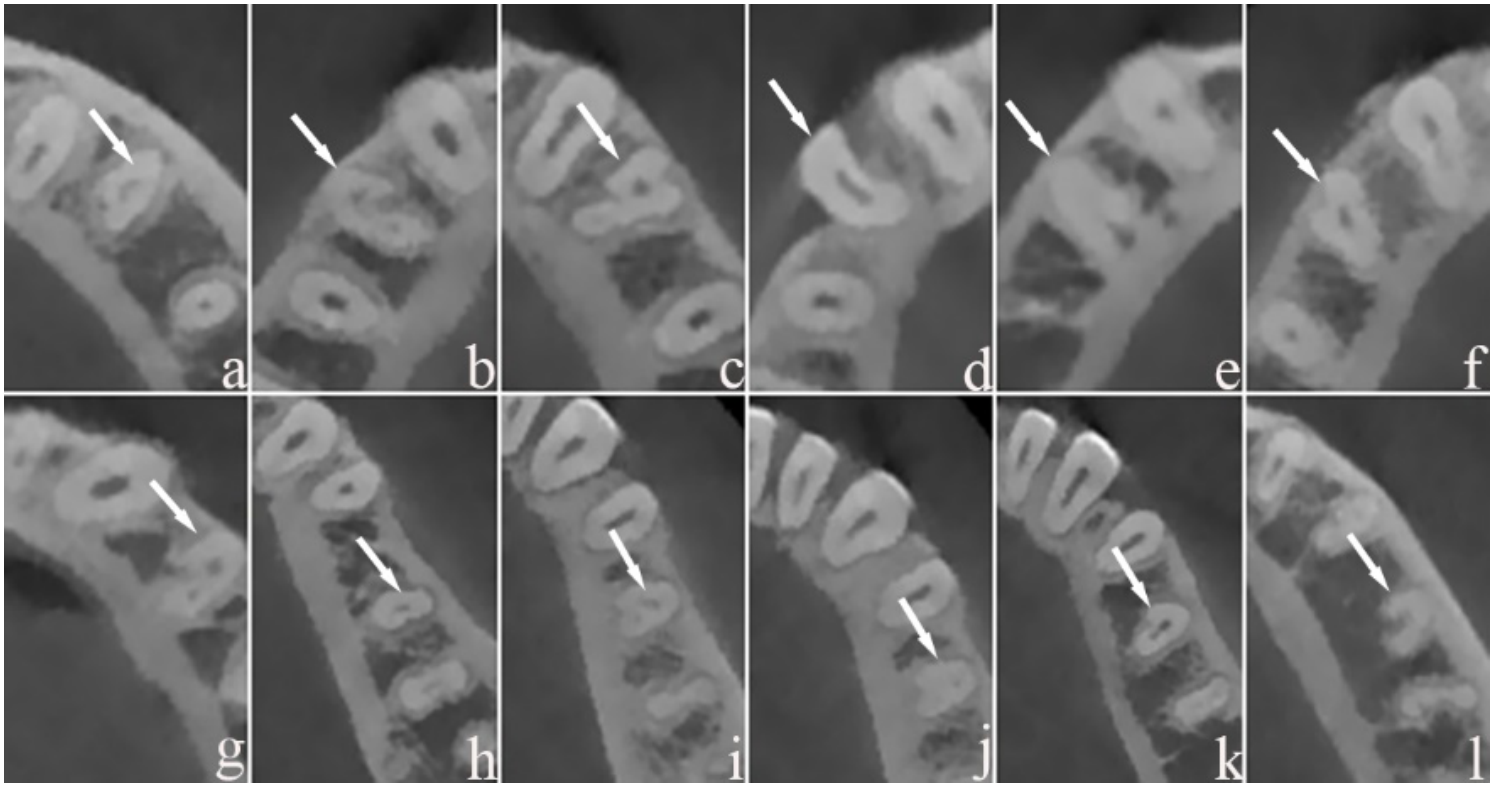

Figure 3

Different types of CSRCs and RGs in MFPs (a, C1, Lingual; b, C2, ML; c, C3, ML and Buccal; d, C4, Mesio; e, C5, Lingual; f, C4, Buccal; g, C4, ML;) and MSPs (h, C1, Distal; i, C2, Lingual; j, C3, Lingual; k, C4, ML; l, C5, Lingual).



Figure 4

Different types of CSRCs and RGs in MFMs (a, C1, Lingual; b, C2, Lingual; c, C3, Lingual; d, C3, Buccolingal; e, C5, Lingual;) and MSMs (f, C1, Lingual; g, C2, Buccolingual; h, C1, Buccal; i, C3, Lingual; j, C3, Buccolingual; k, C4, Lingual; l, C5, Lingual).

Supplementary Files

This is a list of supplementary files associated with this preprint. Click to download.

- CBCTdata.xlsx