Research Square

Preprints are preliminary reports that have not undergone peer review. They should not be considered conclusive, used to inform clinical practice, or referenced by the media as validated information.

Chest Wall Resection and Reconstruction for Locally Recurrent Breast Cancer : An Experience Over a 5-Year Period

Qiang Sun
The First Hospital of China Medical University: The First Affiliated Hospital of China Medical University
Yu-xin Wang
The First Hospital of China Medical University: The First Affiliated Hospital of China Medical University
Shi-feng Jin
The First Hospital of China Medical University: The First Affiliated Hospital of China Medical University
Chen-chao Wang
The First Hospital of China Medical University: The First Affiliated Hospital of China Medical University
You Zhou
The First Hospital of China Medical University: The First Affiliated Hospital of China Medical University
Shu Guo (sguo@cmu.edu.cn)
The First Hospital of China Medical University https://orcid.org/0000-0001-9094-1602

Research

Keywords: locally recurrent breast cancer, chest wall resection, chest wall reconstruction

Posted Date: January 11th, 2021

DOI: https://doi.org/10.21203/rs.3.rs-141171/v1

License: This work is licensed under a Creative Commons Attribution 4.0 International License. Read Full License

---

Abstract

Background

Expanded local resection is suitable for recurrent breast cancer patients who have isolated local lesion and have not metastasized. The extend of chest wall resection must be overall radical resection of the tumors diagnosed by pathology. However, surgery often leads to huge defects, even full-thickness defects, and these defects are difficult to repair.

Methods

Chest wall resection was performed in 5 patients with locally recurrent breast cancer, followed by chest wall reconstruction with a pedicled rectus abdominis musculocutaneous flap or a pedicled latissimus dorsi musculocutaneous flap and, if necessary, a piece of titanium mesh.

Results

Chest wall resection and reconstruction were successfully achieved in all 5 patients. No complication and recurrence were observed, except one patient died of late lymphatic metastasis. Other patients reported good quality of life.

Conclusions

For locally recurrent breast cancer, complete tumor resection is complete tumor resection is essential and ensures no recurrence. Appropriate material and the blood-rich flap or myocutaneous flap should be used to reconstruct the chest wall defect as an effective treatment for surgical procedure.

Background

Comprehensive therapy of breast cancer, including surgical excision, radiotherapy, chemotherapy, endocrinotherapy, and a combination of above approaches, is increasing beneficial for prolonging life [1–3]. However, it is sometimes difficult to avoid tumor recurrence. Although the main goal of chest wall resection is to achieve local tumor control, it may lead to long-term remission [4]. For primary breast cancer, an expanded radical resection is not required. However, regardless of the adjuvant therapy, expanded surgical excision is the essential procedure for the treatment of locally recurrent breast cancer. Repairing huge chest wall defects, especially full-thickness defects, is very difficult. If it is not repaired in time, it will not only damage the internal organs of the thorax, but also cause pathophysiological changes, such as chest wall softening, abnormal breathing and longitudinal swing, which will seriously affect the patient's respiratory cycle function [5]. Furthermore, locally advanced primary breast cancer and radiotherapy following a mastectomy are associated with chest wall defects. Therefore, chest wall resection is an important and essential procedure for the treatment of locally recurrent breast cancer, but ideal reconstruction is a guarantee to completely expanded resection.

It has been reported that chest wall resection has many surgical procedures [6–9], and is usually followed by reconstruction [3]. The purpose of reconstruction of chest wall is to restore the continuity of the chest wall structure, protect the thoracic organs, maintain the normal respiratory cycle function, and at the same time obtain a good thoracic shape, including chest wall bone reconstruction. Chest wall bone reconstruction used titanium mesh to stabilize the chest wall, local skin flaps to cover soft tissue, pedicled musculocutaneous flaps or free musculocutaneous flaps to cover the chest wall [10–12].

Titanium micromesh reconstruction of the chest wall has the following advantages: tough texture, good shape, simple surgical method, good biocompatibility, and no need to place subcutaneous drainage. This is because that the subcutaneous exudate can be discharged into the chest tube through meshes of the titanium mesh [13].

Herein, we reported our experience in chest wall resection and reconstruction of patients with locally recurrent breast cancer using a pedicled latissimus dorsi musculocutaneous flap or a pedicled rectus abdominis musculocutaneous flap, and a piece of titanium mesh if necessary.

Methods

Clinical data

Between April 2010 and June 2014, chest wall resection and reconstruction was performed in 5 women with locally recurrent breast cancer and chest wall invasion at the First Hospital of China Medical University.

Preoperative preparation

Preoperative evaluation of the 5 patients included clinical examination, blood analysis, CT scan, and so on, to ensure that patients can tolerate surgery and completely reconstruct the defects. In addition, all patients underwent vessel detections, such as Doppler ultrasound.

Surgical method

In all patients, an expanded local resection (including at least 2 cm normal tissue around the lesion) was first performed, and pathologically confirmed by negative tissue margins. Afterward, chest wall reconstruction was achieved using a pedicled rectus abdominis musculocutaneous flap or a pedicled latissimus dorsi musculocutaneous flap [10–12]. The type of skin flap was provided based on the result of vessel detection, and then selected according to patient's wishes. For example, if both of the two skin flaps were available, but the patient was overweight. The patient may choose a pedicled rectus abdominis musculocutaneous flap, but do not choose a pedicled latissimus dorsi musculocutaneous flap to reduce abdominal weight. For the full-thickness defect, a titanium mesh (Solothurn, Switzerland) may be used to stabilize the chest wall. The edge of margin of titanium mesh was 1–2 cm larger than the margin of the defect to secure the titanium mesh on libs with titanium screws (Solothurn, Switzerland).

Statistical analysis

Data collected in this study included patient demographics, diagnosis, clinical examination, blood analysis, surgical data, adjuvant therapy data, and postoperative care data. Surgical data were obtained from operative reports, including indication and type of surgery, location and size of chest wall defects, number of resected ribs, prosthesis, type of skin flaps, and histological diagnosis. Postoperative care data mainly included postoperative hospital stay, follow-up time, complications, and patient status and satisfaction.

Results

In four years, a total of five patients with locally recurrent breast cancer, who underwent follow-up visit, were confirmed to statistics. The mean age of the 5 patients was 53.4 years, ranging from 33 to 72 years old (**Table 1**).

After diagnosis, there were 3 cases of ductal-invasive carcinoma, 1 case of metaplastic carcinoma, and 1 case of malignant phyllodes tumor. All patients' tumors were removed completely under the microscope. Four patients underwent the plastic reconstruction with a pedicled latissimus dorsi musculocutaneous flap, and the other underwent the plastic reconstruction with a pedicled rectus abdominis musculocutaneous flap. In addition, two patients underwent costectomy using a piece of titanium mesh to stabilize the chest walls were. The chest tubes were removed respectively 3 and 8 days after surgery.

All patients underwent a 3-day antibiotic treatment, except that one patient underwent a 5-day antibiotic treatment, and the chest tube was removed 8 days after surgery. After surgery, 3 patients received both adjuvant radiotherapy and chemotherapy, and 1 patient received only adjuvant chemotherapy. The other patient diagnosed with malignant phyllodes tumor did not received any adjuvant therapy.

Under prophylactic antibiotic treatment, all wounds showed a pattern of physiologic healing. There is no postoperative complications, such as flap necrosis, haematoma or seroma, herniation, local infection, hemia, respiratory failure, and pleural effusion.

All patients were followed up for 5 years after surgery, with a minimal interval of 1 year. At that time, only 1 patient died of late distant lymphatic metastasis at 27 months after surgery. The other 4 patients were still alive and had no local recurrence.

Typical Case

A 57-year-old female patient underwent radical mastectomy in 1995. However, the wound did not healed, and gradually became larger and worse. Even worse, she developed local ductal-invasive carcinoma recurrence (Fig. 1A).

Resection of the lesion: in December 2012, expanded local resection was performed according to pathologic demonstration, and the left chest wall defect was approximately 20 cm × 15 cm (Fig. 1B). The full-thickness defect was from the second to fifth ribs, about 12 cm × 10 cm. The heart and lung were all exposed.

Reconstruction of chest wall defect: A piece of titanium micromesh was used to stabilize the thoracic cage defect (Fig. 1C). Thereafter, the defect was further reduced to 17 cm × 14 cm, which was larger than 15 cm × 13 cm of preoperative estimation. It was considered that the pedicled rectus abdominis musculocutaneous flap was the best reconstruction option. This is because that in addition to epigastric vessels, Doppler ultrasound cannot detect adjacent vessels that may contribute to reparation. The flap turned up 180° towards the defect through the subcutaneous space without tension (Fig. 1D). Thoracic surgeon completed closed thoracic drainage.

Repair of abdominal defect: The pedicled aponeurosis flap of obliquus externus abdominis was about 10 cm × 5 cm, sutured with the white line below the arcuate line and the free edge of the anterior sheath of the rectus abdominis. The abdominal wall was then repaired and reinforced with a piece of e-PTFE about 8 cm × 6 cm (Fig. 1E). An incision about 10 cm long was made on the left umbilical level to form a rotation and advancement flap, which was then sutured with a advancement flap formed by the residual tissue of the right abdomen.

The patient left hospital 7 days after operation. The postoperative procedure was uneventful without any complication, such as paradoxical respiration, abdominal hernia, flap necrosis, wound infection, and so on (Fig. 1F). In addition, no signs of recurrence were found during the 5-year follow-up period.

Discussion

Therapy for locally recurrent breast cancer

Approximately 30% of patients experienced recurrence of breast cancer, but most patients with metastases may lose their chance of surgery [14]. The incidence of locally recurrent breast cancer was 4% (2–20%), and can occur as an isolated cancer or in combination with distant metastasis in other organ systems [15]. That's why we reported a small number of surgical cases within 5 years. Whenever possible, isolated local recurrence should be treated with a curative intent. If feasible, it was recommended to pathologically confirm the margin of negative tissue and completely remove the recurrent tumor [16]. The resection area must contain at least 2 cm of normal tissue around lesion [17, 18]. Then, the chest wall defect coverage should be performed immediately instead of breast reconstruction. This was due to limited tissue, limited surgical tolerance, and poor patient willingness to perform breast reconstruction immediately. Adjuvant treatments for recurrent breast cancer were radiotherapy, endocrine therapy in patients with estrogen or progesterone receptor-positive cancer, and chemotherapy in patients with receptor-negative cancer [19–21].

Reconstruction Materials for the chest wall bone

Local recurrence of breast cancer in the deep chest wall will lead to thoracic defects after surgery. If the diameter of full-thickness defect was greater than 6 cm, or if there were more than three defected ribs, especially in the anterior and lateral chest wall, it is recommended to reconstruct the chest wall bone in order to maintain proper cardio-pulmonary function [22]. Ideally, materials used for chest wall reconstruction should have good tensile strength, elasticity, stable physical and chemical properties, ease of use, ready availability, and high biocompatibility as well as characteristics that do not affect chest inspections [23]. Various materials for chest wall reconstruction were classified into autologous tissue, allogeneic tissue, and artificial materials [24–27].

Although autologous tissue and allogeneic tissue are considered to be the most suitable repair materials for human physiology, the disadvantages of autologous and allogeneic tissues are limited materials, increased trauma, increased difficulty in surgery, poor satisfaction in shaping, poor aesthetics, and insufficient hardness. These disadvantages often lead to postoperative abnormal breathing, thus it is more suitable for smaller defect repair and difficult to repair larger defect area, especially in the case of local infection or radioactive necrosis. Compared with autologous tissue, artificial materials have better bone support for the chest wall, simplifying the operation process, shortening the operation time, and reducing the surgical trauma. Therefore, for larger chest wall defects, artificial materials are currently the preferred materials for bone reconstruction [28].

Although many artificial repair materials were used clinically, none of them can meet all of the above requirements at the same time. Polytetrafluoroethylene (PTFE) patch may injury intrathoracic organs due to thermal reaction. Insufficient rigidity of repair materials such as Marlex mesh, Prolene mesh, Vicryl mesh, Gare-Tex patch may cause abnormal breathing. Autologous tissue and allogeneic

tissue are not suitable for bone reconstruction of large chest wall defects. Moreover, titanium mesh has become a better option, originally created for craniofacial reconstruction [29, 30]. Thus, we applied titanium mesh to stabilize the chest wall in two cases because titanium mesh has the following characteristics: rigid enough to prevent paradoxical respiration movement; malleability can be shaped into appropriate shape, inertness can avoid immune rejection, radiolucency can used for radiographic tracking of potential problems, and porosity can allow in-growth of fibrous tissue [31]. Although it affects X-ray inspection, CT and MRI are now more common and accurate for chest examination. Therefore, we recommend titanium mesh for bone reconstruction of large chest wall defects.

Selection of flaps for the chest wall reconstruction

As a prerequisite for stabilizing the chest wall, care should be taken to cover the soft tissue coverage, not only to cover the artificial material that reconstructs the chest wall, but also restore the integrity of the chest wall, maintain the function of normal breathing and circulation, and improve the appearance and quality of life of the patients [11, 12]. The soft tissue characteristics of recurrent breast cancer are often quite different from those of the primary cancer. There may be no donor vessels in the lesion available for free flaps because of resection and radiotherapy. Meantime, for recurrent breast cancer patients, the simpler the surgery, the less invasive. Hence, free flaps are not preferred. Especially for closure of large defects, they are not the first choice for increasing the time of surgery and the incidence of complications. In addition to the local flap, the pedicle flap, or both flaps fail to repair [32, 33]. Myocutaneous flaps are more suitable for the repair of breast cancer patients [33].

The selection of flaps depends primarily on the location and area of the defect. On the vertical axis, the latissimus dorsi musculocutaneous flap and the pectoralis major myocutaneous flaps are generally recommended for use in the upper 1/3 of the chest wall. It is recommended to use the latissimus dorsi musculocutaneous flap, rectus abdominis myocutaneous flap, pectoralis major myocutaneous flap, and omentum in the middle 1/3 of the chest wall. For the lower 1/3 of chest wall, it is recommended to use the rectus abdominis myocutaneous flap and omentum flap. On the horizontal axis, if the defect is located in the center of the chest wall, the latissimus dorsi musculocutaneous flap [34], the rectus abdominis myocutaneous flap [35] and the pectoralis major myocutaneous flap [36, 37] can be repaired. In addition, in the lateral chest wall, the latissimus dorsi musculocutaneous flap is more commonly used.

However, the pectoralis major is usually resected in the locally recurrent breast cancer patients. Although the omentum flap has abundant blood supply, strong anti-infection ability, and strong plasticity, there is still a high risk of complicated operation, prolonged operation time, hemorrhage, abdominal hernia, and gastrointestinal complications after surgery. This is why they are not the first choice for repairing chest wall defects. Although the latissimus dorsi myocutaneous flap may affect the ability of arm to lift, and the rectus abdominis myocutaneous flap may cause a weakness of the abdominal wall, they are still recommended [1, 2, 10, 11]. In addition, they not only provide enough volume to cover a large soft tissue defect, but also are simple to operate and can achieve good outcome.

Radical mastectomy and subsequent radiation may result in the loss of many important tissues, such as vessels, which may result in some of those flaps being unstable for reconstruction. Therefore, it is an important process to detect adjacent vessels by Doppler ultrasound before the operation.

Conclusion

In summary, for locally recurrent breast cancer, complete tumor resection is a crucial step and ensures that there is no recurrence. After surgery, the appropriate material should be selected to reconstruct the chest wall to restore the integrity of the thorax. Finally, according to the location and size of the defect, the blood-rich flap or myocutaneous flap is used to cover the wound, eliminate the dead space, and repair the soft tissue defect of the chest wall.

Abbreviations

CT
computed tomography
PTFE
Polytetrafluoroethylene

Declarations

Ethics approval and consent to participate

This study was approved by the Ethics Committee of the First Hospital of China Medical University, and written informed consent was obtained before surgery from all patients.

Consent to publish

Not applicable.

Availability of data and meterials

All data generated or analyzed during this study are included in this published article.

Competing interests

The authors declare that they have no competing interests.

Funding

Not applicable.

Authors' contributions

SQ, GS and WYX designed this study. JSF, WCC and ZY collected literatures and conducted the analysis of data. ZY drafted the manuscript. SQ wrote the manuscript. All authors contributed to review the manuscript. All authors read and approved the final manuscript.

Acknowledgements

Not applicable.

References

[1] Marschner N , Trarbach T , Rauh J , et al. Quality of life in pre- and postmenopausal patients with early breast cancer: a comprehensive analysis from the prospective MaLife project. Breast Cancer Research and Treatment, 2019:1-12.

[2] Skoracki RJ, Chang DW. Reconstruction of the chest-wall and thorax. J Surg Oncol 2006; 94: 455-465.

[3] Caswell-Jin J L , Mcnamara K , Reiter J G , et al. Clonal replacement and heterogeneity in breast tumors treated with neoadjuvant HER2-targeted therapy. Nature communications, 2019, 10(1):657.

[4] Santillan AA, Kiluk JV, Cox JM, Meade TL, Allred N, Ramos D, , King J, Cox CE. Outcomes of locoregional recurrence after

surgical chest wall resection and reconstruction for breast cancer. Ann Surg Oncol 2008; 15: 1322-1329.

[5] Chagpar A, Meric-Bernstam F, Hunt KK. Chest wall recurrence after mastectomy does not always portend a dismal outcome. Ann Surg Oncol 2003; 10: 628-634.

[6] Arnold PG, Pairolero PC. Chest-wall reconstruction: an account of 500 consecutive patients. Plast Reconstr Surg 1996; 98: 804-810.

[7] Beahm EK, Chang DW. Chest wall reconstruction and advanced disease. Semin Plast Surg 2004; 18: 117-129.

[8] Larson DL, Mcmurtrey MJ, Howe HJ, Irish CE. Major chest wall reconstruction after chest wall irradiation. Cancer 1982;49:1286-1293.

[9] Spicer J D, Shewale J B , Antonoff M B , et al. The Influence of Reconstructive Technique on Perioperative Pulmonary and Infectious Outcomes Following Chest Wall Resection[J]. The Annals of Thoracic Surgery, 2016: S0003497516305677.

[10] Hathaway CL, Rand RP, Moe R, Marchioro T. Salvage surgery for locally advanced breast cancer and locally recurrent breast cancer. Arch Surg 1994; 129: 582-7.

[11] Veronesi G, Scanagatta P, Goldhirsch A, Rietjens M, Colleoni M, Pelosi G, Spaggiari L. Results of chest wall resection for recurrent or locally advanced breast malignancies. Breast 2007; 16: 297-302.

[12] Tukiainen, E. Chest Wall Reconstruction after Oncological Resections[J]. Scandinavian Journal of Surgery, 2013, 102(1):9-13.

[13] Tamburini N, Grossi W, Sanna S, et al. Chest wall reconstruction using a new titanium mesh: a multicenters experience. J Thorac Dis 2019;11(8):3459-3466.

[14] Pennery E. The role of endocrine therapies in reducing risk of recurrence in postmenopausal women with hormone receptor-positive breast cancer. Eur J Oncol Nurs 2008; 12: 233-243.

[15] E.-M. Grischke, D.Wallwiener, R. Souchon, T. Fehm, C. R. Loehberg, S.M. Jud, M. P. Lux, M.W. Beckmann, S. P. Renner. Isolated Loco-Regional Recurrence of Breast Cancer-Established and Innovative Therapy Concepts. Geburtsh Frauenheilk 2013; 73: 611–622.

[16] Cardoso F, Harbeck NL. Fallowfield, Kyriakides S, Senkus E. ESMO Guidelines Working Group. Locally recurrent or metastatic breast cancer: ESMO Clinical Practice Guidelines for diagnosis, treatment and follow-up. Ann Oncol 2012; 23 Suppl 7: vii11-19.

[17] Friedel G, Kuipers T, Dippon J, Al-Kammash F, Walles T, Kyriss T, Veit S, Greulich M, Steger V. Full-Thickness Resection With Myocutaneous Flap Reconstruction for Locally Recurrent Breast Cancer. Ann Thorac Surg 2008; 85: 1894-1900.

[18] Aukema TS, Russell NS, Wesseling J, Rutgers EJ. Extensive soft tissue resection with autologous tissue closure for locally recurrent breast cancer: Lasting local control and acceptable morbidity. Eur J Surg Oncol 2009; 35: 469-474.

[19] Buzdar AU. Phase III study of letrozole versus tamoxifen as first-line therapy of advanced breast cancer in postmenopausal women: analysis of survival and update of efficacy from the international letrozole breast cancer group. J Clin Oncol 2004; 22: 3199-3200.

[20] Robertson JF, Come SE, Jones SE, Beex L, Kaufmann M, Makris A, Nortier JW, Possinger K, Rutqvist LE. Endocrine treatment options for advanced breast cancer-the role of fulvestrant. Eur J Cancer 2005; 41: 346-356.

[21] Sledge GW, Neuberg D, Bernardo P, Ingle JN, Martino S, Rowinsky EK, Wood WC. Phase III trial of doxorubicin, paclitaxel and the combination of doxorubicin and paclitaxel as front-line chemotherapy for metastatic breast cancer: an intergroup trial. J Clin Oncol 2003; 21: 588-592.

[22] F Thomas PA, Brouchet L. Prosthetic reconstruction of the chest wall. Thorac Surg Clin 2010; 20: 551-558.

[23] Ursula H, Philipp S, Patrick Z. Chest wall resection and reconstruction for locally advanced primary breast cancer. Arch Gynecol Obstet 2013; 287: 1205-1209.

[24] McCormack PM. Use of prosthetic materials in chest-wall reconstruction. Surg Clin North Am 1989; 69: 965-966.

[25] Nomori H, Horio H, Hasegawa T. Chest wall reconstruction using titanium hollow screw reconstruction plate. Thorac Cardiovasc Surg 1997; 45: 35-37.

[26] Burkhart HM, Allen MS, Nichols FC III, Deschamps C, Miller DL, Trastek VF, Pairolero PC. Results of en bloc resection for bronchogenic carcinoma with chest wall invasion. J Thorac Cardiovasc Surg 2002; 123: 670-675.

[27] Mansour KA, Thourani VH, Losken A, Reeves JG, Miller JI Jr, Carlson GW, Jones GE. Chest wall resections and reconstruction: a 25-year experience. Ann Thorac Surg 2002; 73: 1720-1726.

[28] Deschamps C, Tirnaksiz BM, Darbandi R, Trastek VF, Allen MS, Miller DL, Arnold PG, Pairolero PC. Early and long-term results of prosthetic chest wall reconstruction. J Thorac Cardiovasc Surg 1999; 117: 588-591; discussion 591-592.

[29] Zimmerman M, Seifert V. Anatomic reconstruction of the posterolateral cranial base with titanium micromesh for combined transpetrosal approach: technical note. Neurosugery 1997; 41: 983-985.

[30] Jones C, Rogers S. Combined use of titanium mesh and biocompatible osteoconductive polymer in the treatment of full thickness calvarial defects. Br J Oral Maxillofac Surg 1998; 36: 143-145.

[31] Rong G, Kang H. Local recurrence involving the sternum and ribs following mastectomy and titanium mesh implants for chest wall reconstruction: A case report. Oncol Lett 2013; 5: 1649-1652.

[32] Dudek W, Schreiner W, Horch RE, Sirbu H. Sternal resection and reconstruction for secondary malignancies. J Thorac Dis 2018;10(7):4230-4235.

[33] Chang RR, Mehrara BJ, Hu QY, Disa JJ, Cordeiro PG. Reconstruction of complex oncologic chest wall defects: a 10-year experience. Ann Plast Surg 2004, 52: 471-479.

[34] Hameed A, Akthar S, Naqvi A, Pervaiz Z. Reconstruction of complex chest wall defects by using polypropylene mesh and a pedicled latissimusdorsi flap: a 6-year experience. J Plast Reconstr Aesth Surg 2008, 61: 628-635.

[35] Martella S, Caliskan M, Brenelli FP, Rossetto F, Aparecida De Oliveira H, De Brito Lima LN, Chifu C, Rodriguez-Fernandez J, Petit JY, Luini A. Surgical closure of chest wall in noninflammatory locally advanced breast carcinoma with ulceration of the skin. Breast J 2008, 14: 345-352.

[36] Zhou F, Liu W, Tang Y. Autologous rib transplantation and terylene patch for repair of chest wall defect in a girl with Poland syndrome: a case report. J Pediatr Surg 2008, 43: 1902-1905.

[37] Hoch J, Eckmann S, Stahlenbrecher A, Elsner T. The contralateral pectoralis muscle fl ap: a valuable afternative to cover chest wall tissue defects. Eur J Plast Surg 2006, 29: 85-88.

Tables

Table 1. Clinical, resection and reconstruction data

in all patients with locally recurrent breast cancer

No.	Age	Histological diagnosis	TNM classification	Size of defect	Type of skin flaps	Adjuvant therapy	Complications (including donor site)	Duration of follow-up (months)	Present condition
1	49	Ductal-invasive carcinoma	T2N0M0	20×18	A	Radiotherapy and chemotherapy	None	109	Alive and non-recurrence
2	57	Ductal-invasive carcinoma	T3N0M0	20×15 (full-thickness defect: 12×10)	B (with titanium mesh)	Radiotherapy and chemotherapy	None	88	Alive and non-recurrence
3	72	Ductal-invasive carcinoma	T3N0M0	25×20	A	Radiotherapy and chemotherapy	None	68	Alive and non-recurrence
4	56	Metaplastic carcinoma	T2N0M0	26×17	A	Chemotherapy	None	27	Death for metastasis
5	33	Malignant phyllodes tumor	T3N0M0	26×19 (full-thickness defect: 10×10)	A (with titanium mesh)	None	None	60	Alive and non-recurrence

*A: a pedicled latissimus dorsi musculocutaneous flap; B: a pedicled rectus abdominis musculocutaneous flap.

Figures

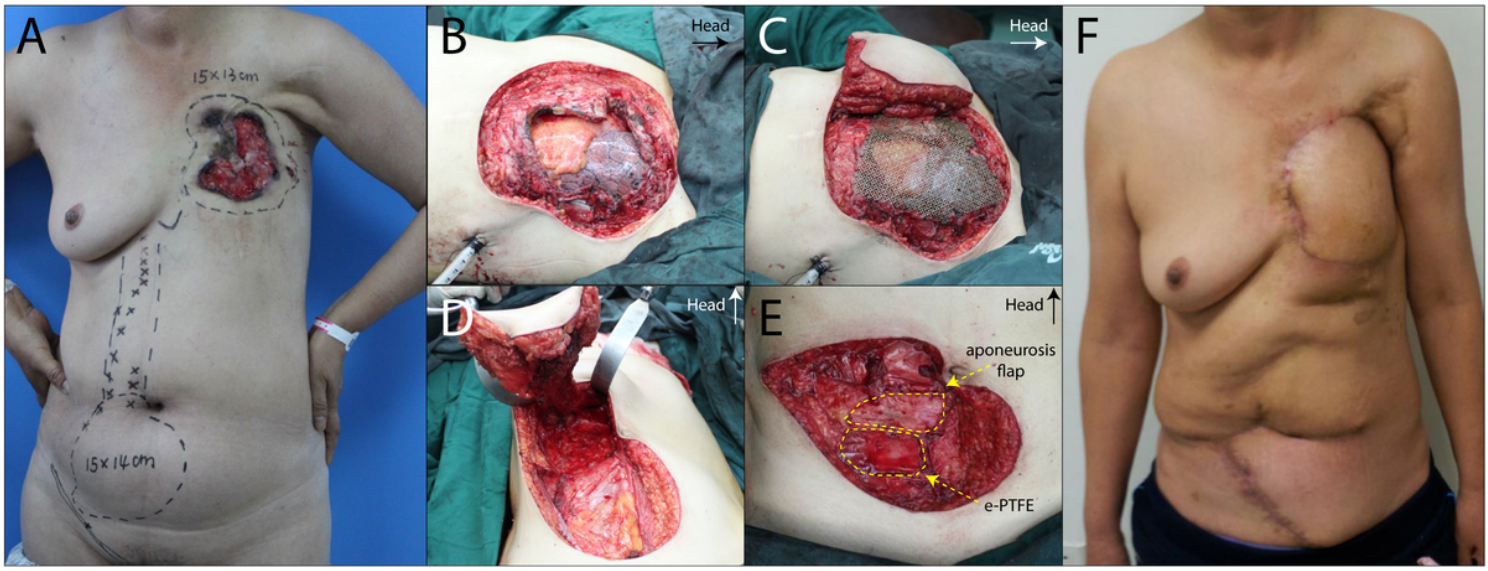

Figure 1

Patient with locally recurrent breast cancer and preoperative design of skin flap (A). A piece of titanium mesh used to stabilize the thoracic cage defect. The heart and lung were all exposed (B). The pedicled rectus abdominis musculocutaneous flap formation to coverage the chest wall defect (C). A pedicled aponeurosis flap of obliquus externus abdominis about 10 cm×5 cm (D) and a piece of e-PTFE about 8 cm×6 cm used to stabilize the abdominal wall and eliminate the abdominal tension (E). Outcome of the patient 3 years after operation (F).