Bilateral Chylothorax Following Left Neck Dissection and Literature Review

Sachiko Kimizuka (kimizuka@med.kitasato-u.ac.jp)
Kitasato University: Kitasato Daigaku https://orcid.org/0000-0002-8306-0361

Hiroyuki Yamada
Iwate Medical University: Iwate Ika Daigaku

Koji Kawaguchi
Tsurumi University: Tsurumi Daigaku Tsurumi Daigaku Tanki Daigakubu

Toshikatsu Horiuchi
Saiseikai Yokohamashi Tobu Hospital: Saiseikai Yokohama-shi Tobu Byoin

Akira Takeda
Kitasato University: Kitasato Daigaku

Yoshiki Hamada
Tsurumi University: Tsurumi Daigaku Tsurumi Daigaku Tanki Daigakubu

---

Case report

Keywords: chylothorax, radical neck dissection, chyle

Posted Date: January 9th, 2021

DOI: https://doi.org/10.21203/rs.3.rs-141175/v1

Abstract

Background: Although chyle leakage may occur in the neck when the thoracic duct is damaged during cervical dissection, it is extremely rare for the chylothorax alone to leak chyle into the thoracic cavity.

Case presentation: We report a case of bilateral chylothorax without chyle cervical leakage after left neck dissection, wherein partial left upper jaw resection and left radical neck dissection were performed in a 46-year-old woman who was diagnosed with left upper gingival cancer. The thoracic duct was ligated and cut during surgery and, although no obvious leakage of lymph was observed, dyspnea and cough reflex during deep inhalation were observed from the 3rd postoperative day. Approximately 600 mL of yellowish-white pleural effusion was aspirated during bilateral thoracentesis, and chylothorax was diagnosed based on clinical findings and biochemical analysis results. The patient was put on a low-fat diet on the 4th postoperative day, and a total of 3 neck drains were removed 8 days after the operation.

Conclusions: Pleural effusion disappeared on imaging examination 16 days after thoracentesis and 5 years and 6 months have passed since the operation. At this time, there has been no evidence of tumor recurrence, metastasis, or pleural effusion.

Background

Chylothorax is an accumulation of chyle, a milky fluid usually of lymphatic origin, in the pleural cavity. Chyle is milky white because it contains finely emulsified fats[1)]. Chylothorax causes cardiovascular abnormality, respiratory insufficiency, undernutrition, electrolyte abnormality, and immunodeficiency due to copious chyle exudation to the thoracic cavity[2)] and prompt management is required in these cases.

Chylothorax is a frequent complication caused by injury to the thoracic duct during thoracotomy[3)]. However, it is a rare complication following neck dissection[4)] and it was first reported by Stuart in 1907[5)]. The incidence of chylothorax with chylous fistula following neck dissection is reportedly 0.2%[6)]. Moreover, only 9 cases of chylothorax without chylous fistula were reported in the literature[7–13)], associated with head and neck cancer. The diagnosis of chylothorax without chylous fistula was relatively difficult because of its rarity and the lack of visible findings such as neck swelling or white fluid in the drain tube in the early postoperative stage.

Herein, we report a rare case of bilateral chylothorax, without chylous fistula, following neck dissection for the treatment of upper gingival cancer, which was resolved with conservative treatment.

Case Presentation

A 46-year-old woman was referred to the Department of Oral and Maxillofacial Surgery at Tsurumi University Dental Hospital in July of 2014 for diagnosis and treatment of swelling in left upper molar region. She reported mobility of the second molar for approximately 2 years. Her past medical and family histories were unremarkable. An extroverted mass with an induration measuring 2.9 cm in diameter was

found in the left maxilla upon physical examination. No neuroparalysis or cervical lymphoadenopathy was seen. The left maxillary second molar was tilted mesially, and resorption of the surrounding bone was remarkable in panoramic radiographs. A helical CT scan was carried out with Radix Prima (Hitachi Medico Co., Ltd., Tokyo, Japan) and an irregular-shaped mass measuring 3.2 × 2.6 cm, with slight contrast effect, was noted in the left maxilla in contrast-enhanced CT imaging. MRI examination was performed with a MRP-7000 0.3 T system (Hitachi Medico Co., Ltd., Tokyo, Japan). The mass appeared as hypointense in the left upper maxilla in MRI T1-weighted coronal images, while it appeared as hyperintense in T2-weighted images. ^{18}F-Fluorodeoxyglucose (FDG) - positron emission tomography was performed with a POSICAM HZL m-power device (POSITRON Co., Houston, TX). Coronal images showed abnormal accumulation of FDG (SUVmax = 6.2) in the left upper molar region; however, no cervical lymph node and distant metastases were observed (Fig. 1). A biopsy of the left upper gingival lesion revealed well-differentiated squamous cell carcinoma (SCC).

Partial maxillary resection was performed under general anesthesia in August of 2014, based on a clinical diagnosis of upper gingival cancer (cT2N0M0). The defect was closed with a buccal fat pad.

Histopathology revealed findings of the resected buccal lesion similar to those of the biopsy specimen, consistent with a diagnosis of well-differentiated SCC. Neither vascular nor neural invasion was observed, and the resection margins were negative for tumor.

The postoperative course was uneventful; however, rapid enlargement of left cervical lymph nodes was observed at 1 month after surgery. Contrast-enhanced CT showed enlarged left cervical lymph nodes with ring enhancement, and a diagnosis of secondary cervical lymph node metastasis was made (Fig. 2). Left radical neck dissection was performed under general anesthesia in October of 2014, and a thick thoracic duct was found in the supraclavicular fossa during surgery. There was no leakage of lymph after ligation and cutting of the thoracic duct (Fig. 3), and the operation was completed following placement of 3 suction drains in the left neck.

The patient was started on a diet the first day after surgery. On the third day postoperative, she complained of respiratory distress in a supine position, and cough reflex was observed during deep inhalation. Chest x-rays and CT showed pleural effusion in both lower lung fields (Fig. 4), and chylothorax was suspected based on the intraoperative and postoperative clinical findings. Approximately 600 mL of yellowish-white pleural fluid was aspirated during bilateral thoracic puncture. Furthermore, no swelling of the neck was observed, and the contents of the neck drain were serous and had a concentration of 15 mg/dL of triglyceride which was within normal range. Therefore, no evidence of chyle leakage was observed in the neck. On the other hand, the triglyceride concentration of the pleural effusion was 705 mg/dL, which was significantly higher than that of the standard value. The patient was diagnosed with bilateral chylothorax without cervical chyle, according to the above results, but pleural effusion subsequently improved and respiratory distress disappeared. A low-fat diet was started on the fourth day after surgery, and all neck drains were removed on the eighth day postoperative. The pleural effusion on the chest radiograph disappeared 16 days after thoracentesis (Fig. 5), and postoperative

chemoradiotherapy was performed since extra-nodal spread was observed in the left cervical lymph nodes (level II and III), determined through histopathology.

The postoperative course was uneventful, and there was no evidence of recurrence at follow-up examination 5 years and 6 months after surgery.

Discussion And Conclusions

Chylous fistula of the neck, which is related to the occurrence of chylothorax[6)], was reported in 2% of cases following neck dissection[14)], and chylothorax with chylous fistula of the neck is reported to be 0.2%[6)]. Moreover, only 9 cases of chylothorax without chylous fistula were reported in the literature[7–13)], associated with head and neck cancer. The primary tumor included 4 cases of thyroid cancer, 2 cases of tongue cancer, 2 cases of laryngeal cancer, 1 case of lower gingival cancer, and 1 case of oral malignant melanoma **(Table 1)**. Furthermore, 2 theories exist regarding the pathogenesis of chylothorax. First, chyle in the neck descends to the mediastinum through the intra-muscular space by compression of the neck. Then, chyle infiltrates to the lateral wall of the pleura, resulting in the accumulation chyle in the thoracic cavity[15)]. Another theory is that ligation of the thoracic duct leads to elevation of its internal pressure causing rupture of the thoracic duct wall[4)]. The normal range of internal pressure for the thoracic duct is reported as 10 to 25 mmHg; however, the internal pressure can rise to 50 mmHg due to duct closure[16)]. Bilaterally affected chylothorax is related to the anatomical pathway of the thoracic duct. The thoracic duct originates at the cisterna chyli in front of L1 and L2 and ascends along with abdominal aorta into the thoracic cavity. At the level of T4, and T5, it turns left and ascends along with esophagus to finally join the left vein angle[17)]. Although lymphangiography or lymph scintigraphy was not performed to avoid complications in this case, the point of thoracic duct rupture was estimated approximately at the level of T4 and T5, or the upper stream where chyle can spread to the bilatelal thoracic cavity.

The nature and color of the pleural fluid is essential for the diagnosis of chylothorax. A milky liquid is a typical finding in chylothorax; however, lymph fluid becomes transparent after fasting. Therefore, biochemical study to the pleural fluid is necessary. Over 110 mg/dL of triglyceride was the diagnostic finding for the chyle[18)], and if the triglyceride concentration was between 50 to 110 mg, the presence of cyromicron in the pleural fluid would be proof that it is chyle[19)]. In the present case, the patient's complaint of respiratory distress while in a supine position prompted us to suspect chylothorax. Moreover, the triglyceride concentration in pleural fluid was 705 mg/dL with intraoperative thoracic duct ligation; therefore, we easily arrived at the diagnosis of chylothorax.

Sella et al. reported that over 1500 mL of chyle, unchanged condition after concervative treatment for 14 days, and deterioration of nutrition by chyle exudation were the criteria for surgical intervention[20)]. On the other hand, Robinson et al.[21)] suggested 500 to 1000 mL of chyle per day for 2 to 3 weeks for adults required surgical treatment. Although standardized criteria do not exist, these conditions support our selection of surgical intervention. Moreover, the American College of Radiology recommends

lymphangiography and thoracic duct embolization as an effective and minimally invasive method for the treatment of chylothorax[22].

Chylothorax is associated with increased mortality due to significant loss of essential proteins, immunoglobulins, fat, vitamins, electrolytes, and water[23]. Bolger et a al.[24] reported that 50% of patients died if their treatment period was over 35 days. Also, the most frequent direct cause of death for chylothorax is infection[25].

In this case, conservative treatment of low-fat diet improved the patient's condition after 16 days of thoracentesis. Early diagnosis with adequate treatment is critically important for chylothorax following neck dissection.

Abbreviations

CT: Computed tomography; MRI: Magnetic resonance imaging

Declarations

Acknowledgments

The authors would like to thank Enago (www.enago) for the English language review.

Authors' contributions

SK and HY wrote the manuscript. SK, HY, and TH were in charge of treatment of this case. HY, KK, AT, and YH helped SK with revision of the manuscript. All authors read and approved the final manuscript.

Funding

Not applicable.

Availability of data and materials

Not applicable.

Ethics approval and consent to participate:

Not applicable.

Consent for publication

Written informed consent for publication of their clinical details and clinical images was obtained from the patient.

Competing interests

The authors declare that they have no competing interests.

Author details

[1] Department of Oral and Maxillofacial Surgery, Tsurumi University, School of Dental Medicine, 2-1-3 Tsurumi, Tsurumi-ku, Yokohama-city, Kanagawa, 2 30-8501 JAPAN. [2] Department of Plastic and Aesthetic Surgery, Kitasato University, School of Medicine, 1-15-1 Kitasato, Minami-ku, Sagamihara-city, Kanagawa, 252-0374 JAPAN. [3] Division of Oral and Maxillofacial Surgery, Department of Reconstructive Oral and Maxillofacial Surgery, School of Dentistry, Iwate Medical University, 19-1 Uchimaru, Morioka, Iwate, 020-8505 JAPAN. [4] Department of Oral and Maxillofacial Surgery, Saiseikai Yokohamashi Tobu Hospital, 3-6-1 Shimosueyoshi, Tsurumi-ku, Yokohama-city, Kanagawa, 230-8765 JAPAN.

References

1. Aliya N. Husain. : The lung, Pleura: Robbins and Cotran Pathologic Basis of Disease Professional Edition, 9e, Vinay Kumar, Abul Abbas K, Jon C. Aster editors, 2015, Elsevia Saunders, Philadelphia, P722-726.
2. Sriram K, Meguid RA, et al. Nutritional support in adults with chyle leaks. Nutrition. 2016;32:281–6.
3. Brown AL. Traumatic rupture of the thoracic duct with bilateral chylothorax and chylous ascites. Arch Surg 34: 120–128, 1937.
4. Hal EG, Segal K, et al. Bilateral chylothorax complicating radical neck dissection-Report of a case without concurrent external chylous leakage-. Head Neck Surg. 1985;7:225–30.
5. Stuart WJ. Operative injuries of the thoracic duct in the neck. Edinburgh Med J. 1907;22:301–6.
6. Abdul JAS, Al-Abdulkareem A. Bilateral chylothorax following neck dissection. Head Neck. 1996;17:69–72.
7. Al-Sebein H, Sadeghi N, et al. Bilateral chylothorax following neck dissection: a new method of treatment. Ann Otol Rhinol Laryngol. 2001;110:381–4.
8. Kamasaki N, Ikeda H, et al. Bilateral chylothorax following radical neck dissection. Int J Maxillo Surg. 2001;32:91–3.
9. Tsukahara K, Kawabata K, et al. Three cases of bilateral chylothorax developing after neck dissection. Auris Nasus Largnx. 2007;34:573–6.
10. Bae JS, Song BJ, et al. Bilateral chylothoraces without chyle leakage after left-sided neck dissection for thyroid cancer: report of two cases. Surg Today. 2007;37:652–5.
11. Han C, Guo L, et al. Bilateral chylothorax following neck dissection for thyroid cancer. Int J Oral Maxillofac Surg. 2009;38:1119–22.
12. Soodin D, Singh P, et al. Bilateral chylothorax following left sided modified radical neck dissection. Ceylon Med J. 2010;55:126–7.

13. Singh R, Krishnan S, et al. Bilateral chylothorax following neck dissection: case report and review of literature. Indian J Surg Oncol. 2016;7:115–8.
14. Spiro JD, Spiro RH, et al. The management of chyle fistula. Laryngoscope. 1990;100:771–4.
15. Frazell EL, Harrold CC, et al. Bilateral chylothorax. Ann Surg. 1950;134:135–7.
16. Fortin D, Inculet RI, et al: The thoracic duct and chylothorax. Pearson's Thoracic and Esophageal Surgery, 3rd Ed, ed by Pearson FG, Patterson GA, Churchill Livingstone, London, 2008.
17. Schulman A. The lymphographic anatomy of chylothorax. Br J Radio. 1978;51:420–7.
18. Hal EG, Lucente FE. Lymphatic drainage system after left radical neck dissection. Ann Otol Rhinol Laryngol. 1994;103:46–8.
19. Staats BA, Ellefson RD, et al. The lipoprotein profile of chylous and nonchylous pleural effusions. Mayo Clin Proc. 1980;55:700–4.
20. Selle JG, Snyder WH, et al. Chylothorax-Indications for surgery-. Ann Surg. 1973;177:245–9.
21. Robinson CLN. The management of chylothorax. Ann Thorac Surg. 1985;39:90–5.
22. Majdalany BS, Murrey DA Jr, Kapoor BS, et al. ACR Appropriateness Criteria: Chylothorax Treatment Planning. J Am Coll Radiol. 2017;14:118-26. 10.1016/j.jacr.2017.02.025.
23. Nair SK, Petko M, Hayward MP. Aetiology and management of chylothorax in adults. Eur J Cardiothorac Surg. 2007;32:362–9. 10.1016/j.ejcts.2007.04.024.
24. Bolger C, Walsh TN, et al. Chylothorax after oesophagectomy. Br J Surg. 1991;78:587–8.
25. Paes ML, Powell H. Chylothorax-an update-. Br J Hosp Med. 1994;51:482–90.

Figures

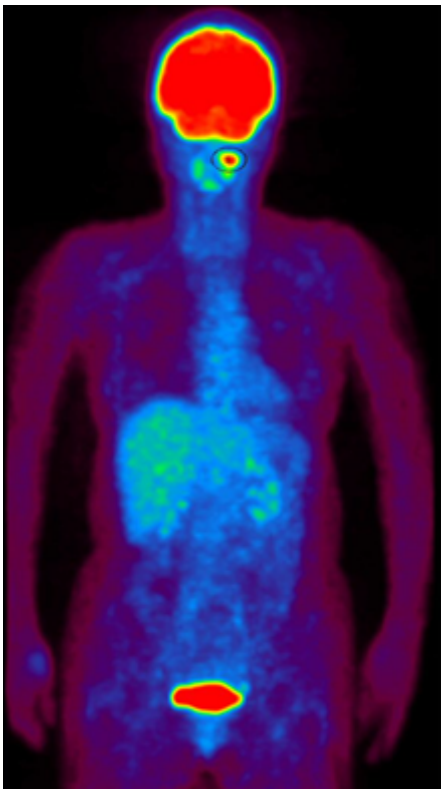

Figure 1

Fluorodeoxyglucose - positron emission tomography showing abnormal accumulation of fluorodeoxyglucose in the left upper molar region. No cervical lymph node or distant metastases is observed.

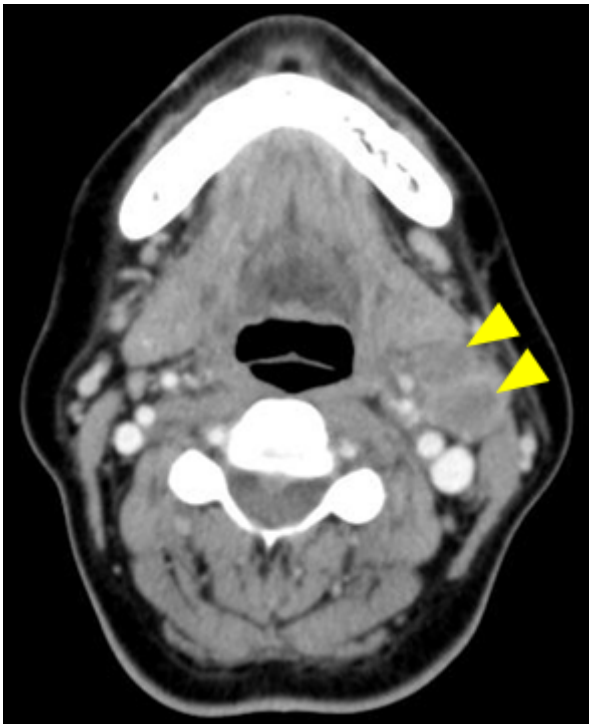

Figure 2

Contrast-enhanced CT is showing enlarged left cervical lymph nodes with ring enhancement (arrowheads).

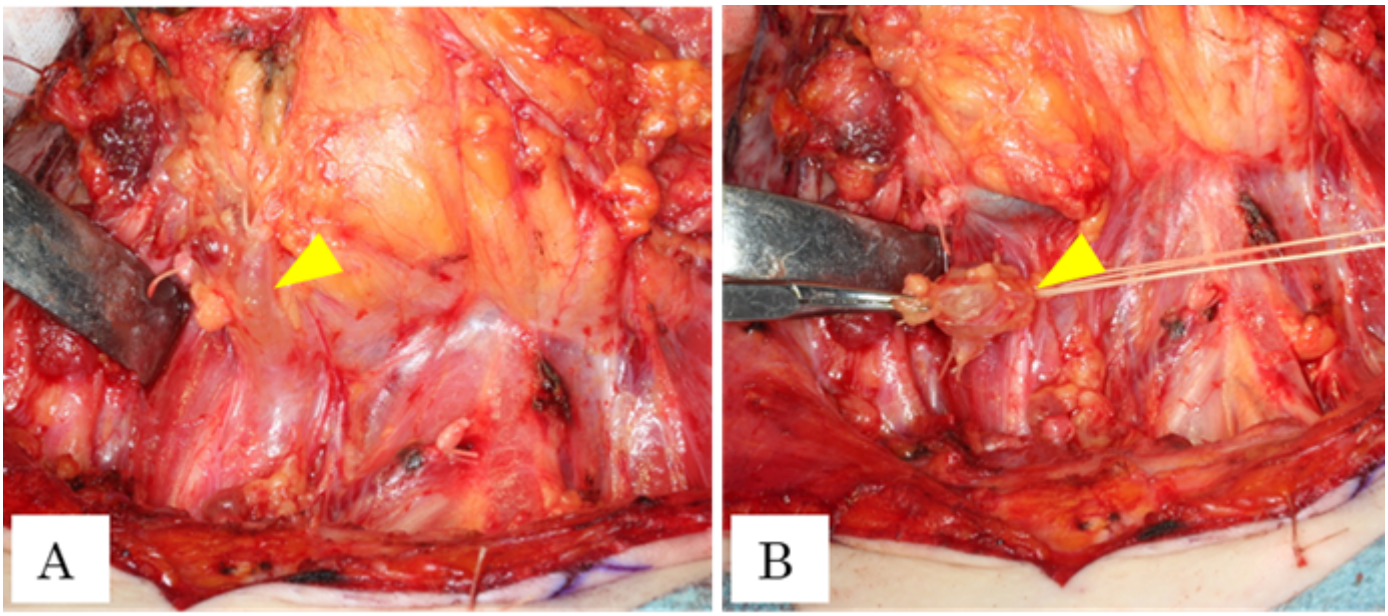

Figure 3

A. Intraoperative photograph is showing dilation of thoracic duct (arrowhead). B. Intraoperative photograph is showing ligation of thoracic duct (arrowhead).

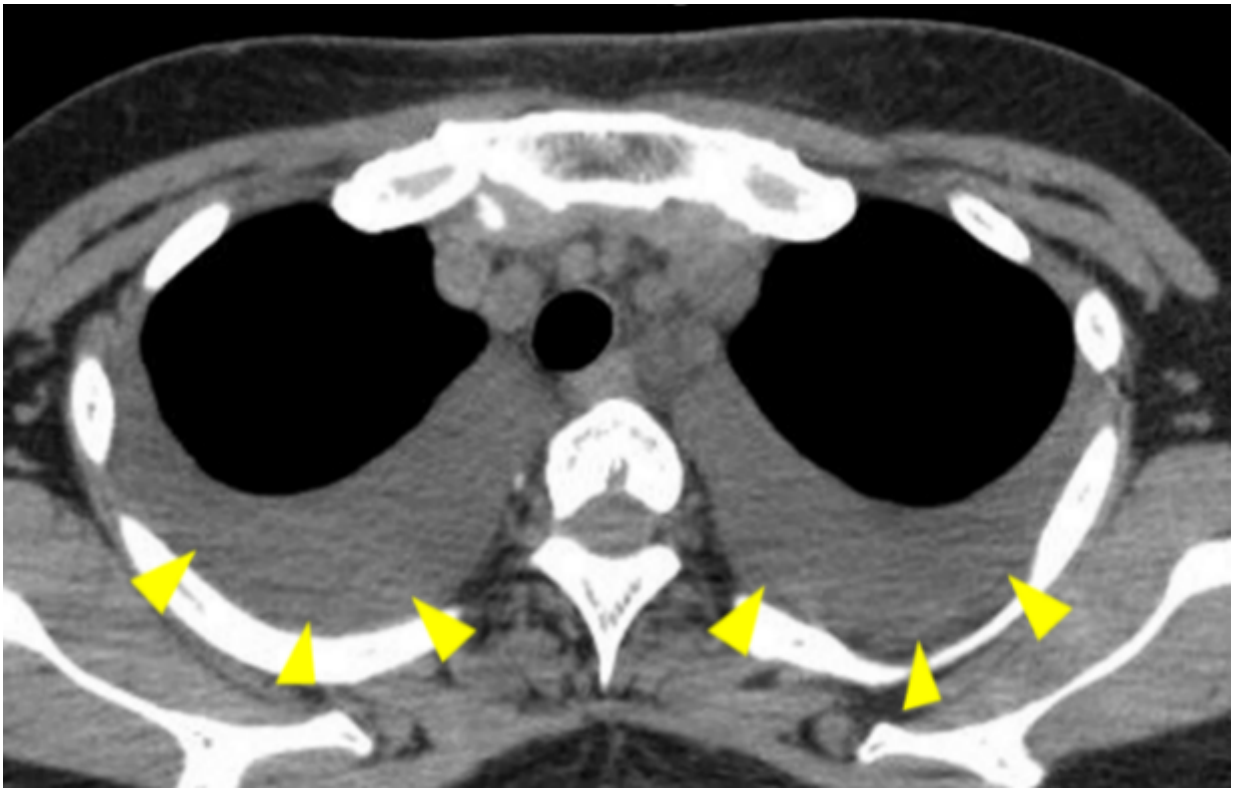

Figure 4

CT showing pleural effusion in both lower lung fields (arrowheads).

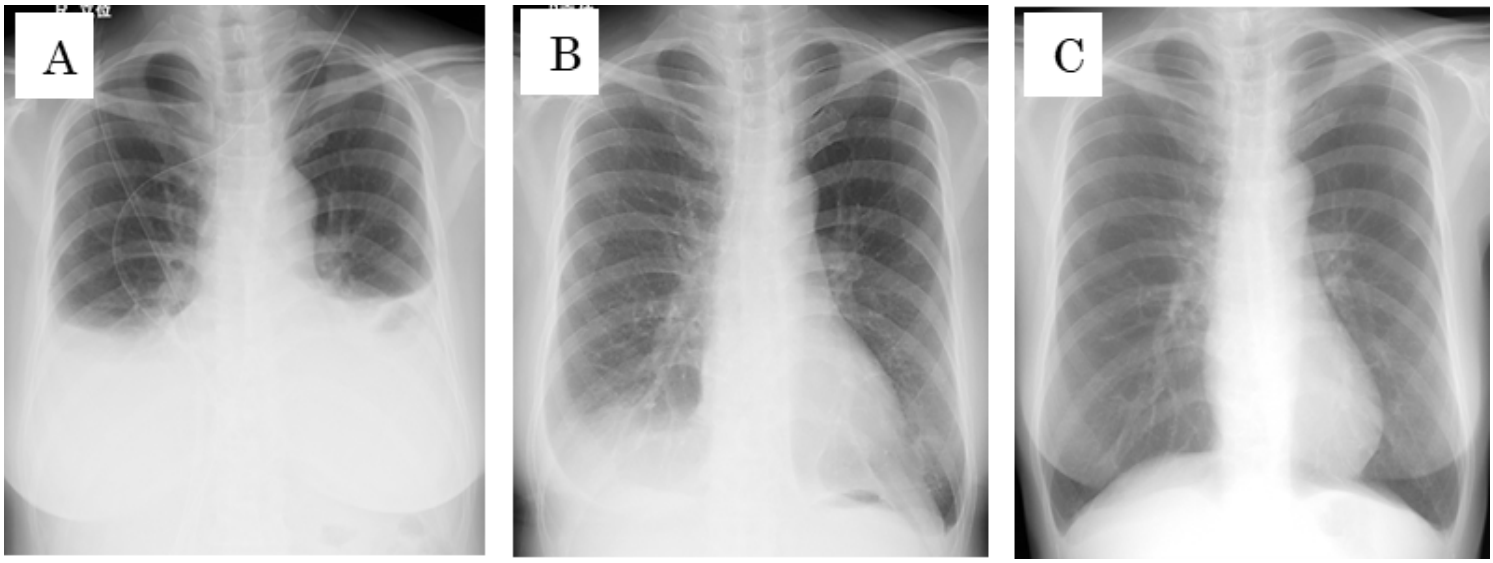

Figure 5

A. Chest x-rays before bilateral thoracic puncture. B. Chest x-ray 7 days after bilateral thoracic puncture. C. Chest x-ray 16 days after bilateral thoracic puncture.