Rim plate in the treatment of hyperextension tibial plateau fracture: surgical technique and a series of cases

Ting Li (liting2000@sina.com)
Beijing Jishuitan Hospital
Zhijian Sun
Beijing Jishuitan Hospital
Yabo Liu
Beijing Jishuitan Hospital
Yujiang Mao
Beijing Jishuitan Hospital
Weihua Li
Beijing Jishuitan Hospital
Qi Guo
Beijing Jishuitan Hospital
Shaoliang Li
Beijing Jishuitan Hospital
Changrun Li
Beijing Jishuitan Hospital

Research Article

Keywords: Tibial plateau fracture, hyperextension, rim plate

Posted Date: March 9th, 2022

DOI: https://doi.org/10.21203/rs.3.rs-1413474/v1

Abstract

Background: “Bare aera” at the anterior plateau was existed with anteromedial and/or anterolateral proximal tibial locking plates fixation in the treatment of hyperextension tibial plateau fractures (HTPF). The aim of this study was to introduce the rim plate fixation technique and evaluate its clinical effect.

Methods: HTPF patients treated with rim plate combined with proximal tibial locking plate in our hospital between April 2015 and December 2019 were retrospectively analyzed. All patients were followed up for a minimum of one year. Open reduction and internal fixation through anteromedial/posteromedial and/or anterolateral approaches was performed for all patients. **Surgical** strategies of rim plate fixation were introduced. And Radiographic and Clinical outcomes were assessed.

Results: A total of 13 patients were enrolled. The average follow-up time was 4.3 years. Satisfactory reduction was achieved and radiographically maintained in all patients. And Satisfactory clinical functions were observed in all patients with a mean HSS knee score of 96.2±2.0 (range: 90-98). No wound complications and implant breakage were observed in this series.

Conclusion: The combined use of rim plate and proximal tibial plate resulted in an effective fixation configuration that led to satisfactory clinical outcomes.

Background

As computed tomography (CT) and magnetic resonance imaging (MRI) are commonly used approaches for preoperative evaluation, several authors have used these approaches to describe the mechanisms of tibial plateau fracture [1, 2]. According to the direction of forces, hyperextension, extension, and flexion types were elaborated in the sagittal plane, varus and valgus in the coronal plane, rotation and transition in the horizontal plane. The hyperextension tibial plateau fracture (HTPF) is characterized by an anterior depression or collapse of the medial and/or lateral plateau, whose fracture involves both condyles is more severe. In their study, Firoozabadi *et al* showed that the incidence of popliteal artery disruption, peroneal nerve injury, and compartment syndrome for hyperextension tibial plateau bicondylar fracture was high compared with other bicondylar plateau fractures [3]. In addition, the clinical outcome of HTPF was also inferior and had worse functional outcomes [4, 5].

For the fixation of the reduced HTPF, anteromedial and/or anterolateral proximal tibial locking plates are usually used. Yet, there is “bare aera” at the anterior plateau between the two plates (Fig. 1). This area is difficult to fix because of the shelter of the patella tendon and the limited space for plate placement. Thus, in our trauma center, we developed the 2.7mm pre-contoured rim plate to buttress the anterior plateau. Rim plate is mainly used to fix posterolateral plateau due to the existence of “bare area” and inferior fixation strength to anti-posterior displacement with standard lateral locking plate [6, 7]. To the best of our knowledge, no previous study reported on its usage for treating HTPF. In this study, we described the surgical strategies of rim plates for the treatment of HTPF and the preliminary results of a case series.

Methods

Patients and preoperative evaluation

Patients with HTPF treated with rim plates between April 2015 and December 2019 were retrospectively analyzed. All the patients were minimally followed up for one year. HTPF was defined by medial and/or lateral decompression of the anterior plateau with decreased posterior slope angle (PSA). Patients with pathological and chronic fractures were excluded. Patients with multiple injuries or with accompanying fractures were also excluded. This study was approved by the ethical committee of Beijing Jishuitan Hospital.

All the patients were temporarily immobilized with casts, braces, or external fixator at the emergency admission. Preoperative radiographs and CT scans were taken for all patients to evaluate the morphological characteristics of the fracture. The definite surgical treatment of open reduction and internal fixation was carried out when the soft tissue condition permitted, i.e., when blister faded and swelling improved, which was evaluated by the surgeon.

Surgical technique

For patients whose fractures only involved the medial or lateral plateau, a single anteromedial or anterolateral approach was used. Also, for patients with bicondylar fracture, anteromedial/posteromedial and anterolateral approaches were most commonly used. A posterior tension fracture was usually found in patients with bicondylar HTPF, for whom the posteromedial incision was firstly made to expose and reduce the posterior fracture, after which it was fixed with a 1/3 tubular plate or anatomical plate with a short proximal screw to allow minimal transition when elevating the anterior decompression, thus providing a hinge point. Next, reduction of the anterior depressed articular surface to restore the sagittal and coronal alignments was performed mainly following the approach described by Firoozabadi *et al* [3]. Simply, an osteotome or spreader was inserted to the impaction area of the anterior metaphysis and was elevated until the PSA was restored. Reductions by multiple Kirschner wires or plates described were also found to be effective methods. For HTPF patients whose fractures only involved medial or lateral plateau, the reduction was performed in the same way. Once satisficed reduction was achieved and verified by intraoperative fluoroscopy, provisional stabilization was performed using Kirschner wires. Structural artificial bone augments (MIIG^{TM} X3 or PRO-DENSE^{TM} Injectable, Wright Medical Technology, Inc., Memphis, USA) were used if the anterior defect was >1 cm.

For the fixation of the anterior reduced plateau, the anteromedial and/or anterolateral locking plates (Synthes GMBH, Oberdorf, Switzerland) were first used. In addition, to further buttress the “bare area” behind and close to the patella tendon, a 2.7mm plate (Synthes GMBH, Oberdorf, Switzerland) was pre-contoured to adapt to the curve of the anterior plateau, after which it was inserted behind the patella tendon above the locking plate. Finally, screws of convenient length were inserted at one/each side of the patella tendon parallel to the articular surface. At least 1 long screw was placed to the posterior fragment or the uncomminuted medial/lateral fragment to prevent secondary loss of reduction (Figure 2, 3).

Postoperative management

Postoperative radiographs and CT scans were obtained. Also, passive and active rehabilitation, including a full range of motion (ROM), was arranged early after surgery. Usually, non-weight bearing lasted for 4 to 6 weeks and was followed by partial-weight bearing. Full-weight bearing was only allowed when bone healing was verified by radiographs. The medial tibial plateau angle (mTPA) and PSA were measured on standard radiographs at immediate post-operation and the last follow-up by two authors (Zhijian Sun and Changrun Li) . Major complications were recorded, and clinical outcomes were assessed by the hospital for special surgery (HSS) knee score at the last follow up.

Results

A total of 14 HTPF patients received surgical treatment with rim plates. As 1 patient was lost to follow-up, 13 patients were finally analyzed. The average follow-up period was 4.3 ± 1.5 (range: 1.9–6.5) years. The demographic data are shown in Table 1. There were 6 males and 7 females with an average age of 45.1 ± 16.6 (range: 23–76) years. Bicondylar was involved in 9 patients, medial condylar in 3 patients, and lateral condylar in 1 patient. Schatzker's classification and OTA classification was illustrated in Table 1. All patients received open reduction and rim plate combined with proximal tibial locking plate fixation. The average operation time was 101.2 ± 22.2 (range: 60–150) minutes, and the average intraoperative blood loss was 105.4 ± 69.8 (range: 20–250) mL.

Table 1
The demographic, surgical, and clinical data of patients

Number	Gender	Age (year)	Fracture type	Schatzker classification	OTA classification	Surgical time (minutes)	Intraoperative blood loss	Range of motion	HSS knee score
1	male	39	bicondylar	[illegible]	41-C3	120	100	0-130	98
2	female	23	Lateral condylar	[illegible]	41-B1	105	100	0-130	98
3	male	58	bicondylar	[illegible]	41-C3	120	250	0-120	97
4	female	34	bicondylar	[illegible]	41-C3	150	100	0-130	98
5	male	42	Medial condylar	[illegible]	41-B3	90	20	0-125	92
6	female	55	Medial condylar	[illegible]	41-B3	60	50	0-130	98
7	male	76	bicondylar	[illegible]	41-C3	100	200	0-130	98
8	female	27	Lateral condylar	[illegible]	41-B3	90	50	0-130	98
9	female	32	bicondylar	[illegible]	41-C3	90	200	5-120	96
10	female	25	bicondylar	[illegible]	41-C3	90	50	0-130	91
11	male	61	bicondylar	[illegible]	41-C3	90	100	0-100	90
12	Female	55	bicondylar	[illegible]	41-C3	120	100	0-130	98
13	male	59	Medial condylar	[illegible]	41-B3	90	50	0-130	98

OTA, Orthopaedic Trauma Association; HSS, hospital for special surgery

The satisfactory reduction was achieved and radiographically maintained in all patients. mTPA was 86.7°±1.9° (range: 83.9e:90.7e) immediately after surgery and 86.1°±2.7° (range: 82.7°-90.9°) at the last follow-up. The medial PSA and lateral PSA were 11.8°±4.1°±(range: 4.3°-19.3°) and 12.0°±4.1°(range: 3.0°-16°) immediately after surgery respectively and changed to 6.8° ±4.8° (range: -2.1°-14.6°) and 8.5°±6.4° (range: -2.9°-19.4°) at the last follow up. There was mild secondary loss of reduction without causing malalignment or articular depression. Satisfied clinical outcome was observed at the last follow up with a mean HSS knee score of 96.2 ± 2.0 (range: 90–98).

There was 1 patient with preoperative nervus peroneus communis injury (patient no. 11). Also, a nerve graft was carried out by a microsurgeon one year later. Ankle dorsiflexion did not significantly improve at the last follow up. However, the patient could walk without assistance. No wound complication and implant breakage were observed in this cohort of patients.

Discussion

HTPF is a severe type of tibial plateau fracture that has been more commonly associated with injuries and inferior functional recovery compared to non-hyperextension types [3–5]. In clinical practice, buttressing “bare area” is observed with the only use of proximal tibial locking plates, which was found to be more likely to cause secondary loss of reduction (Fig. 1) [6]. Herein, we reported a new method, i.e., the rim plate for supporting the “bare area”, and verified the outcomes in a small case series.

The use of rim plate is not uncommon in the treatment of tibial plateau fracture, considering its sufficient buttressing strength and relatively small space it occupies. Pires *et al* [8] reported 9 patients with posterolateral fractures through transfibular approach. Rim plate was used to buttress the articular surface with 2.7mm horizontal rafting plate, and 1 patient presented loss of reduction requiring revision surgery. In their study, Cho *et al* [9, 10] reported the rim plating of posterolateral fracture through a modified anterolateral approach to provide adequate purchase. Moroever, *Zhu et al* [11] reported a new modified Frosch approach to fix the posterolateral fracture with “Barrel hoop plate”, which was also a variant type of rim plate. Kumar and colleagues [12] reported on a case of a patient with posteromedial tibial condyle fracture treated with rim plate. Giordano *et al* [13] introduced a new surgical technique for treating posterior bicondylar shear fracture with the “Hoop” plate. Rim plate osteosynthesis was also reported as minimally invasive under arthroscopic assistance [14].

For the HTPF, the range of articular decompression usually exceeds half of the whole plateau. Also, anterior marginal fragment or decompression of more than half of proximal tibial circumference could be involved, including the area behind the patella tendon. The proximal tibial plate cannot achieve support for all of this area. To prevent knee stiffness, early ROM of the knee was advocated. Under these circumstances, sufficient fixation is mandatory to prevent secondary loss of reduction. The combined use of a pre-contoured rim plate was a reasonable option to provide extra subchondral support. In our series, mild secondary reduction loss was observed, yet to an acceptable extent. Further studies are needed to further verify the biomechanical advantages of the presented approach.

One potential issue related to this new surgical strategy is the plate irritation of the patella tendon; however, the infrapatellar fat pad might provide buffering. Also, no patient complained of pain in the anterior region of the knee. Another concern was the biomechanical support strength of the rim plate considering that comminuted fragments were usually existed at the anterior plateau. Our strategy was to inserted at least 1 long screw on the rim plate to the relatively intact posterior/medial/lateral fragment.

There were several limitations in the present study. Firstly, no control group was included in this case series; thus, it was impossible to compare the advantages of rim plate in treating HTPF. In addition, preoperative MRI was not routinely performed, so the accompanying meniscus and ligament injuries were not evaluated. Finally, a CT scan was not taken regularly during the follow-up period, and subtle secondary loss of reduction might be ignored in the radiographs.

Conclusion

A new fixation method for treating HTPF, i.e., the rim plate combined with proximal tibial locking plates, provided adequate support strength to the “bare area”. The case series presented satisfactory clinical outcomes without major complications and obvious secondary reduction loss during a mean follow-up period of 4.3 years.

Abbreviations

HTPF: Hyperextension tibial plateau fractures; CT: Computed tomography; MRI: Magnetic resonance imaging; PSA: Posterior slope angle; ROM: Range of motion; mTPA: medial tibial plateau angle; HSS: Hospital for special surgery

Declarations

Ethics approval and consent to participate

This study was approved by the ethical committee of Beijing Jishuitan Hospital.

Consent for publication

All patients gave written informed consent to involvement in this study, including consent to use data from medical records and radiographs

Availability of data and materials

The data and materials could be acquired by contacting the corresponding author with e-mail.

Competing interests

None of the author of this paper has a financial or personal relationship with other people or organization that could inappropriately influence or bias the content of the paper.

Funding

None.

Authors' contributions

Sun Z wrote the manuscript. Sun Z and Li C did the measurements. Li T introduced the surgical strategy and Liu Y, Mao Y, Li W and Guo Q helped to modify the procedure. Sun Z and Li S collected the data. All authors reviewed the manuscript.

Acknowledgements

Not applicable.

References

1. Hua K, Jiang X, Zha Y, Chen C, Zhang B, Mao Y. Retrospective analysis of 514 cases of tibial plateau fractures based on morphology and injury mechanism. J Orthop Surg Res. 2019; 14: 267.
2. Xie X, Zhan Y, Wang Y, Lucas JE, Zhang Y, Luo C. Comparative Analysis of Mechanism-Associated 3-Dimensional Tibial Plateau Fracture Patterns. J Bone Jiont Surg Am. 2020; 102:410-418.
3. Firoozabadi R, Schneidkraut J, Beingessner D, Dunbar R, Barei D. Hyperextension Varus Bicondylar Tibial Plateau Fracture Pattern: Diagnosis and Treatment Strategies. J Orthop Trauma, 2016. 30:152-157.
4. Gonzalez LJ, Lott A, Konda S, Egol KA. The Hyperextension Tibial Plateau Fracture Pattern: A Predictor of Poor Outcome. J Orthop Trauma. 2017; 31:369-374.
5. Wu K, Huang J, Lin J, Wang Q. Diagnosis and Treatment of Anterior Tibial Plateau Fracture-Dislocation: A Case Series and Literature Review. J Knee Surg. 2017; 30:114-120.
6. Kim Y, Yoon YC, Cho JW, Cho WT, Jeon NH, Oh CW, et al. Rim Plate Augmentation of the Posterolateral Bare Area of the Tibial Plateau Using a 3.5-mm Precontoured Locking Compression Plate: A Cadaveric Study. J Orthop Trauma, 2018. 32:157-160.
7. Zhang BB, Hu H, Zhan S, Mei J, Zhu Y, Luo CF. Biomechanical analysis of "Barrel hoop plate" technique for the posterolateral fragments of tibial plateau fractures with different displacement tendency. Injury. 2020; 51:2465-2473.
8. Pires R, Giordano V, Wajnsztejn A, Oliveira SEJ, Pesantez R, Lee MA, et al. Complications and outcomes of the transfibular approach for posterolateral fractures of the tibial plateau. Injury. 2016; 47:2320-2325.
9. Cho JW, Samal P, Jeon YS, Oh CW, Oh JK. Rim Plating of Posterolateral Fracture Fragments (PLFs) Through a Modified Anterolateral Approach in Tibial Plateau Fractures. J Orthop Trauma. 2016; 30:362-368.
10. Cho JW, Kim J, Cho WT, Kim JK, Samal P, Gujjar PH, et al. Approaches and fixation of the posterolateral fracture fragment in tibial plateau fractures: a review with an emphasis on rim plating via modified anterolateral approach. Int Orthop. 2017; 41:1887-1897.
11. Zhu Y, Sun H, Zhang B, Tang J, Shi H, Mei J, et al. A new strategy to fix posterolateral depression in tibial plateau fractures: Introduction of a new modified Frosch approach and a "Barrel hoop plate" technique. Injury. 2020; 51:723-734.
12. Kumar P, Agarwal S, Kumar D, Rajnish RK, Jindal K. Rim plating for a rare variant of posteromedial tibial condyle fracture; partial coronal split, akin to Hoffa's fracture, associated with multi-ligament injuries and central depression. Trauma Case

Rep. 2019; 20:1-8.
13. Giordano V, Schatzker J, Kfuri M. The "Hoop" Plate for Posterior Bicondylar Shear Tibial Plateau Fractures: Description of a New Surgical Technique. J Knee Surg. 2017; 30:509-513.
14. Delcogliano M, Marin R, Deabate L, Previtali D, Filardo G, Surace MF, et al. Arthroscopically assisted and three-dimensionally modeled minimally invasive rim plate osteosynthesis via modified anterolateral approach for posterolateral tibial plateau fractures. Knee. 2020; 27:1093-1100.

Figures

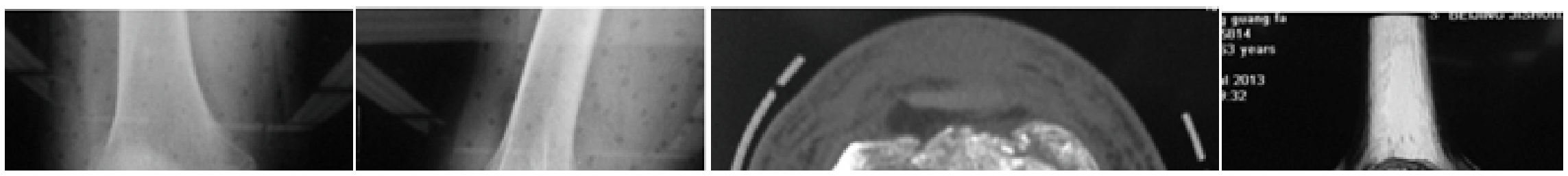

Figure 1

A 63-year-old male patient with bicondylar HTPF **(A-D)**. Open reduction and anteromedial and anterolateral locking plates fixation was performed **(E, F)**. Postoperative CT **(G, H)** showed the buttress “bare area” behind the patella tendon (grey circles).



Figure 2

A 39-year-old male patient with bicondylar HTPF **(A-D)**. Rim plate combined with proximal tibial locking plates was used **(E-H)**. The rim plate was inserted behind the patella tendon; screws of the rim plate were placed through lifting both side of the patella tendon **(E, F)**. Postoperative CT showed that sufficient support of the anterior plateau was provided **(I, J)**.

Figure 3

A 23-year-old female patient with lateral HTPF **(A-E)**. Open reduction and fixation with rim plate combined with anterolateral locking plate were performed **(F-I)**. Screws of the rim plate were placed by lifting both sides of the patella (F, G). Postoperative CT showed that sufficient support of the anterior plateau was provided (J, K).