Management and Outcome of Patients With Femoral Head Fractures: Injuries and Associated Prognostic Factors

Sujan Shakya (hanssujan7@126.com)
West China School of Medicine: Sichuan University West China Hospital
Jialei Chen
West China School of Medicine: Sichuan University West China Hospital
JiaChen Sun
West China School of Medicine: Sichuan University West China Hospital
Zhou Xiang
West China School of Medicine: Sichuan University West China Hospital

Research article

Keywords: Femoral head fractures, Fracture management and surgical methods, surgical approach and fixation method

Posted Date: January 11th, 2021

DOI: https://doi.org/10.21203/rs.3.rs-141488/v1

Abstract

Objective: Femoral head fractures are rare injuries that are often associated with poor functional outcome and complications. Fracture management and surgical methods for these fractures are variable. The purpose of this study was to evaluate the incidence, treatment methods and approaches, complications and functional outcomes of femoral head fractures.

Methods: We conducted a retrospective review of fifty patients who sustained femoral head fractures from January 2011- December 2018. There were thirty-seven males and thirteen females with median age of 40 years. A surgical approach and fixation method were recorded. Patients were classified according to the Pipkin Classification system. Clinical results were evaluated for patients with two years or greater follow-up using the Modified Harris Hip Score (MHHS).

Results: Eight patients (16%) were managed successfully with closed reduction without surgery and thirty-seven (74%) patients required operative reduction and internal fixation (ORIF) of the femoral head and acetabulum, 5 (10%) patients required immediate Total Hip Replacement (THR). Six (12%) developed AVN, four (8%) requiring secondary total hip replacement (THR). Sixteen patients (33%) developed PTA, eight (16%) developed HO and six patients (12 %) had sciatic nerve injury, none requiring operative treatment. Overall functional results, according to modified Harris hip score were excellent in two (4%) patients, good in sixteen (32%) patients, fair in twenty-two (44%) patients, and poor in ten (20%) patients. A statistically significant difference in outcome was observed among four pipkin subtypes.

Conclusion: Femoral head fracture are a rare injury that are often associated with poor outcome. In this study we report the functional outcomes and complications of all treatment approaches for femoral head fracture based on Pipkin classification. This study, adds to the growing literature on femoral head fractures and provide reference for the clinical treatment to guide patient management.

Introduction

Femoral head fractures are rare but severe injury. These fractures are often the result of high energy trauma to the hip and lower extremity, and are commonly associated with posterior hip dislocation[1]. The Pipkin classification system is most widely used to evaluate these fractures [2-4]. Pipkin categorized these injuries based on the location of head fracture in relation to the fovea (Ligamentum Teres) and associated lesion on the femoral neck or acetabulum[5]. Standard treatment strategies for the management of these injuries range from non-operative treatment to fracture fragment excision or fracture fixation using various surgical approaches and implants [6]. However, the optimal management strategy of femoral head remains controversial. However, the optimal management strategy of the femoral head fracture remains controversial. Closed non-surgical treatment can be the approached for Pipkin type I and II fracture, however there is discussion as to whether the treatment should be operative or non-operative[7]. There is still no consensus on the management of injuries, whether to treat these

fractures operatively or non-operatively, whether to fix or excise the head fragment, or which surgical approach to use[3,8-10].

Total hip arthroplasty (THA) is an option that is often recommended in lesion involving femoral head fracture in elderly patients. Regardless of the type of treatment, long-term complications, such as avascular necrosis (AVN), post-traumatic arthritis (PTA), sciatic nerve palsy, and heterotopic ossification (HO), can lead to unfavorable and potentially disabling patient outcome [1,11-13].

Early recognition and prompt treatment are important for successful management of patient with femoral head fracture and dislocation of hip[11]. However, due to the lack of absolute recommendation and indication for fracture management, the outcome of patients with femoral head fractures remains poor. Few studies have reported on the outcome and management of femoral head fractures, however, there are limitations, due to inconsistent fracture classification scheme with prognostic significance, multiple treatment approaches, small patient size, insufficient length of follow-up, and the use of non-validated outcome instruments.

The aim of this retrospective cohort study was to investigate the clinical data of patients who have been non-surgically or surgically treated for femoral head fractures. The postoperative evaluation, complication and functional outcome were further analyzed using modified Harris Hip Score to provide a reference for the clinical treatment.

Methods

Study design, ethics, and patients

This study was approved by the Ethics committee of West China Hospital, Sichuan University and all patients provided a signed consent form. This study is registered under the Chinese Clinical Trial Registry (ChiCTR1900027119). The medical records and radiographs of sixty-one patients who sustained femoral head fractures treated in the Department of Orthopedic at West China Hospital between January 2011-December 2018, were reviewed in this study. Inclusion criteria included: (i) the acute traumatic femoral head fracture with at least an available plain anteroposterior (AP) radiograph of the affected hip; (ii) age 16-65; and (iii) patients' follow-up of two years or greater after the femoral head injury operatively or non-operatively. Patients were excluded if they presented with pathological or non-acute fractures and dislocation of the femoral head had an incomplete radiographic evaluation, or unavailable clinical documentation (initial history, physical examinations, operative notes, post-operative x-rays, and without any follow up were excluded). In addition, one patient who had undergone both ORIF and THR was excluded. The preoperative and postoperative data were electronically stored in the database of Department of Orthopedics in West China Hospital. The data collected from each patient included: demographics, fracture type, presence of associated injury, Injury Severity Score (ISS), mechanism of injury, operation time, intensive care unit care, operation time, intraoperative blood loss, clinical outcomes, and mortality. The presence of associated injuries was determined by reviewing the admission notes,

physical examinations, and radiographic images of each individual. Patients were classified according to the Pipkin classification system[5,14,15].

A total of 50 patients met our eligibility criteria. There were 37 men and 13 women with the median age at the time of injury of 40 years (range 16-65). Thirty-one patients sustained their facture from a motor-vehicle accident, fourteen from a fall, two from sports, two from a bike and one from a workplace related accident. There were eighteen Pipkin I fracture, ten Pipkin II, eight Pipkin IIII, and fourteen Pipkin IV fractures according to Pipkin classification. Patient's classification based on demographic, Pipkin types, and mechanism of injury are listed in Table 1.

Treatment and Management

Treatment approach and timing for recovery to each patient were dependent based on the fracture pattern and associated injuries. The need for operative intervention was determined based on the general guidelines: hip instability, large intraarticular fragments greater than 2mm, bone, or cartilaginous fragment in the joint space[12,16]. In cases of open reduction and internal fixation, the anterior Smith-Peterson (S-P) approach and posterior Kocher-Langenbeck (K-L) approach were used depending on the type and location of the fractured fragments. The choice of fixator was made based on the site and location of the fracture, and the surgeon's preferences. We used reconstruction plates and interfragmentary Herbert screws to obtain stable anatomical fixation in acetabulum and femoral head respectively. For patients undergoing operative intervention, operation time, intraoperative blood loss, surgical approach and type of fixation were all recorded. In our cohort, reduction was performed within six hours of fracture dislocation. If the patients underwent non-operative management, skeletal traction was continued for at least 6 weeks.

Postoperatively, patients were encouraged to preform isometric exercise for quadriceps and lower limb muscles. Simultaneously, the patients with THR was asked for early mobilization postoperatively. Radiographic examination was carried out once a month during the first 3 months to evaluate the efficacy of reduction and presence of acute complications in bone remodeling.

Evaluation of clinical outcome

Patient outcomes and complications were determined based on a review of the clinical and radiographic results from their most recent follow-up. The median follow-up period was 36 months (range 24-84 months). The Brooker classification was used to evaluate HO formation. Patients with HO did not receive any prophylactic radiation or NSAIDs other than analgesic medication for acute pain management. Functional outcomes were graded according to the modified Harris Hip Score (mHHS). The threshold for classification of outcome using the mHHS was as follows: <70 (poor result), 70-79 (fair result), 80-89 (good result) and >90 (excellent result). The mHHS is a surgeon derived outcome measure which contains eight items representing main aspects of pain and function gait, and functional activities [17-19]. The presence of post-traumatic arthritis, osteonecrosis of head, and heterotopic ossification changes was assessed with functional score and radiological changes by experienced orthopedic surgeons. Other

complications such as post-operative infection, deep venous thrombosis (DVT), and sciatic nerve injury were also documented. Post-operative infections were categorized into two groups: superficial infection and deep surgical site infection. Sciatic nerve injury and its peroneal division was diagnosed during physical examination. X-ray (AP, Judet, Lateral view) and computerized tomography (CT) scan was used to assess the radiographic changes before treatment and during each follow-up visit. Functional recovery was evaluated according to the modified Harris Hip score's criteria at the latest clinical follow-up.

Statistical Analysis

Statistical analysis was performed with GraphPad Prism 8.0 software (GraphPad software, Inc., CA, USA). Data are presented as means±standard error of the mean (SEM). The sample size for each variable is included in the figure legends. *P*-values were calculated using one-way ANOVA (analysis of variance). *P*-value of <0.05 was considered to be significant.

Results

Patients and Injury Characteristics (Demographics)

Sixty -one patients were assessed for eligibility in this study as shown in the CONSORT diagram (Figure 1). In total, 50 patients with femoral head fractures met eligibility criteria and were included for this study. Car accident was the most common injury mechanism (31/50), followed by fall injury (14/50). Patients were stratified by ISS ranking into four groups as (a) mild (ISS, 9), (b) mild-to-moderate (ISS, 10-15), (c) moderate-to-severe (ISS, 16-25) and (d) severe (ISS>26). There were 20 mild, 11 mild-to-moderate, 17 moderate-to-severe and 2 severe ISS patients. There were 20 patients with orthopedic case of femoral head fracture, and 30 patients with orthopedic case associated with polytrauma. Patient demographics, classification and associated injuries are listed in Table 1.

Management

Of 50 patients, thirty-seven (74%) patients were managed with open reduction and internal fixation (ORIF) of femoral head and acetabulum, five (10%) patients underwent immediate total hip replacement (THR), and eight (16%) patients were treated non-operatively (Table 2). The anterior (Smith - Peterson) approach was used in 18 patients while the posterior lateral (Kocher-Langenbeck) approach was used in 19 patients. The posterior K-L approach was used for immediate or secondary THR. Three patients were treated with lateral stab approach and two patients were treated using combined anterior and lateral stab approach. Lateral stab approach uses cannulated screws that are percutaneously inserted into femoral neck through stab incision. means percutaneous fixation of the femoral neck through stab incision using cannulated screws. Three patients who underwent ORIF using lateral approach and 2 patients who underwent ORIF using posterior approach developed AVN accompanied with posttraumatic arthritis and required eventful conversion to a secondary THR. Patients treated nonoperatively were believed to be too fragile for surgery due to severity of their associated injury and medical combabilities or were deemed to have stable fracture pattern, and therefore treated with traction.

We next examined different treatment variables, such as non-operative, ORIF, immediate THR and combined ORIF/THR, in relation to each Pipkin subtypes (Figure 2a). The overall treatment in relation to Pipkin classification is given in Table 3. Out of 50 patients, non-operative intervention was mainly rendered to patients with Pipkin Type I (28%) fractures, while ORIF was performed mostly for Pipkin type II (80%) and type IV (79%) fractures. Of note, majority (60%) of patients who had immediate total hip replacement (THR) was within Pipkin type III subgroup. Two patients with Pipkin III fractures and one patient with Pipkin IV fracture, who were treated operatively using ORIF, required an eventful conversion to secondary THR. In addition, one patient with pipkin II fracture who was treated non-operatively required secondary conversion to THR. The association between operative approaches in relation to Pipkin subtypes were also

examined. Anterior approach was mainly used for patients with Pipkin I and Pipkin II fractures

(Figure 3 and Figure 4), while majority of patients with Pipkin III and IV fractures were treated using posterior approach. Combined anterior and lateral stab approach were used in Pipkin III fractures (Figure 5). Lateral stab approach was rendered in three patients with Pipkin III fractures.

Complications

The overall incidence of mid-term complications (median follow-up 36 months) were evaluated. Six patients developed AVN for an overall incidence of 12%. Four (8%) of these patients required eventful conversion to a secondary THR. Sixteen patients (32%) had radiographic criteria of PTA at their latest clinical follow-up. Two patients (4%) had iatrogenic sciatic nerve injury. There was one patient who was diagnosed with post-operative superficial infection and one with DVT in lower limb. Both of these patients were improved by receiving medication and without surgical management. Eight patients (16%) developed Heterotopic ossification. This was graded as Brooker I in all eight patients. None of these patients required an operative intervention.

We next examined the relationship between preferred surgical approaches and complications encountered, mainly AVN, PTA, sciatic nerve palsy and HO (Table 4). Odds ratio analysis revealed that the incidence of HO (all Brooker I) was 1.7 times higher after posterior approach compared to anterior surgical approach (Figure 2b). However, this difference was not statistically significant. There was no incidence of HO when a lateral approach was used. Similarly, post-traumatic arthritis incidence was estimated confirmed when a lateral approach was used than a posterior or an anterior approach, while 1.6 times higher after a posterior approach in comparison to the anterior. Although, this difference did not reach the statistical significance. Out of 19 patients, two patients who were treated using posterior approach developed AVN. Interestingly, all the patients who underwent lateral approach developed AVN, while there was no incidence of AVN when an anterior approach was used. Similarly, none of the patients treated using combined anterior and lateral approach suffered major late complications.

Functional outcome

Clinical and radiographic data were reviewed for all patients at their latest clinical follow-up were grated according to Modified Harris Hip Score (MHHS). The overall clinical results, according to the modified Harris Hip Score criteria were excellent in 2 (4%) patients, good in 16 (32%), fair in 22 (44%), and poor in 10 (20%) patients. Four patients with poor outcome developed AVN and PTA, and underwent eventful conversion to secondary THR. Overall treatment, complications and outcome are given in Table 2.

We next investigated the relations between results (modified Harris hip score) and Pipkin Classification (Table 3). Based on Pipkin classification, the overall outcome interpretation was further subdivided. Majority of patient within Pipkin I fractures showed excellent functional outcome, while the outcome of patients with Pipkin III and Pipkin IV fractures was relatively poor compared to Pipkin I and Pipkin II. Statistical analysis revealed a significant (p=0.0024) difference in outcome among pipkin subtypes, indicating a predictive value of Pipkin classification in femoral head fractures (Figure 2c). However, this might also be due to the potential confounding effect of different treatment strategies. We further examined the relation between outcome, according to Harris Hip score, and each treatment variables (non-operative, ORIF, Immediate THR) (Table 5). For the non-operative group, the results were good in 5(62.5%), fair in 2(25%) and poor in 1(12.5% patients). Among the surgically treated patients, the outcomes were excellent in 2(4.7%), good in 11(26.1%), fair in 20 (35.7%) and poor in 10(21.4%) of patients. The outcome of 5 (100%) patients who underwent primary intention THR was fair. Because of the small number of patients in our cohort, we were unable to examine the influence of confounding effect of treatment strategy on functional outcome. Furthermore, the relation between functional outcome and the operative approaches were also examined. The outcome of patients treated using anterior approach was excellent in 11%, good in 39%, fair in 44% and poor in 6% patients. While the outcome was mostly fair in 9 patients (47%), 4(21%) good and 6(32%) poor using posterior approach. The relation between functional outcome and the operative approaches used were also examined (Table 6). While there was no difference in outcome between anterior and posterior approach, majority (79%) of patients treated using posterior approach had poor or fair outcome. None of the patients treated using lateral approach showed better (excelled or good) outcome (Figure 2c).

Discussion

Femoral head fractures are rare uncommon injuries, which typically occurs as a result of traumatic posterior dislocation of hip joint [11,20-23]. In our study, 62% of these fractures resulted from motor vehicle accident, followed by 28% from injury due to fall. Early diagnosis and prompt concentric reduction are essential for successful management of these fractures [24]. However, due to lack of established consensus on the diagnosis and treatment of femoral head fractures and limited number of cases reported in the literature, the prognosis of these injuries remains uncertain.

In this retrospective review, we evaluated the management, complication and outcome of fifty patients with femoral head fracture treated at a single institution from January 2011- December 2018. We used modified Harris hip score to evaluate the functional outcome. Our study found an overall outcome of excellent in two patients, good in sixteen patients, fair in twenty-two patients, and poor in eleven patients.

The association between functional outcome, treatment approaches and complications were further investigated based on Pipkin Classification.

According to Pipkin classification [2-4] a relative increase of poor outcomes from Pipkin 1 to 4 (11% to 29% respectively) was noted. This observation is indicative for predictive value of pipkin classification which is also supported by the statistical significance. While these observations were in a small cohort of patients, they do suggest the importance of pipkin classification in predicting less favorable outcomes with an associated femoral head fracture.

The femoral head fracture with hip dislocation is a true emergency in orthopedic trauma. Long term fracture and dislocation of the femoral head will damage the blood supply of the femoral head, leading to subsequent avascular necrosis of femoral head [13]. In addition, complication such as traumatic arthritis may develop due to poor reduction of fracture in the weight bearing area of the articular surface [25]. Therefore, timely diagnosis and prompt accurate reduction of the associated hip dislocation should be performed to prevent further damage to peripheral vessels and improve outcome. Treatment measures were either operative or non-operative. Treatment approach and timing for recovery to each patient were dependent based on the fracture pattern and associated injuries. Using skeletal traction [6,26-28], which is frequently used as an initial management of femoral head fractures, 16% of cases in our study were managed non-operatively to decrease risk of chondrolysis. The criteria for non-operative intervention were determined based on anatomic reduction of hip dislocation and femoral head fracture, intraarticular fragment displacement of less than 1 cm, absence of bone or cartilaginous fragment in the joint space and hip stability. Those fractures that did not meet such criteria were treated operatively [11,29]. Operative measure included fracture fixation using ORIF or total hip replacement (THR). Operative management is generally preferred when the fracture is severe and extends superior to the fovea. In our study, ORIF was mainly rendered to Pipkin II (80%) and Pipkin IV (79%) fractures, while THR was performed mostly within Pipkin III fractures (37.5%).

The long-term follow-up analysis after operative (ORIF) or non-operative treatment regimens on Pipkin 1 injuries demonstrated that the best results (80% excellent or good) were accomplished. Although a statistical difference was not found (P= 0.59), the non-operative intervention seems to result in better outcome than an operative intervention. Several studies support this non-operative management of Pipkin I fractures and controversies remain regarding surgical management of these fractures[30-33]. The fact that only 4 cases were managed non-operative, our finding could be attributed to statistical error. Thus we do not make absolute recommendation in favor of non-operative and against all other operative approaches, when dealing with Pipkin 1 factures, but, if head fractures are less than 1 mm, absence of loose bodies in the joint space, stable hip joint with good relation of head with glenoid[34], non-operative intervention may be an adequate intervention.

Pipkin II fractures involves a larger portion of weight bearing femoral head surface and is more challenging injury [30]. The majority (80%) of these fractures were operated with internal fixation of the

fragment. This is in line with current principles of managing Pipkin II fracture with anatomical reduction and surgical fixation [7,13,30].

Pipkin Type III fractures is the least frequent fracture types that involve dual insult to femoral head and neck. All eight of our Pipkin III injuries underwent operative intervention, using ORIF and/or THR, while none of the patients demonstrated best results (excellent or good). Although treatment options for Pipkin III fractures ranges from open reduction and rigid fixation to arthroplasty, the outcome is highly dependent on age and other variables. Generally, the young patients with Pipkin III fractures should be aimed at preserving the joints, while Total Hip Arthroplasty (THA) may be reasonable option for the elderly[35,36]. In our study, two (out of five) patients with Pipkin III fracture who were operated with fixation of fragment required conversion to secondary THR. This trend supports the opinion of published literature that postulates Pipkin III fractures as a predictive of secondary THR in femoral head fractures [5,37].

Pipkin IV injuries leads to worst outcome as they involve both the femoral head and the acetabulum. A majority of our patients with Pipkin IV injuries were treated with ORIF, however there was no significant improvement in outcome among different treatments methods. One of the particular characteristics about this injury group is that, despite of the type of intervention used, it is often challenging to address whether the approach should be directed to acetabulum, femoral head or both. These fractures require anatomical reduction and internal fixation of femoral head and acetabulum lesions with attention toward restorations of hip congruency and hip stability.

Despite advances in several surgical approaches for femoral head fracture management, controversy exists with regard to the choice of optimal surgical treatment. The anterior Smith-Petersen approach offers good exposure and easier access to the fracture head; and thus, it is more suitable for the treatment of Pipkin I and II femoral head fractures [38]. Such an anterior approach can significantly reduce blood loss and operation time, and therefore reduce the incidence of avascular necrosis of the femoral head, compared to posterior Kocher-Langenbeck approach. However, the often-quoted disadvantage of the anterior- based approaches has been the association with increased heterotopic ossification[3,9,12,39]. Similarly, this approach has also been linked to further damage any residual anterior blood supply to the femoral head although, the anatomical studies does not support this theory [40,41]. The posterior-based approach can provide direct visualization of the acetabular fracture and an opportunity for simultaneous repair of femoral head and acetabular fractures as seen in Pipkin type IV injuries. In this study, majority of patients with Pipkin I and II were treated using anterior approach while the posterior was mainly used in Pipkin III and Pipkin IV fractures. Correlation analysis showed no statistical difference ($p>0.05$) in outcome between anterior and posterior approach. Although it should be noted that irrespective of our findings, the choice of surgical approach and outcome is frequently determined by the fracture pattern and the overall injury severity characteristics.

Regarding major complications, our findings suggest that the likelihood of AVN is higher when a lateral approach is used. This could be due to the severity of Pipkin III injuries and the confounding factors such as displaced femoral neck fracture, damage to vascular structures and inadequate reduction that mostly

leads to subsequent AVN despite of surgical approaches. The AVN is one of the main long-term complications secondary to iatrogenic insult or due to damage during the initial injury[16]. Clinical symptoms of AVN may present early (from 6 weeks) or late (several years following injury) with collapse of femoral head accompanied with PTA[42]. In our study, all patients who developed AVN showed poor functional outcome. While two patients who underwent posterior approach for ORIF, developed AVN. It is important to note that our mean follow up time may be too short to capture all patients who develop clinical symptoms of AVN and thus longer follow-up times are required for detailed analysis on incidence of AVN. Similarly, heterotopic ossification (HO) is one of most common complication after operative fixation, with an incident associated with anterior surgical approach [9,13,20]. In our study, odds ratio analysis demonstrated a trend to a higher incidence of HO (all Brooker stages) after posterior approach relative to anterior one, which was statistically not significant. Although it is unclear, this result could be implicated due to extensive surgical dissection of gluteal muscles during fixation[43]. However, only eight (16%) of our patients who developed HO, all with a Brooker grade I, had no impact to the final functional outcome. Post-traumatic osteoarthritis is another most common complication of femoral head fracture management and its incidence is directly related to the severity of initial injury[23]. A higher incidence of PTA was found in case of a posterior or lateral approach respectively versus an anterior approach. This finding, however, could be attributed to the fact that majority of the patients who developed PTA had fractures that belonged to Pipkin type III (37.5%) and IV (43%) category.

Overall, our study has for the first time used modified Harris Hip (mHHS) score for clinical evaluation of femoral head fractures. Using mHHS, our study indicates that Pipkin classification of femoral head fractures can have a predictive value. Operative management using ORIF is carried out among majority of cases with Pipkin I and Pipkin IV fractures. Non-operative intervention may be adequate for Pipkin I fractures and should be recommended after thorough evaluation of the quality of fracture reduction, articular congruency, hip stability and the absences of loose fragments in joint space using modern imaging techniques. Anterior surgical approach has provided promising results with lower incidence of major complications in Pipkin I and II fractures, making it probably the best approach for operative management of Pipkin I and II fractures. The incidence of HO is also shown to be highly prevalent with posterior K-L approach. Despite of rigid and anatomical fixation, the degree of trauma with pipkin III or IV, creates complexity in physio-anatomical healing and poor functional outcome.

Conclusion

There is an immediate need for clinical management of femoral head fractures, particularly in patients with coexistent hip dislocation. Current limitations in diagnosis, inconsistent fracture classification scheme and optimal treatment of femoral head fractures, insufficient length of follow-up time, absence of validated outcome instruments and lack of high quality randomized (prospective or retrospective) studies, have all led to the lack of absolute recommendation for appropriate treatment of these injuries. Our study attempts to evaluate the management, complications and outcome of femoral head fractures patients treated at a single institution in an effort to add to the growing literature on femoral head

fractures. It is important to conduct large prospective studies using validated outcome scores and strict criteria, that will lead to firm conclusion about the most optimal management of femoral head fractures and further help develop the consensus on fracture classification scheme and operative approaches.

Abbreviations

ORIF: Operative Reduction and Internal Fixation

THA: Total Hip Arthroplasty

AVN Avascular Necrosis

PTA Post-Traumatic Arthritis

HO Heterotopic Ossification

S-P Smith-Peterson

K-L Kocher-Langenbeck

mHHS: modified Harris Hip Score

DVT: Deep Venous Thrombosis

SEM: Means± standard Error of the Mean

AP: Anteroposterior

CT: Computerized Tomography

ISS: Injury Severity Score

Declarations

Ethics approval and consent to participate

Our study was approved by Clinical Research and Biomedical Ethical Committee of West China Hospital, Sichuan University. All the participants provided written informed consent to attend the study.

Consent for publication

All the authors have agreed for the publication. Consent to publish was obtained from the patient detailed in this study.

Competing interests

The authors declare no conflict of interests.

Acknowledgements

All the authors would like to thank for the help of orthopedic surgeons Fuguo Huang, Yue Fang, Shiqiang Cen, Gang Zhong. Also thankful to Reshma Shakya for manuscript preparation and language editing.

Funding

The study was funded by National Natural Science Foundations of China (No.31870961).

Authors' information

Sujan Shaky, Jialei Chen, Jiachen Sun, Zhou Xiang

Department of Orthopaedics, West China Hospital, Sichuan University, No. 37 Guoxue Lane, Chengdu 610041, Sichuan, People's Republic of China.

Authors' contributions

Zhou Xiang contributed conceptualization, supervision, project administration and final editing. Sujan Shakya contributed data curation, performed the examination, writing the manuscript, statistics analysis, review and editing. Jialei Chen contributed data collection, performed the examination, methodology and validation. Jiachen Sun contributed data collection, performed the examination and review.

Availability of data and materials

The original data of this study are available from the corresponding author for reasonable request.

Corresponding author

Correspondence to Sujan Shakya

References

1. **Epstein HC, Wiss DA, Cozen L.** Posterior fracture dislocation of the hip with fractures of the femoral head. *Clin Orthop Relat Res* 1985-201:9-17.
2. **Birkett J.** Description of a Dislocation of the Head of the Femur, complicated with its Fracture; with Remarks. *Medico-chirurgical transactions* 1869;52:133-8.
3. **Mostafa MF, El-Adl W, El-Sayed MA.** Operative treatment of displaced Pipkin type I and II femoral head fractures. *Arch Orthop Trauma Surg* 2014;134-5:637-44.
4. **Tripathy SK, Sen RK, Goyal T.** Conservative versus surgical management of Pipkin type I fractures associated with posterior dislocation of the hip: a randomised controlled trial. *Int Orthop* 2011;35-12:1907-8.

5. **Romeo NM, Firoozabadi R.** Classifications in Brief: The Pipkin Classification of Femoral Head Fractures. *Clinical orthopaedics and related research* 2018;476-5:1114-9.
6. **Giordano V, Giordano M, Glória RC, de Souza FS, di Tullio P, Lages MM, Koch HA.** General principles for treatment of femoral head fractures. *J Clin Orthop Trauma* 2019;10-1:155-60.
7. **Chen ZW, Zhai WL, Ding ZQ, Lian KJ, Kang LQ, Guo LX, Liu H, Lin B.** Operative versus nonoperative management of Pipkin type-II fractures associated with posterior hip dislocation. *Orthopedics* 2011;34-5:350.
8. **Pietrafesa CA, Hoffman JR.** Traumatic dislocation of the hip. *Jama* 1983;249-24:3342-6.
9. **Swiontkowski MF, Thorpe M, Seiler JG, Hansen ST.** Operative management of displaced femoral head fractures: case-matched comparison of anterior versus posterior approaches for Pipkin I and Pipkin II fractures. *J Orthop Trauma* 1992;6-4:437-42.
10. **Wang J, Cai L, Xie L, Chen H, Guo X, Yu K.** 3D printing-based Ganz approach for treatment of femoral head fractures: a prospective analysis. *Journal of Orthopaedic Surgery and Research* 2019;14-1:338.
11. **Stannard JP, Harris HW, Volgas DA, Alonso JE.** Functional outcome of patients with femoral head fractures associated with hip dislocations. *Clin Orthop Relat Res* 2000-377:44-56.
12. **Henle P, Kloen P, Siebenrock KA.** Femoral head injuries: Which treatment strategy can be recommended? *Injury* 2007;38-4:478-88.
13. **Giannoudis PV, Kontakis G, Christoforakis Z, Akula M, Tosounidis T, Koutras C.** Management, complications and clinical results of femoral head fractures. *Injury* 2009;40-12:1245-51.
14. **Marecek GS, Scolaro JA, Routt MLC, Jr.** Femoral Head Fractures. *JBJS Reviews* 2015;3-11.
15. **Ross JR, Gardner MJ.** Femoral head fractures. *Curr Rev Musculoskelet Med* 2012;5-3:199-205.
16. **Del Core MA, Gross B, Ahn J, Wallace SB, Starr A.** Clinical and Radiographic Outcomes of Femoral Head Fractures Associated with Traumatic Hip Dislocations. *Strategies in trauma and limb reconstruction* 2019;14-1:6-10.
17. **Kumar P, Sen R, Aggarwal S, Agarwal S, Rajnish RK.** Reliability of Modified Harris Hip Score as a tool for outcome evaluation of Total Hip Replacements in Indian population. *J Clin Orthop Trauma* 2019;10-1:128-30.
18. **Soederman P, Malchau H.** Is the Harris Hip Score System Useful to Study the Outcome of Total Hip Replacement? *Clinical Orthopaedics and Related Research* 2001;1:189-97.
19. **Chahal J, Van Thiel GS, Mather RC, 3rd, Lee S, Song SH, Davis AM, Salata M, Nho SJ.** The Patient Acceptable Symptomatic State for the Modified Harris Hip Score and Hip Outcome Score Among Patients Undergoing Surgical Treatment for Femoroacetabular Impingement. *Am J Sports Med* 2015;43-8:1844-9.
20. **Scolaro JA, Marecek G, Firoozabadi R, Krieg JC, Routt MLC.** Management and radiographic outcomes of femoral head fractures. *Journal of Orthopaedics and Traumatology* 2017;18-3:235-41.
21. **Chakraborti S, Miller IM.** Dislocation of the hip associated with fracture of the femoral head. *Injury* 1975;7-2:134-42.

22. **Marecek GS, Scolaro JA, Routt ML, Jr.** Femoral Head Fractures. *JBJS Rev* 2015;3-11.
23. **Sahin V, Karakaş ES, Aksu S, Atlihan D, Turk CY, Halici M.** Traumatic dislocation and fracture-dislocation of the hip: a long-term follow-up study. *J Trauma* 2003;54-3:520-9.
24. **Ross JR, Gardner MJ.** Femoral head fractures. *Current Reviews in Musculoskeletal Medicine* 2012;5-3:199-205.
25. **Oransky M, Martinelli N, Sanzarello I, Papapietro N.** Fractures of the femoral head: a long-term follow-up study. *Musculoskelet Surg* 2012;96-2:95-9.
26. **DeLee JC, Evans JA, Thomas J.** Anterior dislocation of the hip and associated femoral-head fractures. *J Bone Joint Surg Am* 1980;62-6:960-4.
27. **Kristensen O, Stougaard J.** Traumatic dislocation of the hip. Results of conservative treatment. *Acta Orthop Scand* 1974;45-2:206-12.
28. **Lang-Stevenson A, Getty CJ.** The Pipkin fracture-dislocation of the hip. *Injury* 1987;18-4:264-9.
29. **Wang Z-h, Li K-n, Zhao P, Chen E-d, Zheng J.** In Situ Reduction and Fixation of the Anterior Medial Fenestration Approach for Femoral Head Fracture. *Orthopaedic Surgery* 2019;11-6:1163-72.
30. **Butler JE.** Pipkin Type-II fractures of the femoral head. *J Bone Joint Surg Am* 1981;63-8:1292-6.
31. **Lin D, Lian K, Chen Z, Wang L, Hao J, Zhang H.** Emergent surgical reduction and fixation for Pipkin type I femoral fractures. *Orthopedics* 2013;36-6:778-82.
32. **Yu X, Pang QJ, Chen XJ.** Clinical results of femoral head fracture-dislocation treated according to the Pipkin classification. *Pak J Med Sci* 2017;33-3:650-3.
33. **Chen ZW, Lin B, Zhai WL, Guo ZM, Liang Z, Zheng JP, Lian KJ, Ding ZQ.** Conservative versus surgical management of Pipkin type I fractures associated with posterior dislocation of the hip: a randomised controlled trial. *Int Orthop* 2011;35-7:1077-81.
34. **Wang ZH, Li KN.** In Situ Reduction and Fixation of the Anterior Medial Fenestration Approach for Femoral Head Fracture. 2019;11-6:1163-72.
35. **Pipkin G.** Treatment of Grade IV Fracture-Dislocation of the Hip. *Journal of Bone and Joint Surgery, American Volume* 1957;39-5:1027-197.
36. **Chen L, Hong G, Hong Z, Lin T, Chen Z, Zhang Q, He W.** Optimizing indications of impacting bone allograft transplantation in osteonecrosis of the femoral head. *Bone Joint J* 2020;102-b-7:838-44.
37. **Tonetti J, Ruatti S, Lafontan V, Loubignac F, Chiron P, Sari-Ali H, Bonnevialle P.** Is femoral head fracture-dislocation management improvable: A retrospective study in 110 cases. *Orthop Traumatol Surg Res* 2010;96-6:623-31.
38. **Thannheimer A, Gutsfeld P, Bühren V.** [Current therapy options for fractures of the femoral head]. *Chirurg* 2009;80-12:1140-6.
39. **Guo JJ, Tang N, Yang HL, Qin L, Leung KS.** Impact of surgical approach on postoperative heterotopic ossification and avascular necrosis in femoral head fractures: a systematic review. *International orthopaedics* 2010;34-3:319-22.

40. **Gautier E, Ganz K, Krügel N, Gill T, Ganz R.** Anatomy of the medial femoral circumflex artery and its surgical implications. *J Bone Joint Surg Br* 2000,82-5:679-83.
41. **Sevitt S, Thompson RG.** THE DISTRIBUTION AND ANASTOMOSES OF ARTERIES SUPPLYING THE HEAD AND NECK OF THE FEMUR. *The Journal of Bone and Joint Surgery. British volume* 1965,47-B-3:560-73.
42. **Kuroda Y, Tanaka T, Miyagawa T, Kawai T, Goto K, Tanaka S, Matsuda S, Akiyama H.** Classification of osteonecrosis of the femoral head: Who should have surgery? *Bone & Joint Research* 2019,8:451-8.
43. **Cirino CM, Chan JJ, Patterson DC, Jia R, Poeran J, Parsons BO, Cagle PJ.** Risk factors for heterotopic ossification in operatively treated proximal humeral fractures. *The Bone & Joint Journal* 2020,102-B-4:539-44.

Tables

Table 1: Table showing demographic, classification, associated injuries and mechanism of injuries related to femoral head fractures

Parameters	Number of patients (%)
Number of Patients	50
Gender	
Male	37 (74%)
Female	13 (26%)
Classification	
Pipkin I	18 (36%)
Pipkin II	10 (20%)
Pipkin III	8 (16%)
Pipkin IV	14 (28%)
Associated injuries	
Knee confusion	15 (29%)
Patella Fracture	12 (23%)
Extremities Fracture	13 (25%)
Ribs Fracture	16 (31%)
Lumbar transverse process fracture	10 (20%)
Pubic rami fracture	5 (10%)
Chest confusion	7 (14%)
Sciatic nerve damage	6 (12%)
Brain confusion	6 (12%)
Clavicle fracture	1 (2%)
Hemorrhagic anemia	3 (6%)
20 isolated pipkin fracture out of 51	40%
30 polytraumatic patients with associated injuries	60%
Mechanism of injury	
Car accident	31(62%)
Fall injury	14 (28%)
Sports injury	2 (4%)
Bike accident	2 (4%)

Workplace accident	1 (2%)

Table 2. Table showing treatments, complication and outcome of femoral head injury.

	No. of patients (%)
Treatments	
Nonoperative	8 (16%)
Operative	
ORIF	37 (74%)
Immediate THR	5 (10%)
Complication	
AVN	6 (12%)
PTA	16 (32%)
HO	8 (16%)
Sciatic nerve injury	6(12%)
Modified Harris Score	
Excellent	2 (4%)
Good	16 (32%)
Fair	22 (44%)
Poor	10 (20%)
Secondary THR	4 (8%)

Note: ORIF= open reduction and internal fixation, AVN=avascular necrosis, PTA= post traumatic arthritis, HO=Heterotopic ossification, THR= Total Hip Replacement

Table 3. Table showing treatments, complications and outcome of femoral head injury according on pipkin classification.

	n = 50	Pipkin I (n=18)	Pipkin II (n=10)	Pipkin III (n=8)	Pipkin IV (n=14)
Treatments					
Non-operative	8 (16%)	5 (28%)	1 (10%)	0 (0%)	2 (14%)
Operative					
ORIF	37 (74%)	13 (72%)	8 (80%)	5 (63%)	11 (79%)
Immediate THR	5 (10%)	0 (0%)	1 (10%)	3 (37%)	1 (7%)
Complications					
AVN	6 (14%)	0 (0%)	1 (10%)	3 (38%)	2 (14%)
PTA	16 (33%)	4 (22%)	3 (20%)	3 (38%)	6 (43%)
HO	8 (16%)	2 (11%)	3 (30%)	0 (0%)	3 (21%)
Sciatic nerve injury	6(12%)	2 (0%)	0 (0%)	2 (25%)	2 (14%)
Modified Harris Score					
Excellent	2 (4%)	2 (11%)	0 (0%)	0 (0%)	0 (0%)
Good	16 (32%)	9 (50%)	5 (50%)	0 (0%)	2 (14%)
Fair	22 (44%)	5 (28%)	4 (40%)	5 (64%)	8 (57%)
Poor	10 (20%)	2 (11%)	1 (10%)	3 (36%)	4 (29%)
Secondary THR	4 (8%)	0 (0%)	1 (10%)	2 (25%)	1 (7%)

Note: ORIF= open reduction and internal fixation, AVN=avascular necrosis, PTA= post traumatic arthritis, HO=Heterotopic ossification, THR= Total Hip Replacement, N=number of patients

Table 4. Table showing complications in relation to the surgical approaches.

Complications	Anterior (S-P) (n=18)	Posterior (K-L) (n=19)	Lateral (n=3)	Anterior+ Lateral (n=2)	Total (n=42)
AVN		2	3		5 (12%)
PTA	4	6	3		13 (31%)
HO	3	5			8 (19)
Sciatic nerve injury		2			2(5%)

Note: AVN=avascular necrosis, PTA= post traumatic arthritis, HO=Heterotopic ossification, S-P= Smith-Peterson, K-L= Kocher-Langenbeck, n=number of patients

Table 5. Table showing outcome in relation to the treatment variables.

Complications	Non-operative (n=8)	ORIF (n=37)	THR (n=5)	Total (n=50)
Excellent	0	2 (5.4%)		2 (4%)
Good	5 (62.5%)	11 (29.8%)		16 (32%)
Fair	2 (25%)	15 (40.5%)	5(100%)	22 (44%)
Poor	1 (12.5%)	9 (24.3%)		10 (20%)

Note: n=number of patients

Table 6. Table showing outcome in relation to the surgical approaches.

Complications	Anterior (S-P) (n=18)	Posterior (K-L) (n=19)	Lateral (n=3)	Anterior+Lateral (n=2)	Total (n=42)
Excellent	2(11.1%)	0			2(4.8%)
Good	7(38.9%)	4(21%)			11(26.2%)
Fair	8(44.4%)	9(47.4%)		2(100%)	19(45.2%)
Poor	1(5.6%)	6(31.6%)	3(100%)		10(28.8%)

Note: n=number of patients

Figures

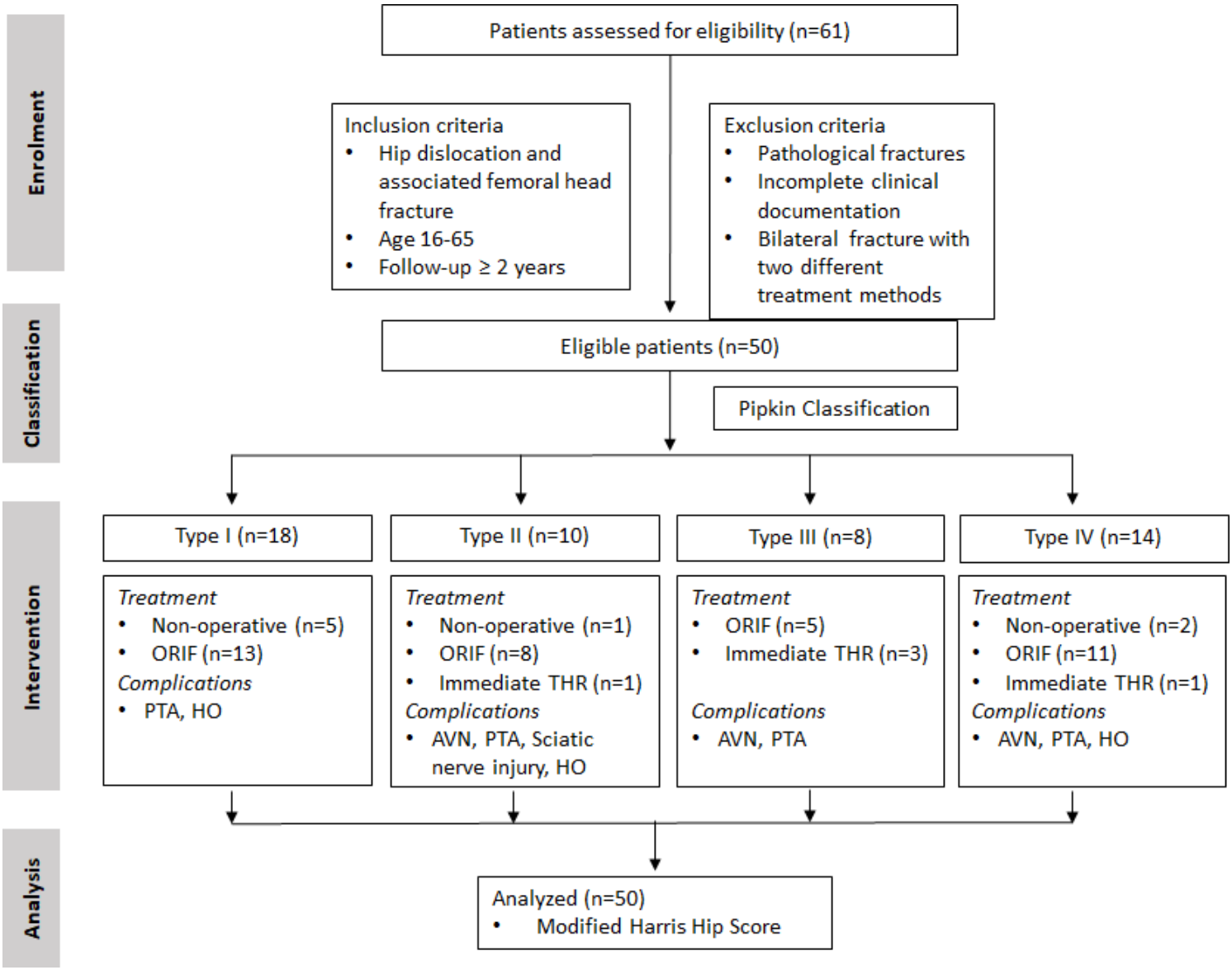

Figure 1

CONSORT diagram showing femoral head fracture patients' recruitment, clinical intervention and analysis

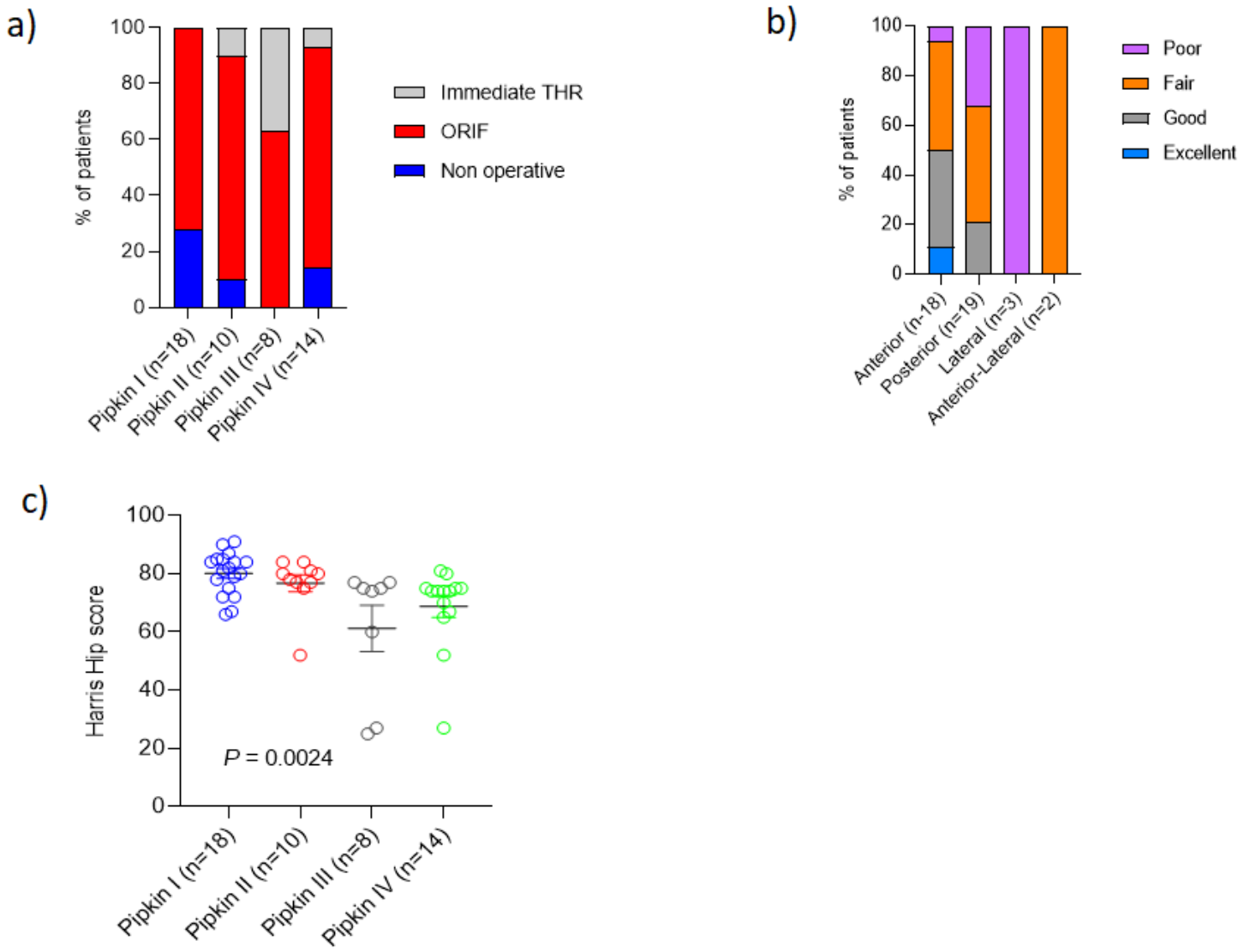

Figure 2

Treatment, complication and outcome of femoral head fracture patients in relation to Pipkin Classification. (a) Relative distribution of femoral head fracture patients in four Pipkin subtypes based on different treatment variable. (b) Relative distribution of femoral head fracture patients in four Pipkin subtypes based on functional outcome. (c) Harris hip score measuring functional outcome in relation to different surgical approaches. Data presented as means±SEM. P-values were calculated using one-way NOVA (analysis of variance). P <0.05 considered as statistically significant

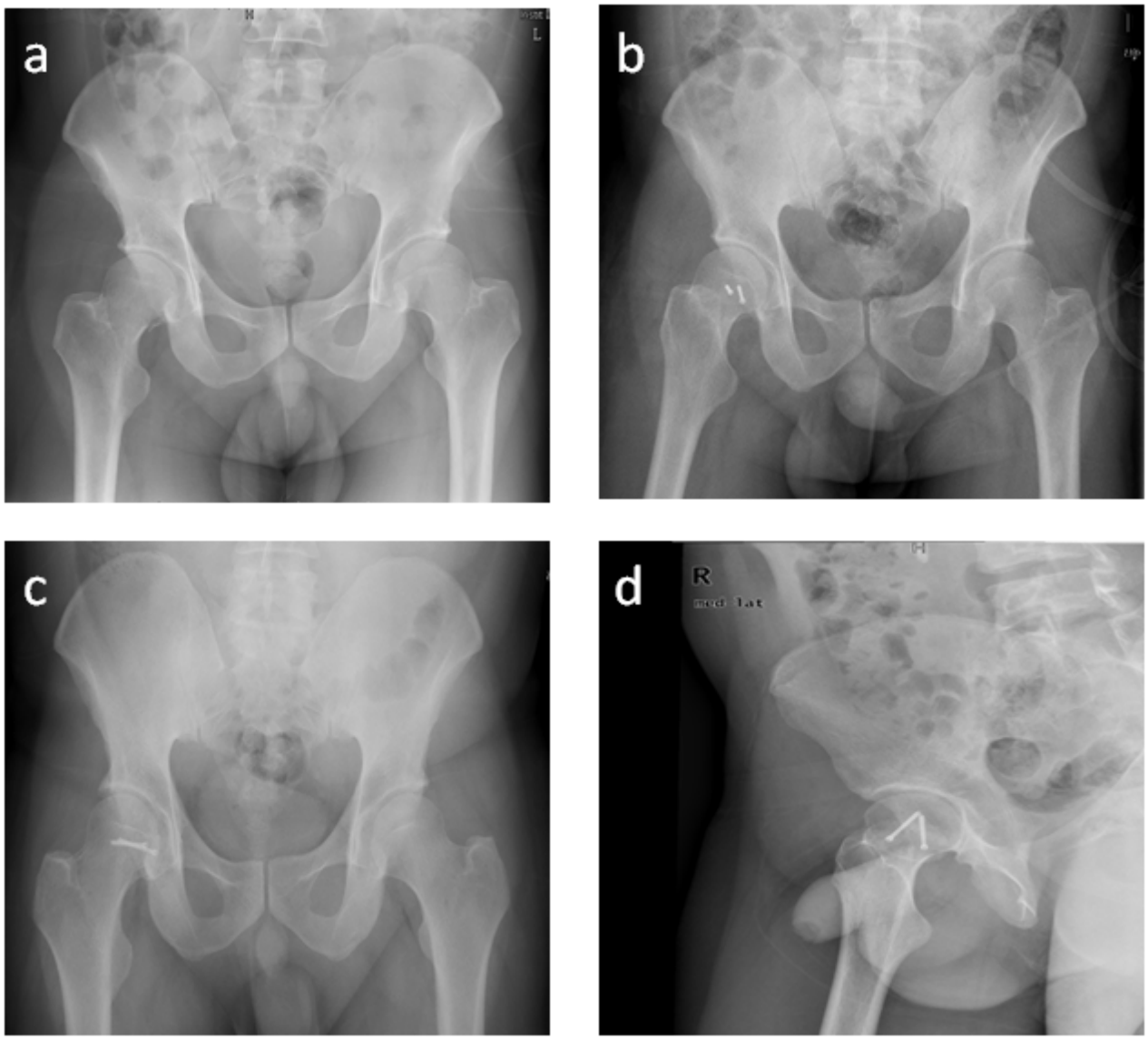

Figure 3

(a) A 39 -year-old man with Pipkin type I right femoral head fracture (b) Anteroposterior (AP) radiographs showing anatomical reduction of femoral head using anterior approach under direct vision. (c) AP and (d)Lateral radiograph of hip during 3rd year follow-up after internal fixation.

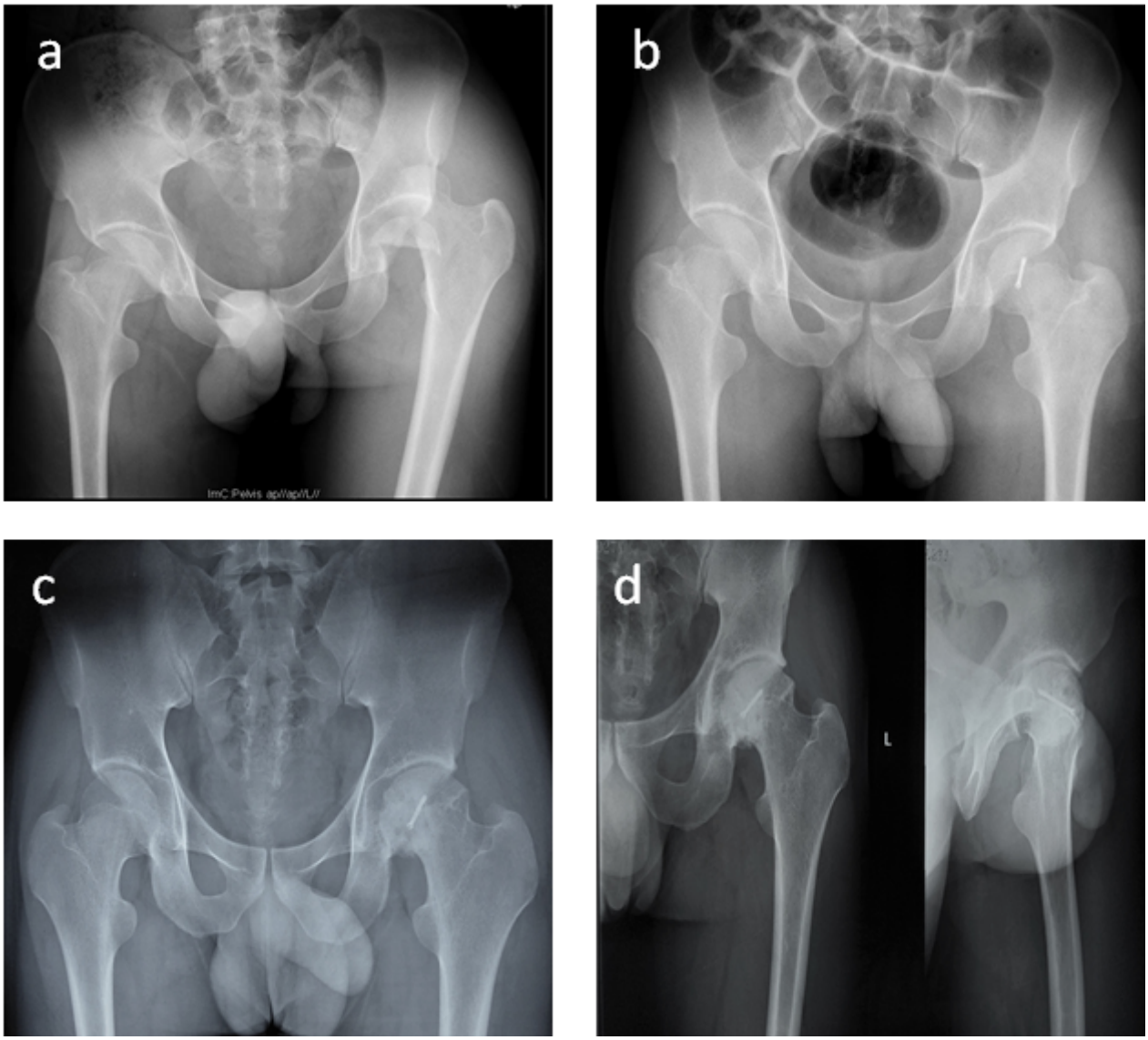

Figure 4

A 27-year female sustained injury after motor vehicle accident. (a) Coronal view (b) 3D CT demonstrated right sided Pipkin III femoral head and neck fracture. (c) The fracture was anatomically reduced with herbert screw via anterior approach and femoral neck was corrected with three cannulated screw utilizing lateral stab approach.

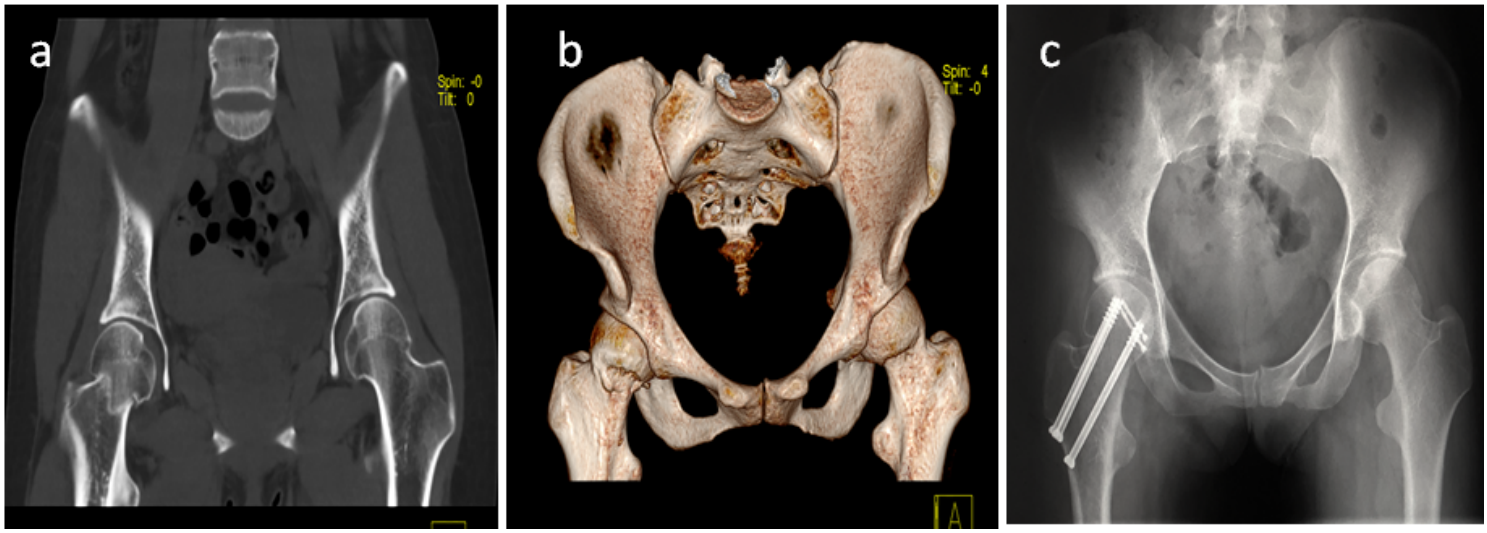

Figure 5

(a) Anteroposterior pelvic radiographs showing a 21-year-old male with left Pipkin II fracture dislocation. (b) Post operatively showing anatomical reduction of femoral head with one herbert screw via anterior approach. (c) AP radiograph of 4th year follow-up. (d AP and Lateral radiograph of 7th year follow-up. There is no sign of AVN but signs of post-traumatic osteoarthritis with some loss of joint space but no heterotopic ossification.