Cardiovascular Particularities in Pega Breed Donkeys (Equus asinus)

Amanda Sarita Cruz Aleixo (amanda.cruz21@hotmail.com)
Sao Paulo State University Julio de Mesquita Filho: Universidade Estadual Paulista Julio de Mesquita Filho

Karina Cristina de Oliveira
Sao Paulo State University Julio de Mesquita Filho: Universidade Estadual Paulista Julio de Mesquita Filho

Lucas Vinícius de Oliveira Ferreira
Sao Paulo State University Julio de Mesquita Filho: Universidade Estadual Paulista Julio de Mesquita Filho

Dario Alejandro Cedeño Quevedo
University of Nariño: Universidad de Narino

Miriam Harumi Tsunemi
Sao Paulo State University Julio de Mesquita Filho: Universidade Estadual Paulista Julio de Mesquita Filho

Simone Biagio Chiacchio
Sao Paulo State University Julio de Mesquita Filho: Universidade Estadual Paulista Julio de Mesquita Filho

Maria Lucia Gomes Lourenço
Sao Paulo State University Julio de Mesquita Filho: Universidade Estadual Paulista Julio de Mesquita Filho

---

Research Article

Keywords: heart, equine, electrocardiogram, echocardiogram, donkeys

Posted Date: March 17th, 2022

DOI: https://doi.org/10.21203/rs.3.rs-1417022/v1

CARDIOVASCULAR PARTICULARITIES IN PEGA BREED DONKEYS (Equus asinus)

Amanda Sarita Cruz Aleixo[1], Karina Cristina de Oliveira[2], Lucas Vinícius de Oliveira Ferreira[3], Dario Alejandro Cedeño Quevedo[4], Miriam Harumi Tsunemi[5], Simone Biagio Chiacchio[6], Maria Lucia Gomes Lourenço[7]

[1]School of Veterinary Medicine and Animal Science, Department of Animal Health, UNESP, Botucatu, São Paulo, Brazil; email: amanda.cruz21@hotmail.com

[2] School of Veterinary Medicine and Animal Science, Department of Animal Health, UNESP, Botucatu, São Paulo, Brazil; email: kaka_c_oliveira@hotmail.com

[3] School of Veterinary Medicine and Animal Science, Department of Animal Health, UNESP, Botucatu, São Paulo, Brazil; email: lucasvini00@hotmail.com

[4]Department of Animal Health, University of Nariño, Pasto, Nariño, Colombia; email: dcedeno@udenar.edu.co

[5] São Paulo State University (Unesp), Institute of Biosciences, Botucatu, São Paulo, Brazil; email: m.tsunemi@unesp.br

[6] School of Veterinary Medicine and Animal Science, Department of Animal Health, UNESP, Botucatu, São Paulo, Brazil; email: sb.chiacchio@unesp.br

[7] School of Veterinary Medicine and Animal Science, Department of Animal Health, UNESP, Botucatu, São Paulo, Brazil; email: maria-lucia.lourenco@unesp.br *Corresponding author. Postal code: Rua Prof. Doutor Walter Mauricio Correa, s/n Bairro: Unesp Campus de Botucatu, Sao Paulo, Brazil, Zip Code: 18618-681 - Botucatu, SP; Phone: +55 3811-6000; Fax: +55 3815-2343

ABSTRACT

Clinical, electrocardiographic and echocardiographic parameters in Pega donkeys are scarce in literature, hence this study was performed to evaluate the effect of sex and age on echocardiographic and electrocardiographic measurements in the Pega breed donkeys. The objectives of this study were to describe and illustrate the clinical, electrocardiographic and echocardiographic parameters in Pega donkeys. Fifty Pega breed donkeys were evaluated, with an average age of 3.4 years, 20 males and 30 females. Based on their age (younger or older than 6 years), animals were separated into two

groups. In each animal the electrocardiographic examination was performed using the TEB® computerized system and the echocardiographic examination was performed using an ultrasound device with a doppler function multifrequency sectorial transducer, in 2D mode. Male echocardiographic measurements were significantly higher than females, except the velocity and pressure gradient of the pulmonary flow, where females had higher values than males. For the electrocardiographic parameters, females presented values of P wave amplitude, R wave amplitude, S wave amplitude and T wave amplitude higher than those found in males. Males had higher values for P wave duration, QRS complex and RR interval. Standardizing the electrocardiographic and echocardiographic parameters for the Pega breed donkey can contribute to future assessments regarding possible changes that excessive effort can promote in these parameters, to a management engrossed on animal welfare. Furthermore, as well as in other species, gender in donkeys should be considered as a factor that influences echocardiographic and electrocardiographic parameters.

Keywords: heart, equine, electrocardiogram, echocardiogram, donkeys

1. INTRODUCTION

Currently, donkeys are animals of great economic interest and also as companion animals, a fact that has increased awareness of the welfare and care of these animals, increasing the demand for specialized veterinary services (Morrow et al. 2011). Anatomical and physiological differences have been reported between donkeys and horses, therefore, the use of clinical data, treatments and diagnostic protocols from horses to donkeys can trigger diagnostic errors and inappropriate therapeutic administration (Mendoza et al. 2018). There is a variety of differences in behavior and social organization between donkeys and horses, although they are often housed as companion animals or as a homogeneous group. However, this does not mean that the nature of social

relationships between different species of equids is the same as between their own species (Trachsel et al. 2016).

Brazil has the largest herd of horses in Latin America and the third in the world. There are l 8 million donkeys and horses, with transactions of R$ 7.3 billion only thru the production of horses (Costa and Pacheco 2017). The main breeds of donkeys used to obtain mules are the Paulista or Brasileiro, the Pega and the Northeastern donkey. The Pega is a national donkey breed with economic value throughout the national territory, raised for the production of new breeders and for marching mules. It is a versatile animal used for pack animals, in preparing the soil, herding cattle, horseback riding, functional tests, walking contests among many modalities, and is currently the most used in the training of saddle-type (Almeida 2009).

Suspicion of potential heart disease may appear after routine examinations or during pre-purchase evaluation of an animal. On the other hand, the care of an equine may be requested due to a specific complaint of cardiovascular signs, however, this assessment is not as widespread in donkeys (Burden and Thiemann 2016). The clinical symptoms or the absence of them are important factors in the assessment of a possible cardiac study for reflection on potential differential diagnoses (Trachsel et al. 2016). Heart disease is rare in horses compared to other domestic species due to the large cardiac reserve, overt clinical signs are often seen only when there is severe dysfunction or during forceful exercise. Although, murmurs and arrhythmias are commonly detected in equines, these are often of physiological origin and have no pathological significance (Keen 2019).

Arrhythmias during or immediately after exercise are common occurrences in equine athletes. The spectrum of these rhythm variations covers clinically irrelevant arrhythmias, arrhythmias that can cause poor performance and rhythms with risk of death

(Solis 2016). A standard base-apex electrocardiogram at rest should be performed in all horses with arrhythmia not attributable to second-degree atrioventricular block (Loon 2019). Digital ECG telemetry systems are readily portable and can be used to obtain real-time digital monitoring and recording at rest or during exercise (Chope 2018). In donkeys, there is little information in the literature regarding arrhythmic events that may occur during exercise, and there is no standardized information about possible arrhythmias that can be considered common in the species.

Thus, since electrocardiographic and echocardiographic parameters in Pega donkeys are scarce in the literature, as well as the description of possible arrhythmic events that may be considered common in the species and the description of cardiovascular diseases, the objectives of this study were to describe and illustrate the clinical, electrocardiographic and echocardiographic parameters in Pega donkeys, which may contribute to future studies aiming to assess the influence of exercise on such parameters as well as the activity of the autonomic nervous system in these animals during overexertion, since they are already adapted for such efforts.

It was also aimed to describe the parameters according to gender, since it is described that there is hormonal influence between males and females in other species. The description of theses parameters can contribute to a better understanding of specific changes that may occur in donkeys, where evaluations in horses are often used as a reference for these animals, which can lead to erroneous conclusions, where the particularities of different categories and breeds of animals must be respected.

2. METHODOLOGY

2.1. Animals and study site

The present study was carried out according to the animal welfare standards, approved by the Ethics Committee on the Use of Animals (CEUA) of the Faculty of Veterinary Medicine and Animal Science of the São Paulo State University "Júlio de Mesquita Filho", Botucatu Campus, under the protocol CEUA-0029/2021.

The present study was carried out on 50 clinically healthy adult donkeys with age under 13 years, 20 males and 30 females. Before enrollment in the study, all donkeys underwent complete physical examination to exclude systemic conditions (colic, respiratory diseases, orthopedic diseases).

The study was carried out at the stud farm Criatório Ximbó, located in the district of Maristela-SP, belonging to the city of Laranjal Paulista-SP, with latitude 23º02'59" south and longitude 47º50'12" west. For this purpose, 50 donkeys were evaluated, with an average age of 3.4 years, 20 males and 30 females, all from the same establishment. The animals were kept in paddocks and individual pens and were fed with Tifton hay produced on the property and pelleted feed with 15% protein, being offered a total of 3 kg of daily feed divided into two portions, also adding commercial mineral salt to horses at will.

The study was carried out after approval by the animal use ethics committee, in accordance with the animal welfare standards, upon signature of the owner's informed consent form.

2.2. Analysis groups

The animals were evaluated according to their clinical parameters such as heart rate (HR - beats per minute - bpm), respiratory rate (RR - movements per minute - mpm), mucosal color, rectal temperature (°C), capillary filling time (CFT).

The evaluations were also carried out according to the division by sex and age group. We also recommend evaluating the influence of age on electrocardiographic and echocardiographic parameters according to gender division. For this purpose, the animals were subdivided into age groups below 6 years and above 6 years.

As there are no specific HR parameters for donkeys, the HR values were divided according to the reference for horses (28-60) and similar to the division into groups according to HR adopted by Guccione et al. (2014) (11). Thus, the division of the study according to HR by class was: class 1: HR ≤30 bpm, class 2: HR 30-60 bpm and class 3 > 60 bpm

2.3 Electrocardiographic examination

The electrocardiographic examination was performed using the TEB® computerized system (Brazilian Electronic Technology, São Paulo-SP, Brazil), and the electrocardiographic tracings were recorded with a sensitivity of 1mV = 1cm and at a speed of 25 mm/s, compiling the bipolar I, II and III lead and unipolar amplified aVR, aVF and aVL.

The electrodes were attached to the skin using “alligator” clips soaked with alcohol. Recordings were performed as described by Loon and Patteson (2010), placing the positive electrode on the left side, above the heart apex (green), just behind the olecranon, the negative electrode on the right side, cranial to the scapula, close to the jugular vein (red) and the ground electrode attached to the animal's withers (black). For each electrocardiographic record, HR, rhythm, P wave duration and amplitude, PR interval duration, QRS complex duration, R wave amplitude, S wave amplitude, QT interval duration were analyzed, duration and amplitude of the T wave.

2.4 Echocardiographic examination

To obtain the echocardiographic evaluation, the animals were kept in a station, manually contained, without any type of sedation for the examination. Trichotomy and cleaning of the right thoracic region were performed, 10 cm above the height of the olecranon, with the right thoracic limb carefully placed forward.

The echocardiographic examination was performed using an ultrasound device (M-turbo Sonosite model, Fujifilm do Brasil Ltda., São Paulo-SP, Brazil), with a doppler function and a 2–8 MHz multifrequency sectorial transducer, in 2D mode. The transducer was positioned between the 4th and 5th intercostal space. The measurements were always performed by the same operator, obtaining three measurements from each assessment.

Through the right parasternal window, in cross-section, M-mode, at the height of the papillary plane, in diastole were measured: interventricular septal thickening (IVS), left ventricular internal diameter (LVID), left ventricular free wall thickness LVFW and right ventricular diameter in diastole (RIVDd). In systole, interventricular septal thickening (IVS), left ventricular internal diameter (LVID), left ventricular free wall thickness (LVFW) were analyzed.

The fractional shortening of the left ventricle (FS) was obtained by the Teichholz method. To calculate the FS (%) the following formula was used: (LVIDd – LVIDs/ LVIDd) x 100, and the left ventricular ejection fraction (EF) was also recorded.

The diameter of the left atrium (LA) at the end of ventricular systole and of the aorta (Ao) in diastole, left atrium/aorta ratio (LA/Ao) (figure 1) were obtained at the height of the aortic plane and the pulmonary flow velocity (pulmonary velocity) and pressure gradient between the right ventricle and pulmonary artery at the level of the pulmonary plane. Lung diameter and aortic diameter were also measured, and the pulmonary/aorta ratio (pul/ao) was obtained from the cross-section of the base. Aortic

flow velocity (Ao. velocity), pressure gradient between left ventricle and aorta artery were also compiled.

2.5 Statistical analysis

The results are illustrated with the mean, standard deviation, minimum and maximum values. To analyze the parameters, the normality test used was the Shapiro-Wilks test; to compare the proposed moments, the Mann-Whitnney test was used. All discussions were carried out at a 5% significance level.

3. RESULTS

The mean standard deviation, minimum and maximum values of the clinical parameters in healthy donkeys are tabulated in Table 1. The average age of the animals was 3.4 years, with a HR of 67 bpm and a RR of 35 mpm.

The mean values and standard deviation of echocardiographic measurements and parameters of the healthy Pega breed donkeys are tabulated in Table 2.

Through right parasternal window, four-chamber longitudinal section by the two-dimensional echocardiogram of a male donkey, 6 years old was achieved to obtained the image illustrated in Figure 2.

The mean values and range of echocardiographic measurements and parameters in healthy donkeys in relation to gender are tabulated in Table 3.

Males had greater IVS thickness and LVd, and females had higher values of LVs and LVFW in systole and diastole obtained in the M mode. For the other parameters, measurements in males, had higher values than females, except for the velocity and pressure gradient of the pulmonary flow, where females had higher values than males.

The statistical analysis did not show a significant difference on any of the echocardiographic measurements between males and females.

The mean values and standard deviation of electrocardiographic measurements and parameters of the 50 healthy Pega breed donkeys are tabulated in Table 4.

In table 4 is tabulated the mean HR of 50 donkeys (65 bpm). According to the class division approved in the study, no animal presented sinus bradycardia and a HR below 35 bpm (class 1 = 0), 22 animals (44%) had a HR within class 2 (30-60 bpm) and 28 animals (56%) presented a HR compatible with class 3 (> 60 bpm). In view of the horse reference, the predominant rhythm was Sinus Tachycardia. Bifid P waves were not observed in the animals in the present study. There was a predominance of the QRS complexes pattern of rS-type (figure 3). The amplitude of the T wave varied, with 45% (22 animals) showing positive T waves, 28% (14 animals) negative T waves and 28% biphasic T waves. Arrhythmic events were not detected in the animals in the present study.

The mean values and range of electrocardiographic measurements and parameters in healthy donkeys in relation to gender are tabulated in Table 5.

In table 5, we observe that females presented values of P and R wave amplitude higher than males with a significant difference between sexes, as well as higher values of S and T wave amplitude with a no significant difference. Males presented higher values for the duration of the P wave, the QRS complex and the RR interval, with statistical difference between groups concerning sex for the duration QRS complex.

Table 6 illustrates the electrocardiographic evaluations according to the division into groups according to gender being subdivided into groups by age group below 6 years and above 6 years.

There were significant differences among males under the age of 6 years and over 6 years for the HR obtained by the electrocardiogram. Animals under the age 6 years had higher HR values and PR interval. Animals above the age 6 years showed a reduction in the duration of the PR interval. The QT interval and the duration of the RR interval differed significantly among males; its value was higher in animals over 6 years old.

A significant difference in the duration of the PR interval and S wave amplitude was presented among females. Females over 6 years old had a longer PR interval duration and a lower S wave amplitude.

Table 7 illustrates the echocardiographic assessments according to the division into groups according to gender, subdivided into groups by age group below 6 years and above 6 years.

There were significant differences among females for IVDs and IVDd. Females over 6 years showed higher values and the measurement for pulmonary artery diameter.

There was a significant difference for IVSs between males, with a higher value and in the measurement of the aorta and pulmonary artery diameter in animals over 6 years old.

4. DISCUSSION

The present study represented the normal reference range of echocardiographic and electrocardiographic measurements and parameters in healthy Pega donkeys. The mean HR results in this study, of the by clinical examination (67 bpm) and electrocardiogram (ECG) (65 bpm), were higher than that reported by Guccione et al. (2014) in donkeys (47 bpm). The authors evaluated the HR in 15 donkeys by Holter examination during the day and night. The mean HR in our study and the reported by the mentioned authors in horses are superior, indicating that there are differences in the activity of the autonomic nervous system (ANS) between donkeys, asses and horses.

There is a need for studies explaining and comparing the ANS activity between them. The different acquisition techniques of these parameters should also be considered, since in our study the HR recording was immediate to manipulation, which may have contributed to higher values.

Escudero et al. (2009) carried out a study to evaluate the electrocardiographic parameters in both sexes in Zamorano-Leones using the conventional method. In our study, the P wave amplitude presented higher values for males (0.29 mV) and females (0.33 mV) in relation to the study of the aforementioned authors (males 0.24 mV, females 0, 13 mV) and the S wave amplitude showed high values for males (1.84 mV) and females (1.94 mV) when compared to the findings by Escudero et al. (2009) (13) (males 0.95 mV) and females (0.51 mV).

In our results the duration of the P waves was higher (males 113 ms) (females 110 ms) than those found by the aforementioned authors (males 100 ms) (females (94 ms). In this study, males had an average of 118 ms and females 108 ms for the QRS complex and in Escudero et al. (2009) results, males had an average of 85 ms and females 66 ms. The QT interval for males in our study, the duration of the interval was 431 ms and for females 433 ms , while Escudero reported 329 ms and 328 ms in duration respectively.

The method used for the electrocardiographic assessment and the breed may have influenced the differences results for the duration and amplitude of the electrocardiographic waves. The scarce information in literature of electrocardiographic parameters in donkeys, requires studies aimed at standardizing clinical and electrocardiographic parameters for the breed. Al-Haidar et al. (2013) demonstrated in horse studies that breed has an influence on echocardiographic parameters.

The echocardiographic parameters obtained in the M mode in the present study, when compared with the donkey parameters originated by Roberts and Dukes-McEwan

(2016), regarding gender in diastole for males, showed higher values, (IVSd = 1.81 and LVIDd = 6.81) than those reported by Roberts and Dukes-McEwan (2016) (15) in males (IVSd = 1.64 and LVIDd = 6.65) and LVFWd for the Pega breed were similar to those of the aforementioned authors for males with an average of 1.68 cm.

The thickness measurement parameters, SIVd and LVFWd, in the females (IVSd = 1.70, LVFWd = 1.77) were higher than those found by aforementioned authors (IVSd = 1.57, LVFWd = 1.74). LVIDd of females, in our study had lower values (LVIDd = 6.79) than the values reported by Roberts and Dukes-McEwan (2016) (LVIDd = 7.31). In the present study and aforementioned authors showed that females had greater thickness of LVFWd, demonstrating that gender should be considered for the analysis of echocardiographic parameters in donkeys.

In this study, parameters obtained in the M mode in systole, females had higher thickness measurement parameters (LIVDs and LVFWs) than males and in the results reported by Roberts and Dukes-McEwan (2016). Pega males and females had higher values for SIVs (males 3.16 X 2.55; females 2.97 X 2.64). In our study, LIVDs measurements showed similar values as those found by the aforementioned authors for females (LIVDs = 4.15 cm), and males had lower values (LIVDs = 3.96) when compared to the work by Roberts and Dukes-McEwan (2016) (LIVDs 4.03). Thickness measurement LVFWs, was higher for both sexes (males = 2.51, females = 2.64) when compared to the study by the aforementioned authors (males = 2.30, females 2.22).

Pega females aged over 6 years had higher values in LIVDs and LIVDd parameters and SIVs in males. Horse heart size and dimensions increases in relation to the animal´s height and weight, but according to Farag and Ibrahim (2020), in study with donkeys, did not find an association between echocardiographic parameters in both the B mode and the mode M with age and body weight.

In horses, age has a great effect on the inner diameter of the aortic and pulmonary arteries. In addition, body weight also has a significant effect on all echocardiographic dimensions, but sex has no effect on any of them (Al-Hadair et al. 2013). In our study, animals over six years old presented higher measurements in aortic and pulmonary diameters. In humans, the aortic diameter may increase with age, and collagen changes and systemic arterial hypertension may contribute to aortic artery aneurysm (Kobeissi et al. 2019; Chen et al. 2021).

Scarce data literature and the need for racial distinction, emphasizes the need to standardize electrocardiographic and echocardiographic parameters in donkeys. Because the animals do not show obvious clinical signs, cardiovascular diseases in this species can be underdiagnosed. The early diagnosis of changes in heart rate and cardiovascular structure can contribute to the use of these animals in modalities that require excessive effort and reduce the number of conditions that go undiagnosed (Hassan and Torad, 2015).

Cardiovascular disease can be seen in donkeys, presumably with a prevalence similar to horses. Available information about these conditions is uncommon in this species, which does not make the diseases rare. However, a large proportion of cardiovascular diseases are described in horses that lead to reduced performance. Considering that donkeys and asses are not commonly used as riding animals and their athletic attitude is limited, these diseases could easily be underdiagnosed (Roberts and Dukes-McEwan (2016).

According to Reef (2019) a regular sinus rhythm, with a range HR at rest from 24 bpm to 44 bpm, is the most common rhythm detected in horses. The adult horse has high vagal tone present at rest, especially in good physical conditions, resulting in low resting heart rates and rhythm disturbances that disappear with excitement, exercise, or any

intervention that increases sympathetic tone. Thus, according to reports by Reef (2019) and with the mean heart rates found in the animals in this study, we observed that donkeys have high HR compared to horses, which may lead us to infer that reference values for horses should not be used to assess normality parameters for donkeys. Studies using HRV analysis in this context are necessary, since, as illustrated in this study, donkeys seem to have a higher sympathetic tone when compared to horses, which have a predominance of vagal tone.

Several studies describe cardiovascular affections in horses, as well as electrocardiographic patterns (Fernandes et al. 2004; Dantas et al. 2014), echocardiographic patterns in the species (Gehlen and Bildheim 2018; Marr 2019; Almeida 2009; Siwinska et al. 2019) in foals (Freccero et al. 2018) also related to weight, sex and age, as well as common changes in the category of athlete animals (Reef et al. 2014). According to the echocardiographic parameters obtained in the present study, donkeys seem to have lower values for these parameters in horses, as described in the literature.

Due Pega donkeys are widely used in work modalities that require physical effort (Proops et al. 2012) we highly recommend echocardiographic and electrocardiographic parameters examination. In recent years, in human and veterinary medicine, modern Doppler echocardiography techniques have been introduced to assess myocardial function by measuring cardiac muscle velocities and deformations. Studies in marathon runners, the effect of training on myocardial deformation parameters, demonstrated that longitudinal myocardial contractility and high early diastolic velocities (E wave) were directly correlated with increased left ventricular diastolic internal diameters (Gehlen and Schalaga 2019). Future studies in donkeys can also be used to assess myocardial function

in order to establish the impact that high workloads can have on the cardiovascular system.

5. CONCLUSIONS

Echocardiographic and electrocardiographic evaluation is feasible in donkeys, and there are parameter similarities described in the equine species. Gender is a factor to be considered when evaluating such parameters. For the analysis and investigation of cardiovascular diseases in the species, it is necessary to evaluate specific parameters for donkeys. The standardization of such parameters can contribute to future studies, aiming to evaluate the influence of exercise on the parameters of this species, since in horses the changes induced by exercise in cardiac electrical conduction are described in the literature, as well as contributing to studies evaluating the heart rate variability in species.

Acknowledgements

The authors want to thank farm Criatório Ximbó, Maristela-SP, Brazil.

Author´s contributions

All authors took part in designing the study. Maria Lucia Gomes Lourenço contributed with conceptualization; Amanda Sarita Cruz Aleixo and Karina Cristina de Oliveira contributed with data curation; Amanda Sarita Cruz Aleixo contributed with formal analysis; Lucas Vinícius de Oliveira Ferreira contributed with investigation; Simone Biagio Chiacchio contributed with methodology; Maria Lucia Gomes Lourenço and Simone Biagio Chiacchio contributed with project administration; Dario Alejandro Cedeño Quevedo contributed with resources and software; Miriam Harumi Tsunemi contributed with statistical analysis; Maria Lucia Gomes Lourenço contributed with supervision and validation; Karina Cristina de Oliveira and Lucas Vinícius de Oliveira

Ferreira contributed with visualization; Amanda Sarita Cruz Aleixo contributed with roles/writing - original draft, writing - review and editing.

Data availability The datasets are available from the corresponding author on reasonable request.

Correspondence

Maria Lucia Gomes Lourenço - School of Veterinary Medicine and Animal Science, Department of Animal Health, UNESP, Botucatu, São Paulo, Brazil;
email: maria-lucia.lourenco@unesp.br Postal code: Rua Prof. Doutor Walter Mauricio Correa, s/n Bairro: Unesp Campus de Botucatu, CEP: 18618-681 - Botucatu, SP; Phone: (14) 3811-6000; Fax: (14) 3815-2343

DECLARATIONS

Ethical approval

The present study was carried out according to the animal welfare standards, approved by the Ethics Committee on the Use of Animals (CEUA) of the Faculty of Veterinary Medicine and Animal Science of the São Paulo State University "Júlio de Mesquita Filho", Botucatu Campus, under the protocol CEUA-0029/2021.

Conflict of interest The authors declare that they have no conflicts of interest.

Consent to participate Not applicable.

Consent for publication Not applicable.

Funding Information

This research did not receive any specific subsidy from funding agencies in the public, commercial or non-profit sectors.

397 **REFERENCES**

398 Al-Haidar A, Farnir F, Deleuze S, Sandersen CF, Leroux AA, Border L, et al (2013)
399 Effect of breed, sex, age and body weight on echocardiographic measurements in the
400 Equine species. Res Vet Sci 95:255–60. doi: 10.1016/j.rvsc.2013.02.014.

401 Almeida LD (2009) Genetic diversity of donkey breeds raised in Brazil, based on the
402 analysis of microsatellite loci and mitochondrial DNA. Dissertation. Faculty of agronomy
403 and veterinary medicine. University of Brasilia, 83p.

404 Burden F, Thiemann A (2015) Donkeys Are Different. J Equine Vet Sci 35:376–82.
405 https://doi.org/10.1016/j.jevs.2015.03.005.

406 Chen Q, Chen Q, Ye Y, Wu R, Wang S, Yao C (2021) Characteristics and Prognosis of
407 Abdominal or Thoracic Aortic Aneurysm Patients Admitted to Intensive Care Units After
408 Surgical Treatment: A Multicenter Retrospective Observational Study. Int. J. Gen. Med
409 14:475–486. https://doi.org/10.2147/IJGM.S296125.

410 Chope KB (2018) Cardiac Cardiovascular Conditions Affecting Sport Horses. Vet. Clin.
411 North Am. Equine Pract 34:409–25. doi: 10.1016/j.cveq.2018.04.001.

412 Costa APB, Pacheco PS (2017) Characterization, insertion and resistance of muares.
413 Nucleus Animalium 9:65-79. doi: 10.3738/21751463.2162.

414 Dantas GN, Lourenço MLG, Santarosa BP, Ulian CMV, Heckler MCT, Carvalho RL et
415 al (2014). Métodos eletrocardiográficos em equinos American Miniature Horse. Cienc
416 Rural 45:848-53. https://doi.org/10.1590/0103-8478cr20140584.

417 Escudero A, González JR, Benedito JL, Prieto FR, Ayala I (2009). Electrocardiographic
418 parameters in the clinically healthy Zamorano-leones donkey. Res Vet Sci 87:458–61.
419 doi: 10.1016/j.rvsc.2009.04.005.

Farag AMM, Ibrahim HMM (2020). Reference Values and Repeatability of B-Mode and M-Mode Echocardiographic Parameters in Healthy Donkey (Equus asinus) - The Guide to Assess Healthy Heart. J. Equine Vet. Sci 88:1-8. doi: 10.1016/j.jevs.2020.102929.

Fernandes WR, Larsson MHMA, Alves ALG, Fantoni DT, Belli CB (2004) Características eletrocardiográficas em equinos clinicamente normais da raça Puro Sangue Inglês. Arq Bras Med Vet Zootec 56:143-49. https://doi.org/10.1590/S0102-09352004000200002.

Freccero F, Cordella A, Dondi F, Castagnetti F, Niinist€o K, Cipone M (2018) Feasibility of the echocardiographic subcostal view in newborn foals: two-dimensional and Doppler aortic findings. Equine Vet. J 50:865–69. doi: 10.1111/evj.12832.

Gehlen H, Bildheim LM (2018) Evaluation of age-dependent changes of myocardial velocity using pulsed wave and colour tissue Doppler imaging in adult warmblood horses. J Anim Physiol Anim Nutr 102:1731–42. doi: 10.1111/jpn.12962.

Gehlen H, Schalaga A (2019) Echocardiographic Evaluation of Myocardial Function in Standardbreds During the First Year of Race Training. J Equine Vet Sci 80:40-8. doi: 10.1016/j.jevs.2019.07.001.

Guccione J, Piantedosi D, Di Loria A, Veneziano V, Ciaramella P (2014) Long-term Electrocardiography Recording with Holter Monitoring in 15 Donkeys. J Equine Vet Sci 34:302–06. https://doi.org/10.1016/j.jevs.2013.07.001

Hassan EA, Torad FA (2015) Two-Dimensional and M-Mode Echocardiographic Measurements in the Healthy Donkey (Equus asinus). J Equine Vet Sci 35:283–89. https://doi.org/10.1016/j.jevs.2015.01.016.

442 Keen JA (2019) Examination of Horses with Cardiac Disease. Vet. Clin. North Am.
443 Equine Pract 35:23–42. doi: 10.1016/j.cveq.2018.12.006.

444 Kobeissi E, Hibino M, Pan H, Aune D (2019) Blood pressure, hypertension and the risk
445 of abdominal aortic aneurysms: a systematic review and meta-analysis of cohort studies.
446 Eur J Epidemiol 34:547–555. doi: 10.1007/s10654-019-00510-9.

447 Loon GV (2019) Cardiac Arrhythmias in Horses. Vet. Clin. North Am. Equine Pract 35:
448 85–102. doi: 10.1016/j.cveq.2018.12.004.

449 Loon G, Pattespm MW (2010) Electrophysiology and arrhythmogenesis. In: Marr CM,
450 Bowen IM. Cardiology of the horse. Toronto: Saunders Elsevier, p. 59-73.

451 Marr CM (2019) Equine Acquired Valvular Disease. Vet. Clin. North Am. Equine Pract
452 35:119–37. doi: 10.1016/j.cveq.2018.12.001.

453 Mendoza FJ, Toribio RE, Perez-Ecija A (2018) Donkey Internal MedicinedPart II:
454 Cardiovascular, Respiratory, Neurologic, Urinary, Ophthalmic, Dermatology, and
455 Musculoskeletal Disorders. J Equine Vet Sci 65:86-97. doi:10.1016/j.jevs.2018.02.025

456 Morrow LD, Smith KC, Piercy RJ, du Toit N, Burden FA, Olmos G, et al (2011)
457 Retrospective analysis of post-mortem findings in 1,444 aged donkeys. J Comp Pathol
458 144:145–56. doi: 10.1016/j.jcpa.2010.08.005.

459 Proops L, Burden F, Osthaus B (2012) Social relations in a mixed group of mules, ponies
460 and donkeys reflect differences in equid type. Behav. Processes 90:337–42. doi:
461 10.1016/j.beproc.2012.03.012.

462 Reef VB (2019) Assessment of the Cardiovascular System in Horses During Prepurchase
463 and Insurance Examinations. Vet. Clin. North Am. Equine Pract 35: 191–204. doi:
464 10.1016/j.cveq.2018.11.002.

465 Reef VB, Bonagura J, Buhl R, McGurrin MKJ, Schwarzwald CC, Van Loon G, et al
466 (2014) Recommendations for Management of Equine Athletes with Cardiovascular
467 Abnormalities. J Vet Intern Med 28:749–61. doi: 10.1111/jvim.12340.

468 Roberts SL, Dukes-McEwan J (2016) Assessment of cardiovascular disease in the
469 donkey: clinical, echocardiographic and pathological observations. Vet. Rec 179:384.
470 doi: 10.1136/vr.103733.

471 Siwinska N, Michalek M, Zak A, Slowikowska M, Noszczyk-Nowak A, Niedzwiedz A,
472 et al (2019) Two-dimensional echocardiographic measurements of the right coronary
473 artery in healthy horses – a pilot study. BMC Vet Res 15- 43. doi: 10.1186/s12917-019-
474 1792-1.

475 Solis CN (2016) Exercising arrhythmias and sudden cardiac death in horses: Review of
476 the literature and comparative aspects. Equine Vet J 48:406–13. doi: 10.1111/evj.12580.

477 Trachsel DS, Giraudet A, Maso D, Hervé G, Hauri DD, Barrey E, et al (2016)
478 Relationships between body dimensions, body weight, age, gender, breed and
479 echocardiographic dimensions in young endurance horses. BMC Vet Res 12:226. doi:
480 10.1186/s12917-016-0846-x.

481

482

483

484

485

486

487 **Table 1.** Clinical parameters (mean, standard deviation, minimum and maximum) in Pega
488 breed donkeys.

Parameter	Mean ± SD	Minimum	Maximum
Age(years)	3.46±3.08	1.00	13.00
HR (bpm)	67.20±16.38	40.00	120.00
RR (mpm)	35.60±9.08	20.00	60.00
T ºC	37.82±0.63	36.60	39.10

489 **Table 2.** Echocardiographic parameters in Pega breed donkeys (mean, standard deviation,
490 minimum and maximum

Parameter	Mean ± SD	Minimum	Maximum
IVSd (cm)	1.74±0.34	1.26	2.59
LVIDd(cm)	6.80±1.08	4.60	9.17
LVFWd (cm)	1.73±0.33	1.17	2.67
IVSs (cm)	3.05±0.55	1.83	4.59
LVIDs (cm)	4.07±0.71	2.45	5.47
LVFWs (cm)	2.59±0.46	1.77	3.84
RIVDd (cm)	1.81±0,61	1.0	3.74
EF (%)	68.82±7.09	53.00	86.00
FS (%)	39.92±5.99	27.90	55.80
LA (cm)	5.27±0.64	4.03	6.51
Ao (cm)	4.03±0.59	2.67	5.14
LA/Ao	1.31±0.14	1.02	1.67
Pulmonary diameter	3.28±0.45	2.25	4.30

Aortic diameter	4.04±0.59	2.70	5.17
Pul./Ao	0.82±0.10	0.66	1.35
Pul.Veloc. (m/s)	91±14.71	64.60	135.00
Pul.Gr. Pres.(mmHg)	3.39±1.11	1.67	7.29
Aortic Veloc. (m/s)	87.60±14.95	60.30	130.60
Ao.Gr. Pres. (mmHg)	3.13±1.06	1.45	6.82

The level of significance was defined as $p < 0.05$. IVSd: IVSd: interventricular septal thickening in diastole; LVIDd: left ventricular internal diameter in diastole; LVFWd: left ventricular free wall thickness in diastole; IVSs: interventricular septal thickening in systole; LVIDs: left ventricular internal diameter in systole; LVFWs: left ventricular free wall thickness in systole; RIVDd: right ventricular diameter in diastole; EF: ejection fraction; FS: fractional shortening of the left ventricle ; LA: left atrial diameter; Ao: internal diameter of the aortic root; LA/Ao: left atrium and aorta diameter ratio; Pul./Ao: Pulmonary and aorta diameter ratio; Pul. Veloc.: Pulmonary velocity; Pres. Gr. Pul.: Pressure gradient between right ventricle and pulmonary artery; Aortic Veloc.: Aortic velocity; Ao. pres. Gr.: Pressure gradient between left ventricle and aorta.

Table 3. Descriptive statistics for echocardiographic measurements and parameters in Pega breed donkeys according to gender (mean, standard deviation, minimum, maximum), males (n=20) and females (n=30).

Parameter	**Mean ± SD (males)**	**Mean ± SD (females)**	**Minimum (males)**	**Minimum (females)**	**Maximum (males)**	**Maximum (females)**	**p-value**
IVSd (cm)	1.81±0.34	1.70±0.34	1.27	1.26	2.29	2.59	0.310
LVIDd(cm)	6.81±1.32	6.79±0.92	4.60	4.89	9.17	9.13	0.934
LVFWd (cm)	1.68±0.26	1.77±0.37	1.27	1.17	2.12	2.67	0.364
IVSs (cm)	3.16±0.59	2.97±0.52	2.46	1.83	4.59	3.99	0.247
LVIDs (cm)	3.96±0.82	4.15±0.62	2.45	3.19	5.44	5.47	0.370

LVFWs (cm)	2.51±0.51	2.64±0.44	1.80	1.77	3.57	3.84	0.361
RIVDd (cm)	2.00±0.64	1.68±0.57	1.26	1.00	3.57	3.74	0.078
EF (%)	71.10±6.18	67.30±7.34	61.00	53.00	86.00	82.00	0.062
FS (%)	41.78±5.44	38.68±6.10	34.00	27.90	55.80	51.90	0.073
LA (cm)	5.42±0.66	5.17±0.62	4.03	4.15	6.51	6.27	0.171
Ao (cm)	4.02±0.62	4.03±0.58	2.67	2.90	5.00	5.14	0.965
LA/Ao	1.35±0.15	1.28±0.12	1.11	1.02	1.67	1.63	0.066
Pulmonary diameter	3.30±0.54	3.27±0.39	2.25	2.66	4.30	4.10	0.787
Aortic diameter	4.11±0.72	3.99±0.50	2.71	2.70	5.17	4.88	0.516
Pul./Ao	0.83±0.13	0.82±0.07	0.71	0.66	1.35	0.98	0.753
Pul.Veloc.(m/s)	89.73±16.00	91.84±14.00	66.80	64.60	135.00	118.40	0.624
Pul.Gr. Pres.(mmHg)	3.31±1.25	3.45±1.02	1.78	1.67	7.29	5.61	0.682
Aortic Veloc. (m/s)	88.83±14.28	86.79±15.57	65.10	60.30	110.50	130.60	0.641
Ao.Gr. Pres. (mmHg)	3.16±1.00	3.10±1.12	1.70	1.45	4.88	6.82	0.853

The level of significance was defined as $p < 0.05$. IVSd: interventricular septal thickening in diastole; LVIDd: left ventricular internal diameter in diastole; LVFWd: left ventricular free wall thickness in diastole; RIVDd: right ventricular diameter in diastole; IVSs: interventricular septal thickening in systole; LVIDs: left ventricular internal diameter in systole; LVFWs: left ventricular free wall thickness in sistole; EF: ejection fraction; FS: fractional shortening of the left ventricle ; LA: left atrial diameter; Ao: internal diameter of the aortic root; LA/Ao: left atrium and aorta diameter ratio; Pul./Ao: Pulmonary and aorta diameter ratio; Pul. Veloc.: Pulmonary velocity; Pres. Gr. Pul.: Pressure gradient between

510 right ventricle and pulmonary artery; Aortic Veloc.: Aortic velocity; Ao. pres. Gr.: Pressure gradient between left ventricle
511 and aorta.

512 **Table 4.** Electrocardiographic parameters in Pega breed donkeys (mean, standard
513 deviation, minimum, maximum), males (n=20) and females (n=30).

Parameter	Mean ± SD	Minimum	Maximum
HR (bpm)	65.00±16.50	35.00	95.00
P (ms)	111.00±18.38	73.00	160.00
P (mV)	0.31±0.05	0.18	0.46
PR (ms)	230.80±41.57	150.00	337.00
QRS (ms)	112.36±15.84	87.00	177.00
R (mV)	0.10±0.02	0.04	0.20
S (mV)	1.90±0.45	0.93	3.03
QT (ms)	432.74±61.12	320.00	573.00
QTc (ms)	442.00±32.90	349.00	538.00
T (ms)	137.58±32.20	80.00	213.00
T (mV)	0.46±0.17	0.23	0.90
RR (ms)	974.36±277.47	630.00	1757.00

514 The level of significance was defined as $p < 0.05$.

515 **Table 5.** Electrocardiographic parameters in Pega breed donkeys according to gender (mean, standard
516 deviation, minimum, maximum), males (n=20) and females (n=30)

Parameter	Mean ± SD (males)	Mean ± SD (females)	Minimum (males)	Minimum (females)	Maximum (males)	Maximum (females)	p-value
HR (bpm)	65.80±18.35	65.83±15.47	35.00	41.00	95.00	95.00	0.994

P (ms)	113.35±19.07	110.66±18.16	87.00	73.00	160.00	147.00	0.618
P (mV)	0.29±0.06	0.33±0.05	0.18	0.25	0.43	0.46	0.017
PR (ms)	230.80±52.37	230.80±33.51	150.00	167.00	337.00	293.00	1.000
QRS (ms)	118.70±19.42	108.00±13.00	87.00	87.00	177.00	133.00	0.019
R (mV)	0.08±0.02	0.11±0.03	0.07	0.04	0.14	0.20	0.003
S (mV)	1.84±0.52	1.94±0.40	0.93	1.37	3.03	2.76	0.493
QT (ms)	431.40±63.28	433.63±60.17	320.00	333.00	567.00	573.00	0.900
QTc (ms)	439.30±37.59	444.90±29.84	379.00	349.00	538.00	492.00	0.564
T (ms)	130.40±32.57	142.36±31.59	97.00	80.00	213.00	200.00	0.201
T (mV)	0.45±0.17	0.47±0.18	0.24	0.23	0.90	0.79	0.778
RR (ms)	1003.25±335.05	955.10±235.76	630.00	633.00	1757.00	1460.00	0.553

517 The level of significance was defined as $p < 0.05$

518 **Table 6.** Electrocardiographic measurements and parameters in male and female Pega donkeys

519 according to age group (< 6 years and > 6 years old).

	Females		**p-value**	**Males**		**p-value**
Parameters ECG	< 6 years (n = 22)	> 6 years (n=8)		< 6 years (n =17)	> 6 years (n = 3)	
HR (bpm)	66.86±15.90 (41.00;95.00)	63.00±14.86 (43.00;87.00)	0.550	71.00±14.43 (50.00;94.00)	36.33±1.15 (35.00;37.00)	0.0007
P (ms)	110.63±17.85 (73.00;147.00)	110.75±20.25 (73.00;140.00)	0.980	112.94±20.16 (87.00;160.00)	115.66±14.01 (100.00;127.00)	0.820
P (mV)	0.32±0.04 (0.25;0.45)	0.35±0.06 (0.29;0.46)	0.070	0.28±0.06 (0.18;0.43)	0.31±0.02 (0.30;0.34)	0.520

PR (ms)	223.27±29.94 (167.00;273.00)	251.50±36.00 (193.00;293.00)	0.030	216.23±39.72 (150.00;273.00)	313.33±37.58 (270.00;337.00)	0.001
QRS (ms)	107.22±10.34 (93.00;127.00)	110.62±14.54 (87.00;133.00)	0.480	115.70±14.88 (87.00;133.00)	135.66±36.14 (110.00;177.00)	0.100
R (mV)	0.11±0.03 (0.04;0.20)	0.11±0.02 (0.07;0.15)	0.930	0.08±0.01 (0.07;0.12)	0.10±0.03 (0.08;0.14)	0.110
S (mV)	2.04±0.40 (1.45;2.76)	1.65±0.28 (1.37;2.06)	0.010	1.80±0.51 (0.93;3.03)	2.09±0.58 (1.43;2.52)	0.380
Q (mV)	0.00±0.00	0.00±0.00	0.00	00.00±0.00	00.00±0.00	0.00
QT (ms)	425.00±59.97 (333.00;573.00)	455.00±61.38 (373.00;540.00)	0.250	413.41±48.49 (320.00;477.00)	533.33±29.72 (510.00;567.00)	0.0007
QTc (ms)	440.00±32.18 (349.00;490.00)	457.00±18.83 (430.00;492.00)	0.180	443.70±38.18 (379.00;538.00)	414.66±26.27 (399.00±445.00)	0.220
T (ms)	138.00±29.57 (80.00;200.00)	153.25±36.42 (113.00;200.00)	0.260	122.23±23.24 (97.00;167.00)	176.66±44.52 127.00;213.00	0.004
T (mV)	0.48±0.18 (0.25;0.79)	0.43±0.20 (0.23;0.70)	0.530	0.42±0.16 (0.24;0.90)	0.63±0.08 (0.55;0.71)	0.056
RR (ms)	943.90±238.66 (633.00;1460.00)	985.87±240.65 (673.00;1327.00)	0.670	884.23±179.94 (630.00;1203.00)	1677.66±68.88 (1633.00;1757.00)	0.000

The level of significance was defined as $p < 0.05$.

Table 7. Echocardiographic measurements and parameters in male and female Pega donkeys according to age group (< 6 years and > 6 years old).

	Females		p-value	Males		p-value
Parameters ECO	< 6 years (n = 22)	> 6 years (n=8)		< 6 years (n=17)	> 6 years (n=3)	
IVSd (cm)	1.66±0.34 (1.26;2.46)	1.83±0.34 (1.44;2.59)	0.24	1.75±0.33 (1.27;2.29)	2.12±0.22 (1.87;2.29)	0.080
LVIDd (cm)	6.41±0.60 (4.89;7.39)	7.81±0.88 (6.28;9.13)	0.0001	6.59±1.27 (4.60;8.37)	8.06±0.96 (7.39;9.17)	0.070
LVFWd (cm)	1.71±0.35 (1.17;2.67)	1.92±0.42 (1.27;2.50)	0.18	1.67±0.26 (1.27;2.12)	1.70±0.29 (1.53;2.04)	0.890
IVSs (cm)	2.88±0.51 (1.83;3.99)	3.23±0.49 (2.52;3.91)	0.10	3.03±0.46 (2.46;3.78)	3.91±0.77 (3.06;4.59)	0.010
LVIDs (cm)	3.90±0.44 (3.19;4.74)	4.82±0.57 (3.74;5.47)	0.0001	3.86±0.84 (2.45;5.44)	4.53±0.42 (4.08;4.93)	0.200
LVFWs (cm)	2.59±0.43 (1.77;3.48)	2.76±0.46 (2.22;3.84)	0.35	2.42±0.47 (1.80;3.46)	3.03±0.46 (2.72;3.57)	0.050
EF (%)	67.68±7.51 (56.00;82.00)	66.25±7.22 (53.00;75.00)	0.64	70.76±6.57 (61.00;86.00)	73.00±3.46 (69.00;75.00)	0.570
FS (%)	38.90±6.33 (30.20;51.90)	38.07±5.78 (27.90;46.00)	0.74	41.45±5.75 (34.00;55.80)	43.63±3.30 (39.90;46.20)	0.530
LA (cm)	5.06±0.59 (4.21;6.24)	5.46±0.67 (4.15;6.27)	0.12	5.32±0.64 (4.03;6.24)	6.02±0.42 (5.70;6.51)	0.090
Ao (cm)	3.88±0.52 (2.90;4.87)	4.45±0.58 (3.36;5.14)	0.015	3.91±0.60 (2.67;4.96)	4.67±0.28 (4.49;5.00)	0.040
LA/Ao	1.30±0.10	1.22±0.14	0.12	1.37±0.16	1.28±0.13	0.400

	(1.14;1.63)	(1.02;1.47)		(1.11;1.67)	(1.17;1.43)	
Pulmonary diameter	3.16±0.34 (2.66;3.84)	3.58±0.39 (2.78;4.10)	0.008	3.20±0.49 (2.25;4.30)	3.91±0.42 (3.44;4.26)	0.030
Aortic diameter	3.92±0.53 (2.70;4.88)	4.20±0.36 (3.52;4.68)	0.17	3.98±0.69 (2.71;5.10)	4.80±0.55 (4.17;5.17)	0.070
Pul./Ao	0.81±0.08 (0.66;0.98)	0.85±0.04 (0.78;0.93)	0.20	0.83±0.14 (0.71;1.35)	0.80±0.04 (0.76;0.84)	0.720
Pul.Veloc. (m/s)	89.35±14.17 (64.00;113.00)	98.67±11.71 (80.00;118.00)	0.10	89.32±16.70 (66.80;135.00)	92.06±13.90 (77.00;104.40)	0.790
Pul.Gr. Pres.(mmHg)	3.27±1.01 (1.67;5.14)	3.94±0.93 (2.61;5.91)	0.11	3.29±1.31 (1.78;7.29)	3.44±1.00 (2.37;4.36)	0.860
Aortic Veloc. (m/s)	88.15±16.07 (61.00;130.00)	83.03±14.39 (60.00;90.00)	0.43	90.70±12.85 (67.30;110.50)	78.23±20.45 (65.10;101.80)	0.160
Ao.Gr. Pres. (mmHg)	3.20±1.19 (1.52;6.82)	2.83±0.93 (1.45;3.76)	0.42	3.27±0.93 (1.81;4.88)	2.56±1.37 (1.70;4.15)	0.270

The level of significance was defined as $p < 0.05$. IVSd: IVSd: interventricular septal thickening in diastole; LVIDd: left ventricular internal diameter in diastole; LVFWd: left ventricular free wall thickness in diastole; IVSs: interventricular septal thickening in systole; LVIDs: left ventricular internal diameter in systole; LVFWs: left ventricular free wall thickness in sistole; RIVDd: right ventricular diameter in diastole; EF: ejection fraction; FS: fractional shortening of the left ventricle ; LA: left atrial diameter; Ao: internal diameter of the aortic root; LA/Ao: left atrium and aorta diameter ratio; Pul./Ao: Pulmonary and aorta diameter ratio; Pul. Veloc.: Pulmonary velocity; Pres. Gr. Pul.: Pressure gradient between right ventricle and pulmonary artery; Aortic Veloc.: Aortic velocity; Ao. pres. Gr.: Pressure gradient between left ventricle and aorta.

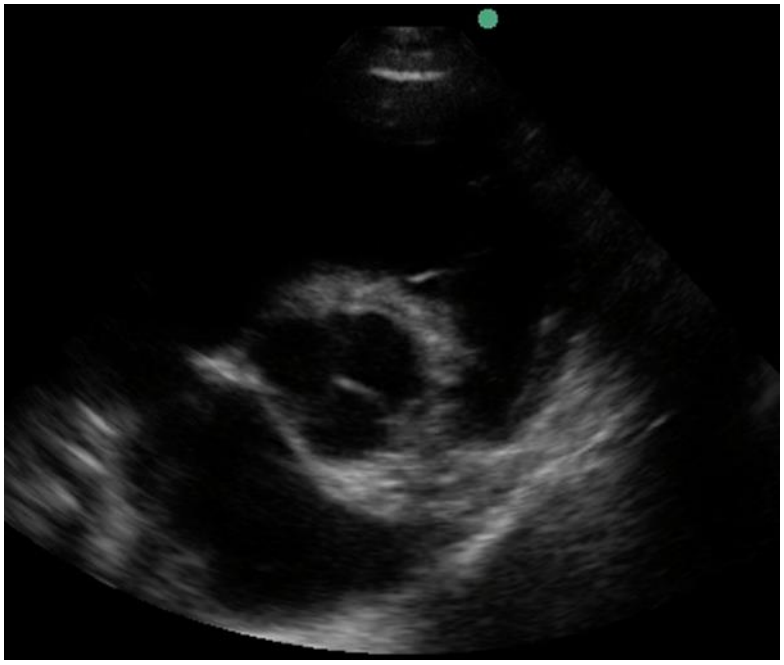

533 Figure 1. Donkey echocardiogram, male, 6 years old, right parasternal window, cross-
534 section, aortic plane.

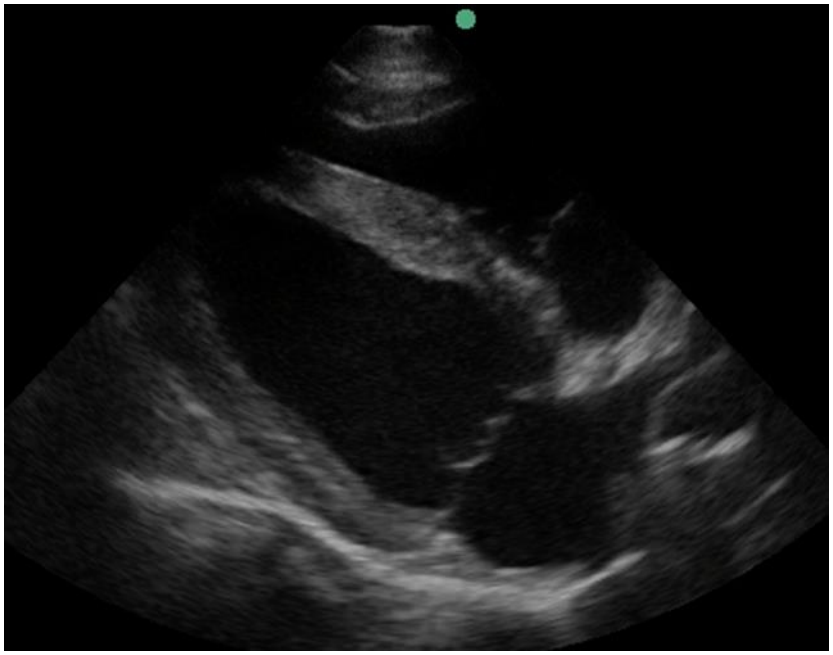

535 Figure 2. Image obtained by the two-dimensional echocardiogram of a donkey, male, 6
536 years old, right parasternal window, four-chamber longitudinal section.

537 Figure 3. Electrocardiogram, donkey, male, 6 years old, base-apex plane, rS pattern.