Hybrid Transcranial Access for Venous Sinus Stenting

Elissa Xian (elissa.xian@gmail.com)
Royal Prince Alfred Hospital https://orcid.org/0000-0003-2020-3166
Angela Li Ching Ng
Thomas Morrison
Rodney Allan

Research Article

Keywords: intracranial hypertension, venous sinus stenting, transcranial venous access, endovascular

Posted Date: March 16th, 2022

DOI: https://doi.org/10.21203/rs.3.rs-1423100/v1

Abstract

Background

There is increasing evidence to demonstrate the use and efficacy of venous sinus angioplasty in select patients with medically refractory idiopathic intracranial hypertension (IIH) and venous sinus stenosis. In patients with challenging venous access, transcranial access to the venous sinus may be required.

Methods

We describe the novel technique of open cranial access for venous sinus stenting and demonstrate that it is safe and effective in the appropriate candidate.

Results and Conclusion

Transcranial venous sinus stenting for IIH has not yet been described in the adult population. It utilises combined open and endovascular techniques, which are safe and effective where distal access is not feasible.

Introduction

Idiopathic intracranial hypertension (IIH) is a neurologic disorder characterised by raised intracranial pressure in the absence of radiological primary cerebral disease. The pathophysiology of the condition is not fully understood but focal venous sinus stenosis of the transverse and sigmoid sinuses have been demonstrated in 30–93% of IIH patients.[12–14] Whilst first-line therapy is focused on weight loss and the use of acetazolamide, further intervention such as endovascular treatment with dural venous sinus stenting can be considered for medically refractory IIH.[11]

Venous angiography demonstrating dural venous sinus narrowing and a focal pressure gradient across the stenotic region greater than or equal to 10mmHg is considered significant and a criteria for stent placement.[3, 6]There is increasing evidence that venous sinus stenting is comparable in terms of efficacy and safety profile to the gold standard CSF diversion procedures such as shunting and optic nerve fenestration.[8, 12, 16] The overall recurrence rate post-stenting is 9.8% and overall rate of major complications, including intracranial haemorrhage is 1.9%.[12]

Venous access for venous sinus stenting procedures is generally accomplished via the common femoral vein however standard endovascular techniques may be unsuitable in patients with vascular aberrations. Whilst transcranial access for endovascular procedures has been described, there is a scarcity of cases in the literature addressing a transcranial approach to venous sinus stenting for difficult venous access. We describe the technique of accessing the superior sagittal sinus via craniotomy for transverse sinus stenting for venogenic idiopathic intracranial hypertension.

Technical Description / Methods

A 22-year-old female presented with papilledema from idiopathic intracranial hypertension. Her time-of-flight MRI demonstrated left sided transverse sinus stenosis and hypoplasia of the right transverse sinus (Fig. 1.). She had undergone bilateral optic nerve fenestrations but had ongoing visual deterioration despite the procedure. She had no other remarkable past medical history and informed consent was obtained for all procedures.

Imaging: Venography was performed under minimal sedation and confirmed a significant stenosis in the left dominant transverse sinus likely secondary to a large arachnoid granulation. The stenosis measured approximately 40 mm, at around 25 mm from the torcular. Manometry demonstrated a significant pressure differential, revealing a pressure of 44mmHg in the superior sagittal sinus, 33mmHg in the anterior transverse sinus and 20mmHg at the jugular bulb.

Treatment: The patient was commenced on dual antiplatelet therapy (aspirin 300mg dispersible and ticagrelor 90mg twice daily) 10 days prior to the procedure. Post venous manometry, general anaesthesia was administered and systemic heparinization undertaken. Attempts were then made to pass multiple configurations of guiding catheters up to the level of the left transverse sinus stenosis. Due to kinking of her left jugular bulb, it was not possible to access the stenosed transverse sinus with the shuttle sheath or pass the planned stent to that location. A contralateral approach was undertaken and again it was not possible to gain access to the stenosis through this non-dominant hypoplastic transverse sinus. Access was removed and compression was undertaken to close the femoral vein.

Transcranial access and stenting

After discussion with the patient, a transcranial approach to stenting was agreed upon a week following the initial transfemoral attempt. She remained on dual antiplatelet therapy prior to intervention. After general anaesthetic, the patient was positioned supine on the operating table in Mayfield pin fixation in a hybrid operating theatre. Stealth registration was undertaken. Under neuro-navigation, a 2cm craniotomy was performed over the superior sagittal sinus, which was then accessed using an 18G percutaneous vascular access needle (Fig. 3). A Bentson wire was passed into the left transverse-sigmoid junction and a 6 French shuttle sheath was advanced across the stenosis (Fig. 4). Multiple venograms were obtained and ultimately a 7mm x 60mm EverFlex stent (Medtronic, Dublin, Ireland), was deployed without incident. A post-stenting venogram demonstrated satisfactory stenting across the stenotic segment (Fig. 5).

The superior sagittal sinus was closed with a single 6 – 0 prolene suture and reinforced with Duragen. The dura was approximated with vicryl sutures and bone flap replaced prior to layered closure of the scalp.

The patient made an uneventful post-operative recovery. She remained on dual antiplatelet agents immediately post operatively. At 6 weeks follow up, the patient’s headaches had resolved with improvement of her papilledema.

Discussion

There is paucity of data describing patients with anatomical anomalies that preclude them from undergoing a typical trans-femoral approach. Variations in venous anatomy are common and should be noted when treating venous sinus pathology. Transverse sinus asymmetry, hypoplasia, aplasia and arachnoid granulations have been previously described with left side anomalies being more common than right.[9] Goyal et. al reported 33.1% rate of asymmetry in their patients with unilateral hypoplasia in 26.8% and aplasia in 4.8%. 1.6% demonstrated bilateral hypoplasia.[5] McCormick et. al. reported 79% of their cadaveric cases showed sinus luminal aberration with septations and blind pouches.[10]

Alternate approaches for variant venous anatomy include upper limb venous access, contralateral access and direct transcranial access. Ramos et. al. have described a successful approach utilising the upper limb brachial or basilic vein as an alternative for patients who may have higher groin complications.[15] A contralateral approach has also been demonstrated as a safe substitute for those patients where antegrade stenting is not feasible.[4] However these approaches do not address the cases where patients have anatomically aberrant intracranial venous systems that do not allow for peripheral access. In this case, a contralateral approach via femoral approach was also attempted without success due to a hypoplastic contralateral sinus.

Transcranial access for endovascular procedures have been described, particularly in the case of embolization for dural arteriovenous malformations.[1] However to our knowledge, there has been no documented description of a transcranial sinus access technique to stent an adult patient.

Technical considerations include the precision in placement of the craniotomy, which can be attempted under fluoroscopic guidance or neuro-navigation techniques.[1, 2] This was accomplished via neuro-navigation in our case and allowed for accurate cannulation of the superior sagittal sinus. There is no consensus in the literature regarding size of craniotomy to allow for successful cannulation as larger craniotomies to a single burr hole have been described.[2, 7] It is also pertinent to counsel the patient regarding the increased risk of performing a craniotomy whilst on dual antiplatelet therapy and the theoretical likelihood of increased bleeding.

There are infrastructural limitations, as a hybrid operating theatre with high quality fluoroscopy will be required to safely execute this procedure. Houdart et. al. reported a subdural bleed as a complication of the only case in their series where the endovascular procedure was not performed in an angiography suite.[7] The case can also be performed with a multidisciplinary team consisting of a neurosurgeon and neurointerventionalist where a dual-trained proceduralist is not available.

Conclusion

Utilising combined open surgical and endovascular techniques for transcranial venous sinus stenting is safe and effective where transvenous stenting is required but distal access is not feasible. A

multidisciplinary team consisting of a neurosurgeon and neurointerventionalist where a dual-trained proceduralist is not available should be considered.

Declarations

Funding

No funding was received for this research.

Conflict of Interest

The authors declare that there is no conflict of interest

All authors certify that they have no affiliations with or involvement in any organization or entity with any financial interest (such as honoraria; educational grants; participation in speakers' bureaus; membership, employment, consultancies, stock ownership, or other equity interest; and expert testimony or patent-licensing arrangements), or non-financial interest (such as personal or professional relationships, affiliations, knowledge or beliefs) in the subject matter or materials discussed in this manuscript.

Author Contributions

All authors contributed to the study conception and design. The first draft of the manuscript was written by E Xian and all authors commented on previous versions of the manuscript. All authors read and approved the final manuscript.

Ethical Standards and Informed Consent

All procedures performed in studies involving human participants were in accordance with the ethical standards of the institutional and/or national research committee and with the 1964 Helsinki declaration and its later amendments or comparable ethical standards

Informed consent was obtained from all individual participants included in the study and informed consent was provided for publication of images.

References

1. Abaunza-Camacho J, Vergara-Garcia D, Perez F, Benavides C, Portilla F, Riveros W, et al. Direct transcranial coil and Onyx embolization of a dural arteriovenous fistula: Technical note and brief literature review. Journal of Clinical Neuroscience. 2020;80:232-7.
2. Caplan JM, Kaminsky I, Gailloud P, Huang J. A single burr hole approach for direct transverse sinus cannulation for the treatment of a dural arteriovenous fistula. Journal of NeuroInterventional Surgery. 2015;7(2):e5.

3. Case D, Seinfeld J, Roark C, Kumpe D. Idiopathic Intracranial Hypertension: Contemporary Management and Endovascular Techniques. Semin Intervent Radiol. 2020;37(2):175-81.
4. Gordon W, Abraham M. Contralateral approach to transverse-sigmoid sinus stenting. Interventional neuroradiology : journal of peritherapeutic neuroradiology, surgical procedures and related neurosciences. 2020;26(5):658-63.
5. Goyal G, Singh R, Bansal N, Paliwal VK. Anatomical Variations of Cerebral MR Venography: Is Gender Matter? Neurointervention. 2016;11(2):92-8.
6. Higgins JN, Cousins C, Owler BK, Sarkies N, Pickard JD. Idiopathic intracranial hypertension: 12 cases treated by venous sinus stenting. J Neurol Neurosurg Psychiatry. 2003;74(12):1662-6.
7. Houdart E, Saint-Maurice JP, Chapot R, Ditchfield A, Blanquet A, Lot G, et al. Transcranial approach for venous embolization of dural arteriovenous fistulas. J Neurosurg. 2002;97(2):280-6.
8. Koovor JM, Lopez GV, Riley K, Tejada J. Transverse venous sinus stenting for idiopathic intracranial hypertension: Safety and feasibility. Neuroradiol J. 2018;31(5):513-7.
9. Massrey C, Altafulla JJ, Iwanaga J, Litvack Z, Ishak B, Oskouian RJ, et al. Variations of the Transverse Sinus: Review with an Unusual Case Report. Cureus. 2018;10(9):e3248.
10. McCormick MW, Bartels HG, Rodriguez A, Johnson JE, Janjua RM. Anatomical Variations of the Transverse-Sigmoid Sinus Junction: Implications for Endovascular Treatment of Idiopathic Intracranial Hypertension. Anat Rec (Hoboken). 2016;299(8):1037-42.
11. Mollan SP, Davies B, Silver NC, Shaw S, Mallucci CL, Wakerley BR, et al. Idiopathic intracranial hypertension: consensus guidelines on management. Journal of Neurology, Neurosurgery & Psychiatry. 2018;89(10):1088.
12. Nicholson P, Brinjikji W, Radovanovic I, Hilditch CA, Tsang ACO, Krings T, et al. Venous sinus stenting for idiopathic intracranial hypertension: a systematic review and meta-analysis. J Neurointerv Surg. 2019;11(4):380-5.
13. Owler BK, Parker G, Halmagyi GM, Dunne VG, Grinnell V, McDowell D, et al. Pseudotumor cerebri syndrome: venous sinus obstruction and its treatment with stent placement. Journal of Neurosurgery. 2003;98(5):1045-55.
14. Puffer RC, Mustafa W, Lanzino G. Venous sinus stenting for idiopathic intracranial hypertension: a review of the literature. J Neurointerv Surg. 2013;5(5):483-6.
15. Ramos AD, Sundararajan S, Santillan A, Schwarz JT, Patsalides A. Single arm access venous sinus stenting (SAVeS) technique: Technical note. Interventional neuroradiology : journal of peritherapeutic neuroradiology, surgical procedures and related neurosciences. 2020;26(4):501-5.
16. Starke RM, Wang T, Ding D, Durst CR, Crowley RW, Chalouhi N, et al. Endovascular Treatment of Venous Sinus Stenosis in Idiopathic Intracranial Hypertension: Complications, Neurological Outcomes, and Radiographic Results. The Scientific World Journal. 2015;2015:140408.

Figures

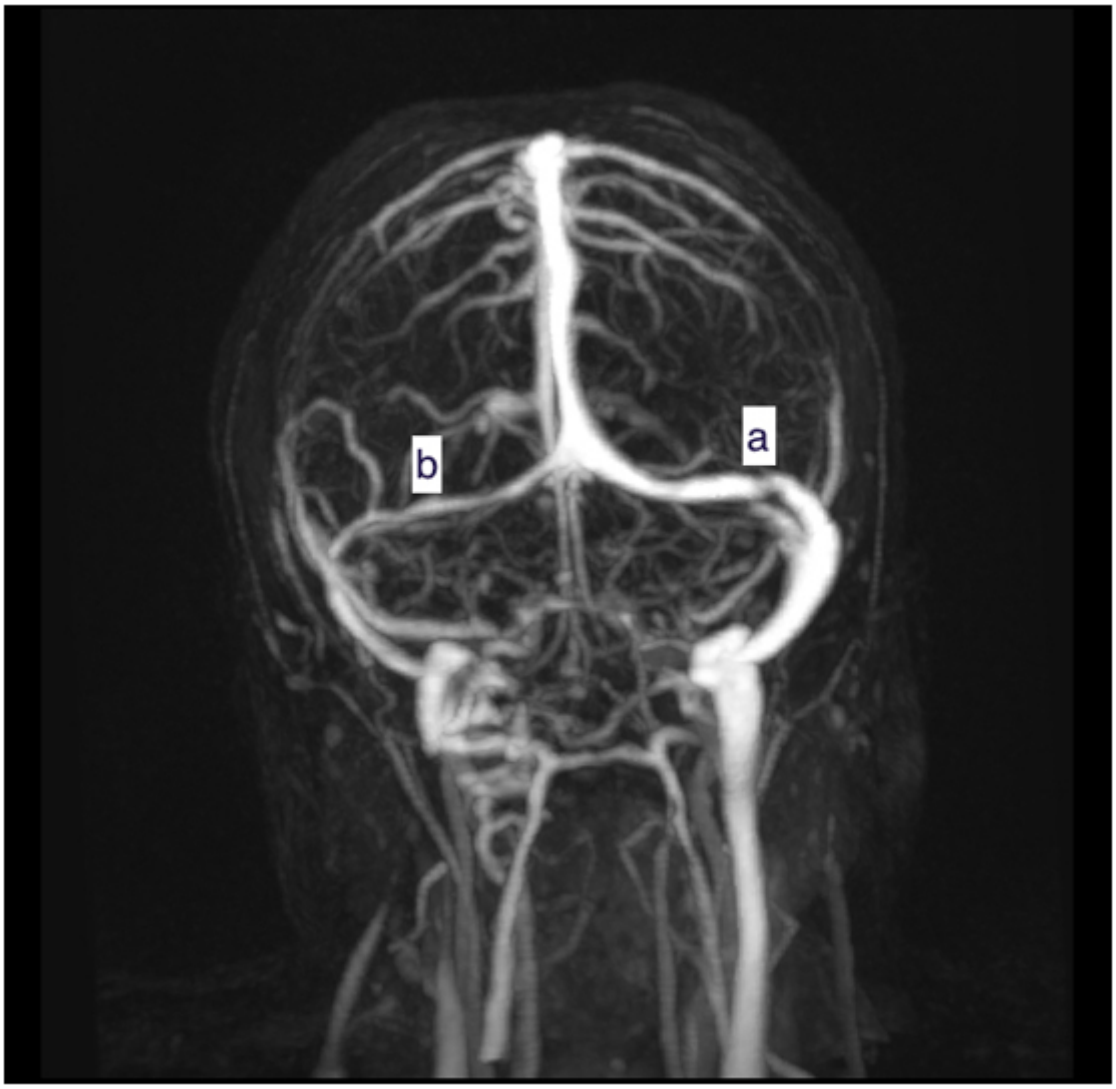

Figure 1

MR-Venogram demonstrating left transverse sinus stenosis (a) and right transverse sinus hypoplasia (b)

Figure 2

Wire within the left jugular vein demonstrating tortuosity of the vein making it difficult to access the left transverse sinus stenosis.

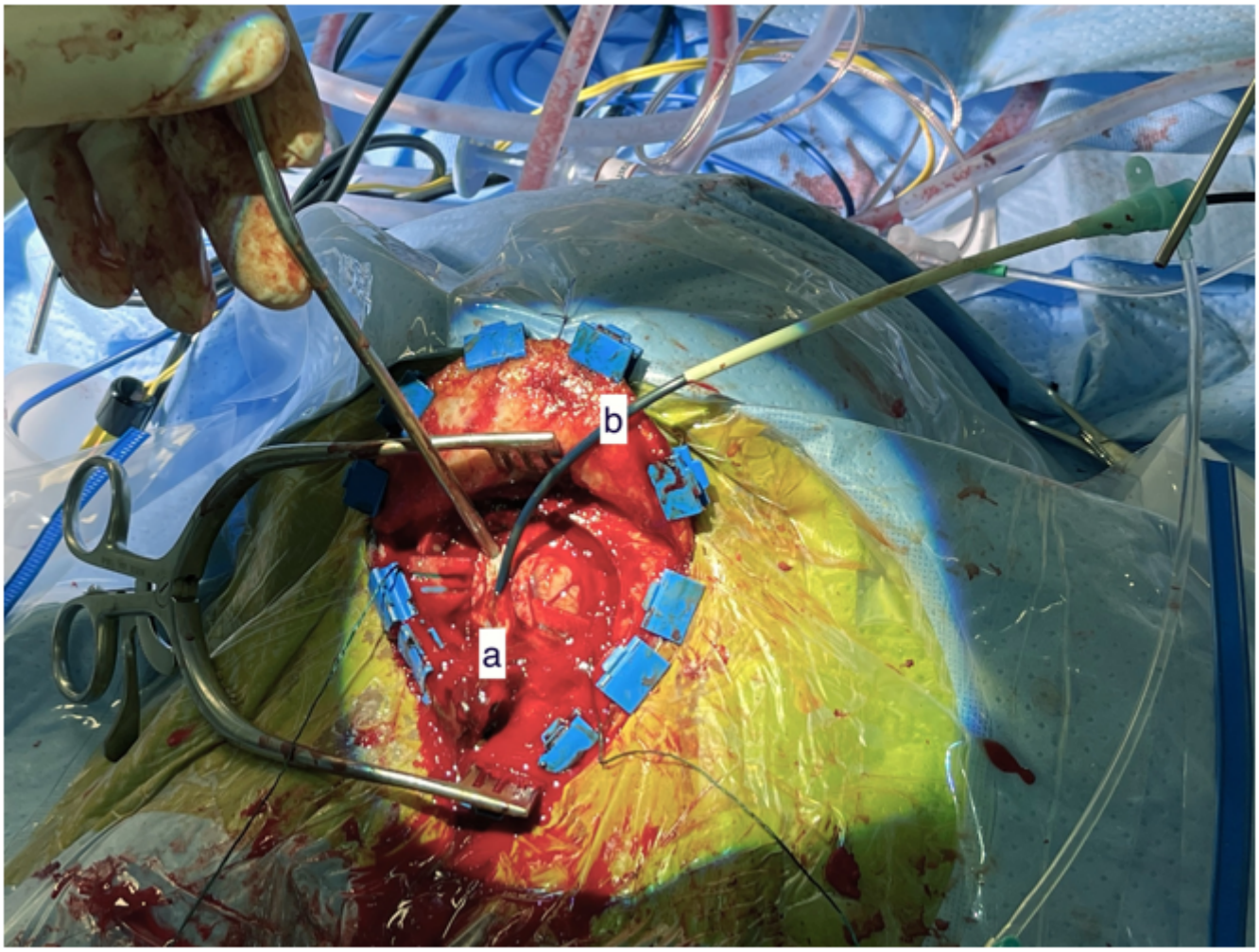

Figure 3

Cranial access image demonstrating a 2cm craniotomy over the superior sagittal sinus(a), the dura is opened. A 6 French shuttle sheath is shown cannulating the superior sagittal sinus (b).

Figure 4

Pre stent venogram via 6 French intracranial sinus catheter demonstrating left transverse sinus stenosis

Figure 5

Post stent venogram demonstrating angioplasty across stenotic segment