Preoperative orbital CT scan findings in patients with nasolacrimal duct obstruction and its impact on surgical planning

Abdolreza Medghalchi
Guilan University of Medical Sciences
Yousef Alizadeh
Guilan University of Medical Sciences
Maryam Dourandeesh (maryam.dourandeesh.dl@gmail.com)
Guilan University of Medical Sciences
Sima Fallah Arzpeima
Guilan University of Medical Sciences
Reza Soltani-Moghadam
Guilan University of Medical Sciences
Mitra Akbari
Guilan University of Medical Sciences
Sara Khadem
Guilan University of Medical Sciences
Ehsan Kazemnejad
Guilan University of Medical Sciences

Research Article

Keywords: nasolacrimal duct obstruction, dacryocystorhinostomy, computerized tomography, endoscopic dacryocystorhinostomy, external dacryocystorhinostomy

Posted Date: April 11th, 2022

DOI: https://doi.org/10.21203/rs.3.rs-1423529/v1

Abstract

Objective

External dacryocystorhinostomy (DCR) failure is sometimes due to pathologies located within the nasal cavity. Preoperative computerized tomography (CT) scan is useful in the assessment of nasolacrimal drainage and adjacent anatomical structures; however, it is not routinely performed before DCR. The present study evaluates abnormal findings in CT scans of patients with nasolacrimal duct obstruction (NLDO) and its effect on changing treatment approaches.

Methods

This prospective descriptive cross-sectional study included 162 patients with NLDO. All the patients underwent a supine axial CT scan. Patients with signs of rhinosinusitis, sinus mucositis, nasal septal deviation, nasal polyps or masses, and turbinate deformities were referred to an otolaryngologist. The rest of the patients underwent external DCR. The demographics and radiologic characteristics of the patients undergoing CT scans and their effect on changing treatment approaches were evaluated.

Results

The study participants included 162 patients with a mean ± SD age of 62.5 ± 14.0 years (age range of 35–93 years). The percentage of endonasal DCR in cases with an abnormal nasal cavity on CT scan was almost 30% higher compared to those without this problem (59.6% vs. 30.2%). Septum deviation and turbinate deformity led to 3.6-fold and 3.9-fold changes in the surgical approach, respectively.

Conclusion

A significant association existed between the sinonasal pathologies in patients with NLDO and changing surgical approach. It is believed that a preoperative CT scan is necessary to detect such pathologies and manage them appropriately.

Introduction

The most common cause of epiphora or dacryocystitis is nasolacrimal duct obstruction (NLDO). Dacryocystorhinostomy (DCR) is the preferred procedure to treat NLDO. This treatment is performed in two ways, external DCR and endoscopic DCR. The success rate of these two methods is almost equal.[1–3] One of the causes of failure in external DCR is pathologies located within the nasal cavity which include middle turbinate abnormalities (concha bullosa, lateralization, hypertrophy), ostium problems (closed, small, or too high ostium), mucosal abnormalities (intranasal adhesions, contact granuloma, scar formation, rhinosinusitis, and pouch formation known as sump syndrome), nasal wall abnormalities

(preceding maxillofacial trauma, ipsilateral septal deviation, lateral nasal wall scarring) and aggernasi over pneumatization.[4–8]

However, a preoperative CT scan is useful in the assessment of nasolacrimal drainage and adjacent

anatomical structures; although, it is not routinely performed before DCR. The importance of preoperative imaging in these patients is indicated by several reasons including the evaluation of bony anatomy surrounding the lacrimal outflow system to recognize bony erosions, knowledge of anatomical variants, diagnosis of contributing factors to nasolacrimal obstruction (such as septal deviation, turbinate malposition, and sinusitis), and recognition of malignancies or other mucosal abnormalities.[9, 10]

This study aimed to evaluate the abnormal findings in CT scans of patients with NLDO and their effect on changing treatment approaches.

Methods

This prospective descriptive–cross-sectional study included 162 patients, diagnosed with NLDO using conventional irrigation tests or obvious signs of nasolacrimal duct obstruction (such as purulent regurgitation) from March 2019 to March 2020. The study was approved by the Ethics Committee of Guilan University of Medical Sciences (IR.GUNS.REC.1397.255) and adheres to the tenets of the declaration of Helsinki and informed consent was obtained from all subjects and/or their legal guardian(s). Patients with a previous history of DCR, trauma, nasal and orbital surgery, lid abnormalities, ocular surface diseases, and facial nerve palsy were excluded from the study.

Data collection was performed using demographic characteristics form which included such information as patient’s gender, history of sinonasal diseases, and previous facial fractures. All patients underwent detailed examinations for the eyelid, ocular surface, punctum, and tear film conditions. In addition, all the patients underwent supine axial imaging using a multi-detector (8-slice) CT scanner (General Electric, USA) with images obtained at 1.0-mm intervals. All CT images of patients were interpreted by a radiologist for the abnormalities within the nasolacrimal drainage system and around the orbit.

Demographics and radiologic characteristics of patients were analyzed on CT scans findings, which included the abnormalities of orbit, sinus, and other facial structures. Patients with abnormal findings assessed by preoperative CT scan nasal septal deviation (Fig. 1), turbinate deformity (Fig. 2), mucocele, nasal polyp, inflammation around the lacrimal sac, signs of chronic rhinosinusitis, soft tissue opacity in the nasolacrimal duct (Fig. 3), previous fracture, and suspicious mass (Fig. 4) were referred to an otolaryngologist. If the otolaryngologist recommended endonasal DCR, the procedure was performed accordingly in ENT service. The rest of the patients underwent external DCR.

Statistical analysis:

Data were analyzed using SPSS software (version 21.0). Descriptive statistics were presented with mean ± standard deviation and 95% confidence interval. However, the analytic statistics were presented with the chi-square test and fisher's exact test. A Chi-square test was used to compare the approaches of surgery according to CT scan findings. The multivariant logistic backward LR method was used for multiple variant analysis. A p-value less than 0.05 was considered statistically significant.

Results

This study was conducted on 162 patients with the mean ± SD age of 62.5 ± 14.0 years (age range of 35–93 years) and the majority of patients were female (n = 103, 63.6%). 16.0% (n = 26) of patients stated a history of nasal and sinus diseases. Moreover, 64.2% of the patients had positive regurgitation test and 35.8% showed nasolacrimal duct obstruction in irrigation test.

Abnormal CT scan findings on the same side of NLD were detected in 115 (71%) patients. These abnormal findings included abnormal nasal cavity (61.1%) including nasal septal deviation, turbinate deformity, mucocele, and nasal polyp, inflammation around lacrimal sac (23.5%), signs of chronic rhinosinusitis (15.4%), soft tissue opacity in the nasolacrimal duct (6.8%), previous fracture (1.9%) and suspicious mass (0.6%) (Table 1).

Table 1
Summary of CT scan findings

CT scan findings	No. of patients (%) *
Abnormal nasal cavity	99 (61.1)
Nasal septal deviation	60 (37)
turbinate deformity	58 (35.8)
Mucocele	6 (3.7)
Nasal polyp	4 (2.5)
Periocular inflammation (including cellulitis or dacryocystitis)	38 (23.5)
Signs of chronic rhinosinusitis	25 (15.4)
Soft tissue opacity in the nasolacrimal duct	11 (6.8)
Previous fracture	3 (1.9)
Suspicious mass	1 (0.6)
* Some patients had more than one finding	

The percentage of turbinate deformity in females was almost twice that of males (47.7% vs 23.7%, P = 0.009). Soft tissue opacity in the nasolacrimal duct was observed in 10.7% of females; however, none of

the males had this finding. No difference was found between genders in other abnormal CT scan findings.

The percentage of endonasal DCR in patients with an abnormal nasal cavity on CT scan was almost 30% higher compared to those without this problem (59.6% vs. 30.2%). Patients with nasal polyps, turbinate deformity, and septal deviation needed endonasal DCR more than others, which is statistically significant (100% vs 46.8%, 62.1% vs 40.4%, and 63.3% vs 39.2%, respectively) (Table 2).

Table 2
Frequency distribution of type of surgery according to CT scan findings in patients with lacrimal duct obstruction.

		approach of surgery			
		External DCR NO (%)	Endonasal DCR NO (%)	Total NO (%)	p
Chronic rhinosinusitis	Yes	(9)36.0%	(16)64.0%	(25)100.0%	0.085
	No	(75)54.7%	(62)45.3%	(137)100.0%	
Periorbital inflammation	Yes	(24)63.2%	(14)36.8%	(38)100.0%	0.111
	No	(60)48.4%	(64)51.6%	(124)100.0%	
Suspected mass	Yes	(0)0.0%	(1)100.0%	(1)100.0%	0.298
	No	(84)52.2%	(77)47.8%	(161)100.0%	
Abnormal nasal cavity	Yes	(40)40.4%	(59)59.6%	(99)100.0%	< 0.001
	No	(44)69.8%	(19)30.2%	(63)100.0%	
Septal deviation	Yes	(22)36.7%	(38)63.3%	(60)100.0%	0.003
	No	60.8% (62)	(40)39.2%	(102)100.0%	
Nasal polyp	Yes	(0)0.0%	(4)100.0%	(4)100.0%	0.036
	No	(84)53.2%	(74)46.8%	(158)100.0%	
Mucocele	Yes	(2)33.3%	(4)66.7%	(6)100.0%	0.355
	No	(82)52.6%	(74)47.4%	(156)100.0%	
Turbinate deformity	Yes	(22)37.9%	(36)62.1%	(58)100.0%	0.008
	No	(62)59.6%	(42)40.4%	(104)100.0%	
Previous fracture	Yes	(3)100.0%	(0)0.0%	(3)100.0%	0.092
	No	(81)50.9%	(78)49.1%	(159)100.0%	
soft tissue opacity in the nasolacrimal duct	Yes	(6)54.5%	(5)45.5%	(11)100.0%	0.853
	No	(78)51.7%	(73)48.3%	(151)100.0%	

Given the logistic regression model (backward LR method), the variables leading to the change of surgical approach in patients with NLDO included septal deviation (P = 0.001), and turbinate deformity (P = 0.001). Septal deviation and turbinate deformity led to 3.6-fold and 3.9-fold changes in the surgical approach respectively. The rate of endonasal DCR in patients with a history of nasal and sinus diseases was seven times more than those without such a history.

Discussion

Pathologies located within the nasal cavity are a cause of external DCR failure. Although a preoperative CT scan is useful in the assessment of nasolacrimal drainage and adjacent anatomical structures, it is not routinely performed before DCR.[4–10]The present study evaluates abnormal findings in CT scans of patients with NLDO and its effect on changing treatment approaches.

The majority of patients (n = 162) enrolled in this study were female (63.6% female vs 36.4% male) Which was consistent with previous studies.[11, 12] Dimensions of the bony nasolacrimal canal, middle nasolacrimal duct, and lower nasolacrimal fossa were smaller in females. In addition, acute angle between the bony canal and the nasal floor in females predisposes them to chronic inflammation of the nasolacrimal drainage system and consequent NLDO. All these anatomical differences can justify the greater prevalence of NLDO among females.[13–17] Furthermore, the results of the present study showed that turbinate deformity was more common in females, which might be another reason for the higher prevalence of NLDO in females.

In this study, abnormal CT scan finding on the same side of NLDO was detected in 71% of the participants which was similar to the results of the study conducted by Yazici et al. (70%). This rate was lower than that obtained in the studies performed by Kallman et al. (87%) and Habesoglu et al. (95.1%).[18, 19] However, a lower rate (57.3%) of abnormal CT scan findings has been reported by Choi et al. which may be due to racial and anatomical variations in different countries.

It should be noted that the most common abnormal finding in this study was nasal septal deviation (37%) followed by turbinate deformity (35.8%) and periocular inflammation (23.5%). In a study carried out by Choi et al., soft tissue opacity in NLDO was reported as the most common (85.9%) abnormal CT finding, which could be attributed to the upright position of patients during CT scans since a high percentage of patients without NLDO (81.7%) showed this abnormality.[10] Loftus et al. and Czyz et al. reported NLD opacity in approximately 70% of the normal population. Czyz et al. showed that air was present more fully in the upright rather than supine position.[16, 17] In the present study, all CT scans were performed in a supine position which can justify the lower percentage of soft tissue opacity in NLD (6.8%).

Nasal septal deviation as the most common CT scan finding in this study was observed in 37% of the cases which was comparable to that in studies conducted by Kallman et al. (39%),[18, 19]though less than that in the studies performed by Habesoglu et al., Sefı et al. and Yazici et al. (64.6%, 65%, and 70% respectively).[19, 20] On the other hand, the rate of patients with nasal septal deviation in Choi et al. and Kaplama et al. studies was lower than that in the current study (11.9% and 27.4% respectively).[10, 21] The nasal septal deviation was the first and second abnormal CT scan findings in the studies carried out by Kaplama et al. and Habesoglu et al, respectively.[19, 20] These differences can be explained by racial and anatomical differences, different imaging indications, and different criteria for the interpretation of abnormal CT scan findings.

In this study, septum deviation and turbinate deformity caused 3.6-fold, and 3.9-fold changes in the surgical approach, respectively. Habesoglu et al. and Kallman et al. reported a higher prevalence of sinonasal pathologies in patients with NLDO compared to those in the control group. Moreover, they reported a higher rate of nasal septal deviation in these patients compared to those in the control group.[18, 19] In the study performed by Habesoglu et al, it has been reported that the incidence of inferior turbinate hypertrophy and maxillary sinusitis was higher in patients with NLDO than in the control group, which was in line with the results obtained in the study conducted by Sefı et al study.[19] The results of the studies conducted by Yazici et al., Lee et al., and Taban et al. were indicative of the correlation between the side of the septal deviation with the side of NLDO.[20, 22–23] On the other hand, based on the results of the previous studies, DCR failure may be due to the untreated existing sinonasal pathologies, such as nasal septum and concha bullosa pathologies.[19, 21] The high percentage of nasal and sinus pathologies in the present study and the role of these conditions in the development of NLDO and the rate of recurrence following DCR could be the reason for changing the surgical approach in a significant number of patients.

In the present study, chronic sinusitis did not lead to a change in the surgical approach. The reason for this difference might be the presence of sinusitis in sinuses not adjacent to the nasolacrimal duct or the resolution of sinusitis by medical treatment. Habesoglu et al. showed that maxillary sinusitis was more common in patients with NLDO; however, they did not find any relationship between the presence of ethmoidal sinusitis and NLDO.[19] The sinuses were not evaluated separately in this study, therefore, no association was found in this regard.

Abnormal CT scan finding was detected in 71% of patients in the present study. The percentage of endonasal DCR was almost 30% higher in cases with an abnormal nasal cavity on CT scan than those without these problems (59.6% vs. 30.2%) which highlights the importance of performing CT scans for surgical planning. Numerous studies supported the performance of CT scans before surgery in all cases of acquired nasolacrimal obstruction. However, some arguments oppose this. Moreover, a CT scan can recognize bony anatomy surrounding the lacrimal outflow system, anatomical variants, factors contributing to nasolacrimal obstruction (such as septal deviation, turbinate malposition, and sinusitis), and malignancies or other mucosal abnormalities.[9,10.21] However, there are some limitations regarding the application of CT scans. Intrinsic tumors of the lacrimal outflow tract may not be evident on a CT scan. The positive predictive value of the test is low for neoplasia as the cause of lacrimal outflow obstruction. Radiation exposure and cost are other concerns in this regard.[24, 25] It is worth mentioning that there are several ideas about the importance of imaging in a patient with nasolacrimal duct obstruction.

Regarding the limitations of the present study, one can refer to the limited number of patients. Moreover, the effect of sinonasal surgery was not evaluated on the surgical outcome, which should be considered in future studies.

Conclusion

Based on the obtained results, a significant association was observed between the sinonasal pathologies in patients with NLDO and changing the surgical approach. Therefore, a preoperative CT scan seems to be necessary to detect and manage such pathologies.

Declarations

Ethical approval and Consent for publication

The study was approved by Guilan University Of Medical Sciences ethics review board and was conducted in accordance with the Declaration of Helsinki with the code of IR.GUNS.REC.1397.255**. Informed consent was obtained from all subjects and/or their legal guardian(s).**

Consent for publication

Not applicable.

Availability of data and materials

The datasets used and analysed during the current study are available from the corresponding author on reasonable request.

Competing interests

All authors declare that they have no conflict of interest.

Funding

This research is not funded from any organization and the interest is academic

Authors' contributions

Abdolreza Medghalchi, Yousef Alizadeh, Maryam Dourandeesh and Sima Fallah Arzpeima wrote the main manuscript text and Reza Soltani-Moghadam, Mitra Akbari and Sara khadem prepared figures 1-4, Ehsan Kazem Nezhad did statistical issues and All authors reviewed the manuscript

Acknowledgements

We thank the patients participating in this study and all staff at the hospital for their contributions to this study

References

1. Karim R, Ghabrial R, Lynch TF, Tang B. A comparison of external and endoscopic endonasal dacryocystorhinostomy for acquired nasolacrimal duct obstruction. Clin Ophthalmol (Auckland, NZ). 2011;5:979.

2. Simon GJ, Joseph J, Lee S, Schwarcz RM, McCann JD, Goldberg RA. External versus endoscopic dacryocystorhinostomy for acquired nasolacrimal duct obstruction in a tertiary referral center. Ophthalmology. 2005;112:1463–8.
3. Medghalchi A, Mohammadi MJ, Moghadam RS, Dalili H. Results of nasolacrimal duct probing in children between 9–48 months. Acta Med Iran. 2014:52;545–51.
4. Elmorsy SM, Fayk HM. Nasal endoscopic assessment of failure after external dacryocystorhinostomy. Orbit. 2010;29:197–201.
5. Hull S, Lalchan SA, Olver JM. Success rates in powered endonasal revision surgery for failed dacryocystorhinostomy in a tertiary referral center. phthalmic Plast Reconstr Surg. 2013;29:267–71.
6. Liang J, Hur K, Merbs SL, Lane AP. Surgical and anatomic considerations in endoscopic revision of failed external dacryocystorhinostomy. Otolaryngol Head Neck Surg. 2014;150:901–5.
7. Paik JS, Cho WK, Yang SW. Comparison of endoscopic revision for failed primary external versus endoscopic dacryocystorhinostomy. Clin Exp Ophthalmol. 2013;41:116–21.
8. Yarmohammadi ME, Ghasemi H, Jafari F, Pupak I, Nadoushan MJ, Saghari chin N. Teamwork endoscopic endonasal surgery in failed external dacryocystorhinostomy. J Ophthalmic Vis Re. 2016;11:282.
9. Freitag SK, Roos JC. Preoperative imaging should be performed prior to surgery in all cases of acquired nasolacrimal obstruction–Yes. Eye. 2017;31:351–2.
10. Choi SC, Lee S, Choi HS, Jang JW, Kim SJ, Lee JH. Preoperative computed tomography findings for patients with nasolacrimal duct obstruction or stenosis. Korean J Ophthalmol: KJO. 2016;30:243.
11. Lee-Wing MW, Ashenhurst ME. Clinicopathologic analysis of 166 patients with primary acquired nasolacrimal duct obstruction. Ophthalmology. 2001;108:2038–40.
12. Nemet AY, Vinker S. Associated morbidity of nasolacrimal duct obstruction—a large community based case–control study. Graefes Arch Clin Exp Ophthalmol. 2014;252:125–30.
13. Groessl SA, Sires BS, Lemke BN. An anatomical basis for primary acquired nasolacrimal duct obstruction. Arch Ophthalmol. 1997;115:71–4.
14. Shigeta KI, Takegoshi H, Kikuchi S. Sex and age differences in the bony nasolacrimal canal: an anatomical study. Archives of ophthalmology. 2007;125:1677–81.
15. Janssen AG, Mansour K, Bos JJ, Castelijns JA. Diameter of the bony lacrimal canal: normal values and values related to nasolacrimal duct obstruction: assessment with CT. AJNR Am J Neuroradiol. 2001; 22:845–50.
16. Loftus WK, Kew J, Metreweli C. Nasolacrimal duct opacity on CT. Br J Radiol. 1996;69:630–1.
17. Czyz CN, Bacon TS, Stacey AW, et al. Nasolacrimal system aeration on computed tomographic imaging: effects of patient positioning and scan orientation. Clin Ophthalmol (Auckland, NZ). 2015;9:469.
18. Kallman JE, Foster JA, Wulc AE, Yousem DM, Kennedy DW. Computed tomography in lacrimal outflow obstruction. Ophthalmology. 1997;104:676–82.

19. Habesoglu M, Eriman M, Habesoglu TE, Kinis V, Surmeli M, Deveci I. Co-occurrence and possible role of sinonasal anomalies in primary acquired nasolacrimal duct obstruction. J Craniofac Surg. 2013;24:497–500
20. Yazici H, Bulbul E, Yazici A,Kaymakci M, Tiskaoglu N, Yanik B,etal, Primary acquired nasolacrimal duct obstruction: is it really related to paranasal abnormalities?. Surg Radiol Anat. 2015;37:579–84.
21. Kaplama ME, Ak S, Doblan A. Primary Endoscopic Dacryocystorhinostomy: Concomitant Sinonasal Pathologies, Either Cause of Disease/or Cause of Recurrence. Allergy. 2020;3:59–63.
22. Lee JS, Lee H, Kim JW, Chang M, Park M, Baek S. Association of facial asymmetry and nasal septal deviation in acquired nasolacrimal duct obstruction in East Asians. J Craniofac Surg. 2013;24:1544–8.
23. Taban M, Jarullazada I, Mancini R, Hwang C, Goldberg RA. Facial asymmetry and nasal septal deviation in acquired nasolacrimal duct obstruction. Orbit. 2011;30:226–9.
24. Lefebvre DR, Freitag SK. Update on imaging of the lacrimal drainage system. Semin Ophthalmol. 2012; 27:175–186.
25. Roos JC, Ezra DG, Rose GE. Preoperative imaging should be performed for all cases of acquired nasolacrimal duct obstruction—No. Eye. 2017;31:349–50.

Figures

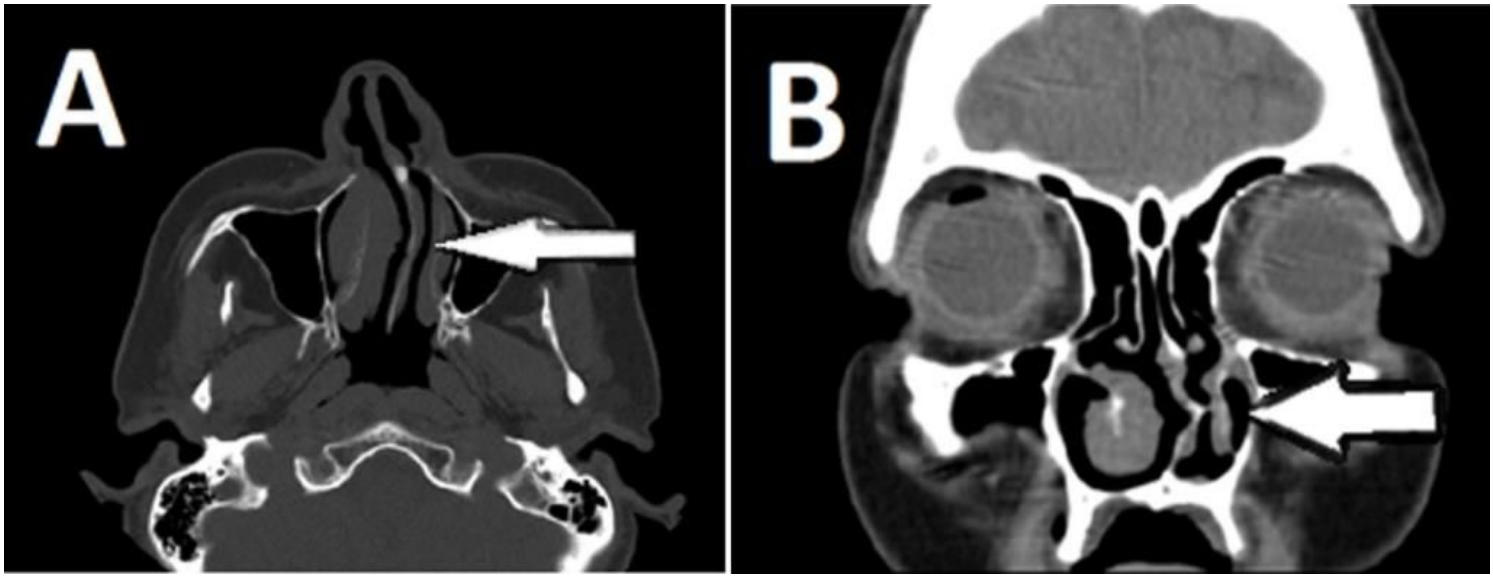

Figure 1

Paranasal CT scan in axial (A) and coronal (B)sections: left convex nasal septal deviation associated with adhesion to left lateral inferior turbinate.

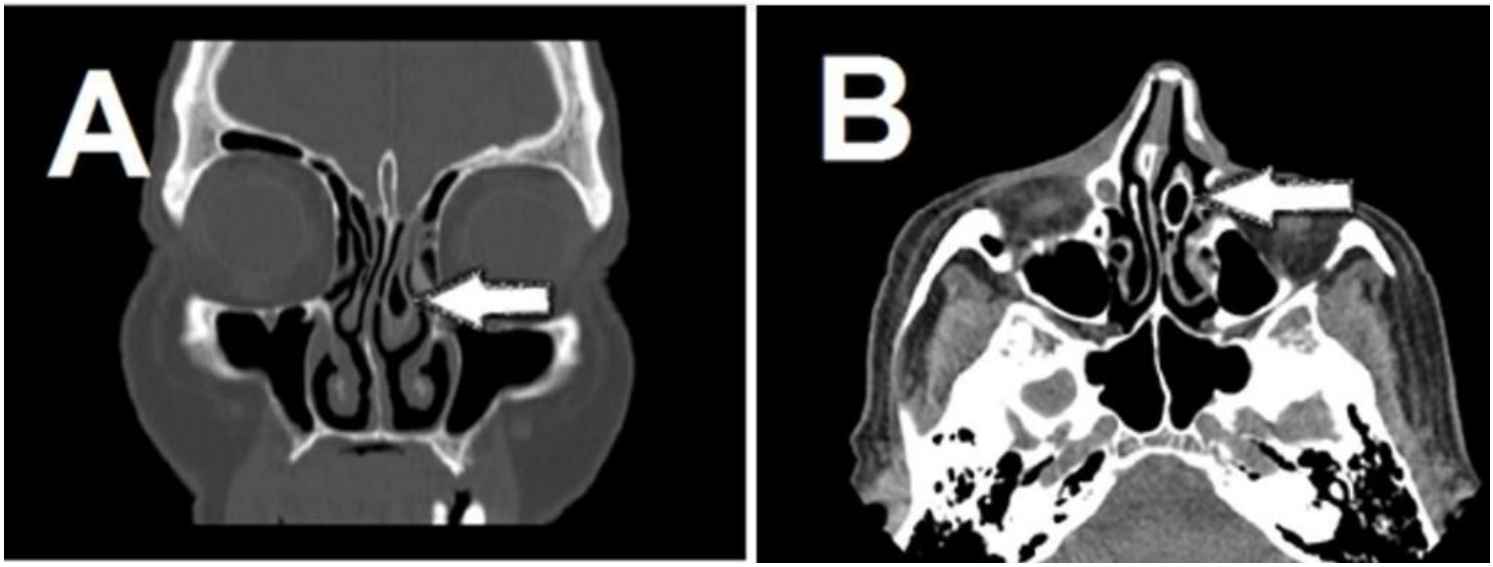

Figure 2

Paranasal CT scan in axial (A) and coronal (B) sections: Left-sided concha bullosa as middle turbinate pneumatization is evident. A slightly right-sided deviation of the nasal septum is obvious (A).

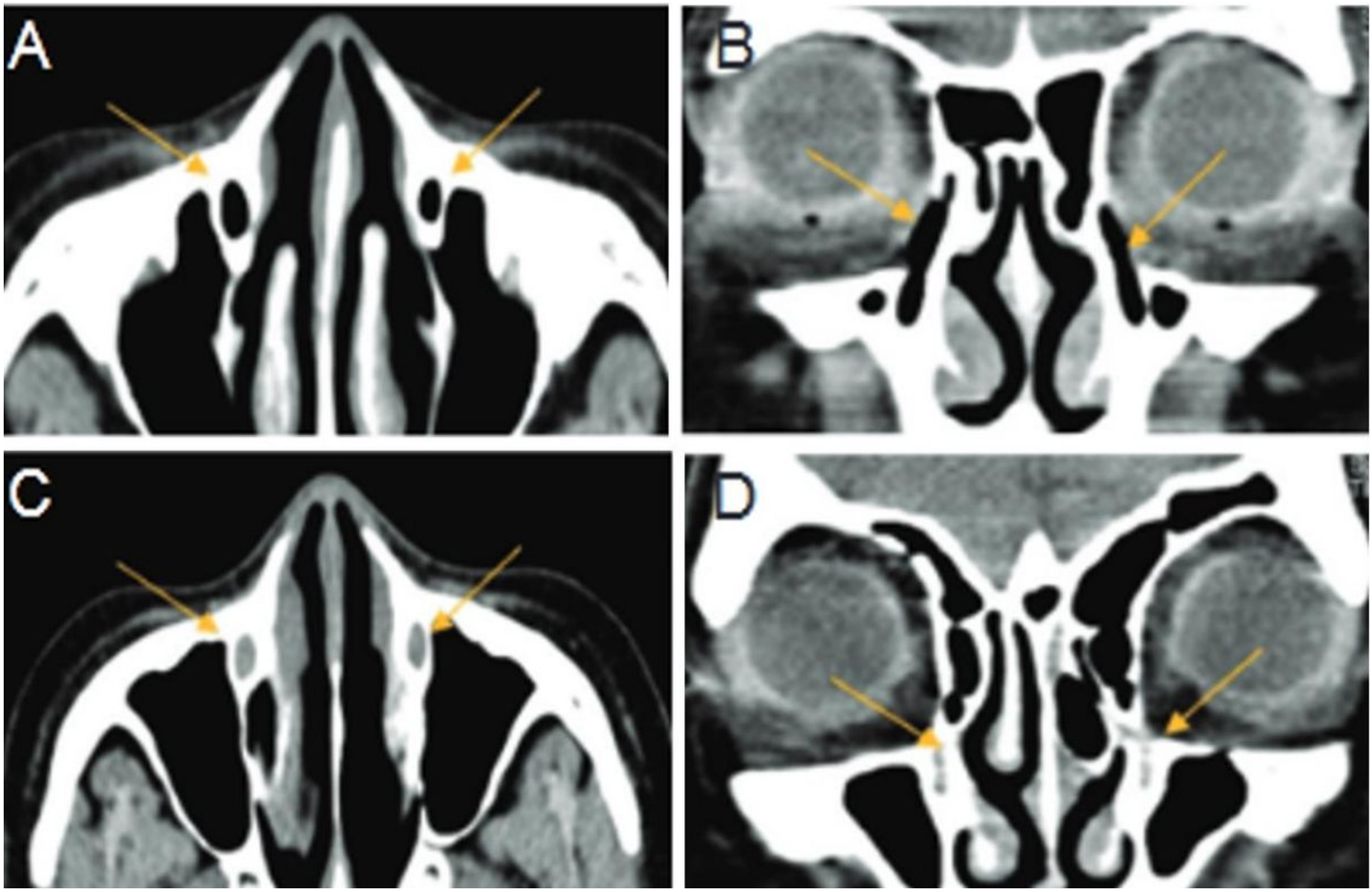

Figure 3

Paranasal CT scan in axial (A, C) and coronal (B, D) sections: normal nasolacrimal duct, air content (A and B). Soft tissue opacity was noted in nasolacrimal ducts on each side (C). Both ostiomeatal complexes are occluded (D).

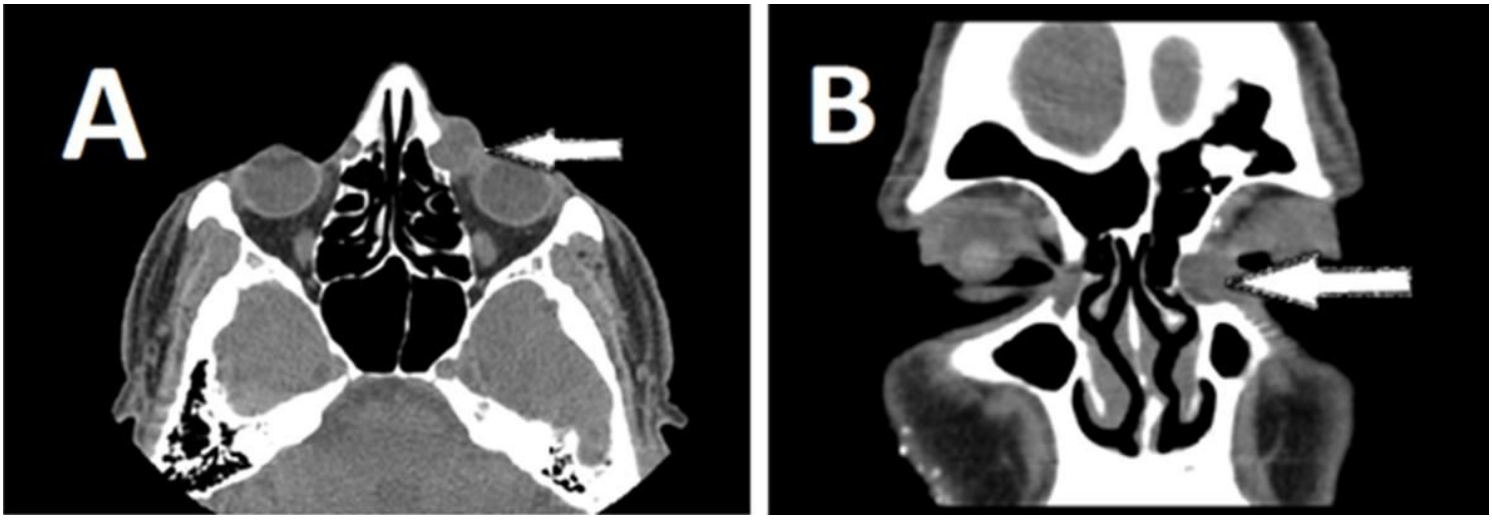

Figure 4

Paranasal CT scan in axial (A) and coronal (B) sections: a hypodense medial epicanthal mass (fluid density) centered over the left lacrimal sac with preseptal soft tissue stranding.