

Anticoagulation for Left Ventricular Thrombi Secondary to COVID – Is Three Months Too Long?: A Case Report

Rimmy Garg (✉ rimmy.p.garg@gmail.com)

University of Illinois College of Medicine Peoria

Amitoj Sachdeva

University of Illinois College of Medicine Peoria

Juan Del Cid Fratti

University of Illinois College of Medicine Peoria

Samuel Mortoti

OSF Healthcare Cardiovascular Institute

Case Report

Keywords: Left ventricle thrombi, COVID, anticoagulation, STEMI

Posted Date: March 11th, 2022

DOI: <https://doi.org/10.21203/rs.3.rs-1424864/v1>

License:  This work is licensed under a Creative Commons Attribution 4.0 International License.

[Read Full License](#)

Abstract

Background: Venous and arterial thromboembolic events are common sequelae of COVID-19 infection. However, there are no set guidelines as to the appropriate duration of anticoagulation for such thrombotic events.

Case Presentation: A 62-year-old woman presented with chest pain 2 weeks after she was diagnosed with COVID-19. She was found to have an anterior STEMI with a thrombotic occlusion of the left anterior descending artery as well as multiple left ventricular (LV) thrombi. The patient was treated with guideline directed medical therapy for acute coronary syndrome. As for the LV thrombi, she was bridged from heparin to warfarin with plan to continue anticoagulation for a minimum of 3 months; however, she was noted to have resolution of the thrombi in 2 months with no subsequent recurrence.

Conclusion: In the setting of an acute myocardial infarction with apical akinesis, an LV thrombus is not uncommon. In such cases, ACC/AHA recommends oral anticoagulation (OAC) for 3 months while ESC recommends OAC for up to 6 months. There have been no large studies looking at the optimal duration for OAC for LV thrombi due to COVID-19. Given resolution of the thrombi in our patient within 2 months, we suggest a shorter length of anticoagulation for such cases guided by echocardiographic imaging. However, prospective data regarding this matter is first needed.

Background

COVID-19 has been associated with venous and arterial thromboembolic disease likely due to potent local and systemic cytokine production with subsequent platelet activation, thrombin stimulation, and fibrin deposition [1]. Such thromboembolic disease is treated with anticoagulation but there are no guidelines to direct the types and duration of oral anticoagulation. We present a case of COVID-associated acute coronary syndrome (ACS) and left ventricular thrombi with resolution of the thrombi within 2 months of warfarin initiation.

Case Presentation

A 62-year-old female with a past medical history of hypertension, hyperlipidemia, and tobacco use presented with left-sided chest pain with radiation to the left arm that started the night prior to admission. She was recently diagnosed with mild COVID-19 infection two weeks earlier and was treated conservatively as an outpatient. She, nor her family, has any history of coronary artery disease, heart failure, or any arrhythmias. She was found to be tachycardic but with a regular rhythm and an otherwise normal physical exam.

Laboratory data was notable for an elevated troponin of 31.2 ng/ml (reference: < 0.028 ng/ml) and elevated aspartate aminotransferase of 177 U/L. Electrolytes and an arterial blood gas values were within normal range.

ECG demonstrated ST elevations in leads II, III, aVF as well as V3-V5 with ST depression in aVL (Fig. 1). With a diagnosis of anterior and inferior myocardial infarction, patient was taken emergently for a left heart catheterization (LHC).

LHC showed a thrombotic occlusion of the proximal subsection of the distal left anterior descending (LAD) coronary artery with evidence of organized thrombus, judged by the difficulty in passing a wire across (Fig. 2A, Video 1). Multiple balloon dilatations as well as multiple rounds of aspiration with a penumbra catheter were attempted and intracoronary eptifibatid was administered with restoration of TIMI 2 flow (Fig. 2B, Video 2). Given the presence of organized clot, decision was to treat medically. The patient otherwise had non-obstructive disease of the other coronaries. A LHC was repeated 2 days later to see if the thrombus had resolved and stent could be placed. However, there was still residual thrombus in the distal LAD, unchanged from prior study (Fig. 2C). As patient was chest pain free and hemodynamically stable, no further intervention was attempted. A transthoracic echocardiogram (TTE) was performed, demonstrating apical akinesis with left ventricular (LV) ejection fraction of 39% by Simpson's biplane method, as well as multiple large, mobile LV thrombi with a maximum size of 2cm x 1.5cm (Fig. 3A-B, Videos 3–9).

With systolic dysfunction in the setting of STEMI, the patient was maintained on aspirin, ticagrelor, atorvastatin, metoprolol succinate, spironolactone, and losartan. She was additionally started on a heparin drip with bridge to warfarin in setting of multiple large LV thrombi. Given the size and number of thrombi and associated increased risk of stroke, cardiac surgery was consulted for potential surgical LV thrombus evacuation. Surgical intervention was not recommended due to high risk of complications in the setting of recent ACS, and plan was to continue medical management.

It was thought that the LAD as well as LV thrombi were secondary to the patient's recent COVID infection. At time of discharge, aspirin was discontinued. Ticagrelor was to be continued for a year and warfarin for at least 3 months based on resolution of thrombi.

Our patient followed up with cardiology and had a repeat TTE 2 months after hospital discharge. This TTE showed that there was a large apical aneurysm of the LV but no evidence of any thrombi in the apex (Fig. 4, Videos 10–13). The ejection fraction was still low around 35%. Warfarin was continued at this time due to lack of contrast with the last TTE study, but discontinued 3.5 months later when a repeat TTE with contrast showed that the LV remained unchanged with no evidence of thrombi (Fig. 5, Videos 14–16).

Discussion And Conclusion

Cardiac manifestations of COVID-19 ACS are due to coronary thrombosis or acute plaque rupture from systemic inflammation and catecholamine surge [2, 3]. For ACS due to plaque rupture, it is recommended that dual anti-platelet therapy and full-dose anticoagulation be administered in the acute setting per the American College of Cardiology (ACC)/American Heart Association (AHA) and the European Society of Cardiology (ESC) guidelines [4]. There are currently no specific guidelines on the anticoagulant used or

the duration of anticoagulation in the setting of coronary thrombosis and/or LV thrombosis related to COVID-19.

As LV thrombus is not an uncommon complication of an acute myocardial infarction, the 2013 ACC/AHA STEMI guidelines recommend oral anticoagulation (OAC) use in setting of STEMI with anterior apical akinesis or dyskinesis to prevent the thrombus formation for 3 months, aiming for a lower international normalized ratio (INR) of 2.0-2.5 [5]. The 2017 ESC STEMI guidelines recommend OAC for up to 6 months with final duration guided by a repeat TTE, risk of bleeding, and need for concomitant antiplatelet therapy [6]. The ACTION Study Group also concluded that anticoagulation for LV thrombus for at least 3 months was associated with a lower risk of major cardiovascular events or all-cause mortality [7].

There have not been any large prospective or direct comparison studies looking at direct OAC (DOAC) versus warfarin for treatment of LV thrombus. One metaanalysis did show that DOACs appear to be non-inferior to warfarin without any statistical difference in stroke or bleeding complications when treating for LV thrombus [8].

There have been cases that reported resolution of the LV thrombus in the setting of COVID-19 infection prior to the 3-month mark. One reported resolution on a 1-month follow-up TTE while on warfarin [9] while another reported resolution at 10 days on low molecular weight heparin [10]. Our patient had a large LV thrombus burden that resolved within 2 months with warfarin use.

As such, a shorter duration of anticoagulation under close supervision should be considered in patients with COVID-19 related cardioembolic/thrombotic events, guided by echocardiographic imaging. Such imaging would require a thorough sweep of the left ventricle in on-axis and off-axis views so as to not miss any residual thrombi. Prospective data about proper OAC regimen and duration is still needed.

Declarations

Ethics Approval and Consent to Participate

As this was a case report with de-identified patient information, an IRB approval was not needed.

Consent for Publication

The patient from this case graciously consented to the publication of this manuscript.

Availability of Data and Materials

Not Applicable

Competing Interests

The authors of this manuscript have no competing financial or non-financial competing interests.

Funding

This case report was not funded.

Authors' Contributions

All authors contributed equally to the preparation of this manuscript, including literature review, writing, acquiring images, and final review. All authors have read and approved the final manuscript.

Acknowledgement

The authors acknowledge the patient's generosity in allowing us to publish this case.

Authors' Information

Not applicable

References

1. Ortega-Paz L, Capodanno D, Montalescot G, Angiolillo DJ. Coronavirus disease 2019 – associated thrombosis and coagulopathy: review of the pathophysiological characteristics and implications for antithrombotic management. *J Am Heart Assoc.* Feb 2021; 10(3):e019650.
2. Xiong TY, Redwood S, Prendergast B, Chen M. Coronaviruses and the cardiovascular system: acute and long-term implications. *Eur Heart J.* 2020 May 14;41(19):1798–1800.
3. Dominguez-Erquicia P, Dobarro D, Raposeiras-Roubín S, Bastos-Fernandez G, Iñiguez-Romo A. Multivessel coronary thrombosis in a patient with COVID-19 pneumonia. *Eur Heart J.* 2020 Jun 07;41(22):2132.
4. Bikdeli B, Madhavan M, Jimenez D, et al. COVID-19 and thrombotic or thromboembolic disease: implications for prevention, antithrombotic therapy, and follow-up: JACC State-of-the-Art review. *J Am Coll Cardiol.* June 2020;75(23):2950–73.
5. O'Gara PT, Kushner FG, Ascheim DD, et al. 2013 ACCF/AHA Guideline for the Management of ST-Elevation Myocardial Infarction: a report of the American College of Cardiology Foundation/American Heart Association task force on practice guidelines. *Circulation.* 2013;127(4):362–425.
6. Ibanez B, James S, Agewall S, et al; ESC Scientific Document Group. 2017 ESC Guidelines for the management of acute myocardial infarction in patients presenting with ST-segment elevation: the task force for the management of acute myocardial infarction in patients presenting with ST-segment elevation of the European Society of Cardiology (ESC). *Eur Heart J.* 2018;39(2):119–177.
7. Lattuca B, Bouziri N, Kerneis, et al. Antithrombotic therapy for patients with left ventricular mural thrombus. *J Am Coll Cardiol.* 2020;75:1676–1685.

8. Dalia, T., Lahan, S., Ranka, S, et al. Warfarin versus direct oral anticoagulants for treating left ventricular thrombus: a systematic review and meta-analysis. *Thrombosis J.* 2021; 19:7. <https://doi.org/10.1186/s12959-021-00259-w>
9. Jeon HD, Patel J, Priester T, Moten M. Left ventricular thrombus caused by COVID-19: how long to treat? *J Am Coll Cardiol.* May 2021; 77 (18_Supplement_1) 2013.
10. Sonaglioni A, Albin A, Nicolosi GL, et al. Case report: an unusual case of biventricular thrombosis in a COVID-19 patient With ischemic dilated cardiomyopathy: assessment of mass mobility and embolic risk by tissue doppler imaging. *Front Cardiovasc Med.* 2021 Jul 29;8:694542.

Figures

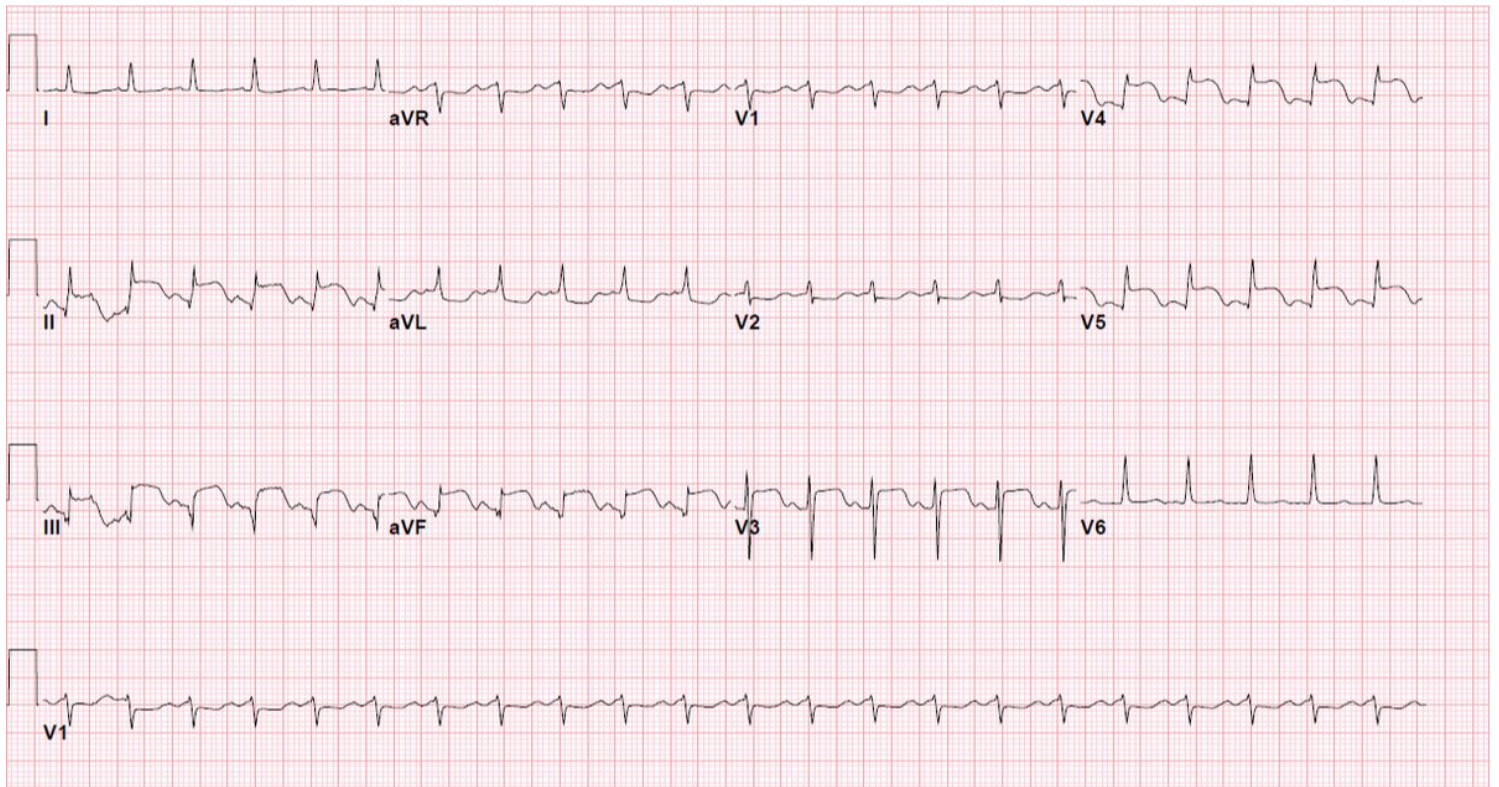


Figure 1

EKG demonstrating ST elevations in leads II, III, aVF as well as V3-V5 with ST depression in aVL

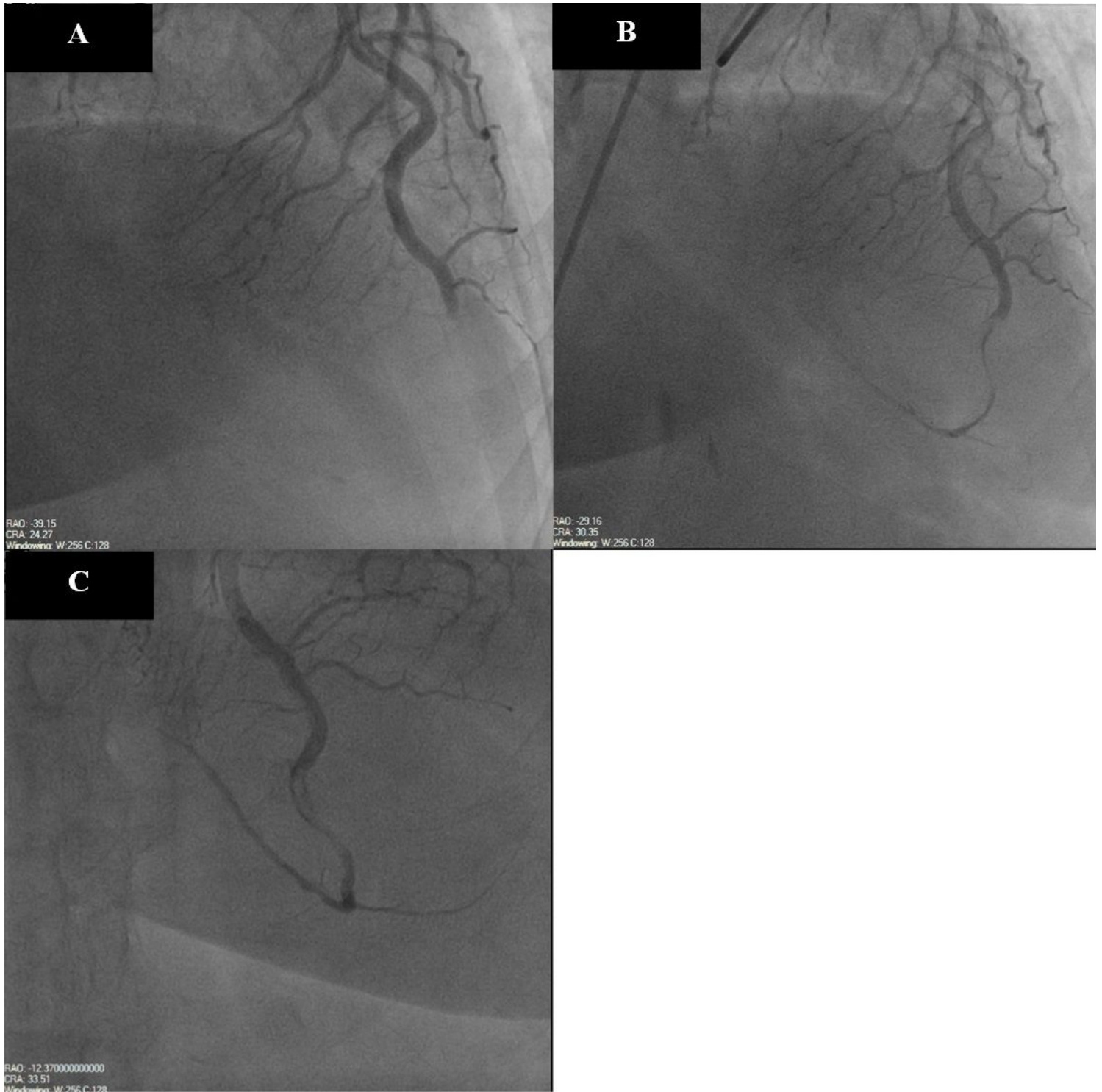


Figure 2

A- Thrombotic occlusion of the proximal subsection of the distal LAD with evidence of organized thrombus. **B -** Occluded LAD after PCI with restoration of TIMI 2 flow. **C -** Persistently occluded LAD two days after PCI.

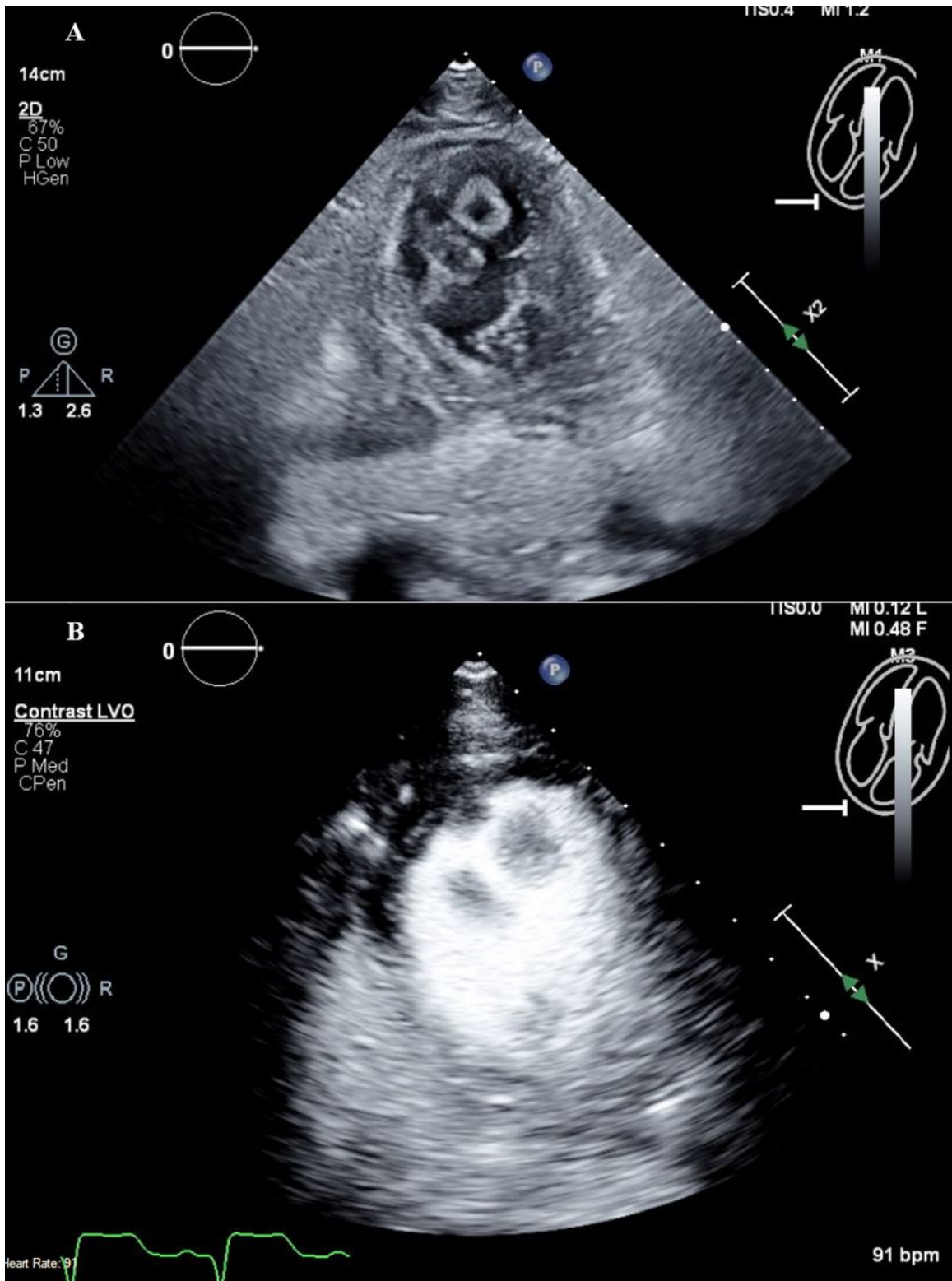


Figure 3

A - TTE without contrast at the off-axis apical 4 chamber view demonstrating multiple LV thrombi. **B** - TTE with contrast at the off-axis apical 4 chamber view demonstrating multiple LV thrombi.

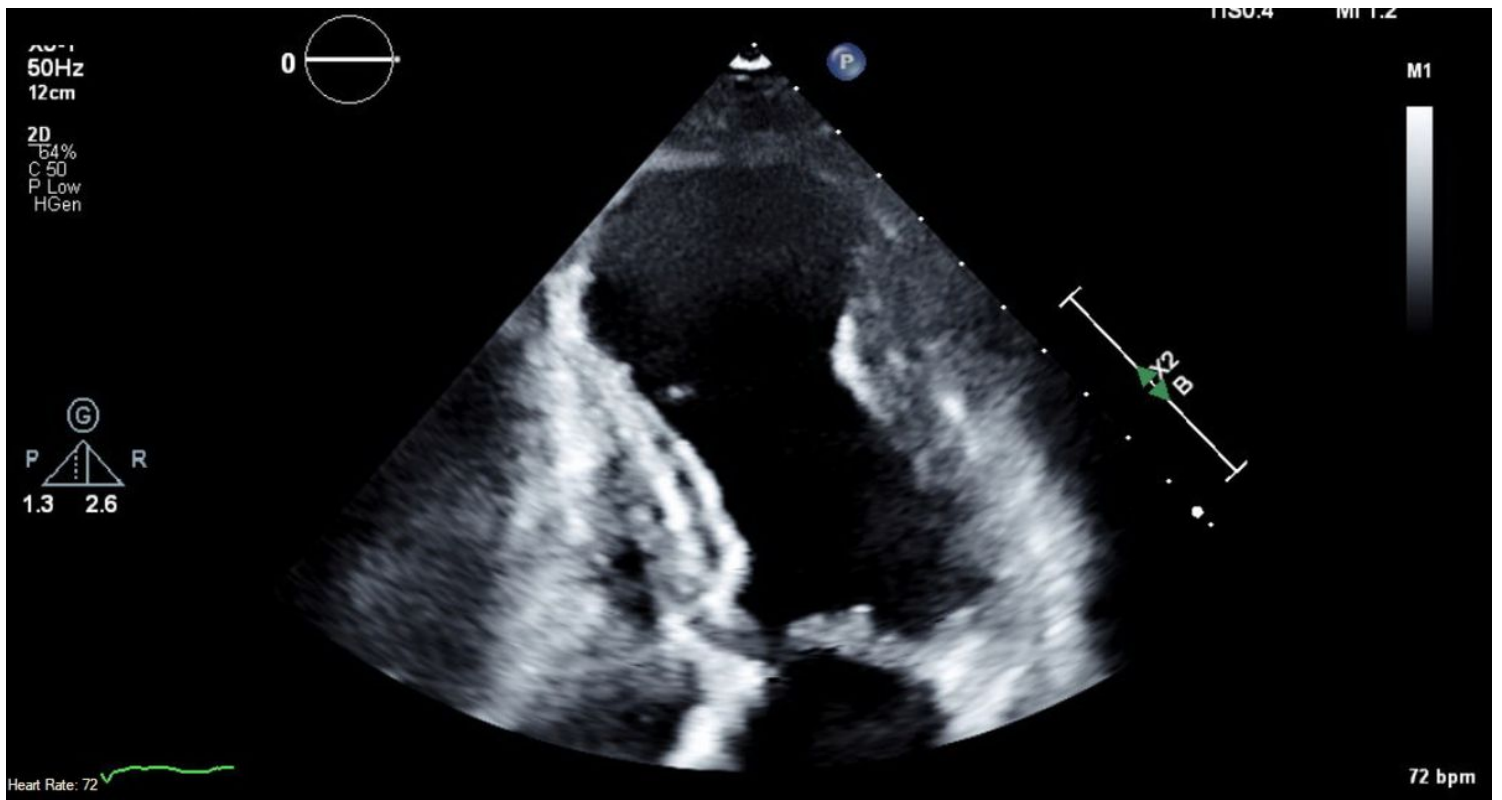


Figure 4

TTE without contrast at the apical 4 chamber view shows resolution of LV thrombi.

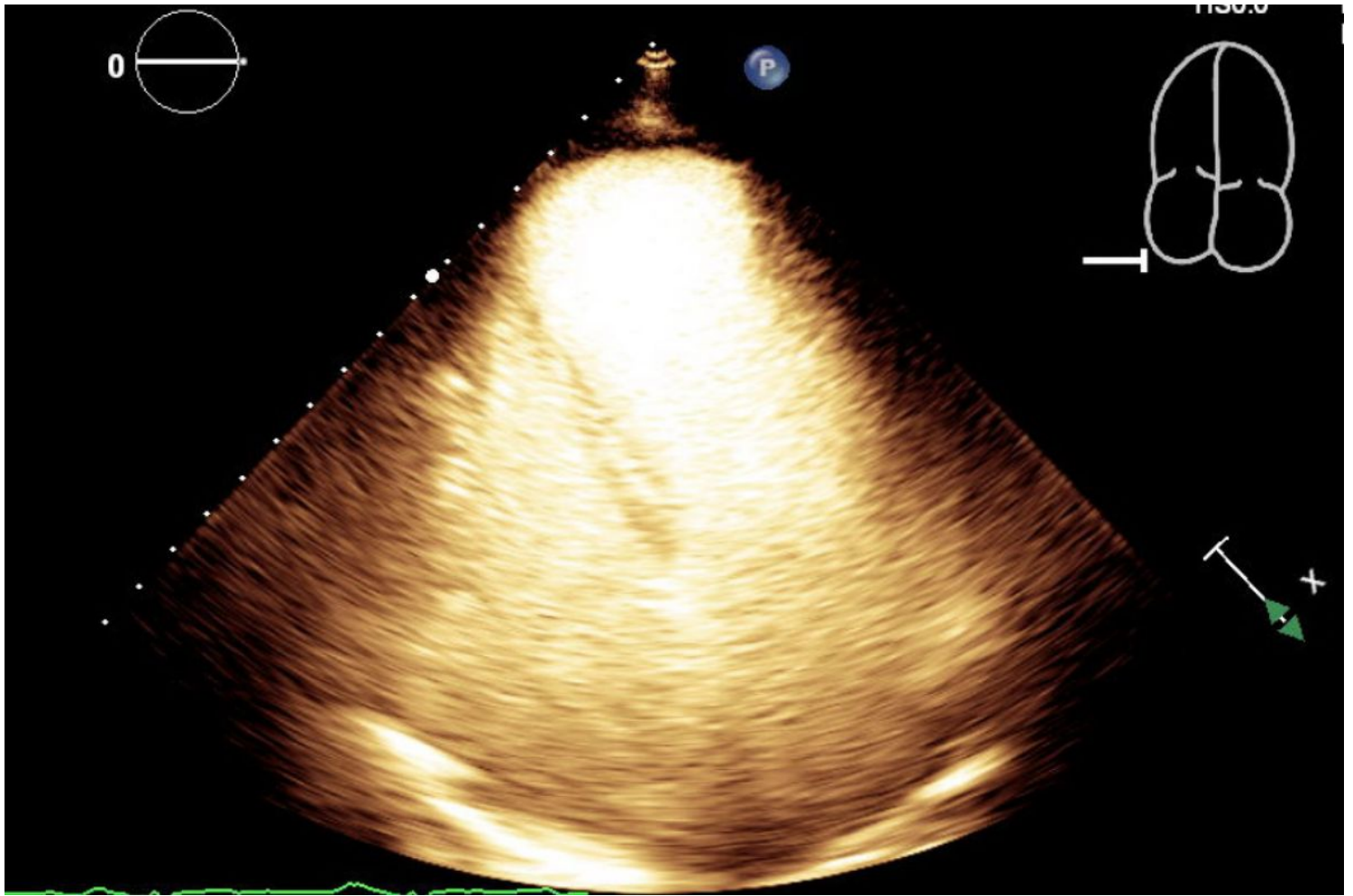


Figure 5

TTE with contrast at the apical 4 chamber view shows resolution of LV thrombi.

Supplementary Files

This is a list of supplementary files associated with this preprint. Click to download.

- [Video70ffaxisA1Cwcontrast.mp4](#)
- [Video1OccludedLAD.mp4](#)
- [Video3ParasternalShortAxiswocontrast.mp4](#)
- [Video6A3Cwocontrast.mp4](#)
- [Video5A2Cwocontrast.mp4](#)
- [Video2TIMI2FlowPostPCI.mp4](#)
- [Video40ffaxisA4Cwocontrast.mp4](#)
- [Video9A3Cwcontrast.mp4](#)

- Video1OccludedLAD.mp4
- Video10ParasternalshortaxiswoLVthrombus.mp4
- Video10ParasternalshortaxiswoLVthrombus.mp4
- Video114ACwoLVthrombus.mp4
- Video133ACwoLVthrombus.mp4
- Video114ACwoLVthrombus.mp4
- Video122ACwoLVthrombus.mp4
- Video133ACwoLVthrombus.mp4
- Video8A2Cwcontrast.mp4
- Video144ACwcontrastwoLVthrombus.mp4
- Video122ACwoLVthrombus.mp4
- Video144ACwcontrastwoLVthrombus.mp4
- Video152ACwcontrastwothrombus.mp4
- Video163ACwcontrastwoLVthrombus.mp4
- Video163ACwcontrastwoLVthrombus.mp4
- Video2TIMI2FlowPostPCI.mp4
- Video152ACwcontrastwothrombus.mp4
- Video3ParasternalShortAxiswocontrast.mp4
- Video4OffaxisA4Cwocontrast.mp4
- Video5A2Cwocontrast.mp4
- Video6A3Cwocontrast.mp4
- Video7OffaxisA1Cwcontrast.mp4
- Video8A2Cwcontrast.mp4
- Video9A3Cwcontrast.mp4