Spontaneous Peroneal Entrapment Neuropathy due to Anatomic Abnormality of Proximal Tibiofibular Joint：A Clinical Study of 10 Cases

Aihemaitijiang Yusufu (ahmatjang@163.com)

Department of Microrepair and Reconstructive Surgery, The First Afliated Hospital of Xinjiang Medical University

Hui Chen

Department of Microrepair and Reconstructive Surgery, The First Afliated Hospital of Xinjiang Medical University

Yiliyaer Wumaierjiang

Department of Microrepair and Reconstructive Surgery, The First Afliated Hospital of Xinjiang Medical University

Zhenhui Liu

Department of Microrepair and Reconstructive Surgery, The First Afliated Hospital of Xinjiang Medical University

Maimaiaili Yushan

Department of Microrepair and Reconstructive Surgery, The First Afliated Hospital of Xinjiang Medical University

Xiayimaierdan Maimaiti

Department of Microrepair and Reconstructive Surgery, The First Afliated Hospital of Xinjiang Medical University

Lei Xu

Department of Hand Surgery, Huashan Hospital, Fudan University

Research Article

Keywords: proximal tibiofibular joint, common peroneal nerve palsy

Posted Date: March 11th, 2022

DOI: https://doi.org/10.21203/rs.3.rs-1428030/v1

Abstract

Background: Dislocation or instability of the proximal tibiofibular joint is often obscure, difficult to diagnose, easily overlooked by clinicians, and may be the cause of some unexplained cases of common peroneal nerve compression. Moreover, the literature on proximal tibiofibular joint dislocation is very limited, with only a few case reports. This study aimed to evaluate the morphological characteristics and anatomic variation of tibiofibular joint through preoperative auxiliary examination and intraoperative exploration and to discuss its clinical significance.

Methods: From October 2015 to July 2021, a common peroneal nerve palsy diagnosis was made for 243 patients in our institution, of whom 10 were diagnosed with unexplained common peroneal nerve palsy. We carefully compared the results of intraoperative exploration with anteroposterior and lateral radiographs of the patients' lower limbs and CT of their lower limbs to investigate the presence of bony structural abnormalities.

Results: In the examination of lower limb CT, we found that the anatomical relationship of tibiofibular joint was significantly abnormal in three patients, among whom the preoperative CT plain scan of the lower limbs indicated that the fibula position of the affected limb was 2 cm lower than that of the opposite side in one typical patient. In one of the three patients with abnormal CT results, high common peroneal tension was found even after releasing the thickened fibers at the fibula head. The compression factor of this patient was the anatomic variation of the tibiofibular joint, which led to the common peroneal nerve being pulled downward by the fibular head; thus, peroneal osteotomy was performed during the operation. After osteotomy, the common peroneal nerve was markedly reduced in tone.

Conclusions: Anatomic abnormalities or dislocation of the proximal tibiofibular joint may result in the entrapment of the common peroneal nerve. Preoperative CT examination of these patients is required to determine the presence of common peroneal nerve compression due to bony structural abnormalities. If the patient has a definite bony structural abnormality, peroneal osteotomy may be required at the time of peroneal nerve release.

Background

The common peroneal entrapment neuropathy is the most prevalent lower extremity entrapment neuropathy and accounts for 15% of all such cases[1]. The common peroneal nerve arises from the L4-S2 nerve roots. After the common peroneal nerve originates from the sciatic nerve, along the upper lateral margin of the popliteal fossa, namely the medial side of the biceps femoris tendon, it moves to the lateral angle of the popliteal fossa, continues to pass down obliquely, passes around the fibula neck, crosses the deep surface of the origin of the peroneal longus muscle, and divides into the superficial peroneal nerve, the deep peroneal nerve, and the inferior iliac branch. Common clinical manifestations of a common peroneal nerve injury include weakness during dorsal extension and valgus, as well as anterolateral leg and dorsal foot paresthesias[1].

There are many causes of peroneal nerve injury. Traumatic causes include knee dislocation, severe ankle varus, lacerations, and direct blunt force injuries, which often lead to poor outcomes. Diabetes also often leads to common peroneal nerve disease. Iatrogenic injuries are common as well. Acute common peroneal nerve injuries are usually the result of hip, knee, and ankle surgery. Other causes include anesthetic positions for specific procedures, prolonged bed rest, and compression such as bandages and casts[2]. These are the main risk factors for common peroneal nerve entrapment. However, there are still a small number of common peroneal nerve palsy cases that cannot be identified clinically.

In the reviewed literature, most authors have reported that common peroneal entrapment neuropathy occurs around the fibular head and neck, due to it being superficial in the subcutaneous space directly over the unyielding fibula and being tethered by tight fascial bands.[3] Although the mechanism by which the common peroneal nerve is compressed in the fibular tunnel could not be clearly explained by any of the researchers, this anatomic location was believed to cause a significant compression of the common peroneal nerve[3]. Based on this anatomical basis, other scholars have proposed that dislocation, instability, and anatomical abnormalities of the proximal tibiofibular joint could also cause common peroneal nerve palsy in the long term, if the conditions are not treated in time[4]. Dislocation or instability of the proximal tibiofibular joint is often obscure, difficult to diagnose, easily overlooked by clinicians, and may be the cause of some unexplained cases of common peroneal nerve compression. Moreover, dislocation of the proximal tibiofibular joint is poorly understood by clinicians, and the literature on proximal tibiofibular joint dislocation is very limited, with only a few case reports. M. O. Ashraf et al.[5] reported a case of acute dislocation of the proximal tibiofibular joint. The authors concluded that proximal tibiofibular dislocation is a rare injury which is often ill informed in textbooks and underdiagnosed. It can result in chronic knee pain and instability if not diagnosed and treated appropriately. Götz Klaunick et al.[6] concluded that anterolateral is the most common type and when misdiagnosed, chronic pain and joint instability occur requiring extensive surgical management. The present study was necessary to explore the relationship between unknown common peroneal nerve palsy and proximal tibiofibular joint abnormality. Further, we aimed to evaluate the morphological characteristics and anatomic variation of tibiofibular joint through preoperative auxiliary examination and intraoperative exploration and to discuss its clinical significance.

Methods

From October 2015 to July 2021, a common peroneal nerve palsy diagnosis was made for 243 patients in our institution, of whom 10 were diagnosed with unexplained common peroneal nerve palsy. The inclusion criteria for this study included patients with common peroneal nerve palsy diagnosed by medical history, physical examination, or neurophysiological investigations and confirmed by subsequent intraoperative exploration and neurophysiological investigation. Exclusions were a past medical history of diabetic mellitus, smoking history, fractures of the affected limb, neuromuscular disorders affecting the limbs, as well as spinal cord and brain injuries. We carefully compared the results of intraoperative exploration with anteroposterior and lateral radiographs of the patients' lower limbs and CT of their lower limbs to

investigate the presence of bony structural abnormalities with unexplained common peroneal nerve palsy. The demographic data of the 10 patients are shown in Table 1.

This retrospective study was carried out in accordance with the Declaration of Helsinki. Each participant provided written informed consent.

Surgical Technique

All operations were performed under general anesthesia in the lateral decubitus position. For common peroneal nerve decompression, a 5-cm S-type incision was made at the popliteal fossa and lateral fibular capitulum; the biceps femoris muscle and common peroneal nerve end were exposed; and the cause of the entrapment of the common peroneal nerve was investigated intraoperatively. If the common peroneal nerve was found to be compressed by scarring at the small head of the fibula, we removed the hypertrophic scar and released the common peroneal nerve all the way to the beginning of the peroneal longus muscle (Figure 1). After the scar tissue around the common peroneal nerve was released, the proximal tibiofibular joint was investigated for dislocation or bony compression of the common peroneal nerve all the way to the common peroneal nerve branch below the fibular head, and the knee joint radiographs and CT results were compared.

Table 1

Preoperative parameters of 10 patients.

MRC: Medical Research Council

Postoperative management

All patients underwent rehabilitation exercise after 2 weeks of fixation with an ankle extension brace. Each patient was followed up weekly for the initial 2 weeks after surgery, then monthly, and subsequently every 3 months after month three.

Results

Ten patients underwent peroneal nerve decompression during the study period. Two were female. The mean age was 38.4 years, with a range of 18-52 years. The median follow-up was 32 months, with a range of 9-39 months. The median interval between injury and surgery was 3 months, with a range of 2-9 months.

All 10 patients showed no obvious abnormality in lower limb radiographs（Figure 2）. In the examination of

Patient	Age	Sex	Preoperation period (Mos)	Follow up (Mos)	Foot dorsiflexion (MRC)	Foot eversion(MRC)	Toe flexion (MRC)	Sensory recovery score (MRC)
1	48	M	3	38	M1	M1	M1	S1
2	39	M	9	32	M1	M1	M1	S2
3	18	M	2	32	M2	M2	M2	S3
4	43	M	6	30	M3	M1	M2	S2
5	52	M	3	24	M1	M1	M1	S2
6	23	F	3	39	M0	M0	M1	S2
7	21	M	2	13	M2	M2	M2	S3
8	49	M	4	9	M1	M1	M4	S3
9	40	M	5	38	M1	M1	M1	S1
10	51	F	2	36	M1	M1	M1	S2

lower limb CT, we found that the anatomical relationship of the tibiofibular joint was significantly abnormal in three patients, among whom the preoperative CT plain scans of the lower limbs indicated that the fibula position of the affected limb was 2 cm lower than that of the opposite side in one typical patient. In surgical exploration, significant band compression of the common peroneal nerve at the fibular head was found in five patients（Figure 1）. No obvious compression factor was detected in two patients. In one of the three patients with abnormal CT results, high common peroneal tension was found even after releasing the thickened fibers at the fibula head. The common peroneal nerve was found to be pulled by the fibular head when the operation was performed below the fibular head. CT results showed that the position of the fibular head on the affected side of the patient was lower than that on the opposite side （Figure 3）. We believed that the compression factor of this patient was the anatomic variation of the tibiofibular joint, which led to the common peroneal nerve being pulled downward by the fibular head; thus, peroneal osteotomy was performed during the operation（Figure 4）. After osteotomy, the common peroneal nerve was markedly reduced in tone.

Most patients had improved dorsiflexion function: MRC M5 in five cases (50%) and M4 in three cases (30%). Two patients had no recovery of muscle strength, resulting in functional reconstructive surgery of posterior tibialis muscle transposition. If the cause of common peroneal nerve compression was clearly corrected, then the majority of patients (6/10) recovered their dorsiflexion muscle strength to M3 at the 3-month follow-up. The recovery time of M3 of the tibialis anterior muscle was 3-6 months, with an average of 3.4 months. Valgus usually recovers more slowly than dorsiflexion, which may have been related to the patients' rehabilitation and exercise. M3 recovery time of the peroneus longus muscle was from July to December, with an average of 8.2 months. We present the results of one of these patients here (Figure 5).

Discussion

Common peroneal palsy is a common nerve disease of the lower extremities. Most common peroneal palsy can be treated by nerve release. Samuel C. George et al.[7] evaluated 28 studies (1577 cases of common peroneal nerve repair) through a review of extensive literature and found that 80% of patients undergoing common peroneal nerve release had a good prognosis, while 37% of patients undergoing direct nerve suture had a good prognosis. The proportion of patients who underwent nerve graft repair had a good prognosis (defined as muscle strength of M4 or above as measured by the MRC Muscle Strength Scale) of 36%. Dorsiflexion can be achieved by reconstructing the tibialis posterior muscle transposition, even if the prognosis is poor. Therefore, most scholars do not pay attention to the etiological research of common peroneal nerve palsy. There are a small number of patients with common peroneal nerve palsy in clinical practice, for whom no possible cause is found when their medical histories are queried. We call these patients spontaneous common peroneal nerve palsy. Regarding these patients and considering the proximal tibiofibular joint, a rare clinical injury that is often neglected and difficult to diagnose, we believe that spontaneous peroneal nerve palsy may be related to the proximal tibiofibular joint. Therefore, we conducted a retrospective study on the etiology of patients with spontaneous peroneal nerve palsy.

The earliest description of Peking Opera by Dubrueil Ogden's research on the proximal tibiofibular joint has been widely recognized[8][9]. Ogden divided proximal tibiofibular joint dislocation into four main types: subluxation, anterolateral dislocation, posterometral dislocation, and superior dislocation. Nikolaides et al.[10] suggested that the lower dislocation was considered as Type V for the upper tibiofibular joint dislocation. The lower dislocation is caused by high-energy trauma and is often associated with severe fractures and vascular and nerve damage, suggesting severe limb damage. The overall proportion of the 200 proximal tibiofibular joint dislocations reported by Ogden was as follows: 18% sucuxations, 69% anterolateral, 4% posterolateral, 7% superior lateral, and 2% inferior. Ogden[8][11] divided the proximal tibiofibular joint into two types according to the inclination of the joint surface. Type I is horizontal: the shape of the joint surface is flat and round, and the angle between the joint surface and the horizontal plane is less than 20°, with relatively larger joint area and rotation. Type II is inclined: the angle between the articular surface and the horizontal plane is > 20°, with a variety of different shapes, structures, and degrees of tilt; the tilt angle is up to 76°, and more prone to instability and dislocation (Figure 6).

Acute dislocation can cause lateral swelling, pain, inability to load, and varying degrees of knee movement limitation. Temporary symptoms of common peroneal nerve injury may occur in some patients, especially those with posteromedial dislocation[12]. For patients with acute dislocation, it is characteristic that almost no pain or instability is felt on the lateral side of the knee immediately after successful reduction[13]. Subluxation of the proximal tibiofibular joint may present as unprovoked pain on the lateral side of the knee, with increased pain when the fibular head is pressed, or, in rare cases, as an external deformity caused by the protrusion of the fibular head without any discomfort. X-ray is used to diagnose the dislocation of the tibiofibular joint. Hey et al.[14] studied 2984 knee radiographs and found that the anteroposterior radiographs of the fibular head always pointed to the outer margin of the lateral femoral condyle, and the lateral radiographs pointed to the top line of the intercondylar fossa of the femur, which

was highly specific for the diagnosis of tibiofibular joint dislocation. The optimal anteroposterior radiographs of the knee should be under weight bearing, and the lateral radiographs should bend at least 20°. The knee contrast film is helpful for definite diagnosis, but this method is affected greatly by the angle of projection and sometimes is not accurate. Three-dimensional CT is the gold standard for definite diagnosis. MRI can be used to evaluate the soft tissue injuries around the capsule and joint and can also be used to distinguish chronic instability from meniscus injury.

Currently, diagnosis of proximal tibiofibular joint dislocation usually requires a history of trauma and CT examination. However, none of the 10 patients in this study had complaints of lower extremity trauma, and no obvious abnormalities were found in X-ray films of both lower extremities. CT results of lower limbs in three patients showed anatomic abnormalities of the proximal tibiofibular joint but did not meet the diagnostic criteria for proximal tibiofibular joint dislocation. When the proximal tibiofibular joint is anatomically abnormal, similar to the inferior or anterolateral dislocation of the proximal tibiofibular joint, the proximal fibula occasionally pulls on the common peroneal nerve, resulting in compression of the common peroneal nerve. During the intraoperative exploration, we found that although the proximal and distal parts of the common peroneal nerve were released, the tension of the common peroneal nerve remained high. When we removed the proximal part of the fibula, the tension of the common peroneal nerve was significantly reduced. This results confirms our hypothesis.

In clinical practice, patients with common peroneal nerve palsy, who have no history of trauma or cyst compression, often develop symptoms of common peroneal nerve palsy without obvious cause. In these patients, we speculate that the cause of common peroneal nerve palsy may be anatomic abnormality of the proximal tibiofibular joint or recessive dislocation of the old proximal tibiofibular joint (Figure 7). This may result in chronic compression of the common peroneal nerve, which remains stretched after the release of scar tissue around the nerve at the fibula head. Some patients are still not satisfied with the therapeutic effect after the release. Complete release of the common peroneal nerve can only be achieved if anatomic abnormalities at the proximal tibiofibular joint, such as a peroneal osteotomy, are resolved.

In this study, the etiology of common peroneal nerve palsy of unknown clinical origin was investigated. We found that the common peroneal nerve was compressed by the anatomic abnormality at the proximal tibiofibular joint. Part of the fibula should be removed during the operation to release the common peroneal nerve completely. The limitation of this study lies in the small number of such patients, which affects the reliability of the conclusion. However, the preoperative imaging evidence that we found and the fact that the common peroneal nerve recovered quickly after osteotomy verified our conclusion, which also provides some inspiration for the study of such etiology.

Conclusion

Anatomic abnormalities or dislocation of the proximal tibiofibular joint may result in the entrapment of the common peroneal nerve. The etiology of some spontaneous peroneal nerve palsy may be related to the anatomic abnormality of the proximal tibiofibular joint. Preoperative CT examination of these patients is required to determine the presence of common peroneal nerve compression due to bony structural

abnormalities. If the patient has a definite bony structural abnormality, peroneal osteotomy may be required at the time of peroneal nerve release.

Declarations

Acknowledgements

Not applicable.

Authors' contributions

AY and LX designed the study protocol. HC and XM did the literature search. The titles, abstracts, and full texts were screened and selected by HC, MY, and YW. The figures 6-7 were prepared by YW. The data were extracted and analyzed by ZL. All authors read and approved the fnal manuscript.

Funding

Not applicable.

Availability of data and materials

All data generated or analyzed during this study are included in this published article.

Declarations

Ethics approval and consent to participate

All patients gave written informed consent before participation in this study and study protocols were approved by ethical committee of the frst afliated hospital of Xinjiang medical university. All methods were carried out in accordance with relevant guidelines and regulation.

Consent for publication

Not applicable.

Competing interests

The authors declare that they have no competing interests.

References

1. .Poage C, Roth C, Scott B. Peroneal Nerve Palsy: Evaluation and Management. J Am Acad Orthop Surg. 2016 Jan;24(1):1-10.
2. Hobson-Webb LD, Juel VC. Common Entrapment Neuropathies. Continuum (Minneap Minn). 2017 Apr;23(2, Selected Topics in Outpatient Neurology):487-511.
3. Jeong-Hyun Park, Jinseo Yang, Kwang-Rak Parket al. A Cadaveric Study of the Distal Biceps Femoris Muscle in relation to the Normal and Variant Course of the Common Peroneal Nerve: A Possible Cause of Common Peroneal Entrapment Neuropathy[J]. BioMed Research International, 2020, 2020: 1-8.
4. J. Horan. Proximal tibiofibular dislocation[J]. Emergency Medicine Journal, 2006, 23□5□: e33.
5. M. O. Ashraf, H. M. Jones, R. Kanvinde. Acute traumatic fracture dislocation of proximal tibiofibular joint: Case report and literature review[J]. Injury, 2015, 46□7□: 1400-1402.
6. Götz Klaunick. Recurrent idiopathic anterolateral dislocation of the proximal tibiofibular joint: case report and literature review[J]. Journal of Pediatric Orthopaedics B, 2010, 19□5□: 409-414.
7. George, S.C. and D.E. Boyce, An Evidence-Based Structured Review to Assess the Results of Common Peroneal Nerve Repair. Plastic and Reconstructive Surgery, 2014. 134(2): p. 302e-311e.
8. Ogden JA. Subluxation and dislocation of the proximal tibiofibular joint. J Bone Joint Surg Am 1974;56:145-154.
9. Ogden JA. The anatomy and function of the proximal tibiofibular joint. Clin Orthop Relat Res 1974;101:186-91.
10. Nikolaides AP, Anagnostidis KS, Kirkos JM, et al. Inferior dislocation of the proximal tibiofibular joint: a new type of dislocation with poor prognosis[J]. Arch Orthop Trauma Surg, 2007, 127(10):933□936.
11. Ogden JA. Subluxation of the proximal tibiofibular joint. Clin Orthop Relat Res 1974; 101:192–197.
12. Turco VJ, Spinella AJ. Anterolateral dislocation of the head of the fibula in sports[J]. Am J Sports Med, 1985, 13(4):209□215.
13. van Wulfften Palthe AF, Musters L, Sonnega RJ, et al. Dislocation of the proximal tibiofibular joint, do not miss it[J]. BMJ Case Rep, 2015, 2015:Pii:bcc2014201875□
14. Hey HW, Ng LW, Ng YH, et al. Radiographical definition of the proximal tibiofibular joint-A cross-sectional study of 2984 knees and literature review[J]. Injury, 2016, 47(6):1276-1281.

Figures

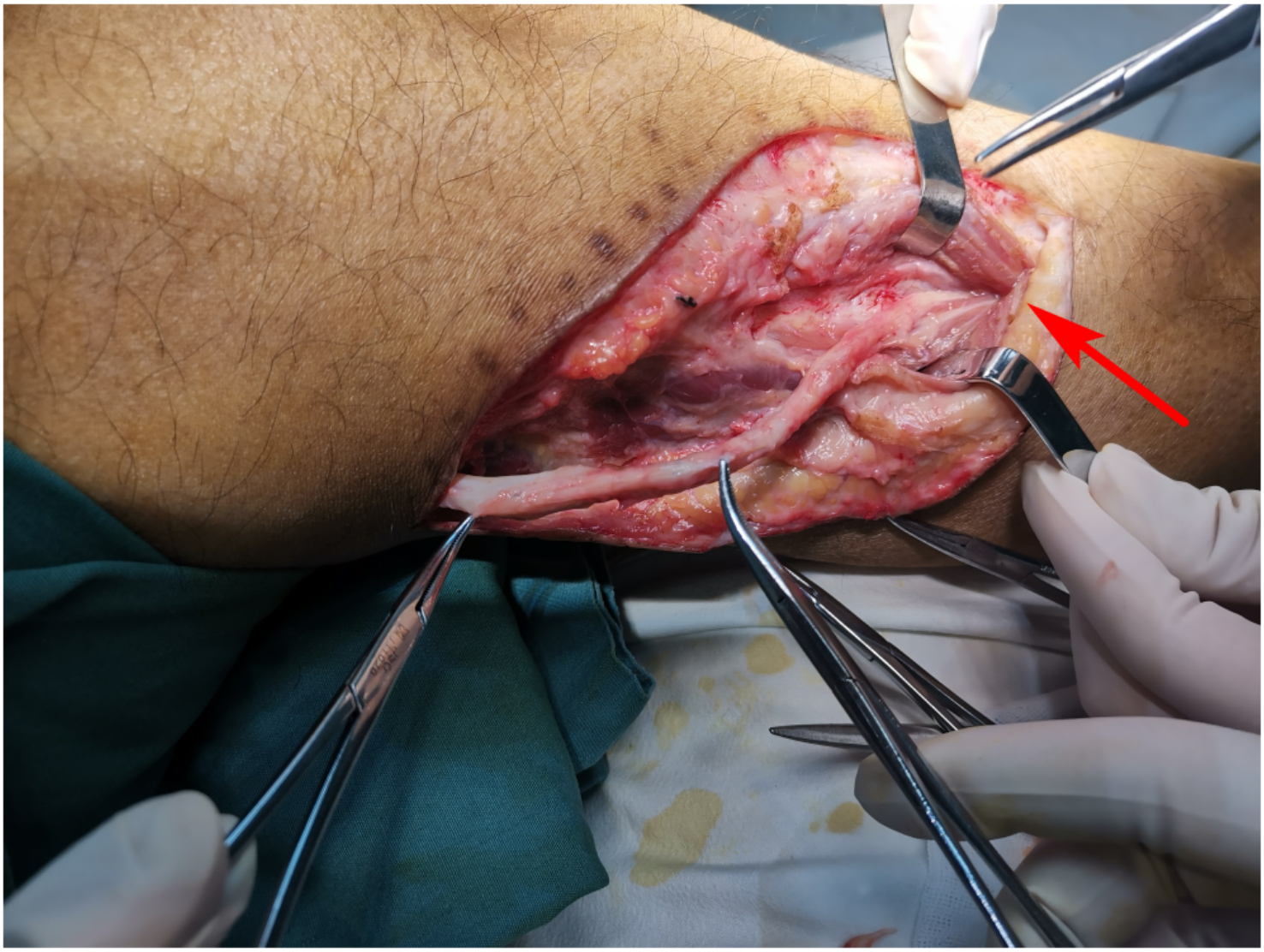

Figure 1

Tendinous entrapment of the common peroneal nerve at the entry point of the peroneal longus muscle.

Figure 2

There was no obvious anatomical difference in lower limbs on X-ray

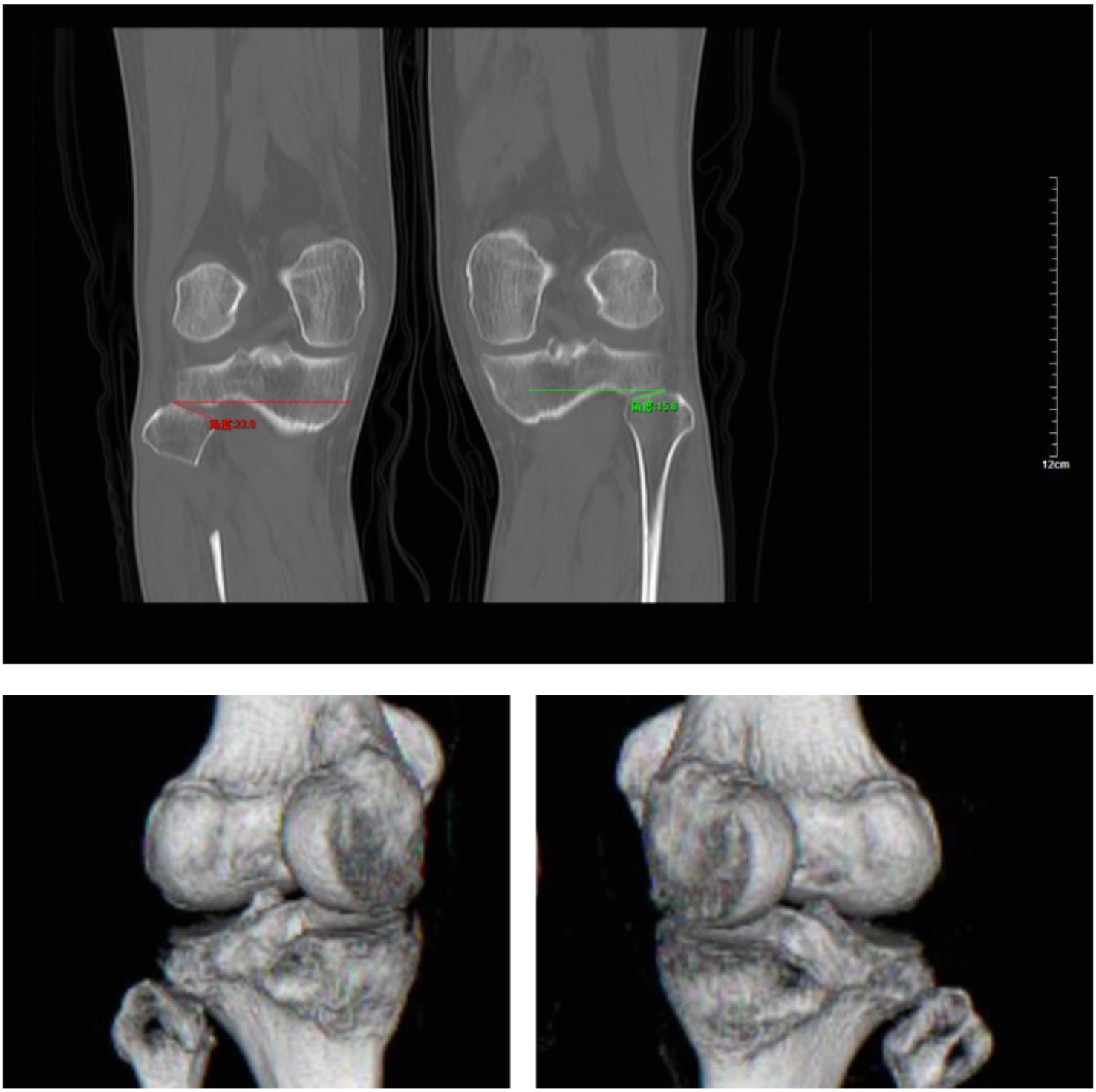

Figure 3

Plain CT scan of both lower limbs indicated that the position of the fibula of the affected limb was 2 cm lower than that of the opposite side, and the angle between the articular surface of the tibiofibular joint and the level was larger.

Figure 4

The dislocation of the tibiofibular joint resulted in compression of the common peroneal nerve after peroneal osteotomy.

Figure 5

Patient 7, peroneal osteotomy, 3 months postoperatively, dorsiflexion with M4.

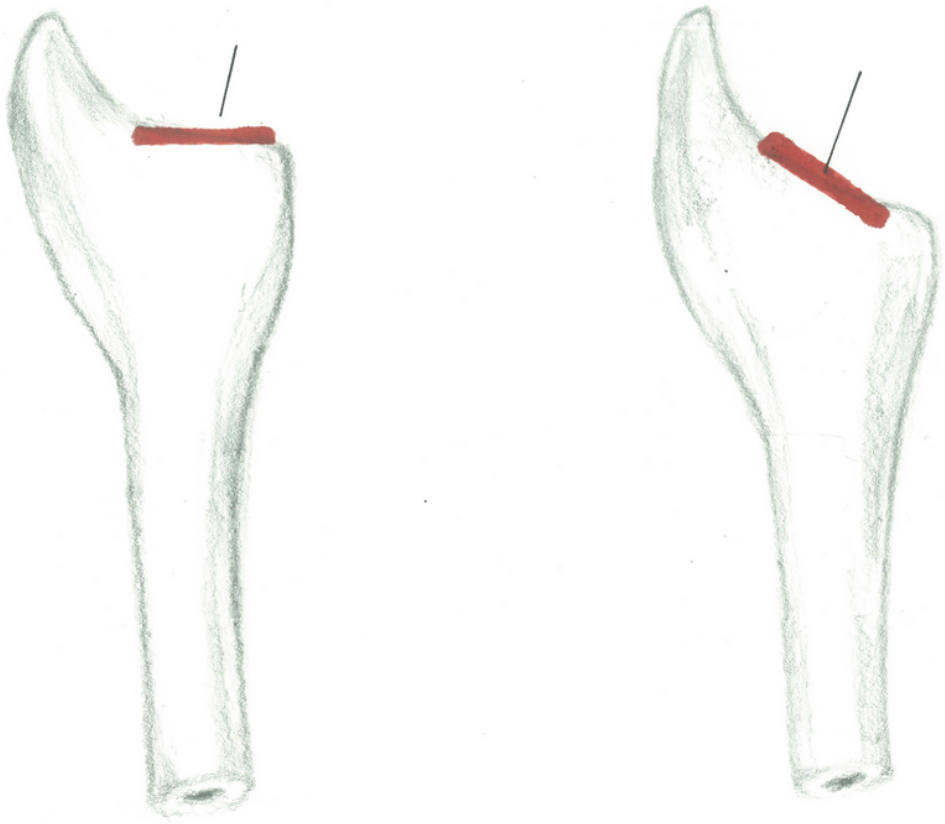

Figure 6

Ogden divided the proximal tibiofibular joint into two types according to the inclination of the joint surface.

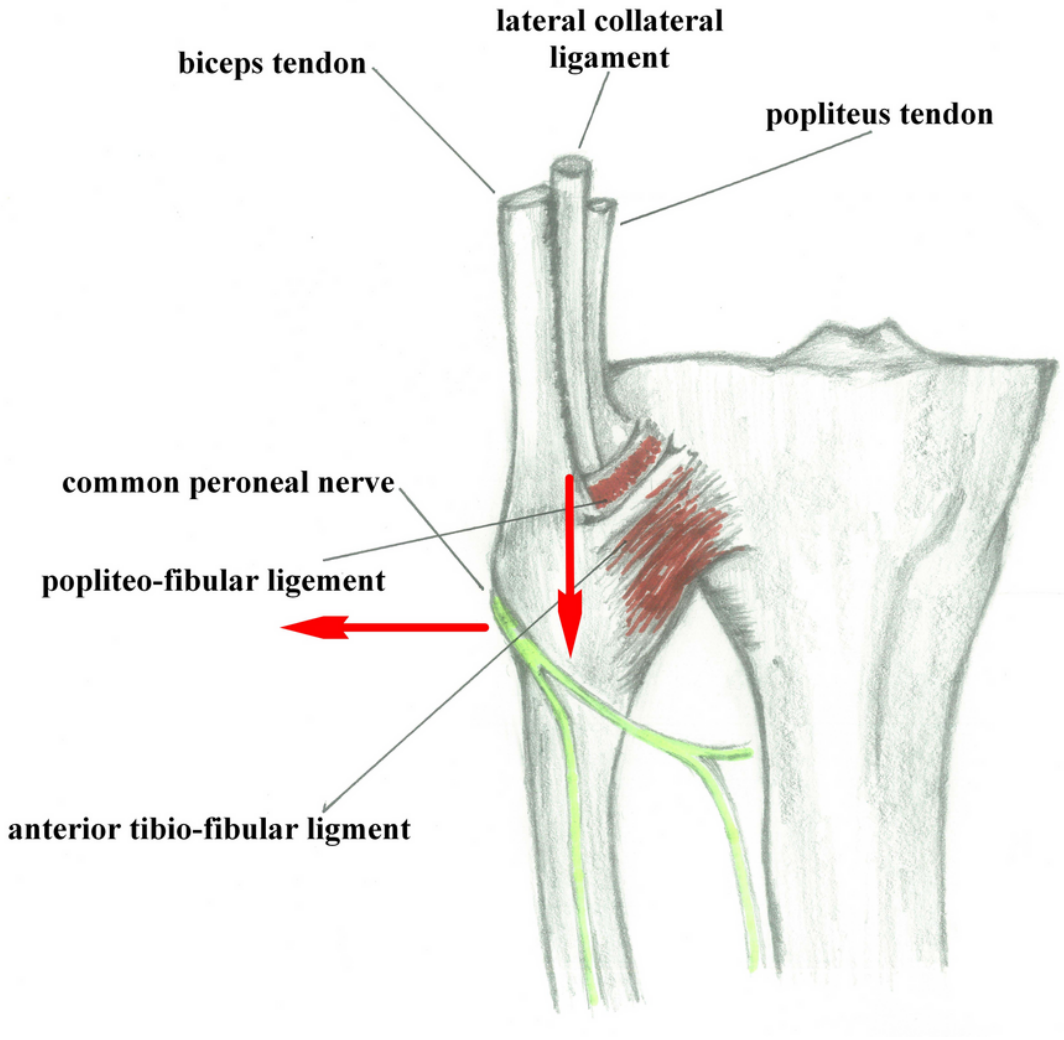

Figure 7

Anterior or inferior dislocation of the proximal tibiofibular joint may cause chronic compression of the common peroneal nerve.