

# Meeting in the Middle: Pediatric Abdominal Wall Reconstruction for Omphalocele

**Katelyn Kondra**

Children's Hospital of Los Angeles

**Christian Jimenez**

Children's Hospital of Los Angeles

**Eloise Stanton**

Children's Hospital of Los Angeles

**Kevin Chen**

Children's Hospital of Los Angeles

**Cathy E. Shin**

Children's Hospital of Los Angeles

**Jeffrey A. Hammoudeh** (✉ [jhammoudeh@chla.usc.edu](mailto:jhammoudeh@chla.usc.edu))

Children's Hospital of Los Angeles

---

## Research Article

**Keywords:** omphalocele, component separation, abdominoplasty, pediatric abdominal wall reconstruction, plastic surgery, mesh

**Posted Date:** March 14th, 2022

**DOI:** <https://doi.org/10.21203/rs.3.rs-1432728/v1>

**License:**  This work is licensed under a Creative Commons Attribution 4.0 International License.

[Read Full License](#)

---

# Abstract

## Purpose

Omphalocele is a congenital abdominal wall defect with an incidence of 1/4,200 births. Repair timing varies from the neonatal period to the first few years of life. Surgical technique has changed over the last two decades. We sought to establish improved surgical/ventilation protocols for patients with omphaloceles requiring abdominal reconstruction.

## Methods

An IRB-approved retrospective review was performed on patients with omphalocele requiring abdominal wall reconstruction by Plastics and/or Pediatric Surgery at a pediatric tertiary-care referral center (January 2006-July 2021). Birth history, comorbidities, surgical details, ventilation data, complications/recurrence were extracted.

## Results

Of 129 patients screened, seven required Plastic Surgery involvement. Defect size was 102.9 cm<sup>2</sup> (range: 24 - 178.5); four patients required component separation; zero patients received mesh; zero complications/recurrences were recorded. Two patients required postoperative ventilation for 2.5 days, based on increased peak inspiratory pressures at surgery stop versus start time.

## Conclusion

Patients with large defects secondary to omphalocele benefit from collaboration between Pediatric and Plastic Surgery for component separation and primary fascial closure without mesh. Future research should follow patients who mature out of pediatric clinics to evaluate the incidence of hernias in adults with Plastic Surgery-repaired omphaloceles.

## Background

Omphalocele is one of the most common congenital abdominal wall defects with an annual incidence of one in every 4,200 births in the United States [1]. This pathology is attributed to a failure of physiologically herniated bowel to return to the abdominal cavity by gestational week 12. The presence of omphalocele carries a heightened risk of over 50% for aneuploidy and genetic abnormalities [2], as well as associated cardiovascular, gastrointestinal, genitourinary, musculoskeletal, or central nervous system anomalies [3], which may require urgent attention in the neonatal period.

Operative management of omphaloceles is categorized based on size and presentation. Many small defects ( $\leq 4$  cm) are able to be repaired primarily in the first several days of life [2] whereas peripartum ruptured omphaloceles carry high morbidity and mortality and require emergent intervention with resuscitation and stabilization of the neonate [4]. Giant omphaloceles ( $\geq 5$ cm) often necessitate

considerable reconstruction given the loss of abdominal domain and potential for rectus abdominis malpositioning and underdevelopment [5]. Timing of giant omphalocele repair is variable and surgeon-dependent with repair occurring immediately in the neonatal period or in a delayed fashion in the first few years of life [6]. The membranous covering over the abdominal contents epithelialize after 4–10 weeks, thereby protecting the viscera [2]. Frequently, the liver and the bowel are concurrently extruded in utero; as such, patients have limited chest wall growth and resultant pulmonary hypoplasia [3] with varying degrees of ensuing chronic pulmonary disease. Accordingly, these resultant physiologic changes deserve careful attention when considering omphalocele repair.

Beyond primary closure, adjunctive techniques such as tissue expanders, component separation, and mesh implantation can be considered for large defects. We hereby sought to provide a Plastic & Reconstructive Surgery perspective on giant omphalocele by reviewing patients with omphaloceles who were cared for at a large pediatric tertiary-care referral center. By establishing recommendations regarding the surgical and ventilatory management of these patients, we hope to improve collaboration between Pediatric Surgery and Plastic Surgery and improve morbidity for patients requiring abdominal wall reconstruction.

## Methods

An Institutional Review Board-approved retrospective review was performed on all patients with diagnosed omphaloceles from January 2006 to July 2021 who received care at a pediatric tertiary-care referral center. Inclusion criteria stated that all patients received abdominal wall operations at Children's Hospital Los Angeles (CHLA) by Pediatric Surgery and/or Plastic Surgery. Patients with other abdominal wall defects, namely gastroschisis, umbilical hernia, prune belly syndrome, and vitelline duct fistula, were excluded. For all patients seen by Plastic Surgery, the treating Pediatric Surgeon was the referring provider for definitive abdominal wall reconstruction/closure, scar revision, or tissue expansion.

Patient birth history including birth weight, height, and gestational age, as well as comorbidities and demographics were collected. Surgical details, such as type of reconstruction with/without component separation, defect size at time of surgery, mesh placement and location of mesh, intraoperative and postoperative complications, and recurrence were collected from chart review. Ventilatory data, such as peak inspiratory pressures (PIP), were abstracted from documented anesthesia records. Initial PIP was recorded at the start of the surgery, whereas final PIP was recorded after skin closure upon completion of the operation.

In order to more accurately compare the Plastic Surgery cohort with the Pediatric Surgery cohort in terms of physiologic stability, the Pediatric Surgery patients were subdivided into those who underwent repair in the neonatal period (< 4 weeks of age) and those who underwent repair after 4 weeks of age (non-neonatal group), once epithelialization of the omphalocele sac occurred.

Descriptive statistics and significance testing, including Student's Independent t-test, were performed on SPSS Advanced Statistics version 28.0 (SPSS Inc, Chicago, Illinois).

## Results

Initial review generated 129 patients with omphaloceles who were cared for at CHLA over the past 15 years. After excluding duplicates, prenatal consults, patients who received surgical management at outside institutions, and those without follow-up at CHLA, 57 patients met inclusion criteria. Seven patients (12.3%) with omphaloceles underwent abdominal wall reconstruction with Plastic Surgery intervention whereas the remaining 50 patients were primarily managed by Pediatric Surgery. Of those patients managed by Pediatric Surgery, 25 patients had primary repair during the neonatal period (< 4 weeks old) and 25 patients were allowed to epithelialize over their omphalocele sac (non-neonatal group).

Indications for Plastic Surgery referral included large defects with loss of domain requiring complex closure, tissue expanders, and/or soft tissue rearrangement. Average age at repair in the Plastic Surgery cohort was 5.5 years old. Average age at repair in the entire Pediatric Surgery cohort was 1.1 years old and 2.3 years old in the non-neonatal subset. Four Plastic Surgery patients (57.1%) had comorbidities including one patient with dextrocardia and hypothyroidism, one patient with Wolff-Parkinson-White and malrotation, one patient with pulmonary hypoplasia and obstructive sleep apnea, and one patient with food aversion and poor weight gain necessitating nasogastric feeding tube. Thirty-six Pediatric Surgery patients (72%) had comorbidities, commonly involving cardiovascular (n = 9) or pulmonary (n = 15) systems, and at least 10 patients were syndromic; 18 patients (72%) in the non-neonatal subset had comorbidities (Table 1).

Table 1  
Demographics & Abdominal Wall Defects

	Plastic Surgery		Pediatric Surgery	
<b>Demographics</b>				
Sex	<i>n (%)</i>	<i>Average (range)</i>	<i>n (%)</i>	<i>Average (range)</i>
Male	4/7 (57.1%)		32/50 (64.0%)	
Female	3/7 (42.9%)		18/50 (36.0%)	
Ethnicity				
Hispanic	6/7 (85.7%)		19/40 (47.5%)	
Non-hispanic	1/7 (14.3%)		21/40 (52.5%)	
Birth weight (g)		3013.5 (2054–3750)		3089.2 (1700–7300)
Birth height (cm)		48.1 (44.5–50.0)		46.9 (35.0–55.5)
Comorbidities	4/7 (57.1%)		36/50 (72.0%)	
Age at reconstruction (years)		5.5 (3.3–7.6)		1.1 (0–12.4)
Follow-up time (months)		16.7 (0.3–51.8)		23.8 (0–162.3)
<b>Abdominal Wall Defects</b>				
Component separation	5/7 (71.4%)		3/25 (12.0%) <sup>^</sup>	
Mesh use	0/7 (0%)		7/25 (28.0%) <sup>^</sup>	
Defect size (cm <sup>2</sup> )		102.9 (24.0–178.5)		26.60 (4.0–100.0)
<i>Non-neonatal</i>				21.5 (1-120)
<i>Pediatric Surgery patients</i>				
<i>Plastic Surgery Patient 1</i>		178.5*		
<sup>^</sup> non-neonatal cohort (> 4 weeks old)				
* received component separation				
- not reported				

	Plastic Surgery	Pediatric Surgery
<i>Plastic Surgery Patient 2</i>	120.0*	
<i>Plastic Surgery Patient 3</i>	-	
<i>Plastic Surgery Patient 4</i>	120.0*	
<i>Plastic Surgery Patient 5</i>	24.0	
<i>Plastic Surgery Patient 6</i>	- *	
<i>Plastic Surgery Patient 7</i>	72.0*	
^non-neonatal cohort (> 4 weeks old)		
* received component separation		
- not reported		

The mean defect size at time of surgery in the Plastic Surgery cohort was 102.9 cm<sup>2</sup> (range: 24.0–178.5 cm<sup>2</sup>), which was significantly larger ( $p < 0.01$ ) than that of the entire Pediatric Surgery cohort (26.6 cm<sup>2</sup>, range: 4.0-100.0 cm<sup>2</sup>) and the non-neonatal Pediatric Surgery subset (21.5 cm<sup>2</sup>, range: 1-120 cm<sup>2</sup>) ( $p = 0.014$ ) (Table 1). Five of the seven patients (71.4%) operated on by Plastic Surgery underwent component separation with transversus abdominis release (TAR) during abdominal wall reconstruction whereas two required fasciocutaneous advancement flaps alone (Fig. 1). In comparison, three of the 25 (12.0%) non-neonatal Pediatric Surgery patients underwent component separations (Figs. 2–4).

Of note, all patients intervened on by Plastic Surgery achieved primary fascial closure without the use of mesh. Eight total patients in the Pediatric Surgery cohort received bridging mesh without fascial closure using Strattice (Allergan; Madison, NJ) or Gore-Tex mesh (W.L. Gore & Associates; Flagstaff, AZ), seven of which underwent non-neonatal repair; two patients received Alloderm (Biohorizons Implant Systems, Inc; Birmingham, AL) implantation (Table 1). Four of the patients who received mesh developed an infection and required explantation. Per chart review, all Pediatric Surgery patients who received mesh had giant and/or peripartum ruptured omphaloceles, either by dimension ( $\geq 5$  cm) or anecdotally containing liver.

Six patients (85.7%) in the Plastic Surgery cohort underwent prior abdominal wall operations with Pediatric Surgery; the mean number of prior operations was 2.5 (range 1–5) including tissue expander implantation/removal, part one of staged closure, exploratory laparotomy with lysis of adhesions, and wound debridement. Two patients experienced complications following their index abdominal wall operations, including infected tissue expanders, placed in collaboration with Plastic Surgery, and tissue flap necrosis. In comparison, 10 patients in the Pediatric Surgery cohort underwent abdominal wall operations prior to their reconstruction, eight of whom underwent repair after the neonatal period; the mean number of prior operations was 2.1 (range 1–4). Operations ranged from exploratory laparotomy

with adhesiolysis and/or washout, appendectomy, part one of staged operations, diaphragmatic hernia, evisceration, and silo placement.

Two patients (28.6%) in the Plastic Surgery cohort required postoperative mechanical ventilation for an average of 2.5 days (range 1–4); this was based on increased PIP at surgery stop versus start time. Average overall change in PIP from the beginning to the end of the operation was  $-0.4$  cm-H<sub>2</sub>O, and average overall change in PIP for those in the Plastic Surgery who remained intubated was  $+6$  cm-H<sub>2</sub>O (Table 2). In comparison, eight non-neonatal patients (32.0%) in the Pediatric Surgery cohort required postoperative ventilation for an average of 2.1 days (range 1–5); five of these patients had preoperative oxygen requirements. Average overall change in PIP from the beginning to the end of the operation was  $+1.6$  cm-H<sub>2</sub>O, and average overall change in PIP for patients who remained intubated was  $+5.5$  cm-H<sub>2</sub>O (Table 2). Of note, the difference in number of patients requiring postoperative ventilation between cohorts was not significant ( $p = 0.863$ ).

Table 2  
Intraoperative Ventilation: Peak Inspiratory Pressure

Plastic Surgery				Pediatric Surgery (non-neonatal)			
PIP (cm-H <sub>2</sub> O)	<i>Initial</i>	<i>Final</i>	$\Delta$	PIP (cm-H <sub>2</sub> O)	<i>Initial</i>	<i>Final</i>	$\Delta$
Average PIP (cm-H <sub>2</sub> O)	14.9	14.9	-0.4	Average PIP (cm-H <sub>2</sub> O)	16.4	17.1	+1.6
Average PIP of Patients who Remained Intubated (cm-H <sub>2</sub> O)	15.5	21.5	+6	Average PIP of Patients who Remained Intubated (cm-H <sub>2</sub> O)	19.5	24.7	+5.5
Individual Patient Metrics				Individual Patient Metrics			
Patient 1	15	21	+6*	Patient 1	-	-	-
Patient 2	15	15	0	Patient 2	-	-	-*^
Patient 3	16	11	-5	Patient 3	-	-	-
Patient 4	16	7	-9	Patient 4	18	20	+2^
Patient 5	13	12	-1	Patient 5	14	13	-1^
Patient 6	16	22	+6*	Patient 6	20	24	+4*^
Patient 7	13	13	0	Patient 7	21	36	+15*
				Patient 8	11	17	+6
				Patient 9	-	-	-
				Patient 10	14	14	0
				Patient 11	-	-	-
				Patient 12	-	-	-
				Patient 13	17	19	+2^

\* remained intubated postoperatively

^ home oxygen requirement

- not reported



Plastic Surgery	Pediatric Surgery (non-neonatal)			
	Patient 14	16	11	-5
	Patient 15	12	10	-2
	Patient 16	14	12	-2
	Patient 17	17	18	-1 *^
	Patient 18	-	-	- ^
	Patient 19	18	12	-6
	Patient 20	15	15	0
	Patient 21	13	15	+ 2
	Patient 22	24	25	+ 1 *^
	Patient 23	17	26	+ 9 *
	Patient 24	-	-	- *
	Patient 25	18	19	+ 1 *^
* remained intubated postoperatively				
^ home oxygen requirement				
- not reported				

Zero complications or recurrences were recorded following Plastic Surgery abdominal wall reconstruction. Average postoperative follow up time by Plastic Surgery was 16.7 months (range 0.3–51.8 months). In the Pediatric Surgery cohort, five patients (10%) expired from cardiopulmonary collapse, three of whom had repairs in the neonatal period and two of whom underwent repairs after the neonatal period. All five patients who expired had comorbidities and/or peripartum ruptured omphalocele. Ten (20.0%) patients in the Pediatric Surgery cohort had complications following abdominal wall reconstruction requiring surgical intervention; of note, two of these patients received neonatal repair. Complications included: small bowel obstruction (n = 5) requiring exploratory laparotomy with adhesiolysis, mesh infection (n = 6), wound dehiscence (n = 2), and suture abscesses (n = 2); one (2.0%) patient had a persistent ventral hernia two years after abdominal wall reconstruction. Average postoperative follow up time was 23.8 months (range: 0–162.3).

## Discussion

The goal of abdominal wall reconstruction in pediatric patients should be primary closure of the abdominal wall in as few procedures as possible. If primary closure is unachievable, adjuncts such as tissue expanders, component separation, and mesh implantation can be considered. Of the 57 patients reviewed, only seven patients (12.3%) were referred to and intervened on by Plastic Surgery. Despite the significantly larger defects seen in the Plastic Surgery cohort, 0% of patients required mesh compared to eight patients (16%) who had mesh implanted by Pediatric Surgery, all of whom had giant omphaloceles. As noted above, four patients who had mesh implanted by Pediatric Surgery developed infections and required explantation. In both peripartum ruptured and giant omphaloceles, the most common complication and cause of mortality is sepsis [7]; accordingly, infection prevention and management are paramount, which can be mitigated by primary fascial closure and avoidance of foreign body usage.

Complications of omphalocele repairs can be secondary to surgical technique or the inherent nature of the disease. Creation of a subcutaneous space via tissue expander placement or component separation can lead to seroma, hematoma, or abscess formation [8]. In addition, use of bioabsorbable materials in abdominal wall repairs has been shown to induce inflammation and foreign body reactions. Zero patients in the Plastic Surgery cohort had recurrence of the defect at their most recent follow-up; however, long-term followup of these patients will be needed to monitor for evidence of hernia [4] and/or enterocutaneous fistula formation [9], which can be precipitated by mesh use. These trends should be compared to patients who had mesh implanted to assess long-term outcomes and efficacy of repair techniques. Future research should follow patients who have matured out of pediatric clinics to evaluate the incidence of hernias in adults with Plastic Surgery-repaired omphaloceles.

A number of case reports have demonstrated the successful management of large omphalocele soft tissue defects using tissue expanders [10, 11]. These expanders can be placed in a variety of tissue planes, including the intramuscular plane between the internal oblique and the transversus abdominis or the subcutaneous plane [12, 13]. Three patients (42.8%) treated in combination with Plastic Surgery underwent tissue expander placement prior to omphalocele repair. In certain instances, the overlying tissues will not accommodate tissue expander placement with large loss of domain, necessitating component separation. In these cases, we advocate for preoperative discussion between Pediatric Surgery and Plastic Surgery teams for component separation and complex closure. Of note, these expanders were placed in collaboration with Plastic Surgery at the request of Pediatric Surgery with plan for closure by the latter team; this inciting event should rather set the stage for collaborative surgical efforts when managing abdominal wall reconstruction for omphalocele, especially given the early realization of tissue limitations and need for future complex closure. Additionally, Plastic Surgery consultation should also be considered in cases of revisional surgery given the potential for scar revision and soft tissue rearrangement.

There is a strong relationship between omphalocele size with morbidity and mortality. Many children with omphaloceles have concurrent comorbidities, chromosomal abnormalities, and syndromes/sequences. Often, these patients have various respiratory conditions secondary to limited chest wall growth and resultant pulmonary hypoplasia [3, 14]. Primary respiratory insufficiency, such as pulmonary hypertension

and pulmonary hypoplasia, requiring positive pressure ventilation at birth is an independent risk factor for mortality in patients with omphaloceles [15, 16]. Surgical intervention aimed at reducing the extracorporeal viscera can cause secondary respiratory insufficiency due to increased abdominal pressures and the elevated diaphragm, further worsening underlying pulmonary disease [17, 18]. Surgical closure has been shown to reduce forced vital capacity (FVC), maximum expiratory flow at 25% of vital capacity (MEF<sub>25</sub>), and pulmonary compliance [19]. Changes in FVC and MEF<sub>25</sub> are suggested to be temporary [20], yet lung compliance does not change, and thus, these patients may require postoperative ventilatory support. Of the patients who underwent repair by Plastic Surgery, two (28.6%) remained intubated postoperatively given elevated PIP at surgery stop time compared to start time. In addition, these two patients had underlying cardiopulmonary disease, furthering the decision for postoperative ventilation. Interestingly, there was no significant difference between the number of Plastic Surgery and Pediatric Surgery patients requiring postoperative mechanical ventilation ( $p = 0.863$ ). Factors such as underlying pulmonary disease and comorbidities, omphalocele size, and changes in intraoperative ventilatory parameters should all be assessed when deciding to extubate postoperatively.

While an inherent selection bias exists for patients who present to Plastic Surgery clinic for abdominal wall reconstruction, the number of patients with comorbidities was not significantly different across cohorts. However, the data indicates that the Pediatric Surgery patients had more severe and multiple comorbidities compared to the Plastic Surgery cohort, which is further highlighted by the higher mortality rate (10%) in the Pediatric Surgery cohort. Given this increased morbidity, we advocate for Plastic Surgery and Pediatric Surgery collaboration for component separation and assistance with fascial closure to mitigate mesh use and decrease infection risk, especially in giant omphaloceles.

We present a collaborative approach between Pediatric Surgery and Plastic Surgery to abdominal wall reconstruction for giant omphaloceles. Our results demonstrate favorable outcomes with primary fascial closure without the need for mesh and highlight the benefits of adjunctive techniques, such as component separation, for abdominal wall reconstruction. Lastly, postoperative ventilation should be considered based on intraoperative parameters, pre-existing comorbidities, and communication with the anesthesia team to ensure patient safety during abdominal wall reconstruction and closure.

## Declarations

## Funding Statement:

This manuscript did not receive any institutional or private funding.

## References

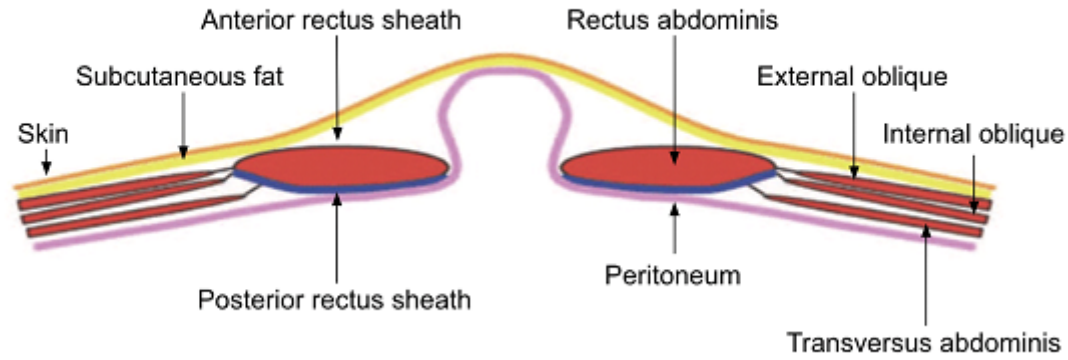
1. Mai CT, Isenburg JL, Canfield MA, Meyer RE, Correa A, Alverson CJ, et al. National population-based estimates for major birth defects, 2010–2014. *Birth Defects Res.* 2019 Nov 1;111(18):1420–35.

2. Prefumo F, Izzi C. Fetal abdominal wall defects. *Best Pract Res Clin Obstet Gynaecol*. 2014 Apr;28(3):391–402.
3. Verla MA, Style CC, Olutoye OO. Prenatal diagnosis and management of omphalocele [Internet]. Vol. 28, *Seminars in Pediatric Surgery*. 2019. p. 84–8. Available from: <http://dx.doi.org/10.1053/j.sempedsurg.2019.04.007>
4. Gonzalez KW, Chandler NM. Ruptured omphalocele: Diagnosis and management. *Semin Pediatr Surg*. 2019 Apr;28(2):101–5.
5. Logsdon NT, Gallo CM, Favorito LA, Sampaio FJ. Investigation of a connection between abdominal wall defects and severity of the herniation in fetuses with gastroschisis and omphalocele. *Sci Rep*. 2021 Jan 8;11(1):27.
6. Barrios Sanjuanelo A, Abelló Munarriz C, Cardona-Arias JA. Systematic review of mortality associated with neonatal primary staged closure of giant omphalocele. *J Pediatr Surg*. 2021 Apr;56(4):678–85.
7. Saxena AK, Raicevic M. Predictors of mortality in neonates with giant omphaloceles. *Minerva Pediatr*. 2018 Jun;70(3):289–95.
8. Levy S, Tsao K, Cox CS Jr, Phatak UR, Lally KP, Andrassy RJ. Component separation for complex congenital abdominal wall defects: not just for adults anymore. *J Pediatr Surg*. 2013 Dec;48(12):2525–9.
9. Zmora O, Castle SL, Papillon S, Stein JE. The biological prosthesis is a viable option for abdominal wall reconstruction in pediatric high risk defects. *Am J Surg*. 2017 Sep;214(3):479–82.
10. Martin AE, Khan A, Kim DS, Muratore CS, Luks FI. The use of intraabdominal tissue expanders as a primary strategy for closure of giant omphaloceles. *J Pediatr Surg*. 2009 Jan;44(1):178–82.
11. Adetayo OA, Aka AA, Ray AO. The use of intra-abdominal tissue expansion for the management of giant omphaloceles: review of literature and a case report. *Ann Plast Surg*. 2012 Jul;69(1):104–8.
12. Zhang ZZ, Haddock C, Verchere C, Arneja JS, Skarsgard ED. Management of narrow stalked giant omphalocele using tissue expansion, staged closure, and amnion preservation technique. *Journal of Pediatric Surgery Case Reports*. 2019 Dec 1;51:101311.
13. Shah RS, Parelkar SV, Sanghvi BV, Gupta RK, Mudkhedkar KP. Staged repair of giant exomphalos major using tissue expanders. *Journal of Pediatric Surgery Case Reports*. 2016 Oct 1;13:13–7.
14. Griscom NT, Driscoll SG. Radiography of stillborn fetuses and infants dying at birth. *AJR Am J Roentgenol*. 1980 Mar;134(3):485–9.
15. Tsakayannis DE, Zurakowski D, Lillehei CW. Respiratory insufficiency at birth: a predictor of mortality for infants with omphalocele. *J Pediatr Surg*. 1996 Aug;31(8):1088–90; discussion 1090–1.
16. Baerg JE, Thorpe DL, Sharp NE, Ramlogan SR, Hutson SM, Goff DA, et al. Pulmonary hypertension predicts mortality in infants with omphalocele. *J Neonatal Perinatal Med*. 2015;8(4):333–8.
17. Ein SH, Rubin SZ. Gastroschisis: Primary closure or Silon pouch [Internet]. Vol. 15, *Journal of Pediatric Surgery*. 1980. p. 549–52. Available from: <http://dx.doi.org/10.1016/s0022->

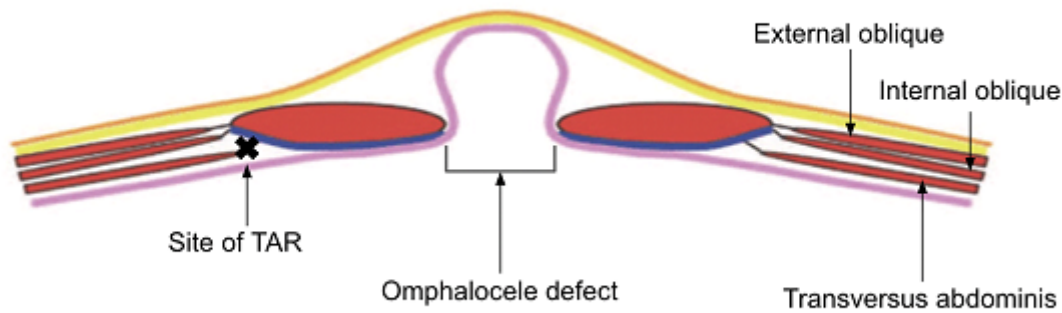
3468(80)80771-8

18. Duggan E, Puligandla PS. Respiratory disorders in patients with omphalocele. *Semin Pediatr Surg.* 2019 Apr;28(2):115–7.
19. Nakayama DK, Motoyama EK, Tagge EM. Effect of preoperative stabilization on respiratory system compliance and outcome in newborn infants with congenital diaphragmatic hernia [Internet]. Vol. 118, *The Journal of Pediatrics.* 1991. p. 793–9. Available from: [http://dx.doi.org/10.1016/s0022-3476\(05\)80048-4](http://dx.doi.org/10.1016/s0022-3476(05)80048-4)
20. Dimitriou G, Greenough A, Giffin F, Davenport M, Nicolaidis KH. Temporary impairment of lung function in infants with anterior abdominal wall defects who have undergone surgery. *J Pediatr Surg.* 1996 May;31(5):670–2.

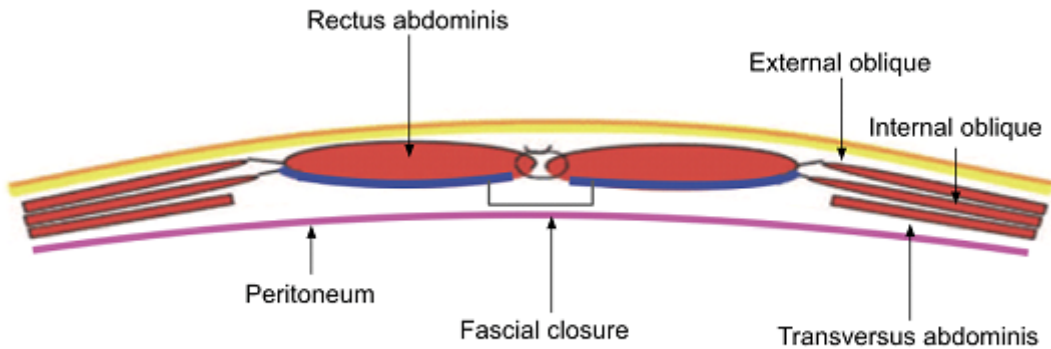
## Figures



**a**



**b**



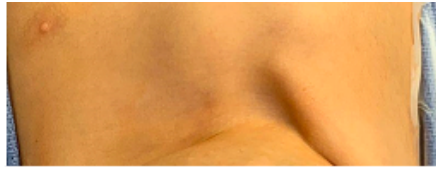
**c**

**Figure 1**

**a** Layers of abdominal wall

**b** Abdominal wall with component separation for omphalocele defect: transversus abdominis release (TAR)

**c** Abdominal wall following component separation and fascial closure

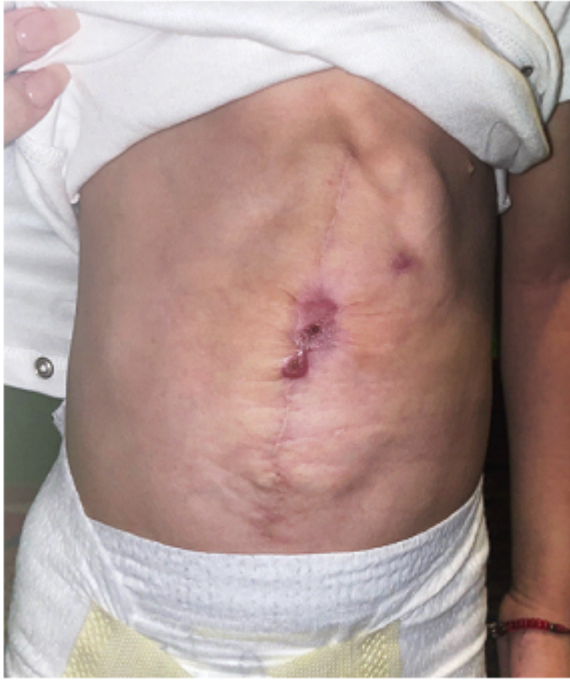


**Figure 2**

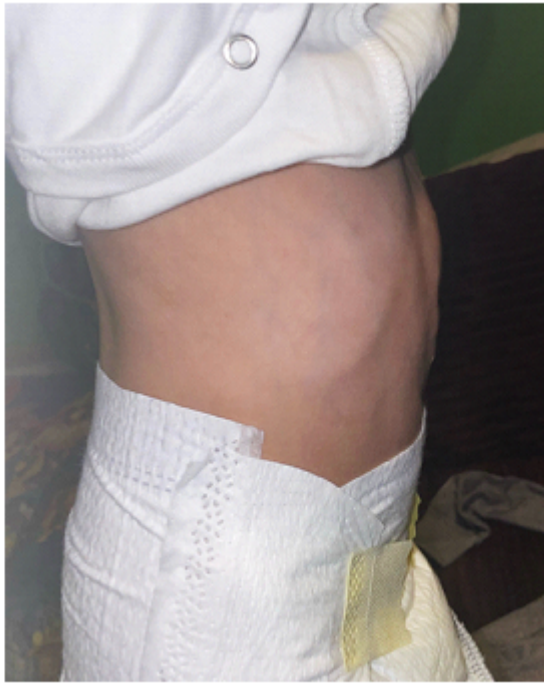**a** Anterior view of an epithelialized giant omphalocele in a 3-year-old patient

**b** Lateral view of giant omphalocele

**c** On-table photo following skin closure



**a**



**b**

**Figure 3**

**a** Healing surgical site following omphalocele closure, anterior view

**b** Lateral view