Haemodynamic Analysis of Single And Double Bare-metal Stents For Coronary Artery Aneurysm

Zhuoxuan Yang
Chinese Academy of Medical Sciences & Peking Union Medical College Fuwai Hospital
Jiansong Yuan
Chinese Academy of Medical Sciences & Peking Union Medical College Fuwai Hospital
Jingang Cui
Chinese Academy of Medical Sciences & Peking Union Medical College Fuwai Hospital
Wenyu Fu
Beijing Union University
Aike Qiao
Beijing University of Technology
Shubin Qiao (qsbfw@sina.com)
Department of Cardiology, Chinese Academy of Medical Sciences Fuwai Hospital No.167 North Lishi Road, Xicheng District, Beijing, 100037 China https://orcid.org/0000-0002-2956-7233

Research article

Keywords: Haemodynamic analysis, coronary artery aneurysm, bare-metal stents

Posted Date: January 15th, 2021

DOI: https://doi.org/10.21203/rs.3.rs-144021/v1

Abstract

Background The aim of this study was to investigate a novel method to treat coronary artery aneurysms(CAAs).

Methods Three CAAs patients who underwent single or double bare-metal stent implantation were recruited. The CAAs and parent artery diameters were measured for model construction. Single- and double-stent implantation were simulated, and the changes in the CAAs haemodynamics after stenting were analysed.

Results In Case 1, the flow velocity in the single-stent model was significantly lower than that in the double-stent model (0.0046±0.013 vs 0.0050±0.011, $p<0.001$), while the pressure (127.33±18.03 vs 121.19±26.92, $p<0.001$) and wall shear stress (WSS, 0.28±1.19 vs 0.22±1.13, $p<0.001$) were significantly higher. In Case 2, the flow velocity (0.005±0.011 vs 0.007±0.01, $p<0.001$) and WSS (0.17±0.82 vs 0.23±0.88, $p<0.001$) in the double-stent model were significantly lower than those in the single-stent model, while the pressure was significantly higher(117.70±10.07 vs 110.64±6.34, $p<0.001$). The same tendency was also observed in Case 3. All CAAs occluded during the follow-up period without obvious in-stent restenosis.

Conclusion Application of the single or double bare-metal stent technique, according to the neck diameter of the coronary artery aneurysms, can effectively change the flow in vessels and aneurysm haemodynamics to achieve occlusion.

Trail registration: Clinicaltrails, NCT04265989. Registered 12 February 2020, https://clinicaltrials.gov/ct2/show/NCT04265989?term=NCT04265989&draw=2&rank=1

Background

Bougon reported the first fatal case of ruptured coronary artery aneurysm (CAA) in 1812[1]. CAA refers to focal dilation of the diameter of the artery in excess of 50% of the diameter of the adjacent normal segment. According to whether the dilatation scope exceeds 50% of the whole length of the parent artery, it is divided into CAA (<50%) and coronary artery ectasia (CAE) (>50%)[2]. The incidence rate of CAA is less than 1% in angiography[3-6].

The aetiology of CAA varies, with atherosclerosis accounting for approximately 50% of cases. Other factors include coronary artery fistula, immune system disease, inflammatory disease, connective tissue disease and so on[7]. Most CAA patients have no obvious clinical symptoms, and a small number of them may suffer from angina pectoris, myocardial infarction, cardiac tamponade caused by aneurysm rupture or even sudden death due to slow flow and thrombosis.

Given the low incidence of CAA, most of what is reported in the literature is case reports[8-11] or small sample studies[12-14], and there are no guidelines for or universal consensus on treatment, so the therapeutic regimen relies on doctors' experience. Treatments include conservation therapy, interventional therapy and surgery. Interventional therapy includes the use of polytetrafluoroethylene-covered stents and stent-assisted coiling to seal the CAA[2]. However, these two interventions require operators with high skill levels; moreover, some disadvantages, such as the high incidence of in-stent restenosis (ISR) [13]and high cost, should also be considered. Therefore, this study proposed the use of a single or double-layer bare-metal stent (SBMSs and DBMSs, respectively) to cover the neck of a CAA, combined with haemodynamic evaluation and patient follow-up to verify the feasibility of this technique.

Methods

1. Patient selection and CAA model construction

To investigate the range of application of this technique in CAAs with different neck diameters. We selected 3 different CAA neck sizes from patients who had an SBMS or DBMS implanted. The neck size of the CAA, maximum length and transverse length of the aneurysm, and parent artery diameter were measured, and the data were input into SolidWorks 2016 software (Dassault Systèmes SolidWorks Corporation, Waltham, MA, USA) for model construction.

Written informed consent was obtained from each patient included in the study. The study protocol conformed to the ethical guidelines of the 1975 Declaration of Helsinki, and the study protocol was approved by Fuwai Hospital's ethics committee on research in humans.

2. Stent model construction

The H-stent (Lepu Medical, Beijing, China) used in this study was made from 316L stainless steel with an elasticity of 200 GPa, Poisson's ratio of 0.3, and thickness of 89 μm. The stent mesh shape was square, covering an area of 91 μm*89 μm. The metal coverage (the ratio of the area covered by metal to the total area after the stent is expanded) was between 8 and 20%, the radial retraction rate was not greater than 10%, and the rate of axial shortening/elongation was less than 10%. The metal coverage rate was 15%, and the above parameters were input into SolidWorks 2016 software to construct a single-layer stent model (Fig. 1A). After successful construction, a double-layer stent model was constructed by adding a second layer on top of the single-layer strut . Common stacking situations were simulated. The two layers of struts were staggered, and the metal coverage rate and porosity of the double-layer stents were calculated as 28.7% and 71.3%, respectively(Fig. 1B).

3. Construction and meshing of CAA with the stent

On the basis of the above work, Boolean subtraction calculations related to the parent artery and stent model were performed in SolidWorks 2016 to obtain a scaffold model (Fig. 1C), which was output in *x_b format. Models of SBMS and DBMS implantation in the parent artery were simulated. The model files were entered into ANSYS ICEM CFD 14 software for gridding.

4. Boundary condition setting

Research shows that when the artery diameter is greater than 0.5 mm, the flow field error is less than 2% when a Newtonian fluid and non-Newtonian fluid model is adopted. Therefore, in this study, blood flow was simulated as adiabatic, incompressible and steady Newtonian laminar flow, and the blood density was 1056 kg/m3. Blood viscosity was 0.035 g/cm *(s)[15]. The average peak normal coronary flow velocity was between 0.2 and 0.4 m/s[16], and the inlet velocity was set to 0.4 m/s to verify the maximum effect of the stent on coronary blood flow in the resting state. The velocity was evenly distributed, the outlet pressure was set at 0, and the vessel wall was set as rigid without slip conditions. The blood flow followed the law of conservation of mass and momentum and conformed to the Navier-Stokes and continuity equations. The above settings were input to ANSYS ICEM CFD 14 software(Ansys Inc.,Berkeley,CA) to analyse the haemodynamics of stent-free, single-stent-loaded, and double-stent-loaded CAAs. The portion size was between 0.02 mm and 0.25 mm.

5. Statistical analysis

Continuous variables are presented as the mean±standard deviation. Between-group comparisons were conducted using one-way analysis of variance for continuous variables. Statistical analysis was performed using SPSS 22.0 Software (SPSS Inc. Chicago, Illinois, USA). A 2-tailed $P<0.05$ was considered significant.

Results

1. Demographic and clinical characteristics of the cases (Table 1)

Patient information is presented in Table 1. Case 1 underwent SBMS implantation, and the other two cases underwent DBMS implantation. All aneurysms were occluded without obvious ISR 12 months after the intervention.

2. Surgical procedure and postoperative follow-up

Figure 2 shows the intervention process and follow-up for Case 1. A CAA of 2.5*4 mm was found in the left artery descending (LAD) (Fig. 2A). A 3.0*12 mm H-stent was implanted (Fig. 2B). After the stent was released, coronary angiography indicated contrast retention in the CAA (Fig. 2C-E). At the follow-up one year after the intervention, the aneurysm had disappeared (Fig. 2F).

Figure 3 shows the intervention process and follow-up for Case 2. A CAA at the proximal LAD was observed before stenting (Fig. 3A), and 3.5 mm*25 mm and 3.5 mm*13 mm stents were implanted in turn (Fig. 3B-C). Angiography after stenting showed contrast retention in the CAA (Fig. 3 D-G). Angiography at the six-month follow-up showed occlusion of the CAA (Fig. 3H-I), and angiography (Fig. 3J-K) and optical coherence tomography (OCT) (Fig. 3 L) at the 5-year follow-up showed also that the aneurysm was also occluded and that the stent surface was covered by endothelial cells without obvious ISR.

Figure 4 shows the operation process and follow-up for Case 3. Saccular aneurysms distal to the right coronary artery (RCA) were observed before stenting (Fig. 4A). Stents of 3.5 mm*16 mm and *4.0 mm*24 mm were implanted in turn (Fig. 4B-C). Angiography 1 year after stenting showed that the aneurysm had occluded without ISR (Fig. 4D), and coronary computed tomography angiography indicated that the aneurysm had a low density (Fig. 4E-F).

2. Computational fluid dynamics in 3 cases

Computational fluid dynamics (CFD) analysis was performed on stent-free, single-stent and double-stent models for each case (Table 2). After implantation of a single-layer stent in Case 1, the blood flow velocity (0.0066 ± 0.015 vs 0.0046 ± 0.013, $p<0.001$) and wall shear stress (WSS) (0.51 ± 1.35 vs 0.281.19, $p<0.001$) in the CAA were significantly lower than those in the stent-free model, and the pressure in CAA was also increased (126.95 ± 12.65 vs 127.33 ± 18.03, $p<0.001$). However, after implantation of the second stent, the flow velocity increased compared with that of the single stent (0.0050 ± 0.011 vs 0.0046 ± 0.013 $p<0.001$), and the pressure also showed a downward trend (121.19 ± 26.92 vs 127.33 ± 18.03, $p<0.001$). In Case 2, the flow velocity in the double-stent model was significantly slower than that in the single-stent and stent-free models (0.005 ± 0.011 vs 0.007 ± 0.013 vs 0.013 ± 0.02, $p<0.001$, respectively), and the WSS had also decreased (0.17 ± 0.82 vs 0.23 ± 0.88 vs 0.23 ± 0.50, $p<0.001$, respectively). The wall pressure increased significantly (117.70 ± 10.07 vs 110.64 ± 6.34 vs 103.28 ± 11.69, $p<0.001$). However, the WSS in the single-stent model was not significantly different from that in the stent-free model (0.23 ± 0.8 vs 0.23 ± 0.50, $P=0.76$). In Case 3, the flow velocity (0.0072 ± 0.0093 vs 0.0079 ± 0.0109 vs 0.012 ± 0.018, $p<0.001$, respectively) and WSS (0.10 ± 0.48 vs 0.14 ± 0.58 vs 0.17 ± 0.58, $p<0.001$) of the double stent were significantly decreased compared with those of the single stent and the stent-free condition. The pressure was also significantly higher (97.33 ± 7.92 vs 92.51 ± 5.78 vs 85.42 ± 4.82, $p<0.001$, respectively). In contrast to Case 2, the WSS in the single stent of Case 3 was significantly lower than that in the stent-free condition (0.14 ± 0.58 vs 0.17 ± 0.58, $p<0.001$).

Figure 5 shows the WSS and streamline in the stent-free, single-stent and double-stent conditions in the 3 cases. The streamline shows the movement of particles in the blood. As seen from the figure, with the successive implantation of stents, the area of low WSS in the CAA gradually expanded, and the movement trajectory of blood particles decreased significantly (see video in the Supplemental Materials).

Discussion

The main findings of this study are as follows: 1) single or double bare-metal stents covering the neck of aneurysms can significantly change the flow in the parent artery and the haemodynamics of the aneurysm to achieve occlusion; 2) CAAs with a neck diameter of less than 5 mm and without adjacent stenosis can be treated with a single bare-metal stent; 3) CAAs with a neck diameter of 5-12 mm and no adjacent stenosis can be treated with double metal stents; and 4) no obvious ISR was found during follow-up.

CFD analysis can be used to simulate and analyse convective physicochemical problems, which helps to understand the haemodynamic changes in arteries resulting from abnormal structures. Therefore, it is widely used in cases of cerebral aneurysms[15,17] and thoracic and abdominal aortic aneurysms[18], while it is rarely used in the study of coronary aneurysms.

In this cerebral aneurysm intervention study, it was found that flow velocity, pressure and WSS were the most important parameters affecting the development of cerebral aneurysms[19]. Flow velocity affected the formation of intracranial thrombi, and pressure and WSS were closely related to structural changes in the aneurysm wall. This study found that after stent implantation, the flow velocity and WSS in the CAA gradually declined, while the wall pressure increased(Table 2). The reason for this is due to the existence of the stent; the permeability of the flow inlet of the CAA was reduced, while a double stent makes this permeability even lower. In Case 1, after implantation of the second stent, the flow velocity in the CAA increased rather than decreased. This abnormal change may have been due to the small range in aneurysm neck diameter (<5 mm) and the change in permeability of the double-layer stents compared with the single-layer stents, which had a limited influence on the haemodynamics in the CAA. This indicates that for a CAA with a neck diameter of less than 5 mm, a single stent can effectively change the haemodynamics of the CAA and reduce the flow velocity.

In this study, the CAA pressure in the double-stent model was higher than that in the single-stent and stent-free models in Cases 2 and 3. Contrast retention was also found in the CAA after stent release. The reason for the increase in pressure was also due to the increased resistance of the outlet flow from the CAA due to stent implantation. This is consistent with the studies in cerebral aneurysms[20].

WSS is the tangential friction between the flow and the vessel wall per unit area. In Case 2, the WSS in the CAA after implantation of a single stent showed no significant difference compared with the stent-free condition, while after implantation of the second stent, the WSS was significantly reduced. This suggests that double-stent placement could influence the haemodynamics in the CAA significantly more than single-stent placement. In Case 3, a significant reduction in WSS was observed after the implantation of a single stent. After implantation of the second stent, the WSS decreased further. As shown in Figure 5, with stent implantation, the low WSS area in the CAA of the 3 cases was significantly increased. Malek[21] found that WSS is an important indicator of CAA growth. When the WSS in the vessel wall is lower than 1.5 Pa, a macrophage-related inflammatory response can be induced, as can endothelial cell degeneration and apoptosis. By regulating the expression level of metalloproteinases, elastic fibres and collagen fibres in the artery wall are broken and absent, causing aneurysm growth and rupture.

Stent design and porosity are important factors in the outcome of aneurysm intervention[15,22]. Kim et al[15] found that the “square mesh” stent shape was more effective in changing the velocity and WSS in cerebral aneurysms than the “ring mesh” stent shape. Lieber's[22] study found that the haemodynamic changes in aneurysms were most pronounced when the porosity dropped to 76% but not noticeable when the porosity was lower than 70%. The range of metal coverage used for aneurysm treatment is generally between 60% and 86%, and the lower limit of this range is usually achieved by overlapping 2-layer stents[23,24]. However, metal coverage< 60% will lead to poor biocompatibility and high operational difficulty when stents are delivered through curved arteries[22]. The H-stent had a square mesh design with metal coverage of 10-20%. When double-layer stents were superimposed, the metal coverage was approximately 71.3%, which was just within the range that has the greatest influence on haemodynamics.

In terms of material, the bare-metal stents were made of 316L stainless steel, which is suitable for the growth of new endothelial cells due to the absence of dug coatings. However, with the process of epithelialization, the permeability of the inlet is further reduced, and thrombosis in the CAA is promoted. OCT follow-up in Case 2 suggested that the stent surface was completely covered by neointima without excessive proliferation. Commercially covered stents contain polyfluortetraethylene (PTFE), which has poor biocompatibility and could affect epithelialization, leading to ISR. The PTFE study[13] suggests that the incidence of subacute stent thrombosis in covered stents was 5.7%, while the incidence of ISR was as high as 31.6% (29.8% at the stent edge, 8.8% in the middle). RECOVERS studies[25] have found similar results, and the incidence of subacute thrombosis within 30 days of PTFE stent placement was higher than that of traditional stent placement. Hachinohe et al[26] performed a retrospective study of 190 patients implanted with PTFE-covered stents over 20 years and found that target vessel myocardial infarction, occlusion, revascularization and in-stent thrombosis events occurred at the early stage after stent implantation, and their incidence increased gradually in the long-term follow-up.

Stent compliance is one of the key factors of operation difficulty. Commercially covered stents, such as Graftmaster stents, generally have a sandwich structure, that is composed of a 50-μm thick PTFE layer between 2 stainless steel stents. Due to the poor compliance of covered stents, the operation difficulty is increased if there is obvious bending or narrowing of the vessels during delivery, and there are even reports that the operational strategy has been changed accordingly[27-28]. Covered stents are not suitable for segments with branches. Sequential bare-metal stent release can not only maintain good stent compliance without increasing the difficulty of the operation but also enable strategic adjustment according to the location of the branches to preserve the branch flow as much as possible. Finally, the longest covered stent is 28 mm, and the longest bare-metal stents can reach 30 mm, indicating a slight advantage of bare-metal stents in terms of stent length.

In terms of antiplatelet therapy, because covered stents are associated with a high incidence of ISR, physicians tend to choose a dual antiplatelet combination with a small dose of oral anticoagulants (such as warfarin), which increases the risk of bleeding. However, if patients are implanted with bare-metal stents without complications that they must use oral anticoagulants for (atrial fibrillation, deep venous thrombosis, etc.), they need to take dual antiplatelet drugs for only 6-12 months, which could reduce the risk of bleeding compared to covered stent therapy.

Limitations

This study has some limitations. First, the core of the DBMS technique is to reduce the porosity of the inlet area of the CAA. However, in practice, the second implanted stent cannot be accurately positioned.

There is a very small chance of complete overlap of the struts of the two stents, which prohibits the stent porosity from being further reduced and delays CAA occlusion. Second, this study used a CAA model without adjacent stenosis. The main objective was to investigate the effects of SBMSs and DBMSs on the haemodynamics of CAAs. The use of simplified models is more conducive to finding common features of diseases and treatments. CAAs with adjacent stenosis will be included in future studies. Third, in previous interventions, the longest CAA neck was closed with DBMSs of 22 mm[29]. The maximum neck length applicable to this technique remains to be further studied.

Conclusion

The application of SBMSs and DBMSs to cover the neck of CAAs can effectively change the flow in vessels and the haemodynamic state in the aneurysm, causing thermogenesis in the CAA. The SBMS and DBMS techniques were selected according to the CAA neck diameter. The proposed technique is an effective method for interventional treatment of CAAs that does not increase the incidence of ISR or the difficulty of the operation.

List Of Abbrievation

CAA coronary artery aneurysm

WSS wall shear stress

CAE coronary artery ectasia

ISR in-stent restenosis

SBMS single-layer bare-metal stent

DBMS double-layer bare-metal stent

OCT optical coherence tomography

CFD Computational fluid dynamics

PTFE polyfluortetraethylene

Declarations

Ethics approval and consent to participate The study is approved and consent by Fuwai Hospital Ethics Committee.

Consent for publication Not applicable

Availability of data and materials The datasets used and analysed during the current study are available from the corresponding author on reasonable request

Competing interests The authors declare that they have no competing interests

Funding: Clinical and Translational Foundation of The Chinese Academy of Medical Sciences (2019XK320064) has provide financial support to the research.

Authors' contributions: ZXY and SBQ contributed to drafting and revising the manuscript. JSY contributed to the Statistical analysis and coronary angiography operation. JGC contributed to follow up and drafting results. WYF and AKQ contributed to the stent and coronary aneurysm model construction and computational fluid dynamics. All the authors critically revised the manuscript and gave final approval and agreed to be accountable for all aspects of the work, ensuring both its integrity and accuracy.

Acknowledgements Yujia Yang of Faculty of Environment and Life, Beijing University of Technology, has provided valuable assistance in the extraction of model data.

References

1. Jarcho S (1969) Bougon on coronary aneurysm (1812). Am J Cardiol 24 (4):551-553. doi:10.1016/0002-9149(69)90500-1
2. Kawsara A, Nunez Gil IJ, Alqahtani F, Moreland J, Rihal CS, Alkhouli M (2018) Management of Coronary Artery Aneurysms. JACC Cardiovasc Interv 11 (13):1211-1223. doi:10.1016/j.jcin.2018.02.041
3. Nunez-Gil IJ, Nunez-Gil IJ, Terol B, Feltes G, Nombela-Franco L, Salinas P, Escaned J, Jimenez-Quevedo P, Gonzalo N, Vivas D, Bautista D, Macaya C, Fernandez-Ortiz A (2018) Coronary aneurysms in the acute patient: Incidence, characterization and long-term management results. Cardiovasc Revasc Med 19 (5 Pt B):589-596. doi:10.1016/j.carrev.2017.12.003.
4. Iannopollo G, Ferlini M, Kozinski M, Ormezzano MF, Crimi G, Lanfranchi L, Camporotondo R, Visconti LO, De Ferrari GM, De Servi S (2017) Patient Outcomes With STEMI Caused by Aneurysmal Coronary Artery Disease and Treated With Primary PCI. J Am Coll Cardiol 69 (24):3006-3007. doi:10.1016/j.jacc.2017.04.030.
5. Ipek G, Ipek G, Gungor B, Karatas MB, Onuk T, Keskin M, Tanik O, Hayiroglu MI, Oz A, Borklu EB, Bolca O (2016) Risk factors and outcomes in patients with ectatic infarct-related artery who underwent primary percutaneous coronary intervention after ST elevated myocardial infarction. Catheter Cardiovasc Interv 88 (5):748-753. doi:10.1002/ccd.26553.
6. Joo HJ, Woong Yu C, Choi R, Park J, Lee HJ, Kim JS, Choi YJ, Park JH, Hong SJ, Lim DS (2018) Clinical outcomes of patients with coronary artery aneurysm after the first generation drug-eluting stent implantation. Catheter Cardiovasc Interv 92 (3):E235-E245. doi:10.1002/ccd.27429.

7. ElGuindy MS, ElGuindy AM (2017) Aneurysmal coronary artery disease: An overview. Glob Cardiol Sci Pract 2017 (3):e201726. doi:10.21542/gcsp.2017.26
8. Antileo P, Dauvergne C, Mendez M, Alvarado M, Sepulveda O, Monsalve R, Sandoval J (2019) Percutaneous intervention of coronary aneurysm. Cardiovasc Revasc Med. doi:10.1016/j.carrev.2019.08.014
9. Cereda AF, Tiberti G, Pera IG, Cantu E, Ferri LA, Savonitto S, Piatti L (2017) A Giant Coronary Artery Aneurysm Treated Using Multiple Overlapping Covered Stents. JACC Cardiovasc Interv 10 (13):e127-e128. doi:10.1016/j.jcin.2017.04.030
10. Chou HH, Huang HL, Ko YL (2018) Acute Myocardial Infarction Due to Prolapse of Covered Stent Into Coronary Artery Aneurysm. JACC Cardiovasc Interv 11 (18):e147-e148. doi:10.1016/j.jcin.2018.07.013
11. Cotter R, Krantz M, Hogan S, Holland M (2019) Exclusion of a Giant Coronary Artery Aneurysm With Covered Stents Using a Long Drug-Eluting Stent Scaffold. Clin Med Insights Case Rep 12:1179547619828689. doi:10.1177/1179547619828689
12. Briguori C, Sarais C, Sivieri G, Takagi T, Di Mario C, Colombo A (2002) Polytetrafluoroethylene-covered stent and coronary artery aneurysms. Catheter Cardiovasc Interv 55 (3):326-330. doi:10.1002/ccd.10063
13. Gercken U, Lansky AJ, Buellesfeld L, Desai K, Badereldin M, Mueller R, Selbach G, Leon MB, Grube E (2002) Results of the Jostent coronary stent graft implantation in various clinical settings: procedural and follow-up results. Catheter Cardiovasc Interv 56 (3):353-360. doi:10.1002/ccd.10223
14. Szalat A, Durst R, Cohen A, Lotan C (2005) Use of polytetrafluoroethylene-covered stent for treatment of coronary artery aneurysm. Catheter Cardiovasc Interv 66 (2):203-208. doi:10.1002/ccd.20448
15. Kim M, Taulbee DB, Tremmel M, Meng H (2008) Comparison of two stents in modifying cerebral aneurysm hemodynamics. Ann Biomed Eng 36 (5):726-741. doi:10.1007/s10439-008-9449-4
16. Bach R G , Kern M J . Practical coronary physiology. Clinical application of the Doppler flow velocity guide wire[J]. Cardiology Clinics, 1997, 15(1):77.
17. Kojima M, Irie K, Fukuda T, Arai F, Hirose Y, Negoro M (2012) The study of flow diversion effects on aneurysm using multiple enterprise stents and two flow diverters. Asian J Neurosurg 7 (4):159-165. doi:10.4103/1793-5482.106643
18. Polydorou A▯Henry M▯Bellenis I▯el a1▯Endovaseular treatment of arterial aneurysms with side-branches a simple method▯Myth or reality?[J]▯Hospital Chronicles▯2010▯2(5)▯88-94
19. Appanaboyina S , Castro M A , Cebral J R . Simulation of endovascular interventions of cerebral aneurysms: techniques and evaluation[C]// Proc Spie Medical Imaging: Physics of Medical Imaging. 2005.
20. Fu W, Gu Z, Meng X, Chu B, Qiao A (2010) Numerical simulation of hemodynamics in stented internal carotid aneurysm based on patient-specific model. J Biomech 43 (7):1337-1342. doi:10.1016/j.jbiomech.2010.01.009

21. Malek AM, Alper SL, Izumo S (1999) Hemodynamic shear stress and its role in atherosclerosis. JAMA 282 (21):2035-2042. doi:10.1001/jama.282.21.2035
22. Lieber BB, Stancampiano AP, Wakhloo AK (1997) Alteration of hemodynamics in aneurysm models by stenting: influence of stent porosity. Ann Biomed Eng 25 (3):460-469. doi:10.1007/BF02684187
23. Liou TM, Li YC (2008) Effects of stent porosity on hemodynamics in a sidewall aneurysm model. J Biomech 41 (6):1174-1183. doi:10.1016/j.jbiomech.2008.01.025
24. Anzai H, Yoshida Y, Sugiyama S, Endo H, Matsumoto Y, Ohta M (2015) Porosity dependency of an optimized stent design for an intracranial aneurysm. Technol Health Care 23 (5):547-556. doi:10.3233/THC-151007
25. Stankovic G, Colombo A, Presbitero P, van den Branden F, Inglese L, Cernigliaro C, Niccoli L, Bartorelli AL, Rubartelli P, Reifart N, Heyndrickx GR, Saunamaki K, Morice MC, Sgura FA, Di Mario C, Randomized Evaluation of polytetrafluoroethylene CsiSvgi (2003) Randomized evaluation of polytetrafluoroethylene-covered stent in saphenous vein grafts: the Randomized Evaluation of polytetrafluoroethylene COVERed stent in Saphenous vein grafts (RECOVERS) Trial. Circulation 108 (1):37-42. doi:10.1161/01.CIR.0000079106.71097.1C
26. Hachinohe D, Latib A, Laricchia A, Iannopollo G, Demir OM, Ancona MB, Mangieri A, Regazzoli D, Giannini F, Azzalini L, Mitomo S, Chieffo A, Montorfano M, Carlino M, Colombo A (2019) Long-term follow-up of covered stent implantation for various coronary artery diseases. Catheter Cardiovasc Interv 94 (4):571-577. doi:10.1002/ccd.28117
27. Kim TH, Marfatia R, Lee J, Azrin M (2017) Giant coronary aneurysm management with Viabahn covered stent. Cardiovasc Revasc Med 18 (6S1):56-59. doi:10.1016/j.carrev.2017.03.019
28. Orlic D, Vitrella G, Corvaja N, Colombo A (2006) New technique to seal a long giant coronary aneurysm with PTFE-covered stents: a case report. Catheter Cardiovasc Interv 67 (1):41-45. doi:10.1002/ccd.20523
29. Qiao S, Xiaowei J, Cui J, Li J, Yuan J, Liu S, Gao L, Zhao J, Chen H, Ma J (2019) Double-layer bare metal stents in the treatment of coronary artery aneurysm: experience and outcomes in nine patients. EuroIntervention 15 (7):644-646. doi:10.4244/EIJ-D-18-01093

Tables

Table 1. Demographic and clinical characteristics of cases

	Case 1	Case 2	Case 3
Gender	Male	Female	Male
Age	58	67	44
Location of aneurysm	LAD	LAD	RCA
Size of aneurysm (Length*Width,mm)	2.5*4	10*8	16*13
Size of aneurysmal neck (mm)	4	8	12
Size of Parent coronary artery (mm)	2.3	3	4
Stent(diameter*length)	3.0mm*12mm	3.5mm*25mm 3.5mm*13mm	3.5mm*16mm 4.0mm*24mm
Antiplatelet therapy	Asprin 100mg/d Clopidogrel 75mg/d	Asprin 100mg/d Clopidogrel 75mg/d	Asprin 100mg/d Clopidogrel 75mg/d
Duration of antiplatelet therapy	12 months	12 months	12 months
Aneurysm exclusion at follow-up	Excluded	Excluded	Excluded
In-stent restenosis (ISR)	No	No	No

Table 2. Comparison of hydromechanical parameters in cases

Case	Flow Velocity(m/s)	Pressure(Pa)	Wall Shear Stress(Pa)
Case 1			
Stent-free	0.0066±0.015 (n=94042)	126.95±12.65 (n=32662)	0.51±1.35 (n=32662)
Single-Stent	0.0046±0.013* (n=98858)	127.33±18.03* (n=33843)	0.28±1.19* (n=33843)
Double-Stent	0.0050±0.011*† (n=81670)	121.19±26.92*† (n=20154)	0.22±1.13*† (n=20154)
Case 2			
Stent-free	0.013±0.02 (n=197491)	103.28±1.69 (n=41061)	0.23±0.50 (n=41061)
Single-Stent	0.007±0.013* (n=366784)	110.64±6.34* (n=68185)	0.23±0.88 (n=68185)
Double-Stent	0.005±0.011*† (n=368201)	117.70±10.07*† (n=68264)	0.17±0.82*† (n=68264)
Case 3			
Stent-free	0.012±0.018 (n=70664)	85.42±4.82 (n=109062)	0.17±0.58 (n=109062)
Single-Stent	0.0079±0.0109* (n=1313301)	92.51±5.78* (n=175490)	0.14±0.58* (n=175490)
Double-Stent	0.0072±0.0093*† (n=1313562)	97.33±7.92*† (n=175474)	0.10±0.48*† (n=175474)

*P: In each case, compared to No-stent group, P<0.01; †P: In each case, compared to Single-stent group, P<0.01.

Figures

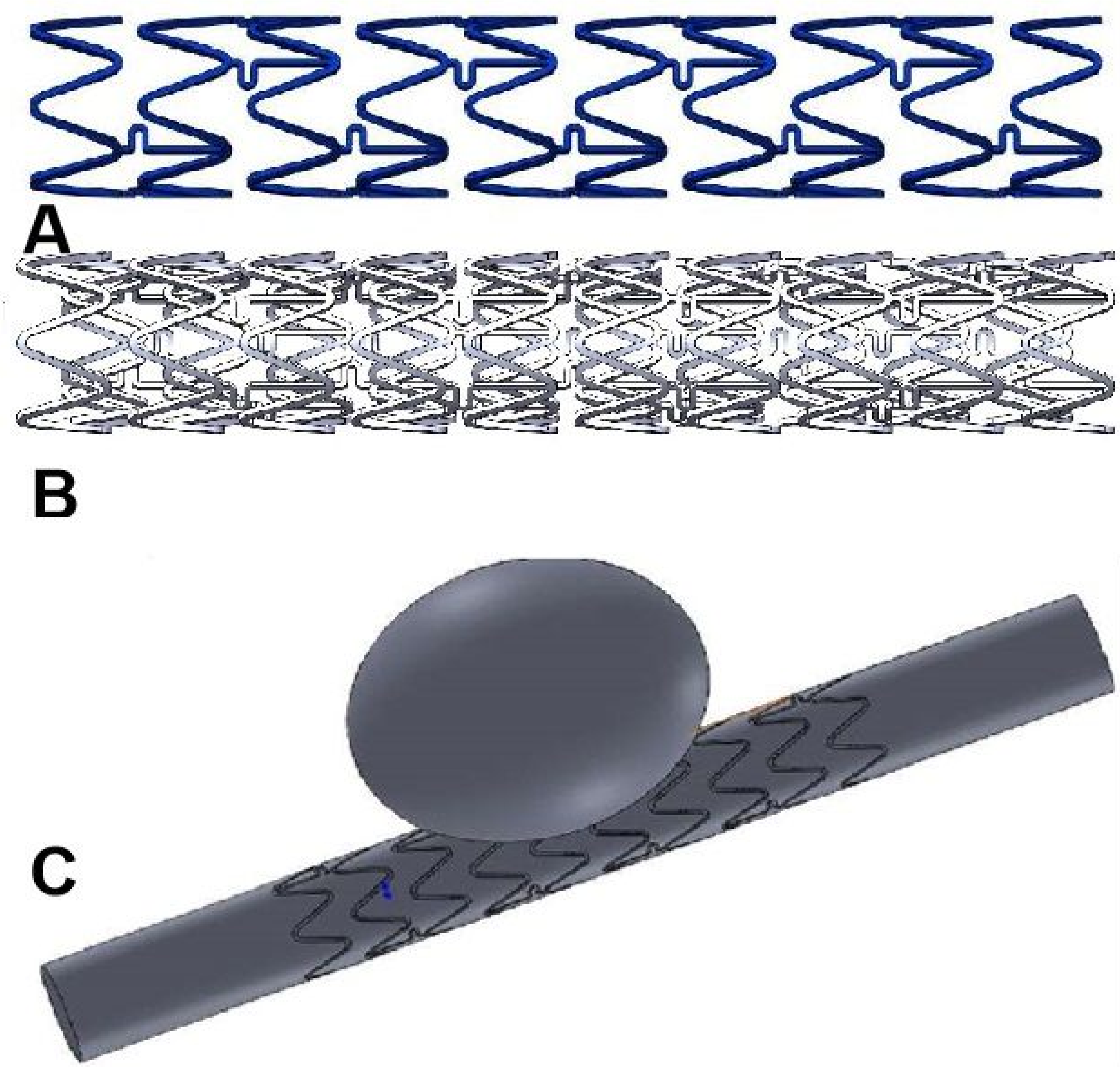

Figure 1

Stent model. single-layer stent model (A), double-layer stent model(B), scaffold model (C)

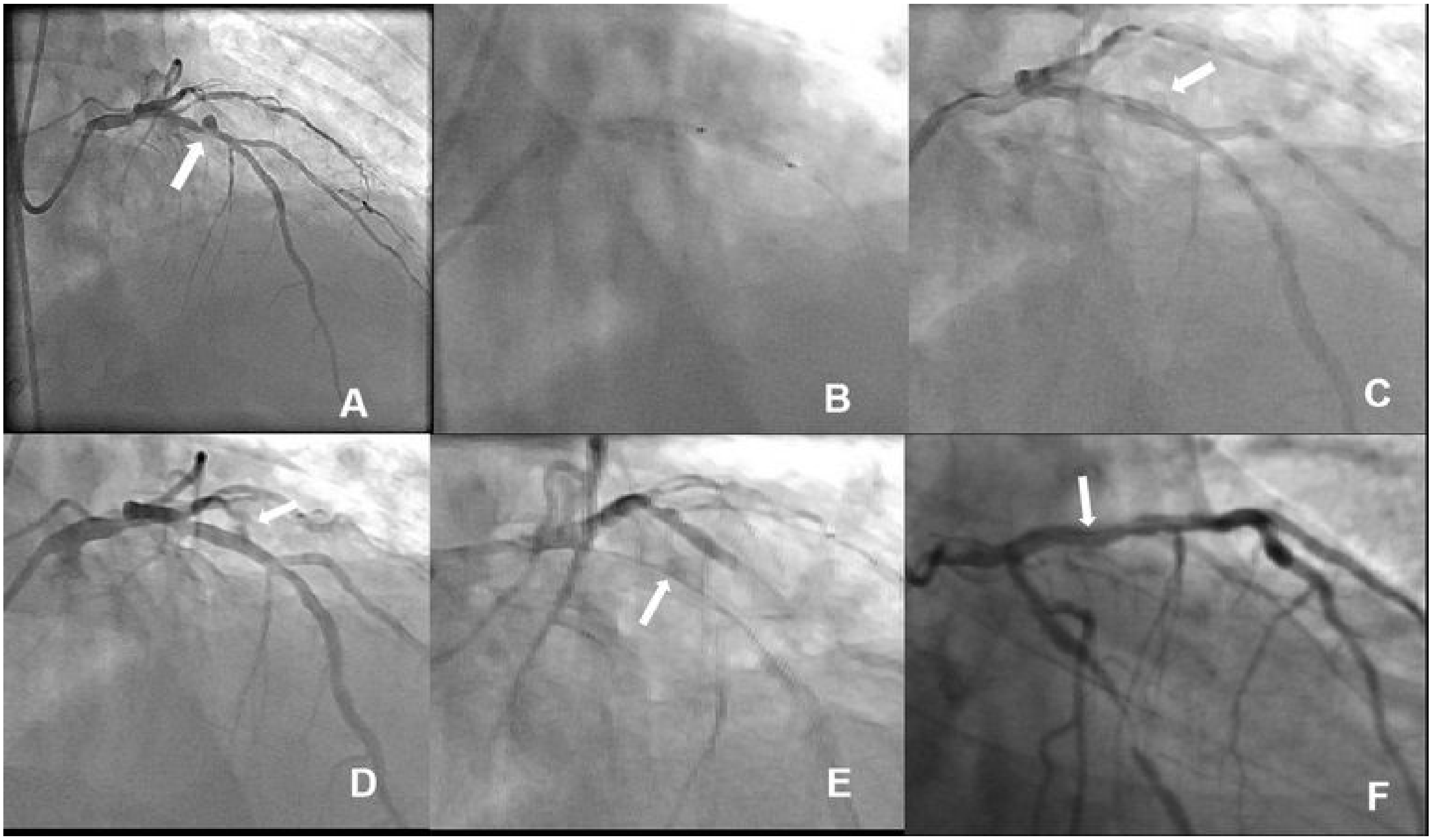

Figure 2

Intervention process and follow-up for Case 1. before stenting (A). A 3.0*12 mm H-stent was implanted (B). angiography after the stent released at the end of 0.5 second (C),1 second(D), 1.5 second(E). Follow-up at 1 year after stenting, white arrow shows the location of the original CAA(F).

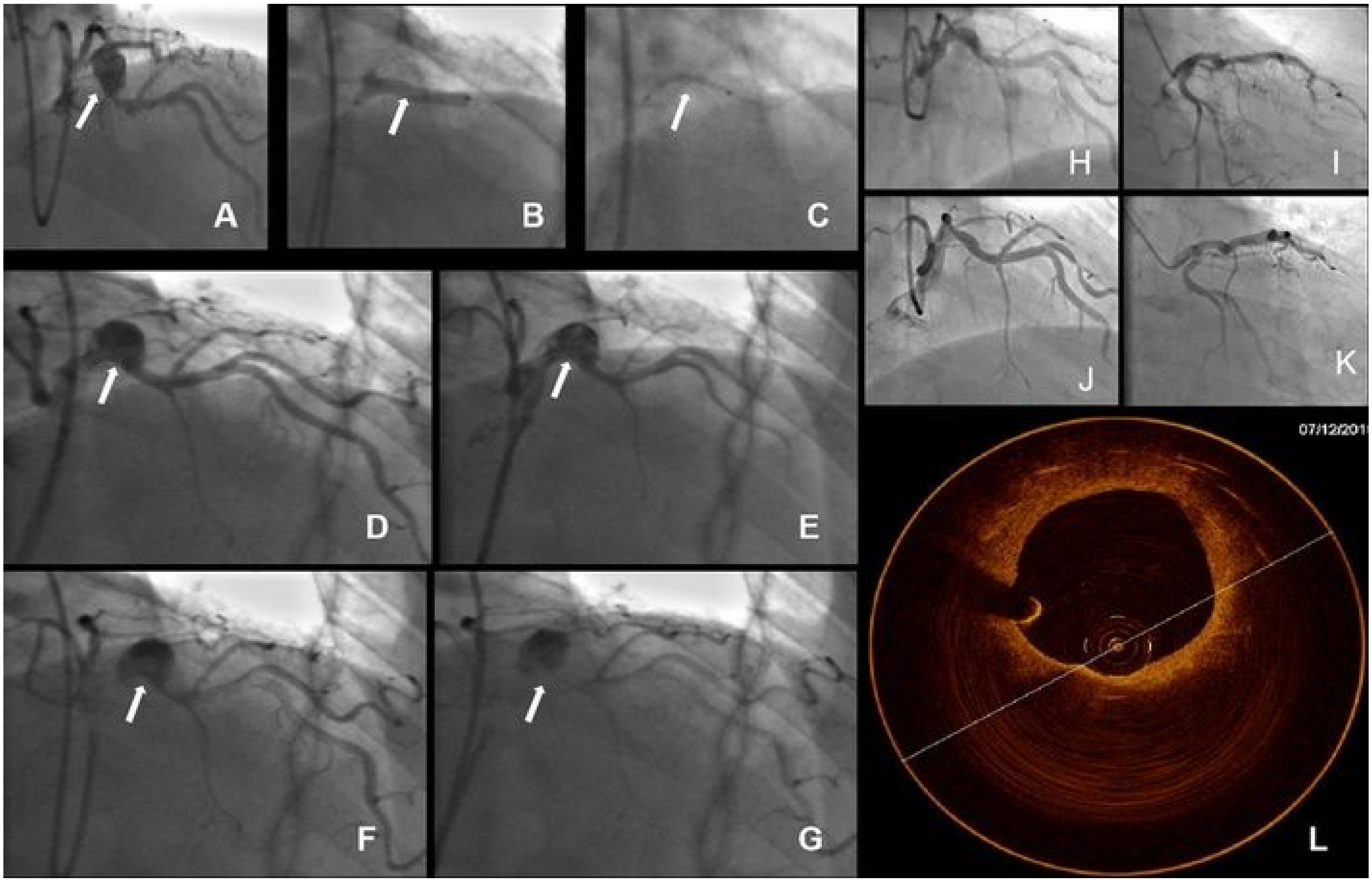

Figure 3

Intervention process and follow-up for Case 2. before stenting (A), A 3.5 mm*25 mm(B) and 3.5 mm*13 mm(C) stents were implanted in turn. angiography after the stent released at the end of 1second (D), 2second(E), 2.5second(F), and 3second(G). Follow-up at 6 month (H-I) and 5 years after stenting (J-K), optical coherence tomography at 5 years after stenting (L).

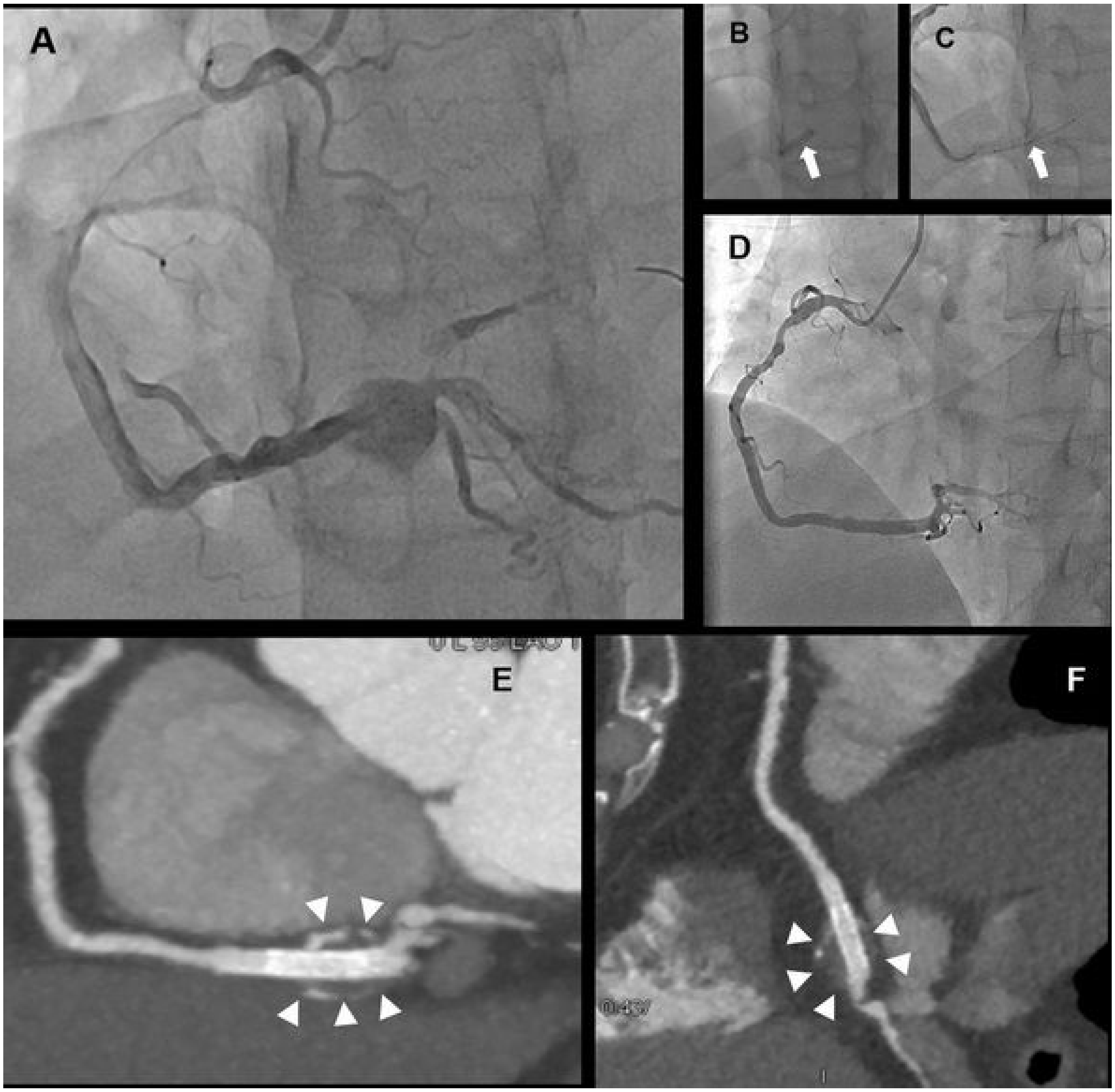

Figure 4

Intervention process and follow-up for Case 3. before stenting (A). Stents of 3.5 mm*16 mm(B) and *4.0 mm*24 mm (C) were implanted in turn. Angiography 1 year after stenting(D), and coronary computed tomography angiography,the white arrow shows that the aneurysm had a low density (E-F).

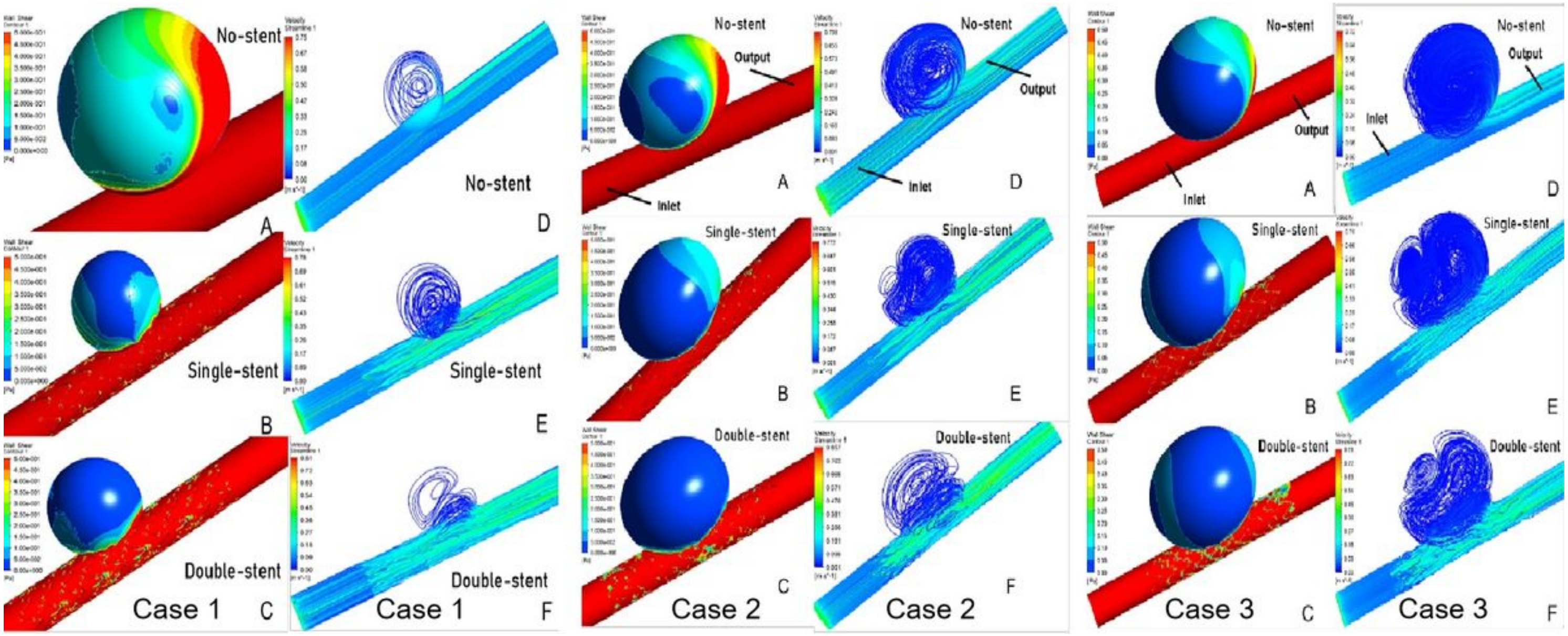

Figure 5

The streamline and WSS distribution in stent-free, single-stent and double-stent conditions in the 3 cases. The A, B and C in each case were streamline shows the movement of particles in the blood. The D, E and F were WSS distribution in CAA in 3 cases.

Supplementary Files

This is a list of supplementary files associated with this preprint. Click to download.

- DBMSincase3.avi
- SBMSincase3.avi
- Stentfreeincase3.avi