Diagnostic Value of Multimodal Transvaginal Contrast-Enhanced Ultrasound Combined with Negative Intrauterine Contrast-Enhanced Ultrasound in Female Infertility

Fu Fen
Union Hospital, Fujian Medical University, Fujian Institute of Ultrasonic Medicine
Qin Ye (xhxhyeye@163.com)
Union Hospital, Fujian Medical University, Fujian Institute of Ultrasonic Medicine
Rongxi Liang
Union Hospital, Fujian Medical University, Fujian Institute of Ultrasonic Medicine
Guangtian Lian
Jingjing Guo
Union Hospital, Fujian Medical University, Fujian Institute of Ultrasonic Medicine
Ensheng Xue
Union Hospital, Fujian Medical University, Fujian Institute of Ultrasonic Medicine

Research Article

Keywords: Infertility, fallopian tube, uterus, multimodal, contrast-enhanced ultrasound

Posted Date: March 18th, 2022

DOI: https://doi.org/10.21203/rs.3.rs-1441212/v1

Abstract

BACKGROUND: Given the important role of the fallopian tube and uterine cavity in human reproduction, a simple, accurate, and quick method for determining fallopian tube patency and diagnosing uterine cavity lesions is needed. This study aimed to investigate the diagnostic value of multimodal transvaginal contrast-enhanced ultrasound combined with negative intrauterine contrast-enhanced ultrasound for infertility in women.

METHODS: A total of 310 patients with infertility were treated in the outpatient clinic of the Union Hospital of Fujian Medical University, from November 2017 to October 2020. Multimodal contrast-enhanced ultrasound combined with negative contrast-enhanced uterine cavity examination was used to analyze transvaginal four-dimensional contrast-enhanced hysterosalpinx ultrasound (TVS 4D-HyCoSy, 4D), three-dimensional hysterosalpinx contrast ultrasound (TVS 3D HyCoCoCoSyGray 3D), two-dimensional hysterosalpinx contrast-enhanced ultrasonography (TVS, 2D), and transvaginal harmonic imaging (TVS, HI), and other modal techniques were used to compare tubal patency diagnostic efficiency between a high- and a low seniority group. Further, the diagnostic efficiency of negative hysterography was analyzed in uterine lesions.

RESULTS: Among the 310 infertile patients, four gave up examination due to pain. In the other 306 patients, salpingography was successful in 612 cases, revealing 538 patency cases and 74 obstruction cases. In both high- and low seniority groups, tubal patency diagnosis efficiency was significantly different ($P<0.01$), with the combination of different modes. Similarly, the differences between the following groups were also statistically significant ($P<0.05$): 4D+3D+2D+HI and 4D+3D+2D, 4D+3D+2D and 4D+3D, and 4D+3D and 4D. However, there was no significant difference in the diagnostic efficiency of fallopian tube patency examination under various multi-modes between the high- and low seniority groups ($P>0.05$). A total of 306 patients underwent successful negative intrauterine contrast examination. Its accuracy was 91.94% (57/62).

CONCLUSIONS: Multimodal transvaginal contrast-enhanced ultrasound combined with negative intrauterine contrast-enhanced ultrasound has high accuracy and consistency in fallopian tube patency and uterine lesions evaluation; thus, it is worth promoting.

Introduction

With the gradual liberalization of the national fertility policy, an increasing number of women are eager to Conceive. Due to factors such as late childbearing, abortion, and pelvic inflammatory disease, the incidence of female infertility, affected by complex factors, has increased.According to statistics, fallopian tube and uterine cavity **issues** are mainly **responsible**[1]. The fallopian tube and the uterus play an important role in human reproduction. Therefore, determining fallopian tube patency and diagnosing uterine cavity lesions simply, quickly, and accurately is crucial. We evaluated the efficacy of multimodal transvaginal contrast US combined with negative intrauterine contrast US for the diagnosis of uterine

fallopian tube lesions. This study aims to provide a comprehensive and simple “single-step” examination method for the overall assessment of the female reproductive tract environment.

Methods

1. Subjects

A total of 310 infertile patients, aged 21–46 (31±5) years old, were admitted to the outpatient department of our hospital from November 2017 to October 2020 (n=117 primary infertile patients; n=193 secondary infertile patients). This study was approved by the hospital ethics committee, and all subjects signed informed consent. Patients with abnormal hysteroscopy were offered hysteroscopy. The inclusion criteria were a normal sexual life, no contraception use for >1 year, and no endocrine abnormalities. The exclusion criteria included a history of ectopic pregnancy, vaginal bleeding, and acute transmitted diseases. Patients also needed to be free from reproductive tract acute/chronic inflammation and fever.

2. Instrument and methods

2.1 Instrument and contrast agent

A GE-VolusonE10 color Doppler ultrasound diagnostic instrument, with coded contrast imaging technology, equipped with a transluminal probe, model RIC59-D probe, 5.0–9.0 MHz frequency, and mechanical index 0.12–0.18, was used. Positive contrast agent SonoVue (Bracco, Italy) was used as the microbubble contrast agent, and 0.9% normal saline was used as the negative intrauterine contrast medium.

2.2 Preparation before operation

Patients were informed regarding the examination contents and potential complications before the procedure and gave their informed consent. The patients emptied their bladder 30 min before surgery, and 0.5 mg of atropine was injected intramuscularly to reduce tubal spasms. Patients were placed in the lithotomy position. Routine transvaginal ultrasound (TVS) was performed to check for abnormal echoes in the uterus and in the bilateral adnexal area. After routine disinfection, a disposable double-cavity water pipe was inserted into the uterine cavity, and 1.5–3 mL normal saline was injected to fill the balloon and fix the catheter. A 5 mL contrast agent microbubble suspension was prepared (5 mL physiological saline was injected into SonoVue for full oscillation). TVS was used to perform transverse scanning of the uterus and start the 3D mode. The volume sampling frame was set to maximum, and the probe was adjusted according to the bilateral uterine angle and ovarian position for 3D pre-scanning. Simultaneously, 20 mL of contrast agent suspension was extracted with a syringe (17.5 mL of preheated physiological saline was placed in an electric thermostatic water bath at 33 °C, mixed with 2.5 mL of the configured microbubble suspension, diluted and shaken), and 20 mL of physiological saline was extracted with another syringe.

2.3 Procedure and sequence of multimodal CEUS Contrast-Enhanced Ultrasound(see Figure 1.1)

(1) Four-dimensional mode: 4D collection was started, and 10 mL contrast agent suspension was injected to observe the contrast agent dispersion around both the ovaries and the pelvic cavity; (2) 3D mode: 3D mode was started, and 10 mL of contrast agent suspension was injected; (3) 2D mode: 2D contrast mode was started. Contrast agent was continuously injected (5–10-mL), and the contrast agent was observed from the uterine cavity through both fallopian tubes and the umbrella end around the ovary; (4) HI mode: all imaging modes were closed, the contrast agent (5–10 mL) was continuously injected again under dynamic tissue harmonic imaging, and both sides of the fallopian tubes were tracked; (5) uterine cavity negative contrast mode: the water sac was slightly shrunk, and the cervical opening plug was gently pulled down; the negative contrast agent was evenly injected through the catheter until the residual sononvue strong echo signal disappeared, and the uterine cavity was anechoic and filled to maintain a suitable degree of expansion. Two-dimensional ultrasound was used to scan the uterine cavity continuously, from the longitudinal and transverse sections, to observe its morphology, the degree of thickness of the endometrial surface, and the presence of lesions. The normal saline in the water sac was completely drained; 0.9% normal saline was rapidly injected while the tube was removed, and 3D imaging of the uterus was rapidly performed [2]. All the angiography data were stored in the instrument's hard disk for later analysis, and patients were advised to rest and stay 15–30 min for observation.

2.4 Image analysis and judgment index

Ultrasound doctors were divided into high- and low seniority groups, based on work experience. Senior doctors had more than five years of contrast-enhanced ultrasound experience. Junior group doctors were residents who **undergo** standardized training in ultrasound medicine. Both groups of doctors independently analyzed the entire research dataset to judge fallopian tube patency and observe uterine lesions.

2.5 Evaluation items and criteria of tubal patency and uterine lesions

According to the Standard of Clinical Application Guide of Contrast-enhanced Ultrasonography by the Chinese Medical Association[3], fallopian tube patency is divided into two types: patency and obstruction. (1) We deemed the fallopian tube "unobstructed” when there was low resistance to contrast medium injection and we observed smooth and natural fallopian tube walking, uniform thickness and full development, overflow of contrast medium at umbrella end, ring around the ovary, no reflux, and uniform dispersion of the pelvic cavity. (2) We deemed the fallopian tube "obstructed” when there was great resistance to the injection of contrast medium, no or partial development of the fallopian tube, no ring around the ovary, no diffusion of contrast medium in the pelvic cavity, obvious reflux, and countercurrent in the uterine wall.

3. Statistical methods

Statistical data analysis was conducted on SPSS v23.0 (IBM Corp., Armonk, NY). The results of contrast-enhanced ultrasound of the fallopian tube were expressed by counting data. The success rate of

contrast-enhanced ultrasound diagnosis of tubal patency in different mode groups was compared by the χ^2 test, and the diagnostic efficiency of tubal patency was compared by the Wilcoxon rank-sum test, between the high- and low seniority groups under multimode contrast-enhanced ultrasound.

Negative hysterography considers hysteroscopy results as the "gold standard." The accuracy of negative hysterography in the diagnosis of uterine lesions and the sensitivity, specificity, positive predictive value, negative predictive value, and accuracy of common uterine lesions were calculated.

Results

1. Evaluation of tubal patency by multimodal contrast-enhanced ultrasound

Among the 310 patients with infertility, 4 refused to undergo the examination due to pain. Salpingography was successful in the remaining 306 cases. In 612 fallopian tubes, there were 538 patency cases (figure 2.1, figure 2.2) and 74 obstructions (21 right cases, 23 left cases, and 15 bilateral cases) (figure 2.3). The 15 bilateral obstruction cases (figure 2.4) were confirmed by laparoscopic surgery. The unobstructed 4D mode of the fallopian tube showed that the fallopian tube was smooth, the contrast medium was ejected from the umbrella end, and the contrast medium was surrounded by a ring around the ovary and dispersed evenly in the pelvic cavity. The fallopian tube was smooth in 3D mode, the liquid echo could be seen in 2D and HI modes, and the injection pressure of the contrast medium was small. The 4D, 3D, 2D, and HI modes of the 74 blocked fallopian tubes did not show the fallopian tubes; only a small segment of the proximal end of the fallopian tubes was developed, and no contrast medium was seen around the obstructed fallopian tubes and pelvis. The injection pressure of the contrast medium was high, and a uterine wall countercurrent was observed in some patients.

2. Comparison of the diagnostic efficiency of multimodal CEUS between the high- and low seniority groups

The diagnostic efficiency of the combination of different modes in the high and low seniority groups was significantly different (high seniority group: χ^2=115.599, P=0.0001, <0.01; low seniority group: χ^2=104.614, P=0.0002, <0.01). A comparison of the diagnostic efficiency of single-mode and multimode joint examinations and verification of fallopian tube patency examination by ultrasound doctors in different seniority groups is shown in Table 1. There were significant differences between the 4D+3D+2D + HI group and the 4D+3D+2D, 4D+3D+2D, 4D+3D, 4D+3D, and 4D groups. The diagnostic efficiency of tubal patency was compared between the high- and low seniority groups, as shown in Table 2. The greater the number of combined modes, the higher the diagnostic efficiency of tubal patency.

There was no significant difference in the diagnostic efficiency of tubal patency between the high seniority group and the low seniority group under the combination of different modes (P=0.857, >0.05). That is, under the combination of multimodal contrast-enhanced ultrasound, the two groups of ultrasound doctors can effectively diagnose tubal patency.

Table1 Diagnostic efficiency of single-mode and multimodal examination/verification of tubal patency in different seniority groups (section)

Different mode groups	Diagnostic efficiency of doctors in high seniority group		Diagnostic efficiency of doctors in low seniority group	
	Displayable +	Not displayable -	Displayable +	Not displayable -
4D	530	82	530	82
4D+3D	558	54	558	54
4D+3D+2D	596	16	593	19
4D+3D+2D+HI	612	0	610	2

Table 2 Tubal patency diagnostic efficiency between high- and low seniority groups by ultrasound physicians in different mode groups

Different mode groups	Diagnostic efficiency of doctors in high seniority group			Diagnostic efficiency of doctors in low seniority group		
	4D+3D	4D+3D+2D	4D+3D+ 2D+HI	4D+3D	4D+3D+2D	4D+3D+ 2D+HI
4D	χ^2=6.485 P=0.014			χ^2=6.485 P=0.014		
4D+3D		χ^2=21.880 P=0.0003			χ^2=17.845 P=0.0003	
4D+3D+2D			χ^2=16.212 P=0.0003			χ^2=14.002 P=0.0002

Table 3 Results comparison between negative hysterography and hysteroscopy in 62 patients (example)

Negative hysterography	Hysteroscopy		Total
	+	_	
Uterine malformation			
+	5	0	5
_	0	57	57
Total	5	57	62
Cesarean section scar diverticulum			
+	2	0	2
_	1	59	60
Total	3	59	62
Intimal polyp			
+	25	2	27
_	2	33	35
Total	27	35	62
Submucosal myoma			
+	1	1	2
_	2	58	60
Total	3	59	62
Uterine adhesion			
+	24	1	25
_	3	34	37
Total	27	35	62

The results for the different types of uterine lesions were statistically analyzed. Compared with the results of hysteroscopy, the overall accuracy of negative hysterography in various types of uterine lesions diagnosis was 91.94% (57pm 62), including uterine deformities 100% (5pm 5), cesarean section scar diverticulum 98.39% (61mp 62), endometrial polyps 93.55% (58max 62), uterine submucous myoma 95.16% (59max 62), and uterine adhesion 93.55% (580.62). The statistical analysis of various uterine lesions examined using negative hysterography is shown in Table 4.

Table 4 Statistical analysis of various uterine lesions examined by negative hysterography

Classification of uterine lesions	Sensitivity	Specificity	Positive predictive value	Negative predictive value	accuracy
Uterine malformation	100%	100%	100%	100%	100%
Cesarean section scar diverticulum	66.67%	100%	100%	98.33%	98.39%
Intimal polyp	92.59%	94.29%	92.59%	94.29%	93.55%
Submucosal myoma	33.33%	98.31%	50%	96.67%	95.16%
Uterine adhesion	88.89%	97.14%	96%	91.89%	93.55%

3. Results of negative hysterography in the diagnosis of uterine lesions

Of the 310 patients with infertility, four refused to undergo the examination because of pain, and the remaining 306 patients successfully underwent negative uterine radiography. A total of 91 cases presented an abnormal uterine cavity, and the detection rate of uterine lesions was 29.7%. Of these, 62 were examined by hysteroscopy. The results showed that there were five cases of uterine malformation (one unicorn uterus and four mediastinal uteri) (figure 2.5), two cases of scar diverticulum, 27 cases of endometrial polyp (figure 2.6), two cases of submucosal myoma, and 25 cases of uterine adhesion after cesarean section (figure 2.7). Comparing the results of negative hysterography with those of hysteroscopy, the final diagnosis was consistent in 57 cases, with an accuracy of 91.94% (57 cm, 62); that is, negative hysterography was more accurate for uterine lesions. A comparison of the results of negative hysterography and hysteroscopy is presented in Table 3.

Discussion

In this study, multimodal transvaginal ultrasound combined with negative hysterography was used to detect tubal patency and uterine lesions, providing a simple, rapid, and accurate examination method for grassroots hospitals. Each mode of step-by-step CEUS attention is described as follows.

1. 4D mode

The 4D mode can clearly display the three-dimensional images of the fallopian tube and uterine cavity [4][5], show the patency of each segment of the fallopian tube in real time, and directly display its shape, course, and contrast medium development to evaluate patency. It can also display the speed difference of bilateral fallopian tube development, show the diffusion of contrast medium around the ovary and the pelvis, and analyze a clear and intuitive image frame by frame. [6][7] The pictures are easily read by clinicians. Thus, unsurprisingly, in 4D mode we found that physicians in both high- and low seniority groups had the same diagnostic efficiency for tubal patency. However, if only 4D mode examination was

used, the diagnostic success rate of the high- and low seniority groups was 86.7% (530pm 612). Notably, in 4D mode, attention should be paid to the injection dose of contrast medium suspension is also controlled at 5-10 mL. In some cases, the contrast medium cannot reach the umbrella end or be ejected, and most of the contrast medium diffuses too much into the pelvis affecting the follow-up modal examination. Approximately 13.3% (82-612) of the fallopian tubes in this group could not be diagnosed for the above reasons and can be combined with other modes to improve the diagnosis' success rate.

2. 3D mode

The 3D mode can directly display the shape and course of the fallopian tube through three-dimensional reconstruction, which aids diagnosis [4-8]. With skillful examination, 3D can completely capture the whole process of the contrast medium flowing in the fallopian tube to the umbrella end, and its three-dimensional imaging is clear and intuitive. In 3D mode, the physicians' diagnostic efficiency for tubal patency in high- and low seniority groups is the same [9]. Because length and course of the fallopian tube are different, the 3D mode scanning angle and phase can affect the fallopian tube display success rate, which requires higher examiner manipulation and proficiency. If the scanning time is too short, the contrast medium does not fill the fallopian tube, the image acquisition process is incomplete, and the whole picture of the fallopian tube cannot be displayed, which makes it difficult to analyze and results can be easily misjudged. However, it is difficult to determine whether there is contrast medium around the ovary. Moreover, when the intubation depth is too deep, the contrast medium flows along one side of the fallopian tube, affecting the development of the other side. Therefore, it is necessary to put the balloon back into the mini-channel and combine the other modes to verify the results. This study showed that 558 fallopian tubes could be successfully diagnosed in both the high- and low seniority groups in the 4D+3D group, and the diagnostic success rate was 91.2% (558x612), which was significantly higher than in the single 4D mode group ($P<0.05$). However, 54 fallopian tubes could not be displayed because of unfavorable scanning angle, intubation depth, previous contrast medium injection, and diffusion to the pelvis. Therefore, combining other modes to improve the diagnosis' success rate is necessary.

3. 2D mode

The modal operation method is flexible and can track the entire course of the fallopian tube dynamically, observe the ejection of the contrast medium at the umbrella end of the fallopian tube, and simultaneously observe the wrapping of the contrast medium around the ovary and the diffusion of the pelvic cavity. However, it requires higher manipulation and experience. Therefore, this study further enhances the 2D modal examination and verification (4D+3D+2D group) by combining 4D and 3D mode, which can improve the success rate of fallopian tube patency diagnosis. It can further verify the accuracy and credibility of the 4D and 3D mode diagnoses. This study showed that the success rate of tubal patency diagnosis in the 4D+3D+2D group was significantly higher than in the 4D+3D group in both the high- and low seniority groups ($P<0.01$). The diagnosis accuracy was further confirmed. However, because of the different fallopian tubes' lengths and courses, it is difficult to display the entire fallopian tubes' course on

a single scan plane. Sixteen fallopian tubes in the high seniority group were not clear enough to make accurate diagnoses. In the low seniority group, 19 fallopian tubes could not be accurately diagnosed.

4. HI mode

The flow of the contrast medium in the fallopian tube can be observed clearly and dynamically in this mode, and the entire process of the fallopian tube can be displayed through flexible manipulation. Even if a part of the fallopian tube is intermittently displayed because of the surrounding intestinal gas, the judgment of its patency is not affected. Indeed, this study showed that the success rate of fallopian tube patency in the high- and low seniority groups was significantly higher than in the 4D+3D+2D+HI group ($P<0.01$). All 612 fallopian tubes in the high seniority group and 610 fallopian tubes in the low seniority group were diagnosed successfully. The diagnosis was less affected by the shortcomings of single-modal examination, which improved accuracy and reliability.

5. Negative hysterography

Negative hysterography directly showed uterine malformations, and the sensitivity and specificity for the diagnosis of uterine malformations in this study were 100%. and three-dimensional reconstruction showed a semi-circular irregular localized eminence. In this study, a case of scar diverticulum after cesarean section was missed because the diverticulum was small and fissure-shaped, water sac occlusion affected the imaging, and the case was complicated by large intimal polyps, who only focused on intimal polyps and ignored small diverticula during examination, resulting in missed diagnosis.

When the uterine cavity was filled with negative contrast media, the contrast between the endometrium and the lesions was enhanced, and endometrial polyps and submucosal myomas were clearly displayed. This showed irregular, round, or nodular localized protuberances or depressions of the uterine cavity [11]. In this study, two cases of endometrial polyps were missed because the polyps were small and located in the lower segment of the uterus, and water sac occlusion affected the imaging. Two cases were misdiagnosed, one as submucosal myoma because of a large polyp and the other as uterine adhesion. Two cases of submucosal leiomyomas were misdiagnosed. All missed cases were endometrial polyps with submucosal myoma, but only endometrial polyps were misdiagnosed as submucosal myomas. In negative hysterography, because the sonogram of endometrial polyps is similar to that of submucosal myoma, they are easily misdiagnosed, especially when the two lesions coexist. To improve the display rate of endometrial polyps, the examination should occur 3-5 days after menstruation. The endometrium in the early stages of hyperplasia is hypoechoic and thin, therefore, polyps can be easily detected. The endometrium's echo in the secretory phase is slightly enhanced and thicker, thus easily confused with intimal hyperplasia. Notably, when a submucosal myoma undergoes ischemic degeneration, the local echo can be highly echoic and easily confused with intimal polyps, resulting in misdiagnosis [11-12]. Through a comparative examination of hysteroscopy, it was found that the lesions missed by negative hysterography were often small, with uneven thickness of the intima, and occlusion of the water sac in the uterine cavity. Therefore, to avoid missing small lesions, at the end of the

examination, while removing the tube and simultaneously injecting normal saline, we should focus on observing the middle and lower segments of the uterus (the position occupied by the balloon). In this study, three cases of uterine adhesion were missed, 2 cases were misdiagnosed because the endometrium was too thin, "**with** only a slight adhesion, the adhesion band was fine and filamentous, 3D-TVS coronal image adhesion was not obvious and missed diagnosis. One case was adhesion with multiple endometrial polyps. Only endometrial polyps were diagnosed without uterine adhesion.

Negative hysterography can not only improve uterine lesions detection rate but also re-evaluate tubal patency through fluid flow in the uterine cavity and the fallopian tube [13-14]. The continuous flow of fluid in the fallopian tube is strong evidence of patency, and the patency of the fallopian tube can be reflected by observing the flow of fluid in the uterine cavity from the corners of the uterus on both sides of the fallopian tube. If the injection speed is the same and the fallopian tube wall is smooth, the lumen thickness is uniform and the direction of the fallopian tube is smooth, the liquid passes smoothly and flows quickly through the cavity. If the fallopian tube wall is not smooth (e.g., due to inflammation) and is slender or unevenly thick, stiff, or twisted, the liquid's flow slows down. If the fallopian tube's proximal end is blocked, and the fluid accumulates at the corresponding corners of the uterus without flowing into the fallopian tube, eddy currents may occur.

Limitations of this study

This study's sample size was small, and a certain bias error was introduced. Because of radiation exposure risks, only a few patients underwent X-ray Lipiodol radiography, and few patients underwent tubal patency. Therefore, comparative studies on other tubal patency examination methods. Contrast-enhanced ultrasound operations are only performed by senior doctors, thus high- vs low seniority diagnosis comparisons are impossible.

Conclusion

In this study, through step-by-step multimodal transvaginal CEUS combined with negative hysterography, we found that the greater the number of joint modes, the higher the diagnostic efficiency. When a 4D diagnosis is confirmed, modal verification can be added to improve diagnostic efficiency. When uncertain, multiple modes can be combined for diagnosis and verification.

Negative hysterography can not only significantly improve the detection rate of uterine lesions but also re-evaluate the patency of fallopian tubes through the flow of fluid in the uterine cavity and fallopian tubes and the overflow of fluid in the pelvic cavity.

In this study, using the same evaluation criteria, senior and junior doctors analyzed the data and images of the same cases, with consistent results with those of experienced doctors. This shows that multimodal transvaginal ultrasound has high consistency in the evaluation of tubal patency and, combined with negative hysterography, high accuracy in the diagnosis of uterine lesions. The combination of

multimodal transvaginal contrast-enhanced ultrasonography and negative hysterography, is practical, accurate, and easy to popularize and apply for female infertility diagnoses.

Abbreviations

HSG:hysterosalpingography;HyCoSy:hysterosalping constrast sonography;

2D-HyCoSy:two-dimensional Hysterosalpingo-contrast sonography

3D-HyCoSy:three-dimensional Hysterosalpingo-contrast sonography

4D-HyCoSy:four-dimensional Hysterosalpingo-contrast sonography

TVS-HI:Transvaginal harmonic imaging

Declarations

Ethics approval and consent to participate

This study was approved by the hospital ethics committee, and all subjects signed informed consent.

Consent for publication

Informed consent was acquired from the patient.

Availability of data and materials

All the generated data are included in this article.

Competing interests

The authors declare that they have no competing interests.

Funding

This work was supported by the Fujian provincial special finance.

Authors' contributions

Fu Fen wrote the main manuscript text.All authors reviewed the manuscript.Ye Qin put forward many suggestions to the article. Liang Rongxi and Lian Guangtian participated in the conception of the article. Guo Jingjing and Xue Ensheng sorted out the data of the article.All the authors contributed towards the preparation of fnal version of the manuscript.The authors read and approved the fnal manuscript.

Acknowledgements

We thank pathology department of our hospital for pathologic review.

References

[1] Ye Qin, Xue Ensheng, Liang Rongxi, Guo Jingjing, Lin Xueying, Wang Yan. Diagnosis and missed diagnosis of uterine adhesion by transvaginal three-dimensional ultrasound volume imaging and tomographic ultrasound imaging [J]. Chinese Journal of Ultrasound Imaging, 2020 (03): 255,256,257,258,259.

[2] Wang Sasha.Contrast-enhanced ultrasonography of uterus and fallopian tube [M].Beijing: military Medical Science Press, 2014: 11-53.

[3] Ultrasound physician Branch of Chinese Physicians Association. Guidelines for clinical application of contrast-enhanced ultrasound in China [M].Beijing: people's Health Publishing House, 2017: 174175.

[4] Wei Liu.Clinical value of four-dimensional contrast-enhanced ultrasonography of uterus and fallopian tube in the diagnosis of infertility [J].Journal of practical Gynecological Endocrinology (Electronic Edition), 2017, 4 (1): 55-56.

[5] Shen Hongmei, Li Bailing, Li Lu.Comparison of real-time three-dimensional and three-dimensional contrast-enhanced ultrasound of uterus and fallopian tube in the diagnosis of female infertility [J].Chinese Journal of Ultrasonic Medicine, 2019, 35 (11): 1023-1026.

[6] Wang W, Zhou Q, Gong Y, Li Y, Huang Y, Chen Z. Assessment of Fallopian Tube Fimbria Patency With 4-Dimensional Hysterosalpingo-Contrast Sonography in Infertile Women. J Ultrasound Med. 2017 Oct;36(10): 2061-2069.

[7] Shi Fuwen, Yang Min, Gu Xiaoning, et al.Transvaginal four-dimensional ultrasound hysterosalpingography to evaluate tubal patency in patients with infertility[J].Chinese Medical Imaging Technology, 2019, 35 (5): 730,734.

[8] Wang Lulu, Li Hong, Gu Yidong, et al. Application of transvaginal dynamic three-dimensional ultrasound salpingography in the diagnosis of infertility [J].Chinese Journal of Medical Ultrasound (Electronic Edition), 2017, 14 (4): 302,306.

[9] Liu Ting, Nie Fang, Wu Chuang, et al.Evaluation of tubal patency by real-time three-dimensional hysterosalpingography [J]. Chinese Medical Imaging Technology, 2018, 34 (7): 1059-1062.

[10] Dai Qing.Further discussion on the application of ultrasound in the evaluation of cesarean section scar and scar diverticulum [J].Chinese Journal of Medical Ultrasound (Electronic Edition), 2014, 11 (10): 788,7881.

[11] Cai Qi, Sui long, Ren Yunyun.Ultrasonic diagnosis value and misdiagnosis analysis of endometrial polyps [J].Tumor Imaging, 2015, 24 (04): 287291.

[12] Vroom AJ, Timmermans A, Bongers MY, van den Heuvel ER, Geomini PMAJ, van Hanegem N. Diagnostic accuracy of saline contrast sonohysterography in detecting endometrial polyps in women with postmenopausal bleeding: systematic review and meta-analysis. Ultrasound Obstet Gynecol. 2019 Jul;54(1): 28-34. doi: 10. 1002/uog. 20229. Epub 2019 Jun 12. PMID: 30693579.

[13] Lee Li-Ling, Guo Wei, Fan Zhihua, Tang Li, Li Jianwei.The value of hysterosalpingography combined with hysterosalpingography in the diagnosis of uterine lesions [J].Fujian Medical Journal, 2018, 40 (04): 16-20.

[14] Gui Y, Wang L, Gao T, Hong H, Zhao W. Ultrasonic Imaging Combined with Hysteroscopy in Diagnosis of Endometrial Polyps Based on Multi Operator Algorithm and Analysis of Nerve Growth Factor Receptor Transmembrane Protein Expression. World Neurosurg. 2020 Oct 28: S1878-8750(20)32339-1. doi: 10. 1016/j. wneu. 2020. 10. 137. Epub ahead of print. PMID: 33130143.

Figures

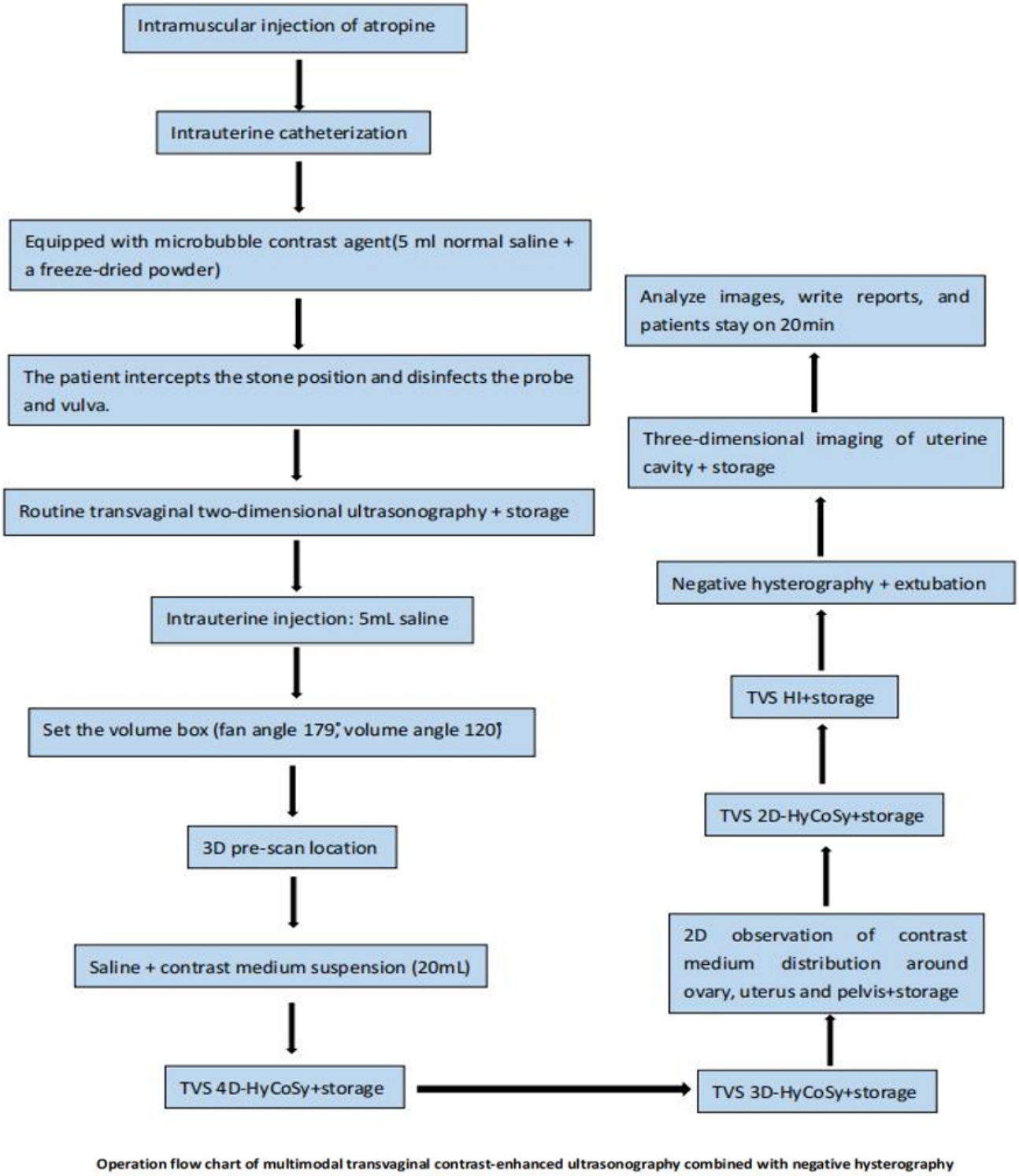

Figure 1

Operation flow chart of multimodal transvaginal ultrasonography combined with negative hysterography

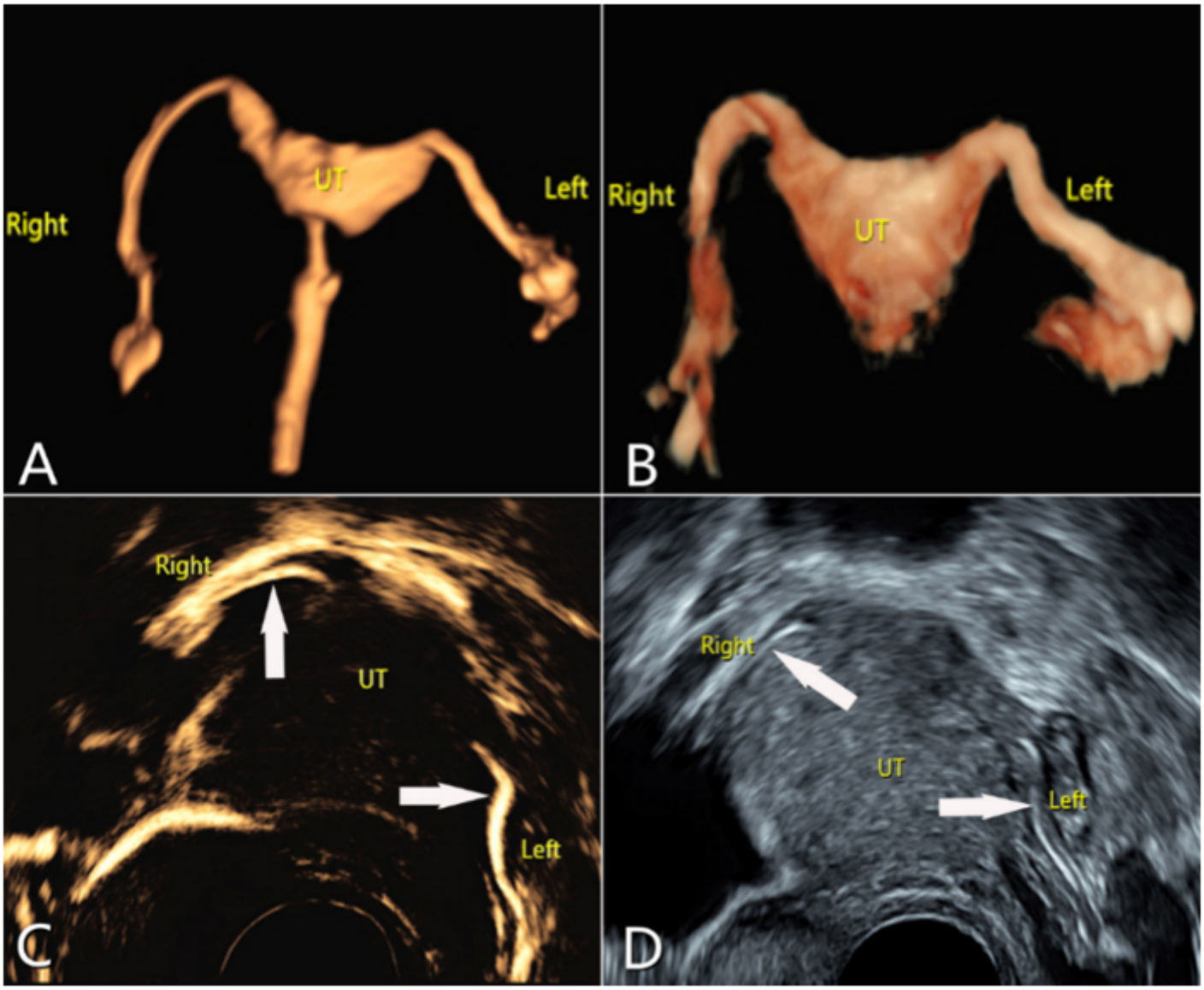

Figure 2

Multimodal contrast-enhanced ultrasound of tubal patency: TVS 4D-HyCoSy mode (figure A), TVS 3D-HyCoSy mode (figure B), stereoscopic and intuitive display of bilateral fallopian tube patency; TVS 2D-HyCoSy mode (figure C) and TVS HI mode (figure D) can show bilateral tubal patency (shown by arrow) (UT: uterus)

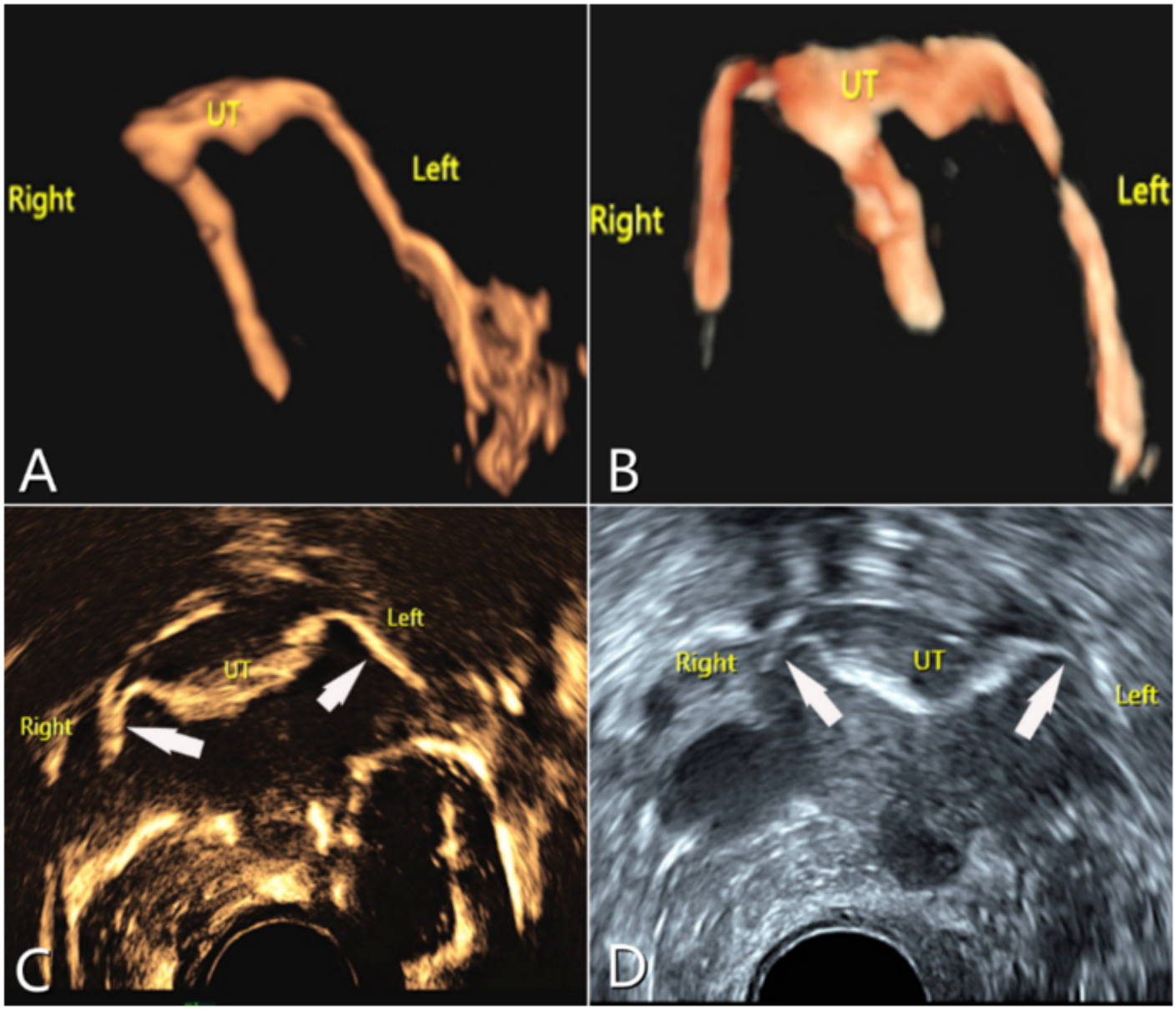

Figure 3

Multimodal contrast-enhanced ultrasound of tubal patency: TVS 4D-HyCoSy mode (figure A) shows only left fallopian tube patency, right fallopian tube is not developed; TVS 3D-HyCoSy mode (figure B) shows bilateral fallopian tube patency; TVS 2D-HyCoSy mode (figure C) and TVS HI mode (figure D) both show bilateral fallopian tube patency (shown by arrow) (UT: uterus)

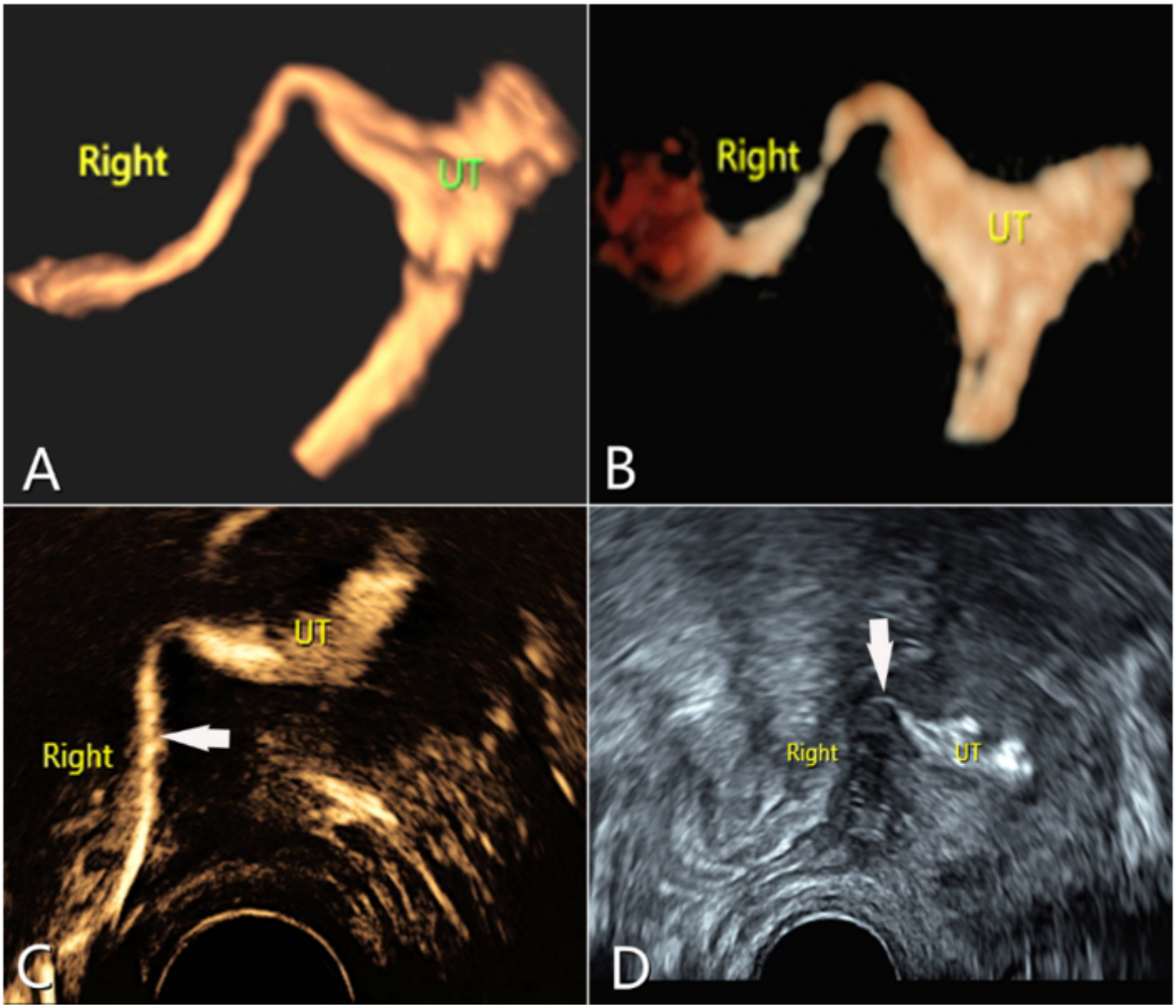

Figure 4

Multimodal contrast-enhanced ultrasound of tubal patency: TVS 4D-HyCoSy mode (figure A), TVS 3D-HyCoSy mode (figure B), TVS 2D-HyCoSy mode (figure C), TVS HI mode (figure D) all show that the right fallopian tube is unobstructed, while the left fallopian tube is blocked (shown by the arrow) (UT: uterus)

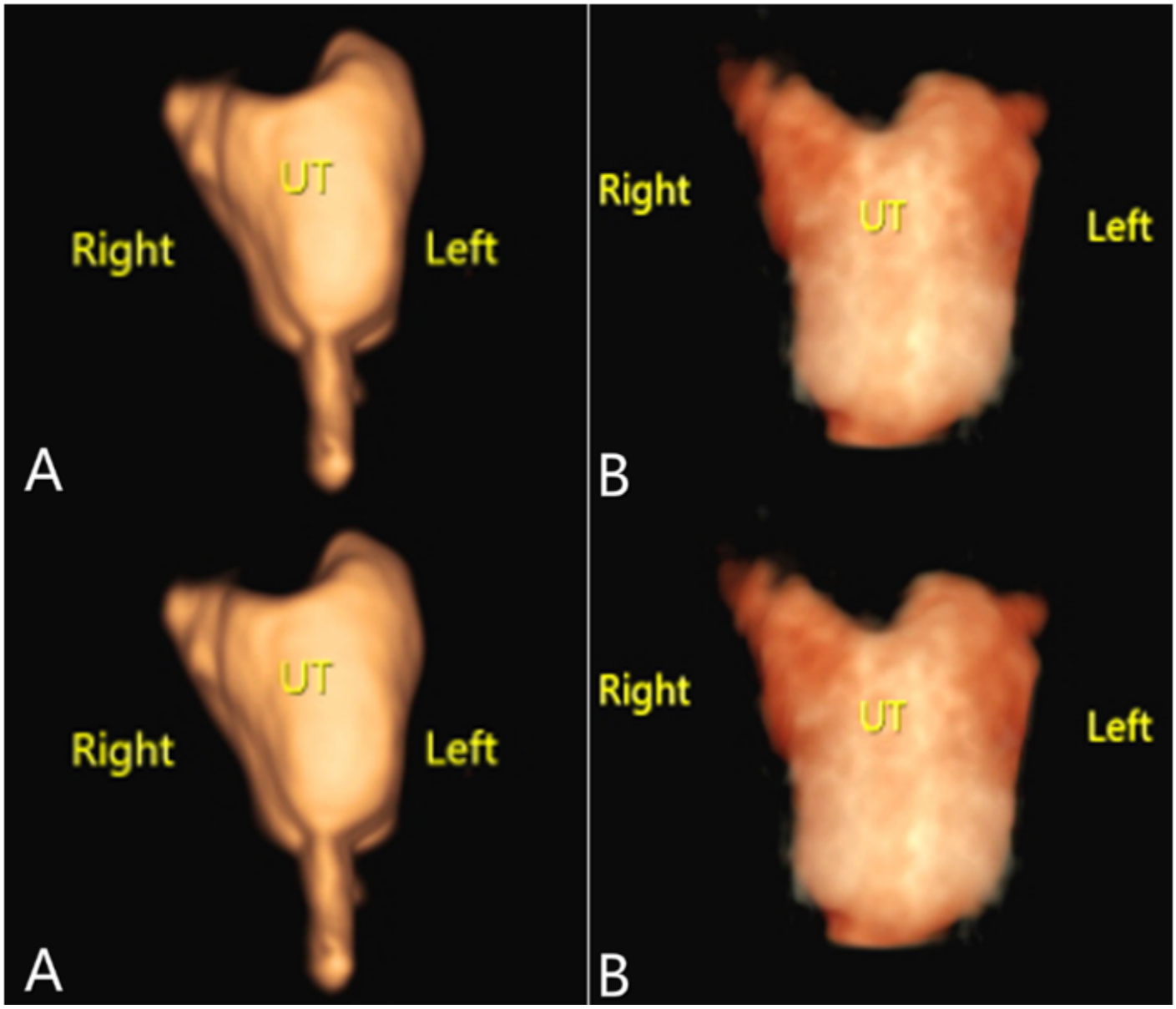

Figure 5

TVS 4D-HyCoSy mode (figure A); TVS 3D-HyCoSy mode (figure B), both modes show bilateral fallopian tube obstruction (UT: uterus)

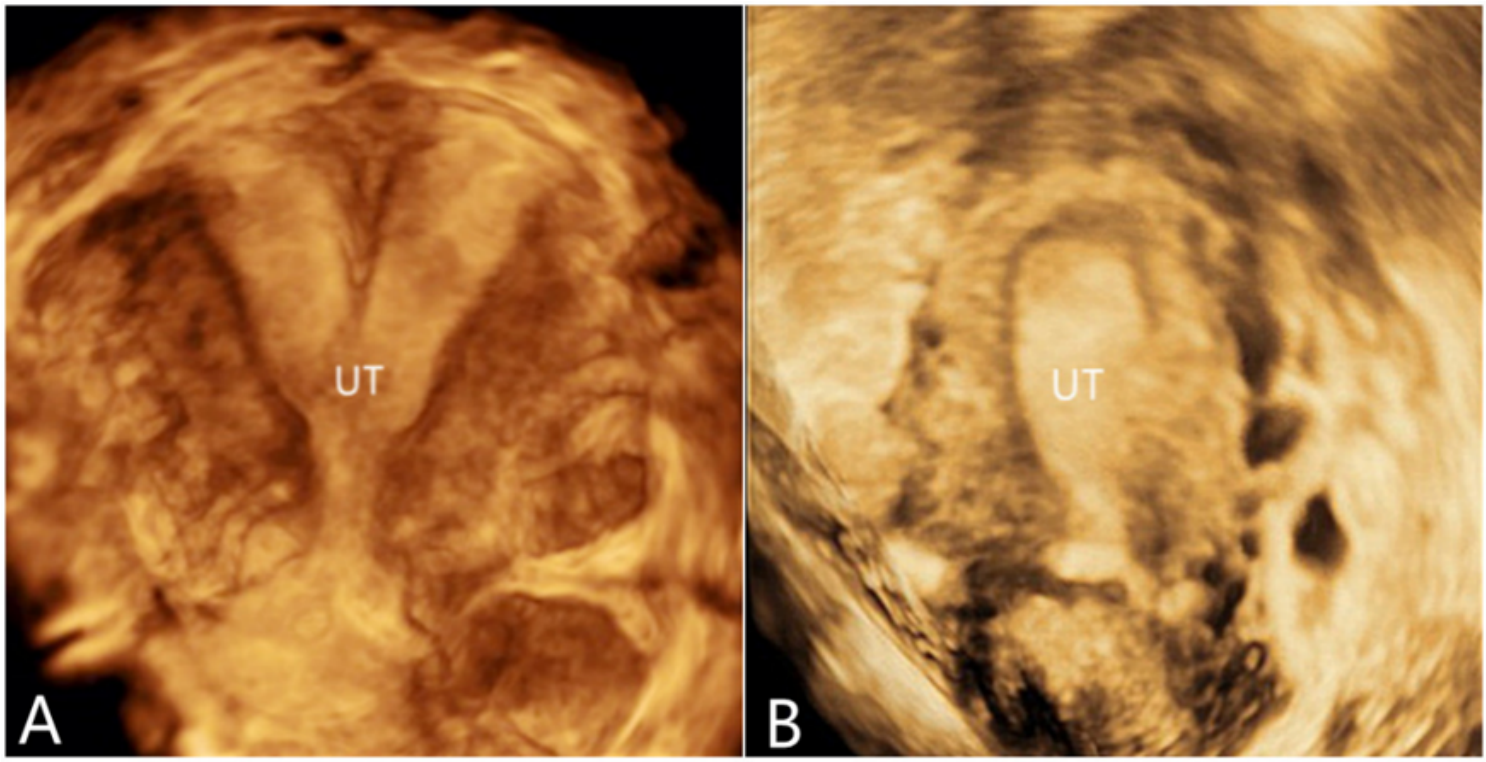

Figure 6

3D-TVS Render coronal imaging after negative hysterography shows mediastinal uterus (figure A) and unicorn uterus (figure B)

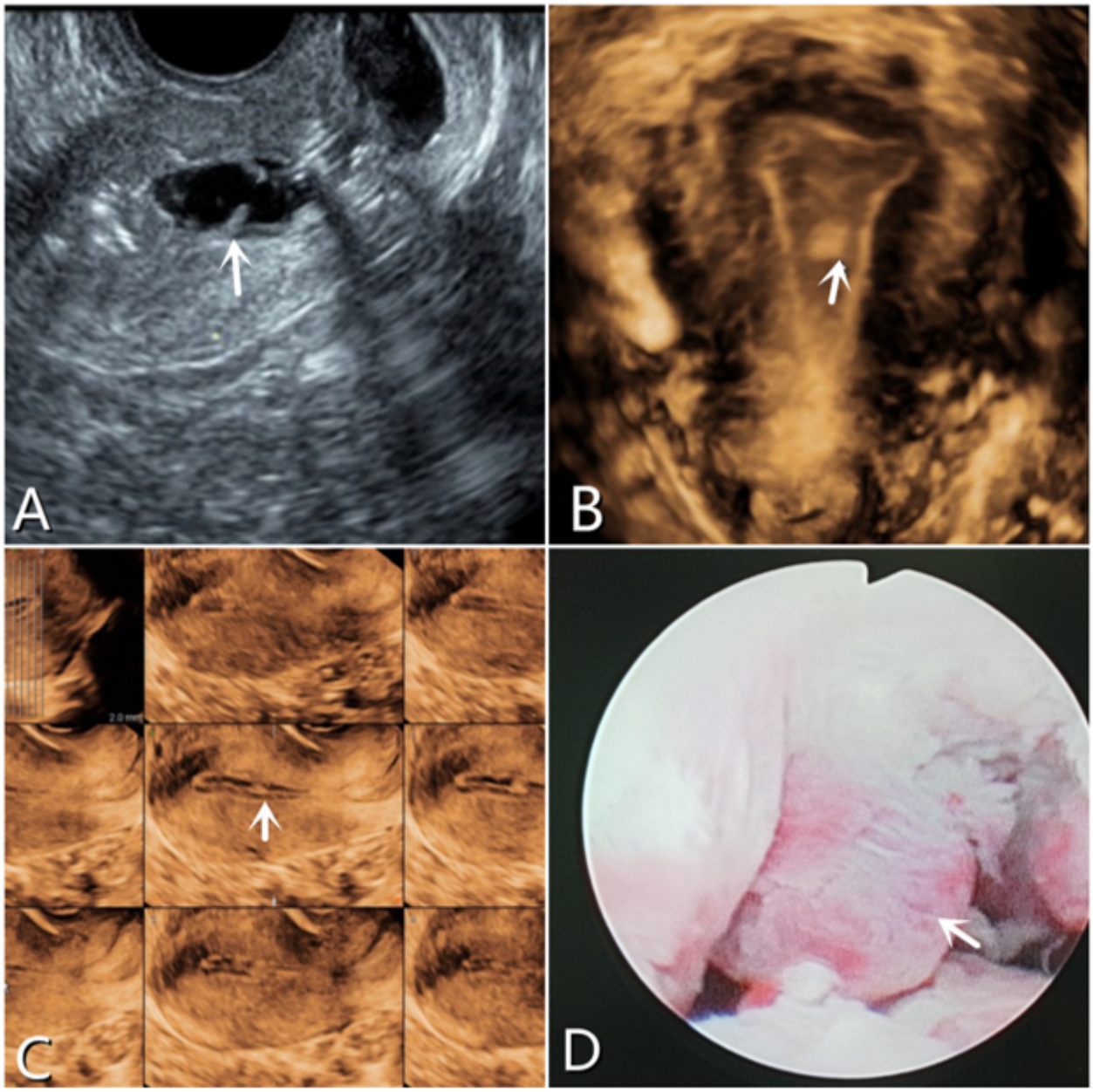

Figure 7

negative hysterography showing endometrial polyps (figure A) 3D-TVS Render coronal imaging of the uterus showing endometrial polyps (figure B) uterine tomographic ultrasonography showing endometrial polyps (figure C) hysteroscopic examination of endometrial polyps (figure D)

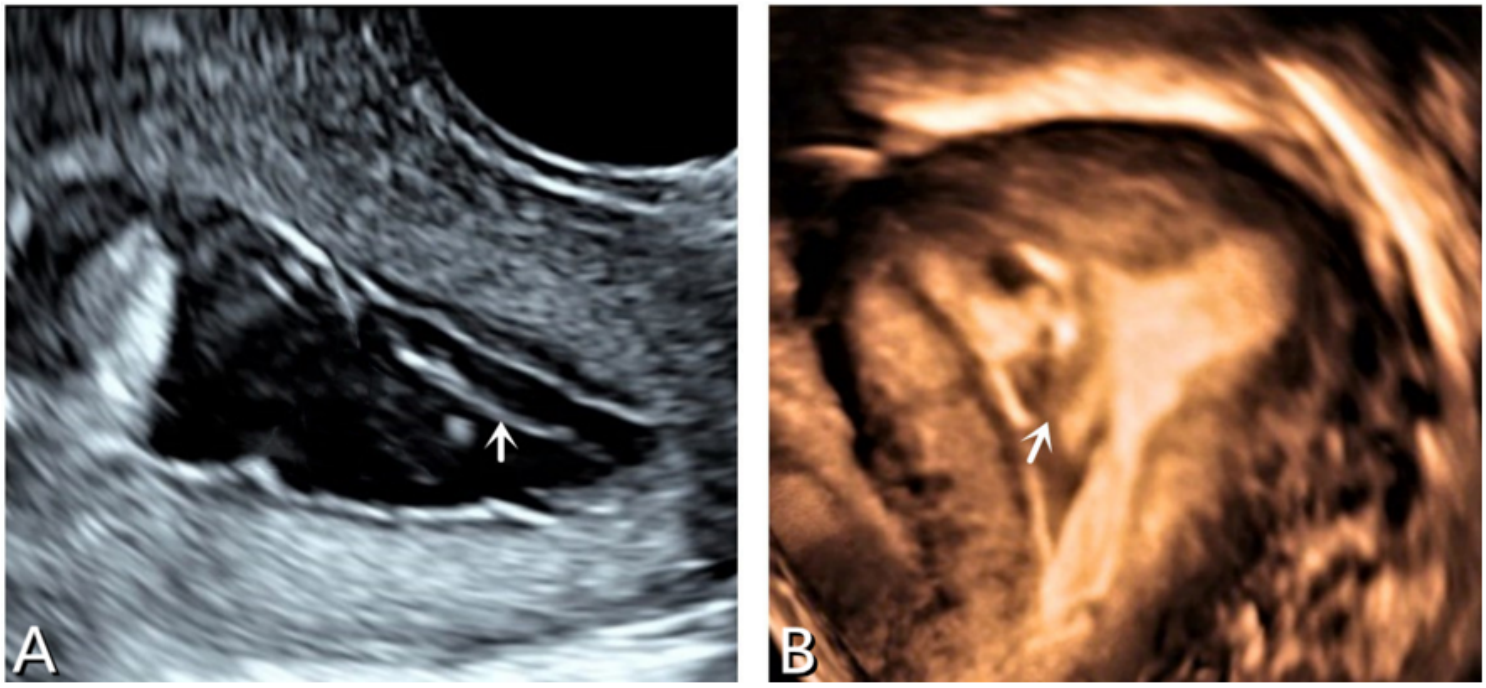

Figure 8

negative hysterography showing uterine adhesion (figure A) coronal 3D-TVS Render imaging of the uterus shows uterine adhesion (figure B)