Recalcitrant Periprosthetic Joint Infection With Iliac Fossa Abscess After Total Hip Arthroplasty

Kuo-Ti Peng (mr3497@cgmh.org.tw)
Department of Orthopedic Surgery, Chang Gung Memorial Hospital, Puzi City, Chiayi County

Tsung-Yu Huang
Division of Infectious Diseases, Department of Internal Medicine, Chang Gung Memorial Hospital, Chiayi

Jiun-Liang Chen
Department of Orthopedic Surgery, Chang Gung Memorial Hospital, Puzi City, Chiayi County

Chiang-Wen Lee
Department of Nursing, Division of Basic Medical Sciences, and Chronic Diseases and Health Promotion Research Center, Chang Gung University of Science and Technology, Puzi City, Chiayi County

Hsin-Nung Shih
Department of Orthopedic Surgery, Chang Gung Memorial Hospital, Linkou

---

Research Article

Keywords: total hip arthroplasty, periprosthetic joint infection, iliac fossa abscess, ilioinguinal incision, debridement

Posted Date: January 21st, 2021

DOI: https://doi.org/10.21203/rs.3.rs-144908/v1

Abstract

Background: Total hip arthroplasty (THA) is a widely used and successfully performed orthopedic procedure for treating severe hip osteoarthritis, rheumatoid arthritis, and avascular necrosis. However, periprosthetic joint infection (PJI) after THA is a devastating complication for patients and orthopedic surgeons. Although surgical technology has been advanced and antibiotic-loaded cemented spacers or beads have developed, the treatment failure rate of one- or two-stage exchange arthroplasty for PJI is reported to be high, with >10% rate of incidence. Therefore, determining the possible pathogenesis and increasing the treatment success rate is a clinically important and urgent issue.

Methods: A total of 256 patients with PJI who had undergone THA from 2005 to 2015 were included in this retrospective review. Seven patients required combined ilioinguinal and anterlateoal approach for debridement of iliac fossa abscess and infected hip lesion, included five patients with intraoperative pus leakage from the acetabular inner wall and the other two patients who underwent pre-operative pelvic computed tomography (CT) because of repeat PJI treatment failure. All available data from the medical records from all patients were retrospectively analyzed.

Results: Of the 256 patients, seven (3.1%) patients was combined iliac fossa abscess in our cohort. For the microbiologic analysis, a total of thirteen pathogens were isolated from seven recurrent PJI patients with iliac fossa abscess, and *Staphylococus aureus* was the most commomly pathogen (4 out of 7 cases). The serum white blood cell (WBC) count was decreased significantly two weeks after debridement with combined the ilioinguinal and anterolateral approach compared to the day before surgery (11840/μL vs. 7370/μL; $p<0.01$), and level of C-reactive protein (CRP) was decreased at postoperative one week (107 mg/dL vs. 47.31 mg/dL; $p=0.03$). Furthermore, no recurrent infection was found in six revision THA patient in a follow up of 7.1 year.

Conclusion: This result suggests that pre-operative pelvic CT and cautious identification of uncertain pus leakage from the inner wall of the acetabulum is essential for the diagnosis of recurrent PJI. Radical debridement with combined ilioinguinal and anterlateoal approach may aviod treatment failure in recurrent PJI with iliac fossa abscess.

Background

Total hip arthroplasty (THA) is one of the most frequently performed adult orthopedic procedures, with nearly one million patients undergoing THA annually [1]. The number of THAs performed annually is increasing [2]. A statistical report revealed that 332,000 THAs were performed in the United States in 2010 [3], and it was predicted that this number will increase to 527,000 (137%) by 2030 [2]. In addition, a recent study suggested that patients undergoing THA have a higher survival rate (10 years after surgery) than the general population[4]. This implies that the expected lifespan of patients with THA is increasing. However, periprosthetic joint infection (PJI) in THA patients is a devastating complication that has challenged patients, orthopedists, and the global health care industry because an increasing number of

THA procedures are being performed [3, 5–7]. The incidence of PJIs after primary THA is 0.5–3% and after revision joint arthroplasty is 4–6% [8].

Generally, several clinical treatment strategies are applied—radical debridement with retention of the implant and long-term antibiotic administration, exchange arthroplasty, which includes one- or two-stage (immediate or delayed) revisions, and excision arthroplasty [9, 10]. The treatment failure rate for PJI at follow-up has been reported to be high (one- or two-stage surgical treatment: >10% and surgical debridement: 30–50%) [11–16]. The two-stage surgical method has a better success rate (91%) than the one-stage (82%) [17]. Although several novel therapeutic methods and agents have been suggested, the pathogenesis and > 10% incidence of recurrent PJI are unclear and difficult to overcome. Hence, reducing the treatment failure rate of PJI is a concern and urgent requirement to be resolved. Hence, this retrospective study evaluated the incidence and management of PJIs with iliac fossa abscess to aviod treatment failure.

Materials And Methods

Hospital setting

This study was conducted at the Chang Gung Memorial Hospital in Taiwan and was approved by the Institutional Review Board (IRB number: 201900832B0) and Ethics Committee.

Definitions of PJI

All patients were diagnosed with PJI based on the Musculoskeletal Infection Society (MSIS) criteria and McPherson staging system [18, 19]. A diagnosis of PJI was made if at least one of followed criteria was fulfilled: (1) presence of sinus tract communication with the prosthesis, (2) a pathogen was isolated from the culture of at least two separate tissue or fluid samples obtained from the affected prosthetic joint, and (3) four of the following six biochemistry phenomena were observed: (i) increase in the C-reactive protein (CRP) level and erythrocyte sedimentation rate (ESR), (ii) increase in the synovial leukocyte count, (iii) increase in the percentage of polymorphonuclear cells (%PMNs) in the synovia, (iv) presence of purulence in the affected joint, (v) isolation of a microorganism from one of the periprosthetic tissue cultures, (vi) presence of more than five neutrophils per high-power field in five high-power fields, histological analysis of the periprosthetic tissue at ×400 magnification.

Study population

A total of 256 patients with PJI after THA at Chang-Gung Memorial Hospital in Taiwan from November 2005 to December 2015 were included in this retrospective review. Seven patients required combined ilioinguinal and anterlateoal approach for debridement of iliac fossa abscess and infected hip lesion, included five patients with intraoperative pus leakage from the acetabular inner wall during debridement and the other two patients who underwent pre-operative pelvic computed tomography (CT) because of

repeat PJIs. The mean age of these seven patients was 67 years (range: 42–83 years) and the mean follow-up period was 7.1 years (range: 3–13 years).

Measurement of biomarkers

The levels of white blood cell (WBC) count, CRP, and ESR were measured before and one week, two weeks, and 4 weeks after debridement with combined the ilioinguinal and anterolateral approach.

Statistical analysis

All data were analyzed using one-way analysis of variance, and a Tukey post hoc test was performed for multiple comparisons ($p < 0.05$). All statistical calculations were performed using GraphPad Prism version 7.0 (GraphPad Software Inc., San Diego, CA), and all values were reported as mean ± standard deviation.

Results

In our study population, the incidence of PJIs combined with iliac fossa abscess was 3.1% (7/256). The mean number of repeated debridements performed in PJI patients with iliac fossa abscess was 4.8 (range, 1–13 times). Accroding to the medical records, the numbers of male and woman PJI patients with iliac fossa abscess were 4 (57%) and 3 (43%), respectively, and these patients had average age was 67 years (range from 42 to 83). Comparison of Musculoskeletal Infection Society (MSIS) classification, there was no significant difference between PJI patients and PJI patients with iliac fossa abscess. (Table 1)

Table 1
Demographic data of patients

Characteristic	Iliac fossa abscess	
	Yes	No
Patients, N = 256	7	249
Gender, M:F	4:3	137:112
Mean age, years (range)	67 (42–83)	62 (45–84)
Repeat debridement, times (range)	4.8 (1–13)	1.3 (1–5)
MSIS classification, n (%)		
A2		38 (15%)
A3	1 (14.3%)	73 (29.3%)
B1	1 (14.3%)	65 (26.1%)
B2	1 (14.3%)	45 (18.1%)
C1	2 (28.6%)	16 (6.4%)
C2	2 (28.6%)	12 (4.8%)
MSIS, Musculoskeletal Infection Society		

A total of thirteen pathogens were isolated from seven recurrent PJI patients with iliac fossa abscess in the microbiologic findings, and *Staphylococus aureus* was the most commomly pathogen. (4 out of 7 cases ,57%). Particulaly, we noticed that diabetes mellitus (DM) was most occurred in PJI patients with iliac fossa abscess (2 out of 7 cases), and other comorbidity disease was occurred in one case, including chronic hepatitis and cirrhosis and cancer. Our data showed no significant linkage in these patients with regard to sex, age, hip location and underlying comorbidity (Table 2). Figure 1 and Fig. 2 showed pre-operative pelvic CT images of patients with recurrent PJI and iliac fossa abscess, and operative wound had healed well two weeks after the combied ilioinguinal incision procedure.

TABLE 2. Pathogen and comorbidity in patients of recurrent PJI with iliac fossa abscess

Patients	Age	Sex	Location (L/R Hip)	Diagnosis of iliac fossa abscess	Comorbidity	Pathogen
1	66	M	L	Intraoperative pus leakage from the acetabular inner wall	nil	*Viridans streptococcus*
2	78	F	L	Intraoperative pus leakage from the acetabular inner wall	Cervical cancer	*Bacteroides fragilis*
						Proteus mirabilis
						Enterococcus faecium
						Proteus vulgaris
						Veillonella sp
						Acinetobacter baumannii
						Viridans streptococci
3	69	M	R	Intraoperative pus leakage from the acetabular inner wall	nil	*Staphylococcus aureus*
4	83	F	R	Pelvic CT	CHC	*Acinetobacter baumannii*
						Staphylococcus capitis
						Staphylococcus epidermidis
						Candida albicans
						Klebsiella pneumoniae
5	77	F	L	Intraoperative pus leakage from the acetabular inner wall	DM	*Staphylococcus aureus*
						Enterococcus faecalis
						Finegoldia magna
6	42	M	L	Intraoperative pus leakage	DM	*Staphylococcus*

				from the acetabular inner wall		*aureus*
7	52	M	L	Pelvic CT	nil	*Serratia marcescens*
						Staphylococcus aureus
						Yeast-like bacteria

Abbreviation: CT, computed tomography; CHC, Chronic hepatitis and cirrhosis; DM, Diabetes mellitus

Moreover, we also compared different inflammatory markers, including C-reactive protein (CRP), white blood cell (WBC), and erythrocyte sedimentation rate (ESR) in these PJI patients with iliac fossa abcess. The serum WBC count was decreased significantly two weeks after debridement with combined the ilioinguinal and anterolateral approach compared to the day before surgery (11840/μL vs. 7370/μL; $p < 0.01$), and level of CRP was decreased at postoperative one week (107 mg/dL vs. 47.31 mg/dL; $p = 0.03$). However, no significant difference was found in mean ESR level over time (Fig. 3). A notable decrease in the level of PJI biomarkers indicates that the infection is controlled. Six of seven patients were shifted to revision total hip replacement after infection was controlled. One patient denied the revision operation because of personal reasons. At end of follow up, no recurrent PJI was found in this study group.

Discussion

PJIs are an important medical challenge, considering the number of THAs and lifetime spent on treatment are increasing [2–5]. Several risk factors that have been indicated to be associated with the development of PJI are high body mass index (BMI; >30), diabetes mellitus, rheumatoid arthritis, revision surgery, tobacco or steroid use, methicillin-resistant *Staphylococcus aureus* colonization, infection, and history of bone cancer [20]. Furthermore, PJI is the key factor of mortality and morbidity of THA patients [21]. The major characteristic of PJI pathogenesis is that it is associated with the bacterial invasion of the surface of prosthetic implants and production of biofilms [22]. The biofilm formation could create a barrier against the antibiotic effects and subsequently, increase the treatment failure rate. However, although the knowledge regarding metabolic processes and bacterial communication in biofilms have been improved recently [23], successful PJI eradication PJI through revision surgery in the clinic remains poor and requirement improvement. Several enhanced methods and novel agents such as antibiotic combination therapy, antibiotic delivery through nanoparticles, photodynamic therapy, and nanoparticles with bactericidal effects have been suggested for treating PJI to increase the treatment success rate [24].

However, some diffiucult treatment of PJIs may not be due to the biofilm formation or antibiotic-resistant bacterial strain colonization. The other risk factors associated with treatment failure of PJI include longer duration of symptoms prior to treatment with debridement, the soft tissue intergrity and *Staphylococcus aureus* infection [25–27]. In the current study, we provided an another possible reason—a non-visible

abscess in the iliac fossa or pyomyositis during debridement in acetabular wall. In our study, 3.1% of patients developed PJI with iliac fossa abscess or iliacus muscle pyomyositis. In addition, we provided a treatment strategy for patients with PJI and iliac fossa abscess or iliacus muscle pyomyositis. The combination of two approaches included the ilioinguinal and anterolateral incision for debridement is necessary to eradicate iliac fossa pus and infected tissue. Through the two approaches debridement, the values of infection biomarkers were reduced and also indicated that the prognosis of patients was significantly improved. Furthermore, no recurrent infection was found in six revision THA patient in a follow up of 7.1 year. In this retrospective review, *Staphylococus aureus* was the most commomly pathogen isolated from recurrent PJI patients with iliac fossa abscess (4 out of 7 cases). Our funding support the conclusion of previous studies that *Staphylococcus aureus* infection was the major clinical risk for treatment failure [26]. Moreover, The presence of liver disease had been associated with the development of PJIs failure treatment in previous study. But only one case with chronic hepatitis and cirrhosis was found in our study and no significant linkage was showed in PJI patients with iliac fossa abscess. There were other comorbidity factors for PJI treatment failure, including history of myocardial infarction, presence of sinus tract, smoking and obesity [28–30]. However, our study did not find these risk factors in PJI patients with iliac fossa abscess.

We acknowledge that our study has some limitations. First because this was a retrospective study, the occurrence time and source of iliac fossa abscess or pyomyositis are not fully confirmed. Second, all patients did not undergo pre-operative pelvic CT examination. Third, our study population was small.

Conclusion

This study intended to provide a possible pathogenesis of recurrent PJI. The iliac fossa abscess or pyomyositis in patients with PJI may be ignored during the surgical procedure because they are not visible or difficult to find. However, undestroyed abscess in the iliac fossa or pyomyositis are risk factors for reinduction of PJI. Hence, we strongly recommend that pre-operative pelvic CT should be performed for the diagnosis iliac fossa abscess or pyomyositis in patients with recurrent PJI and further, suggest that ilioinguinal incision should be performed for the removal of intrapelvic abscess.

List Of Abbreviations

ASIS, anterior superior iliac spine; BMI, body mass index; ESR, erythrocyte sedimentation rate; CRP, C-reactive protein; CT, computed tomography; %PMNs, percentage of polymorphonuclear cells; PJI, periprosthetic joint infection; THA, total hip arthroplasty; WBC, white blood cell.

Declarations

Ethics approval

This study was conducted at the Chang Gung Memorial Hospital of Taiwan and was approved by the Institutional Review Board of Chang Gung Medical Foundation (IRB number: 201900832B0). All methods were carried out in accordance with relevant guidelines and regulations, and the requirement for informed consent was waived due to this a retrospective study by the Institutional Review Board of Chang Gung Medical Foundation.

Consent for publication

Not applicable

Availability of data and materials

All data and materials supporting the conclusions of this article are contained within the manuscript.

Competing interests

The authors declare that they have no competing interests.

Author's contribution

Conceived and designed the experiments: KTP, TYH, HNS. Performed the experiments: KTP, TYH, HNS, JLC,CWL. Analyzed and interpreted the data: KTP, HNS, JLC. Contributed reagents/materials/analysis tools: TYH,CWL. Contributed to the writing of the manuscript: KTP, TYH, HNS, JLC. All authors read and approved the final manuscript.

ACKNOWLEDGMENTS

This study was supported by a grant from the Chang Gung Medical Research Program Foundation [CMRPG6H0402 and CMRPG6J0231-0232] and Ministry of Science and Technology (ROC) (NMRPG6K6011, and NMRPG3J0151).

AUTHOR DETAILS

[1]Department of Orthopedic Surgery, Chang Gung Memorial Hospital, Puzi City, Chiayi County 61363, Taiwan.

[2]College of Medicine, Chang Gung University, Guishan Dist., Taoyuan City 33303, Taiwan.

[3]Division of Infectious Diseases, Department of Internal Medicine, Chang Gung Memorial Hospital, Chiayi, Taiwan

[4]Department of Nursing, Chang Gung University of Science and Technology, Chiayi Campus, Chiayi, Taiwan

[5]Department of Nursing, Division of Basic Medical Sciences, and Recurrent Diseases and Health Promotion Research Center, Chang Gung University of Science and Technology, Puzi City, Chiayi County 61363, Taiwan

[6]Research Center for Industry of Human Ecology and Research Center for Chinese Herbal Medicine, Chang Gung University of Science and Technology, Guishan Dist., Taoyuan City 33303, Taiwan

[7]Department of Rehabilitation, Chang Gung Memorial Hospital, Puzi City, Chiayi County 61363, Taiwan

[8]Department of Orthopedic Surgery, Chang Gung Memorial Hospital, Linkou, Taiwan

Email

Kuo-Ti Peng: mr3497@cgmh.org.tw

Tsung-Yu Huang: r12045@cgmh.org.tw

Jiun-Liang Chen: yq0139@cgmh.org.tw

Chiang-Wen Lee: cwlee@mail.cgust.edu.tw

Hsin-Nung Shih: aronc@adm.cgmh.org.tw

References

1. Pivec R, Johnson AJ, Mears SC, Mont MA. Hip arthroplasty. *Lancet* 2012; 380(9855):1768–1777.
2. Kurtz S, Ong K, Lau E, Mowat F, Halpern M. Projections of primary and revision hip and knee arthroplasty in the United States from 2005 to 2030. *J Bone Joint Surg Am* 2007; 89(4):780–785.
3. Tande AJ, Patel R. Prosthetic joint infection. *Clin Microbiol Rev* 2014; 27(2):302–345.
4. Cnudde P, Rolfson O, Timperley AJ, Garland A, Karrholm J, Garellick G, Nemes S. Do Patients Live Longer After THA and Is the Relative Survival Diagnosis-specific? *Clin Orthop Relat Res* 2018; 476(6):1166–1175.
5. Kurtz SM, Lau E, Watson H, Schmier JK, Parvizi J. Economic burden of periprosthetic joint infection in the United States. *J Arthroplasty* 2012; 27(8 Suppl):61–65 e61.
6. Peel TN, Dowsey MM, Buising KL, Liew D, Choong PF. Cost analysis of debridement and retention for management of prosthetic joint infection. *Clin Microbiol Infect* 2013; 19(2):181–186.
7. McConoughey SJ, Howlin R, Granger JF, Manring MM, Calhoun JH, Shirtliff M, Kathju S, Stoodley P. Biofilms in periprosthetic orthopedic infections. *Future microbiology* 2014; 9(8):987–1007.
8. Sanchez-Sotelo J, Berry DJ, Hanssen AD, Cabanela ME. Midterm to long-term followup of staged reimplantation for infected hip arthroplasty. *Clin Orthop Relat Res* 2009; 467(1):219–224.

9. Rao N, Ziran BH, Lipsky BA. Treating osteomyelitis: antibiotics and surgery. *Plast Reconstr Surg* 2011; 127 Suppl 1:177S-187S.
10. Fagotti L, Tatka J, Salles MJC, Queiroz MC. Risk Factors and Treatment Options for Failure of a Two-Stage Exchange. *Curr Rev Musculoskelet Med* 2018.
11. Vilchez F, Martinez-Pastor JC, Garcia-Ramiro S, Bori G, Macule F, Sierra J, Font L, Mensa J, Soriano A. Outcome and predictors of treatment failure in early post-surgical prosthetic joint infections due to Staphylococcus aureus treated with debridement. *Clin Microbiol Infect* 2011; 17(3):439–444.
12. Byren I, Bejon P, Atkins BL, Angus B, Masters S, McLardy-Smith P, Gundle R, Berendt A. One hundred and twelve infected arthroplasties treated with 'DAIR' (debridement, antibiotics and implant retention): antibiotic duration and outcome. *J Antimicrob Chemother* 2009; 63(6):1264–1271.
13. Bryan AJ, Abdel MP, Sanders TL, Fitzgerald SF, Hanssen AD, Berry DJ. Irrigation and Debridement with Component Retention for Acute Infection After Hip Arthroplasty: Improved Results with Contemporary Management. *J Bone Joint Surg Am* 2017; 99(23):2011–2018.
14. Lora-Tamayo J, Murillo O, Iribarren JA, Soriano A, Sanchez-Somolinos M, Baraia-Etxaburu JM, *et al.* A large multicenter study of methicillin-susceptible and methicillin-resistant *Staphylococcus aureus* prosthetic joint infections managed with implant retention. *Clin Infect Dis* 2013; 56(2):182–194.
15. Nodzo SR, Boyle KK, Spiro S, Nocon AA, Miller AO, Westrich GH. Success rates, characteristics, and costs of articulating antibiotic spacers for total knee periprosthetic joint infection. *Knee* 2017; 24(5):1175–1181.
16. Ricciardi BF, Muthukrishnan G, Masters E, Ninomiya M, Lee CC, Schwarz EM. Staphylococcus aureus Evasion of Host Immunity in the Setting of Prosthetic Joint Infection: Biofilm and Beyond. *Curr Rev Musculoskelet Med* 2018.
17. Hsieh PH, Huang KC, Lee PC, Lee MS. Two-stage revision of infected hip arthroplasty using an antibiotic-loaded spacer: retrospective comparison between short-term and prolonged antibiotic therapy. *J Antimicrob Chemother* 2009; 64(2):392–397.
18. Workgroup Convened by the Musculoskeletal Infection S. New definition for periprosthetic joint infection. *J Arthroplasty* 2011; 26(8):1136–1138.
19. McPherson EJ, Woodson C, Holtom P, Roidis N, Shufelt C, Patzakis M. Periprosthetic total hip infection: outcomes using a staging system. *Clin Orthop Relat Res* 2002(403):8–15.
20. Kuiper JW, Willink RT, Moojen DJ, van den Bekerom MP, Colen S. Treatment of acute periprosthetic infections with prosthesis retention: Review of current concepts. *World J Orthop* 2014; 5(5):667–676.
21. Natsuhara KM, Shelton TJ, Meehan JP, Lum ZC. Mortality During Total Hip Periprosthetic Joint Infection. *J Arthroplasty* 2018.
22. Mirza YH, Tansey R, Sukeik M, Shaath M, Haddad FS. Biofilm and the Role of Antibiotics in the Treatment of Periprosthetic Hip and Knee Joint Infections. *Open Orthop J* 2016; 10:636–645.
23. McConoughey SJ, Howlin R, Granger JF, Manring MM, Calhoun JH, Shirtliff M, Kathju S, Stoodley P. Biofilms in periprosthetic orthopedic infections. *Future Microbiol* 2014; 9(8):987–1007.

24. Taha M, Abdelbary H, Ross FP, Carli AV. New Innovations in the Treatment of PJI and Biofilms-Clinical and Preclinical Topics. *Curr Rev Musculoskelet Med* 2018; 11(3):380–388.
25. Kandel CE, Jenkinson R, Daneman N, Backstein D, Hansen BE, Muller MP, Katz KC, Widdifield J, Bogoch E, Ward S *et al.* Predictors of Treatment Failure for Hip and Knee Prosthetic Joint Infections in the Setting of 1- and 2-Stage Exchange Arthroplasty: A Multicenter Retrospective Cohort. *Open Forum Infect Dis* 2019; 6(11):ofz452.
26. Lee J, Kang CI, Lee JH, Joung M, Moon S, Wi YM, Chung DR, Ha CW, Song JH, Peck KR. Risk factors for treatment failure in patients with prosthetic joint infections. *J Hosp Infect* 2010; 75(4):273–276.
27. Hsieh PH, Lee MS, Hsu KY, Chang YH, Shih HN, Ueng SW. Gram-negative prosthetic joint infections: risk factors and outcome of treatment. *Clin Infect Dis* 2009; 49(7):1036–1043.
28. Hoell S, Sieweke A, Gosheger G, Hardes J, Dieckmann R, Ahrens H, Streitbuerger A. Eradication rates, risk factors, and implant selection in two-stage revision knee arthroplasty: a mid-term follow-up study. *J Orthop Surg Res* 2016; 11(1):93.
29. Jhan SW, Lu YD, Lee MS, Lee CH, Wang JW, Kuo FC. The risk factors of failed reimplantation arthroplasty for periprosthetic hip infection. *BMC Musculoskelet Disord* 2017; 18(1):255.
30. Xu C, Kuo FC, Kheir M, Li X, Chai W, Chen JY. Outcomes and predictors of treatment failure following two-stage total joint arthroplasty with articulating spacers for evolutive septic arthritis. *BMC Musculoskelet Disord* 2019; 20(1):272.

Figures

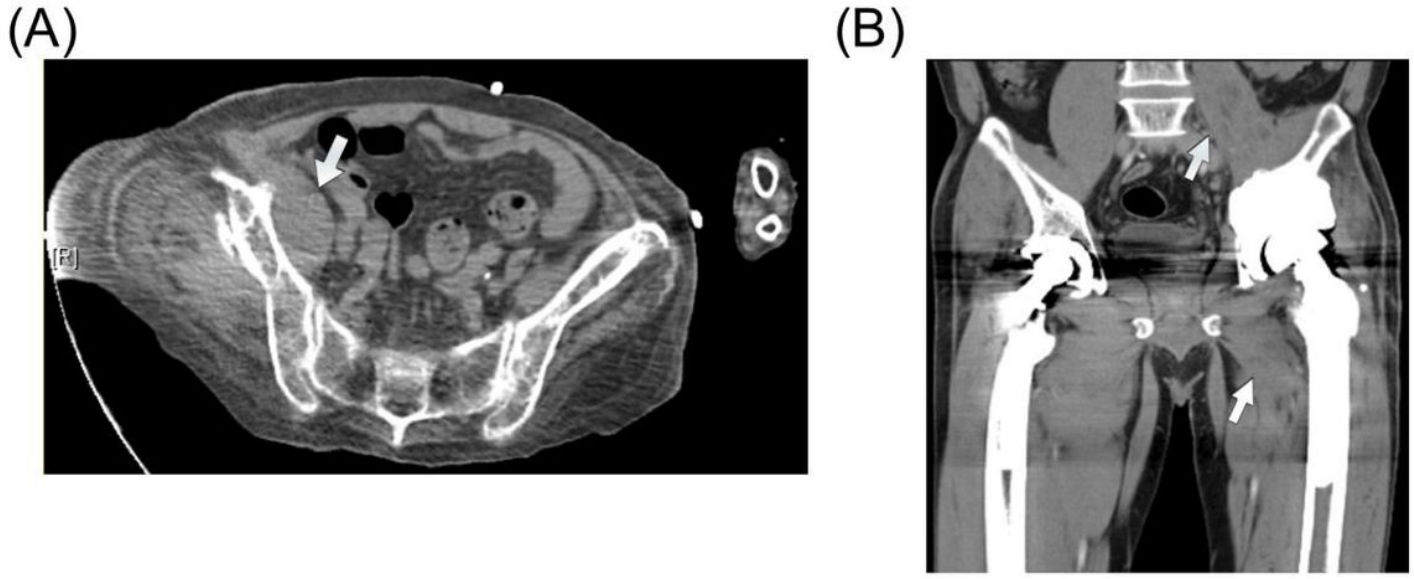

Figure 1

Pre-operative pelvic computed tomography (CT) images of patients with recurrent PJI (A) Status of PJI in 83 y/o female patient after four operations. (B) Status of PJI in 52 y/o male patient after six operations. The arrows indicate the locations of abscess in the iliac fossa and muscle.

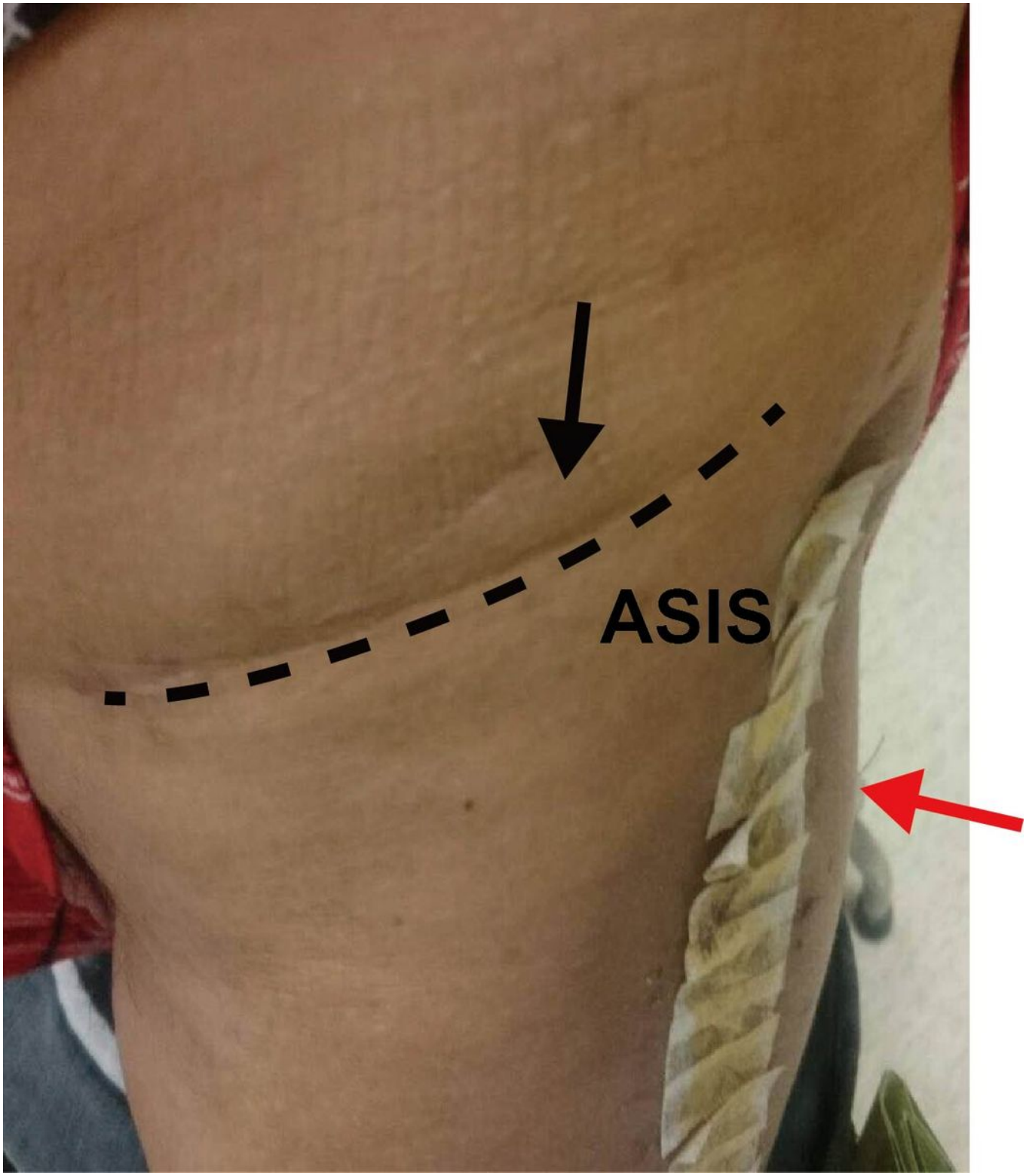

Figure 2

Photograph of ilioinguinal incision on the left thigh of a patient with PJI. The arrow indicates the incision site and dotted line indicates the location of the anterior superior iliac spine (ASIS).

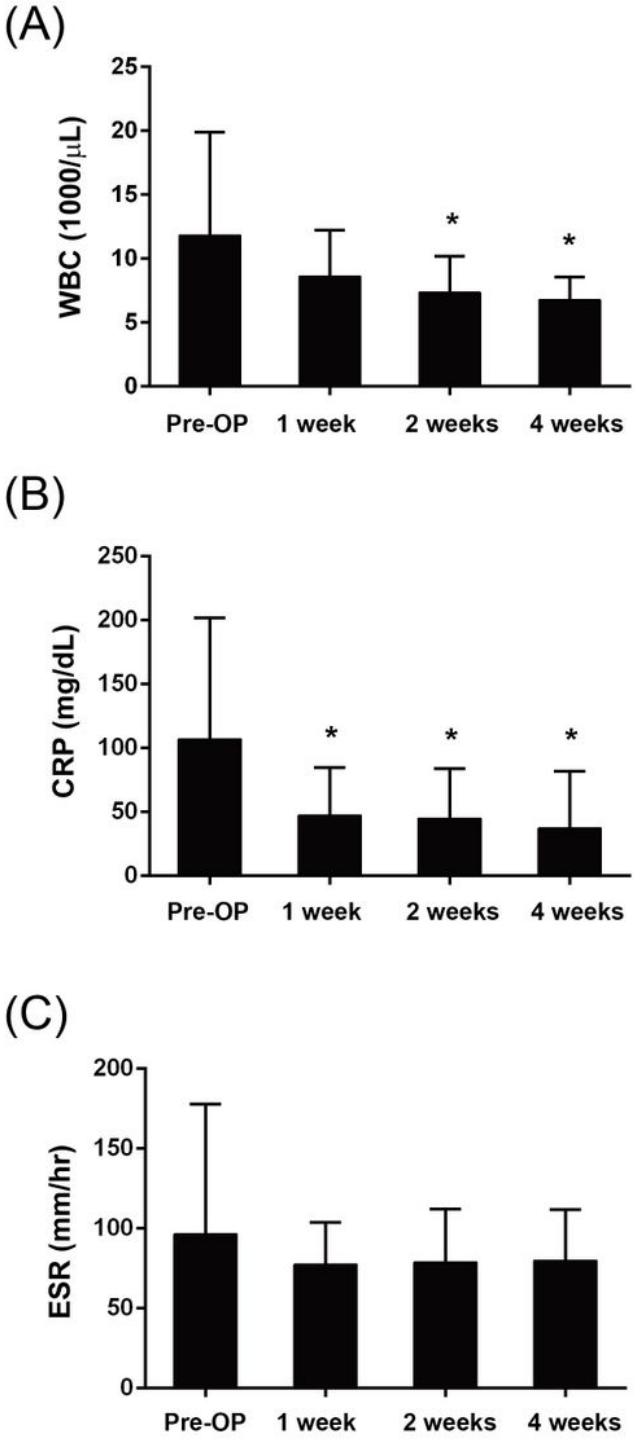

Figure 3

The levels of (A) WBC count, (B) CRP, and (C) ESR were measured before the surgery and one week, two weeks, and four weeks after the index operation. *$p < 0.05$ compared to the day before surgery.