A rare case of cervical squamous cell carcinoma combined with sinonasal inverted Papilloma: A case report

Xiaoyu Hou
University of Electronic Science and Technology
Chunrong Peng
Sichuan Cancer Hospital, University of Electronic Science and Technology
Guonan Zhang
Sichuan Cancer Hospital, University of Electronic Science and Technology
Dengfeng Wang (wonderful_96@163.com)
Sichuan Cancer Hospital, University of Electronic Science and Technology

Case Report

Keywords:

Posted Date: March 18th, 2022

DOI: https://doi.org/10.21203/rs.3.rs-1449494/v1

Abstract

Background: Cervical cancer is the fourth most common malignancy in women worldwide, and sinonasal inverted papilloma (SIP) is a rare benign sinus tumor and has the characteristics of destructive growth pattern, high recurrence rate and easy canceration. Cervical squamous cell carcinoma (SCC) combined with SIP has not been reported so far.

Case Presentation: A 55-year-old woman was diagnosed with cervical SCC in our center and treated with concurrent radiochemotherapy. During the follow-up period, SIP was found twice and both underwent endoscopic left nasal tumor resection. The clues that the diseases were found were the abnormal rise of squamous cell carcinoma antigen (SCCA). SCCA level decreased to normal after operations.

Discussion and Conclusion: (1) when the cervical lesions have resolved satisfactorily but the SCCA is still high, other sites should be promptly investigated for the cause, which may lead to earlier detection and earlier treatment of SIP. (2) Combined with the literature, we recommend that SCCA can be used as a routine monitoring index for SIP. If available, a combination of SCCA1 and SCCA2 can be tried for further judgement. (3) For SIP with a high recurrence rate, can anti-HPV treatment be taken after operation to reduce the risk of recurrence?

Background

Cervical cancer is the fourth most common malignancy in women worldwide, about 84% of it occurs in developing countries, and has been the most common malignancy of the female reproductive system in China [1]. It is reported that in 2020 there are about 604,000 new cases of cervical cancer and 42,000 deaths in the worldwide [2]. There are different histological types of cervical cancer, such as cervical squamous cell carcinoma (SCC), cervical adenocarcinoma, cervical adenosquamous carcinoma and other rare types, of which squamous carcinoma accounts for about 75–80%[3]. For the treatment of cervical cancer, surgery is the mainstay in the early stages, while concurrent radiochemotherapy is preferred in the middle and advanced stages (International Federation of Gynecology and Obstetrics (FIGO) 2018 stages IIB-IVA) [4].

Sinonasal papilloma (SP), also previously known as schniderian papilloma, includes the three major subtypes: inverted papilloma, oncocytic papilloma and exophytic papilloma[5]. sinonasal inverted papilloma (SIP) is the most common subtype and is a rare benign sinus tumor with an incidence of 0.74–1.5/100,000 people per year[6]. SIP originates from the respiratory mucosa differentiated from the ectoderm, accounting for 0.4%-4.7% of all nasal cavity tumors [7]. SIP tends to occur in the age group of 50–70 years old [8], and has a high malignant transformation rate (13.64%) and the recurrence rate (34.09%) [9]. Clinical manifestations of this disease include unilateral nasal congestion, epistaxis, headache, sinusitis, loss of smell, otitis media, vertigo, hearing loss, diplopia, periorbital swelling, etc. [10], 90% of the cases are unilateral [11].

Cervical squamous cell carcinoma combined with SIP has not been reported so far. A case treated in our hospital is reported as follows.

Case Presentation

The patient, female, 55 years old, was admitted to our hospital in October 2019 because of "irregular vaginal bleeding for 2 months after menopause". Specialized physical examination showed a normal vulva, unobstructed vagina while the vaginal fornix had disappeared, the cervix was nodular cauliflower-shaped, approximately 5 cm in diameter, positive for blood on palpation. Bilateral parauterine tissues were hard, shortened, did not reach the lateral pelvic wall, and no obvious abnormalities were found in the uterine body and bilateral adnexal areas. Before admission, cervical SCC was found in cervical biopsy in another hospital. Pathological consultation in our hospital suggested medium-poorly differentiated cervical SCC. After admission, relevant examinations were completed: serum carcinoembryonic antigen (CEA) was 9.86 ng/mL (normal range 0–5 ng/mL), squamous cell carcinoma antigen (SCCA) was 19.60 ng/mL (normal range 0-1.8ng/mL). The enhanced magnetic resonance imaging (MRI) of the whole abdomen showed: (1) there was a soft tissue thickening occupying space in the cervix (approximately 4.6*3.8*5.3 cm in size) (Fig. 1A), which was consistent with the changes of cervical cancer, and the adjacent vaginal wall was invaded, and the uterine wall might be invaded. (2) there was a nodule (approximately 3.1*2.5 cm in size) near the left pelvic wall (Fig. 1C), which was considered to be a metastatic lymph node, and there were several small and slightly large lymph nodes in the bilateral pelvic wall and inguinal region. According to the imaging findings, a diagnosis of medium-poorly differentiated cervical SCC stage IIIC1r (FIGO 2018) was made. From 4th November 2019 to 30th December 2019, external pelvic intensity modulated radiation therapy was performed, once a day at 200 cGy/dose from Monday to Friday, for a total of 25 doses, and sequential internal and external three-dimensional conformal radiotherapy was performed for 5 doses at 500 cGy/dose. Three cycles of TC regimen chemotherapy were administered on 11th October, 2019, 24th November, 2019 and 4th January, 2020. The MRI was repeated at the end of treatment and the lesion regressed satisfactorily (Fig. 1B, 1D). After that, the patient was followed up regularly in our outpatient department.

Her serum SCCA remained significantly higher than the normal range and gradually increased during the outpatient review period from February 2020 to August 2020. Repeated gynecological examination, cervical liquid-based cytology, chest computed tomography (CT) and abdominal MRI showed no obvious abnormalities. A positron emission tomography-computed tomography (PET-CT) was then performed on 15th September, 2020, which revealed that there was the soft tissue shadow in the left maxillary sinus, partially protruding into the left nasal cavity and poorly demarcated from the left superior and middle turbinate, and that the lesion was hypermetabolic (maximum and mean standardized uptake values [SUV_{max} and SUV_{mean}] were 7.2 and 4.5, respectively), and tumor lesion was not excluded (Fig. 2). Further electronic nasopharyngoscopy showed that there was a rough protuberance of the local mucosa in the posterior portion of the middle nasal meatus on the left side, and the nature was undefined; No other abnormalities were noted. Head MRI showed a soft tissue mass occupying the left maxillary sinus and

the left nasal cavity (approximately 3.9*2.6 cm in size), invaded the left middle and upper turbinate and the left ethmoid sinus, and was poorly demarcated from the nasal septum (Fig. 3). On 12th October, 2020, a nasal endoscopic resection of the left nasal sinus tumor and radical excision of the left maxillary sinus and left ethmoid sinus, along with partial resection of the middle turbinate and inferior turbinate was performed in the department of head and neck surgery of our hospital. Intraoperative nasal endoscopic found that the upper side of the nasal septum was slightly deviated; a greyish-white neoplasm was detected in the left middle nasal meatus with papillary surface and no obvious necrotic pseudomembrane, which invaded uncinate process; no other significant abnormalities were observed. Postoperative pathological examination of neoplasm in left maxillary sinus was schniderian papilloma which was suspected to have a tendency to progress to well-differentiated SCC. The SCCA was reviewed 4 weeks after operation, which decreased to normal value (1.49 ng/mL).

In the subsequent regular follow-up, the SCCA was found to be gradually elevated again from 2 months after operation and continuously higher than the normal level (Fig. 5). No abnormality was found in the cervix examinations again, so MRI of the sinuses was performed on 27th May, 2021 that revealed a nodular soft tissue shadow (approximately 1.9*1.7*1.3 cm in size) in the left nasal cavity and the inner wall of the maxillary sinus in the operative area (Fig. 4). The electronic nasopharyngoscopy showed an undefined mass in the left nasal cavity, and recurrence of the tumor was considered. Hence, on 18th June, 2021, an exploratory surgery and extensive resection of the tumor of the left nasal cavity and sinus, along with removal of the left ethmoid sinus lesion and radical resection of the left maxillary sinus was performed by nasal endoscope in our head and neck surgery department. Intraoperative nasal endoscopy showed the nasal septum was slightly deviated; a greyish-white neoplasm was detected in the left middle nasal meatus and maxillary sinus with papillary surface and no obvious necrotic pseudomembrane, which invaded middle part of inferior nasal meatus, inferior turbinate and nasolacrimal duct; no other significant abnormalities were observed. Postoperative pathological examination of neoplasm in left nasal cavity suggested schniderian papilloma with squamous epithelium which was papilloma-like hyperplasia, and some areas had an inverted growth pattern. Then she went to the pathology department of the West China Hospital of Sichuan University for pathological consultation, and the result was inverted papilloma. Immunohistochemistry showed P16 (-), P53 (+/-), S-100 (-), Ki-67 (+); HPV (total) (-), HPV6/11 (-). Her SCCA decreased to normal (1.09 ng/mL) in 2 weeks after operation. Until now, the patient has been in good condition and the SCCA has remained within the normal range (Fig. 5).

Discussion And Conclusions

SCCA is a member of serine protease inhibitor (serpins) ovalbumin family at the gene level, which is transcribed by two highly homologous genes, *SCCA1* and *SCCA2* [12]. At the macromolecular level, SCCA is a sub component of tumor-associated antigens and derived from SCC tissue, which was first isolated from cervical SCC tissue[13]. Elevated SCCA can be detected in SCC of the tongue, esophagus, tonsil, epidermal follicle, lung and uterus[14]. At present, SCCA has become a recognized relatively specific disease-related monitoring index for cervical SCC. It has important clinical significance for the diagnosis,

efficacy monitoring and prognosis of the disease, and it is also an important indicator for follow-up of patients with cervical SCC after treatment. The SCCA of the patient we reported was significantly elevated at the time of initial diagnosis, being more than 10 times the upper limit of normal value. During chemoradiotherapy, the lesions regressed satisfactorily, but the SCCA only showed a slow decline and remained at a high level (14.62ng/mL) at the end of treatment. During the subsequent months of outpatient follow-up, it was found that the SCCA remained high (> 10ng/mL) and gradually increased. We first considered the possibility of cervical SCC progression, but no abnormalities were found in related examinations. To further investigate the cause, we performed a whole-body PET/CT scan on the patient and found a metabolically significantly elevated soft tissue shadow in the left maxillary sinus. After surgical resection, the SCCA rapidly dropped to normal (1.49 ng/mL) after surgical excision, and the discovery for SIP recurrence was due to a slow and gradual increase in SCCA after surgery, which again rapidly decreased to normal after the second surgical excision. As a routine and relatively specific indicator of cervical SCC, SCCA appears to be less impact on the progression of cervical SCC, a malignant tumor, than the benign tumor SIP, which leads us to be interested in the possible association between SCCA and cervical SCC and SIP.

SP was first reported in 1854 by Ward and it was thought to originate from schnerderian epithelium located in the sinuses[15]. The cause of the disease is still unknown, but different etiologies have been postulated, including human papilloma virus (HPV) infection, chronic inflammation, environmental pollution and occupational exposure (such as welding fumes, nickel compounds and organic solvents) [16]. It usually occurs in the lateral nasal wall, ethmoid sinus, and maxillary sinus, but rarely in the frontal and sphenoid sinuses[17–18]. The disease has the characteristics of destructive growth pattern, high recurrence rate and easy canceration. At present, the preferred treatment is endoscopic sinus inverted papilloma resection [19]. However, even after extensive resection of the tumor, there is still a risk of recurrence or malignancy. Moreover, the recurrence rate (RR) of SIP is also largely affected by the location of tumor growth and invasion. In 2000, Krouse proposed a staging system based on the extent of tumor involvement noted on endoscopic examination of the nasal cavity and imaging examination evaluation [20]. A study has shown that in the Krouse staging system, as the invasion of specific areas from stage I to IV changes, the postoperative RR will gradually increase[21]. Therefore, when the preoperative imaging examination shows that the tumor invades the maxillary sinus, frontal sinus, and sphenoid sinus, the surgeon should pay special attention to the thoroughness of tumor resection and the possibility of postoperative recurrence. The surgical approach also affects the RR of SIP, and the present systematic review indicates that endoscopic approach which has a lower RR is a favorable treatment option compared to external approaches [19]. In addition to these factors, the recurrence rate of SIP is also related to factors such as tumor biological variation [22]. Early diagnosis, treatment and close post-operative follow-up are important for the prognosis of patients. Therefore, it is one of the hot spots to find disease-specific indicators in order to assess the efficacy and timely detection of tumor recurrence. Some studies[23–27] have reported that serum SCCA was elevated in patients with SIP and decreased accordingly after treatment. Yamashita et al. [27] conducted a study on 30 cases of SIP patients

undergoing surgical treatment from January 2006 to January 2015. Among them, 25 patients had elevated SCCA levels, with a median preoperative serum SCCA level of 2.4 ng/mL (interquartile range 1.7–5.2 ng/mL) and 1.0 ng/mL (interquartile range 0.8–1.4 ng/mL) in the postoperative period. There was a statistically significant difference in SCCA levels between the preoperative and postoperative phases of this study ($p < 0.001$), and it was therefore suggested that SCCA can be used as an indicator for the diagnosis of SIP and for monitoring disease recurrence. Another study showed that preoperative SCCA levels were not associated with the risk of SIP recurrence, while the postoperative SCCA was positively correlated with the risk of disease recurrence ($p < 0.001$), and that patients with serum SCCA > 1.6ng/mL had a very high probability of tumor recurrence in the further. Therefore, it was recommended that the follow-up frequency should be increased and more comprehensive examination should be carried out for these patients [28].

Serum SCCA levels correlate with both cervical cancer and SIP, both of which can vary with the occurrence and progression of the disease. However, from the whole course of this patient, cervical cancer, as a malignant tumor, seems to have little impact on the changes of SCCA before and after treatment, while SIP, as a benign tumor, affects the general trend of SCCA level. Therefore, it is difficult to determine whether the treatment effect of cervical SCC is poor or the SCCA level remains high due to SIP only through the serum SCCA level. Serum SCCA levels reflect the total amount of serum SCCA1 and SCCA2, and there may be different mechanisms for elevated serum SCCA in benign tumors and SCC. Yasumatsu et al.[29] reported that SCCA1 was more strongly expressed in SIP tissues than in SCC tissues and, conversely. On the contrary, SCCA2 was predominantly expressed in SCC tissues. The results of this study are consistent with those of previous studies in cervical cancer. Previous studies have found that SCCA2 levels are more strongly expressed in malignant cervical tissues than in normal tissues[30]. Appropriate tumor markers can greatly help clinicians deal with various neoplastic diseases, including SIP and cervical cancer. We can distinguish whether SIP or cervical SCC plays a major role in the increase of serum SCCA concentration by detecting SCCA1 and SCCA2. However, this patient did not detected SCCA1 and SCCA2 because this project did not carry out in our hospital. It is possible that this patient has elevated SCCA1 levels due to SIP, and on the whole, SCCA changes with the condition of SIP.

HPV is a circular double-stranded DNA virus that mainly infects epithelial cells of the skin and mucosal tissue. It is a common pahtogen of sexually transmitted infection, and more than 200 subtypes have been found to exist[31]. According to the carcinogenicity, HPV is divided into high-risk types with carcinogenicity, and low-risk types without carcinogenicity. HPV 16, 18, 31, 33, 35, 39, 45, 51, 52, 56, 58 and 59 are the identified high-risk types. The continuous infection of these high-risk HPV is easy to lead to a variety of cancers, especially closely related to the occurrence of cervical cancer. 71% of cervical cancers are caused by infection of HPV 16 and 18[32]. HPV infection is a controversial risk factor for SIP, but is now considered to play an important role in the development of SIP. Gupta et al.[33] summarized 26 studies on HPV infection in SIP patients after April 2012 onwards, a total of 1416 samples of SIP patients were analyzed and 330 cases were found to be HPV positive (23.3%), and the average HPV positive detection rate in SIP patients in different studies ranged from 0–62%. Of the 80 SIP patients reported by

Pähler Vor der Holte et al. [34], 38 cases were HPV positive (38.8%), with the most common HPV genotypes were HPV6 (21/80, 26.3%) and HPV16 (18/80, 22.5%), followed by HPV11 (10/80, 12.5%), HPV58 (4/80, 5%), HPV42 and HPV83 (1/80, 1.3%); they also compared recurrent SP with non-recurrent SP, where the positive detection rate for HPV infection in recurrent and non-recurrent SP were 64.3% (18/28) and 41.9% (36/86), respectively. It can be inferred that HPV infection is a risk factor for SIP and plays a role in promoting the recurrence of SIP, but the detection rate varies greatly among different studies, which is not as clear as the correlation between cervical cancer and HPV. HPV may be transmitted in three ways: sexual transmission, vertical transmission, and extragenital contact. The patient reported in this case was cervical cancer combined with SIP, for which HPV16 was the common risk subtype, and extragenital contact appears to be a more plausible route of transmission for the nasopharyngeal HPV infection in this case, but oral sex has also been reported as a risk factor for HPV transmission[35]. So we speculate that it is possible that the HPV that causes cervical SCC reached the sinus region by some route, causing a local infection that contributed to the development of SIP.

At present, the patient has been followed up for more than 9 months after the second operation. The patient is generally in good condition and the SCCA has been within the normal range, and no abnormalities have been found in relevant examinations. It will be followed up for a longer time to observe the clinical outcome of the patient.

This case gives us some enlightenment: (1) SCCA, as a tumor marker closely associated with cervical SCC, is an important indicator for monitoring changes of cervical SCC. When the change of this indicator is inconsistent with the prognosis of cervical SCC, we should be vigilant about the possibility of combining with other diseases in other sites, especially tumors associated with HPV infection. At the end of radiotherapy and chemotherapy for cervical cancer, when the cervical lesions and pelvic lymph node lesions have resolved satisfactorily but the SCCA is still high, other sites should be promptly investigated for the cause, which may lead to earlier detection and earlier treatment of SIP. (2) When cervical SCC and SIP exist at the same time, it seems that SIP has a greater impact on SCCA than cervical SCC, and that SCCA is more closely related to SIP. Combined with the literature, we recommend that SCCA can be used as a routine monitoring index for SIP. If available, a combination of SCCA1 and SCCA2 can be tried for further judgement. (3) For SIP with a high recurrence rate, can anti-HPV treatment be taken after operation to reduce the risk of recurrence? This may allow the patient to avoid the second surgery within 8 months and its physical and psychological impact on the patient (the patient has a certain impact on the nasal shape after the second operation).

Declarations

Acknowledgments

We thank the relatives of the patients for allowing us to share their medical history and clinical course.

Funding:

Not applicable.

Author information

Affiliations

School of Medicine, University of Electronic Science and Technology, Chengdu 610054, China

Xiaoyu Hou

Gynecologic Oncology Center, Sichuan Cancer Hospital, the affiliated Cancer Hospital, School of Medicine, University of Electronic Science and Technology, Chengdu 610041, China

Chunrong Peng, Guonan Zhang, Dengfeng Wang

Author Contributions

DW provided patient information. XH and CP collected the data and wrote the manuscript. DW and GZ critically revised the manuscript for intellectual content. X.H. and D.W. were responsible for the study conception, design, and acquisition of financial support. XH, CP, GZ and DW were involved directly or indirectly in the care of patients. All authors contributed to the article and approved the submitted version.

Corresponding author

Correspondence to Dengfeng Wang, E-mail: wonderful_96@163.com

Ethics declarations

Ethics approval and consent to participate

The studies involving human participants were reviewed and approved by Sichuan Cancer Hospital, The affiliated Cancer Hospital, School of Medicine, University of Electronic Science and Technology.

Consent for publication

The patients provided their written informed consent to participate in this study. Written informed consent was obtained from the individual(s) for the publication of any potentially identifiable images or data included in this article.

Competing interests

The authors declare that the research was conducted in the absence of any commercial or financial relationships that could be construed as a potential conflict of interest.

Data Availability Statement

The original data presented in the study are included in the article, further inquiries can be directed to the corresponding author/s.

References

1. Arbyn M, Weiderpass E, Bruni L, de Sanjosé S, Saraiya M, Ferlay J, et al. Estimates of incidence and mortality of cervical cancer in 2018: a worldwide analysis. Lancet Glob Health. 2020; 8(2): e191-e203.
2. Sung H, Ferlay J, Siegel RL, Laversanne M, Soerjomataram I, Jemal A, et al. Global Cancer Statistics 2020: GLOBOCAN Estimates of Incidence and Mortality Worldwide for 36 Cancers in 185 Countries. CA. Cancer J Clin. 2021; 71(3): 209–249.
3. Borcoman E, Le Tourneau C. Pembrolizumab in cervical cancer: latest evidence and clinical usefulness. Ther Adv Med Oncol. 2017; 9(6): 431–439.
4. Corrigendum to "Revised FIGO staging for carcinoma of the cervix uteri" [Int J Gynecol Obstet 145(2019) 129–135]. Int J Gynaecol Obstet. 2019; 147(2): 279–280.
5. Buchwald C, Franzmann MB, Tos M. Sinonasal papillomas:a report of 82 cases in Copenhagen Country, including alongitudinal epidemiological and clinical study. Laryngoscope.1995; 105(1): 72–79
6. Thompson LDR, Franchi A. New tumor entities in the 4th edition of the World Health Organization classification of head and neck tumors: Nasal cavity, paranasal sinuses and skull base. Virchows Arch. 2018; 472(3): 315–330.
7. Strojan P, Ferlito A, Lund VJ, Kennedy DW, Silver CE, Rinaldo A, et al. Sinonasal inverted papilloma associated with malignancy: The role of human papillomavirus infection and its implications for radiotherapy. Oral Oncol. 2012; 48(3): 216–218.
8. Lawson W, Ho BT, Shaari CM, Biller HF. Inverted papilloma: A report of 112 cases. Laryngoscope. 1995; 105(3 Pt 1): 282–288.
9. Sbrana MF, Borges RFR, Pinna FR, Neto DB, Voegels RL. Sinonasal inverted papilloma: rate of recurrence and malignant transformation in 44 operated patients. Braz J Otorhinolaryngol. 2019; 87(1): 80–84.
10. Nudell J, Chiosea S, Thompson LD. Carcinoma Ex-Schneiderian Papilloma (Malignant Transformation): A Clinicopathologic and Immunophenotypic Study of 20 Cases Combined with a Comprehensive Review of the Literature. Head Neck Pathol. 2014; 8(3): 269–286.

11. Maroldi R, Farina D, Palvarini L, Lombardi D, Tomenzoli D, Nicolai P. Magnetic Resonance Imaging Findings of Inverted Papilloma: Differential Diagnosis with Malignant Sinonasal Tumors. Am J Rhinol Allergy 2004; 18(5): 305–310.
12. Schneider SS, Schick C, Fish KE, Miller E, Pena JC, Treter SD, et al. A Serine Proteinase Inhibitor Locus at 18q21.3 Contains a Tandem Duplication of the Human Squamous Cell Carcinoma Antigen Gene. Proc Natl Acad Sci USA. 1995; 92(8): 3147–3151.
13. Kato H, Torigoe T. Radioimmunoassay for tumor antigen of human cervical squamous cell carcinoma. Cancer. 1977; 40(4): 1621–1628.
14. Yang D, Wang J, Zhang L. Serum SCCA levels in patients suffering cancers or other diseases. Prog Mol Biol Transl Sci. 2019; 162: 165–175.
15. Ward N. A mirror of the practice of medicine and surgery in the hospitals of London: London hospital. Lancet. 1854; 64(1632): 480–482.
16. Deitmer T, Wiener C. Is there an Occupational Etiology of Inverted Papilloma of the Nose and Sinuses?. Acta Otolaryngol. 1996; 116(5): 762–765.
17. Barnes L, Bedetti C. Oncocytic schneiderian papilloma: A reappraisal of cylindrical cell papilloma of the sinonasal tract. Hum Pathol. 1984; 15(4): 344–351.
18. Anari S, Carrie S. Sinonasal inverted papilloma: narrative review. J Laryngol Otol. 2010; 124(7): 705–715.
19. Goudakos JK, Blioskas S, Nikolaou A, Vlachtsis K, Karkos P, Markou KD. Endoscopic Resection of Sinonasal Inverted Papillomas: Systematic Review and Meta-Analysis. Am J Rhinol Allergy. 2018; 32(3): 167–174.
20. Krouse JH. Development of a staging system for inverted papilloma. Laryngoscope. 2000; 110: 965–968.
21. Cannady SB, Batra PS, Sautter NB, Roh HJ, Citardi MJ. New staging system for sinonasal inverted papilloma in the endoscopic era. Laryngoscope. 2007; 117: 1283–1287.
22. Minni A, Gera R, Bulgheroni C, Ralli M, Cialente F, Candelori F, et al. Endoscopic resection of sinonasal inverted papilloma: a multivariate retrospective analysis of factors affecting recurrence and persistence. Ear Nose Throat J. 2021; 100: 542S-548S.
23. Yasumatsu R, Nakashima T, Kuratomi Y, Hirakawa N, Azuma K, Tomita K, et al. Serum squamous cell carcinoma antigen is a useful biologic marker in patients with inverted papillomas of the sinonasal tract. Cancer. 2002; 94(1): 152–158.
24. Yasumatsu R, Nakashima T, Masuda M, Kuratomi Y, Shiratsuchi H, Hirakawa N, et al. Clinical value of serum squamous cell carcinoma antigen in the management of sinonasal inverted papilloma. Head neck 2005; 27(1): 44–48.
25. Suzuki M, Deng Z, Hasegawa M, Uehara T, Kiyuna A, Maeda H. Squamous Cell Carcinoma Antigen Production in Nasal Inverted Papilloma. Am J Rhinol Allergy.2012; 26(5): 365–370.

26. Matoušek P, Zeleník K, Safarčík K, Cábalová L, Komínek P. Squamous cell carcinoma antigen as a marker of sinonasal inverted papilloma. Eur. Arch. Otorhinolaryngol. 2014; 271(3): 535–538.
27. Yamashita Y, Uehara T, Hasegawa M, Deng Z, Matayoshi S, Kiyuna A, et al. Squamous cell carcinoma antigen as a diagnostic marker of nasal inverted papilloma. Am J Rhinol Allergy. 2016; 30(2): 122–127.
28. van Zijl FVWJ, Monserez DA, Korevaar TIM, Bugter O, Wieringa MH, Baatenburg de Jong RJ, et al. Postoperative value of serum squamous cell carcinoma antigen as a predictor of recurrence in sinonasal inverted papilloma. Clin Otolaryngol. 2017; 42(3): 528–535.
29. Yasumatsu R, Nakano T, Sato M, Jiroumaru R, Hashimoto K, Kogo R, et al. Combination of serum squamous cell carcinoma antigens 1 and 2 as potential diagnostic marker for sinonasal squamous cell carcinoma and inverted papilloma. Head neck. 2018; 40(12): 2583–2589.
30. Hsu KF, Huang SC, Shiau AL, Cheng YM, Shen MR, Chen YF, et al. Increased expression level of squamous cell carcinoma antigen 2 and 1 ratio is associated with poor prognosis in early-stage uterine cervical cancer. Int J Gynecol Cancer. 2007; 17(1): 174–181.
31. Gheit T. Mucosal and Cutaneous Human Papillomavirus Infections and Cancer Biology. Front Oncol. 2019; 9: 355.
32. de Martel C, Plummer M, Vignat J, Franceschi S. Worldwide burden of cancer attributable to HPV by site, country and HPV type. Int J Cancer. 2017; 141(4): 664–670.
33. Gupta R, Rady PL, Sikora AG, Tyring SK. The role of human papillomavirus in the pathogenesis of sinonasal inverted papilloma: a narrative review. Rev Med Virol. 2021; 31(3): e2178.
34. Pähler Vor der Holte A, Fangk I, Glombitza S, Wilkens L, Welkoborsky HJ. Prognostic factors and risk factors for development and recurrence of sinonasal papillomas: potential role of different HPV subtypes. Eur Arch Otorhinolaryngol. 2020; 277(3): 767–775.
35. Sánchez-Vargas LO, Díaz-Hernández C, Martinez-Martinez A. Detection of human papilloma virus (HPV) in oral mucosa of women with cervical lesions and their relation to oral sex practices. Infect Agent Cancer. 2010; 5: 25.

Figures

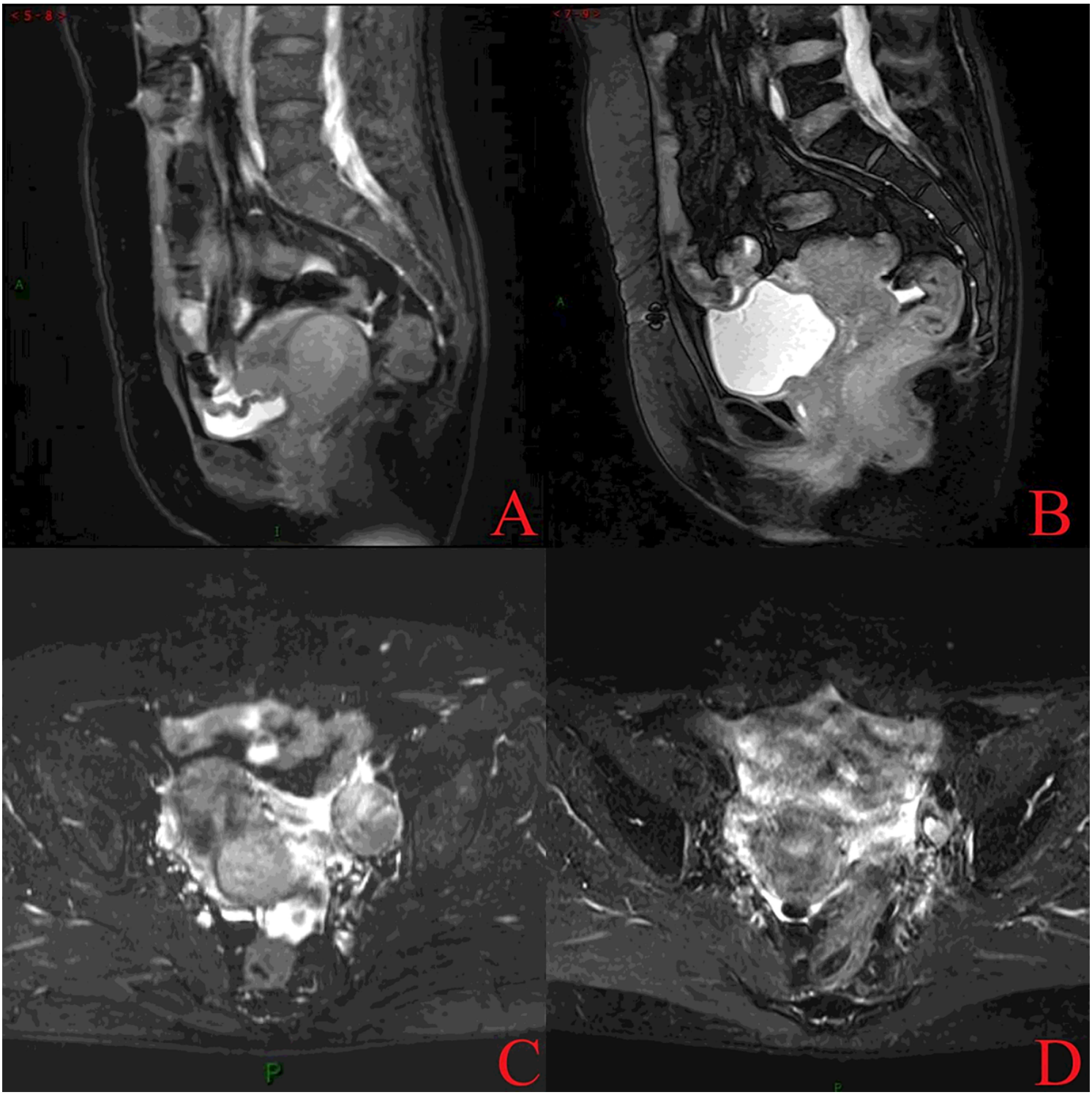

Figure 1

MRI imaging, 1A and 1C showed the cervical lesion and the left pelvic wall metastatic lymph node before treatment, respectively; 1B and 1D showed the cervical and the left pelvic wall lymph node after treatment, respectively

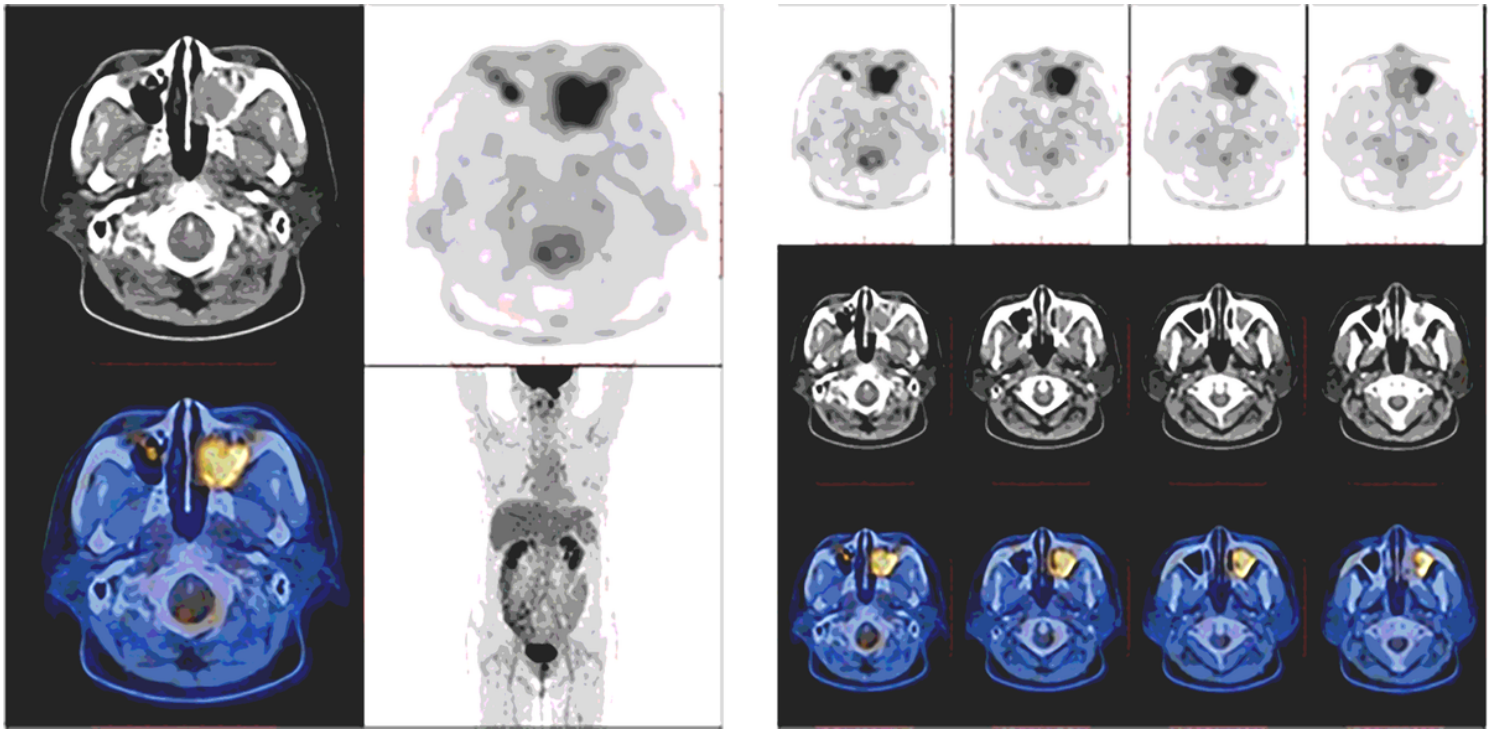

Figure 2

PET/CT image of the soft tissue shadow with increased SUV in the left maxillary sinus

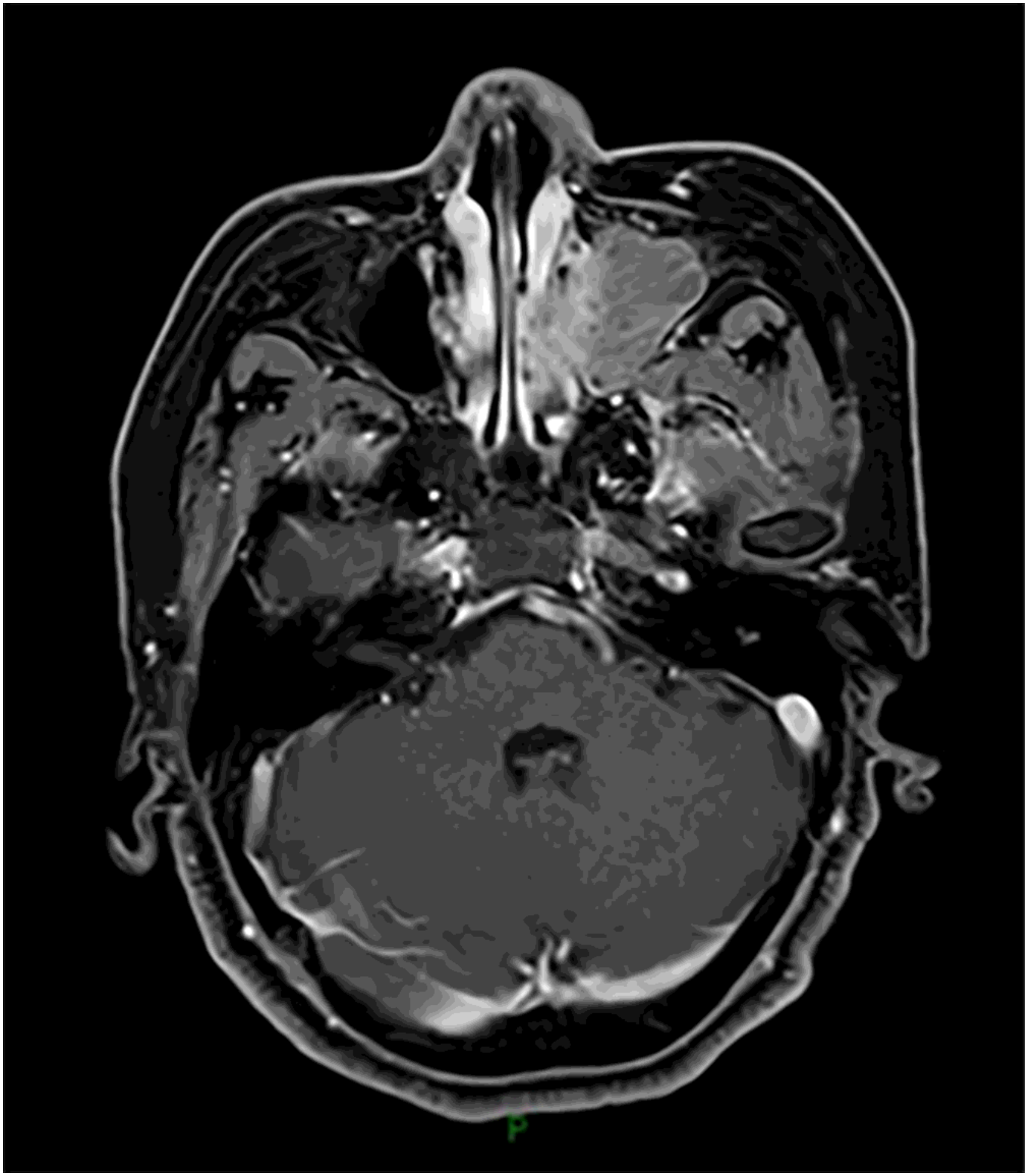

Figure 3

MRI imaging, before the first sinus tumor resection

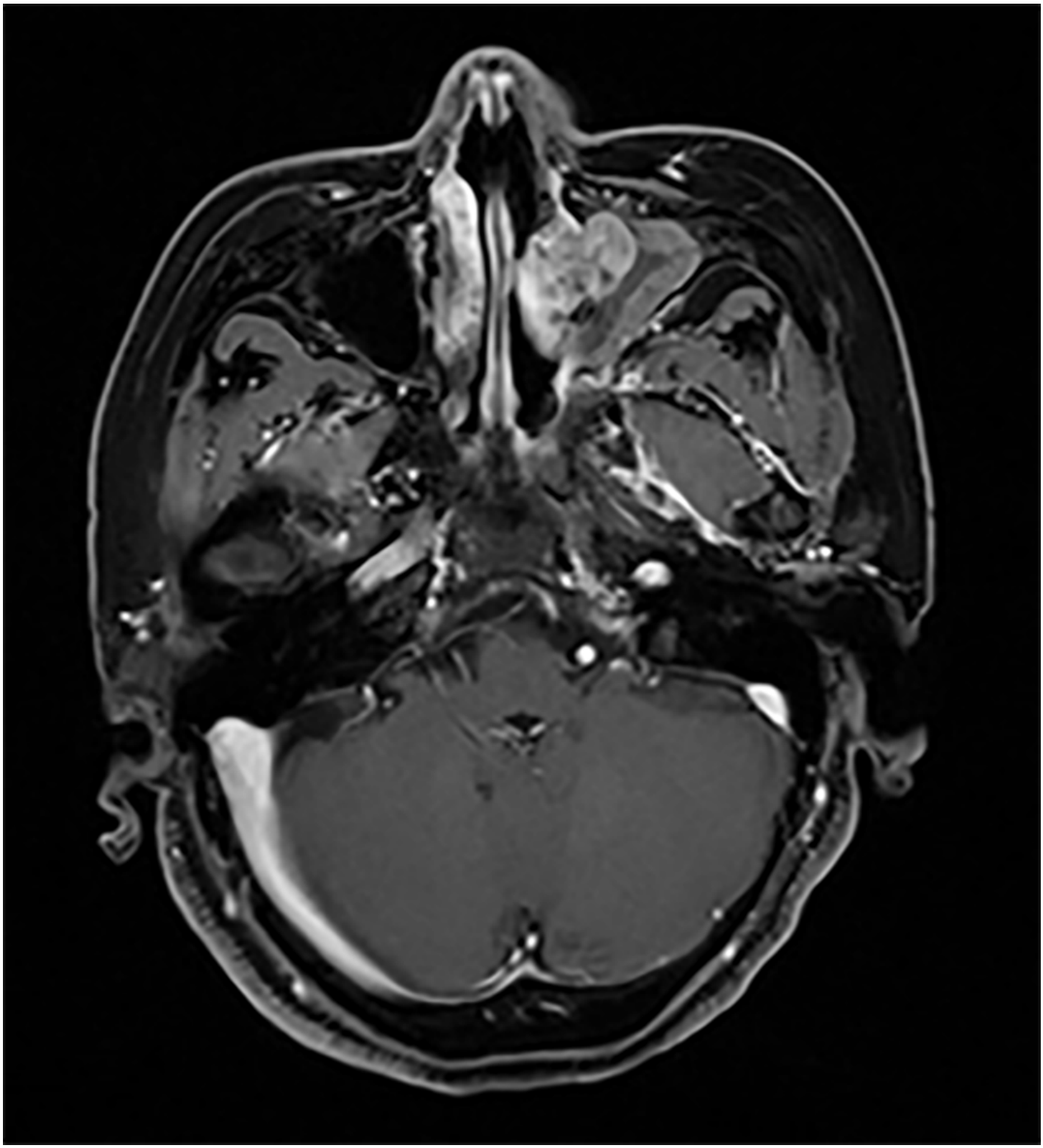

Figure 4

MRI imaging, before the second sinus tumor resection

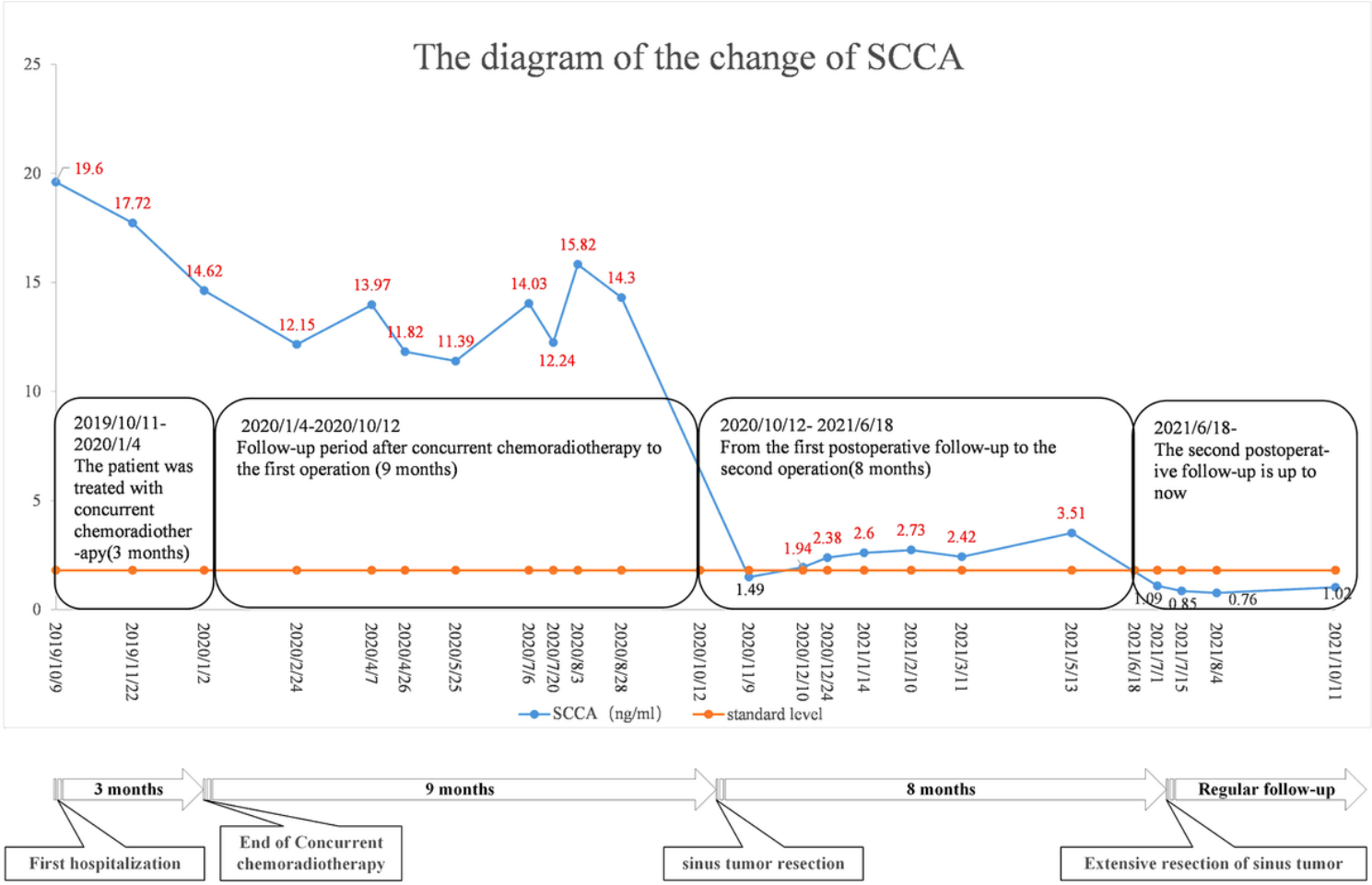

Figure 5

The changes, treatment and timeline of SCCA throughout the course of the disease.