

Individualized Strategy of Minimally Invasive Cardiac Surgery in Congenital Cardiac Septal Defects

Jiaquan Zhu (✉ dr_zhujq@126.com)

Shanghai Jiaotong University School of Medicine Xinhua Hospital <https://orcid.org/0000-0002-9250-4366>

Yunjiao Zhang

Shanghai Jiaotong University School of Medicine Xinhua Hospital

Chunrong Bao

Shanghai Jiaotong University School of Medicine Xinhua Hospital

Fangbao Ding

Shanghai Jiaotong University School of Medicine Xinhua Hospital

Ju Mei

Shanghai Jiaotong University School of Medicine Xinhua Hospital

Research article

Keywords: Congenital heart disease, minimally invasive cardiac surgery, intracardiac septal defect

Posted Date: January 15th, 2021

DOI: <https://doi.org/10.21203/rs.3.rs-145169/v1>

License:  This work is licensed under a Creative Commons Attribution 4.0 International License.

[Read Full License](#)

Version of Record: A version of this preprint was published at Journal of Cardiothoracic Surgery on January 15th, 2022. See the published version at <https://doi.org/10.1186/s13019-022-01753-6>.

Abstract

Background: Intracardiac septal defect tends to be repaired by minimally invasive surgery in both children and adults. This study summarized our strategy of minimally invasive therapy using various lateral mini-thoracotomies in patients with congenital septal defect.

Methods: Four hundred and seventy-two patients who underwent minimally invasive repair of intracardiac septal defects (Atrial septal defect, ASD; ventricular septal defect, VSD; atrioventricular septal defect, AVSD) between January 2012 and June 2020 were retrospectively reviewed. Those who underwent device closure were excluded. The minimally invasive strategy included three groups. First, right sub-axillary vertical incision group (RSAVI group, N=335, 192 ASDs, 135 VSDs and 8 AVSDs; Second, right anterolateral thoracotomy group (RALT group, N=132, 77 ASDs, 51 VSDs and 4 AVSDs; Third, left anterolateral thoracotomy group (LALT group, N=5, all of them were sub-pulmonary VSDs).

Results: Concomitant surgeries included 9 cases of right ventricular outflow tract obstruction relief, 9 mitral repairs and 37 tricuspid repairs. There was one transition from thoracotomy to sternotomy. Three patients required second pump run for residual lesions (2 residual shunts and 1 mitral regurgitation). The age and body weight of RSAVI group were significantly lower than those of RALT and LALT groups. The mean cardiopulmonary bypass time was 67.3 ± 11.3 min and cross clamp time was 38.1 ± 8.9 min. There was no post-operative death, and complications included 1 chest exploration for bleeding, 1 redo operation due to patch dehiscence during the same admission, 1 transient neural dysfunction, 3 diaphragmatic paresis and 13 atelectasis. The median stay in ICU was 2 days, while the median post-operative hospitalization was 6 days. The echocardiography results before discharge indicated no significant residual lesions. There was no reoperation, no new onset of chest deformities and no sclerosis during the follow up.

Conclusions: The commonly seen intracardiac septal defects can be safely and effectively repaired by minimally invasive surgery with good cosmetic results. Right sub-axillary vertical incision is suitable in infants and young children, while right anterior mini-thoracotomy is more commonly used in adolescents and adults. Left anterior mini-thoracotomy is an alternative incision to repair sub-pulmonary artery VSD.

Background

Congenital cardiac septal defects include atrial septal defect (ASD), ventricular septal defect (VSD), atrioventricular septal defect (AVSD) and their combinations. They contribute to half of the congenital heart diseases. Surgical repair of such defects from median sternotomy was developed several decades ago, and widely used as a standard approach in many cardiac centers. The surgical results improved a lot, and the mortality is approaching to zero in the current era. However, the median scar on the chest reminds the patient the surgical history along the whole life, and even leads to emotional issues and psychological diseases. In 1990s, device closure of ASD or VSD via either percutaneous or from mini-thoracotomy was successfully applied in appropriate candidates, and the advantages include less

trauma, fast post-operative recovery, and cosmetic effects.(1, 2) Nevertheless, a number of patients with ASD or VSD cannot be treated by device closure because of inappropriate anatomic features of the septal defects. These patients still require surgical repair with cardiopulmonary bypass.

Minimally invasive cardiac surgery (MICS) becomes very popular in adult heart surgery in recent years, and the principle is to minimize trauma with maintenance of equivalent safety and efficacy. Multiple heart centers reported their experiences of MICS in pediatric and adult congenital heart surgery worldwide. These techniques include repair from anterior-lateral right mini-thoracotomy, right oblique sub-axillary incision, right vertical sub-axillary incision, right posterior mini-thoracotomy, and partial sternotomy et al. (3–12) These different techniques not only had their own advantages, but also had several limitations. Right sub-axillary vertical incision was widely used; however, it can't provide sufficient exposure in sub-pulmonary VSD, and it was not convenient in adolescent and adult patients. In our institution, individualized MICS was used in repairing congenital heart defects based on anatomic features and patients' characteristics. Hereby, the experience of last ten years were summarized.

Methods

Patients selection

This study was approved by our institutional ethic committee, and the consents from the patients were waived. Patients who underwent cardiac septal defects repair between January 2012 and June 2020 in Shanghai Xinhua Hospital were retrospectively reviewed. Patients were screened for their surgical techniques. Those who underwent minimally invasive repair with cardiopulmonary bypass were included for analysis, while those who underwent repair through sternotomy were excluded. Patients who underwent device closure either percutaneously or per mini-thoracotomy were excluded too. The approaches of minimally invasive surgery include three kinds of incisions. Group 1 used right sub-axillary vertical incision (RSAVI group, N = 335), group 2 used right anterolateral thoracotomy (RALT group, N = 132), while group 3 used left anterolateral thoracotomy (LALT group, N = 5).

Surgical techniques

RSAVI group

This technique was mainly used in infants and some young children. The techniques are similar to previously reported methods(13). Patient was intubated with single lumen tube after general anesthesia. Patient was placed laterally with right side up. The right arm was placed cranially and sometime suspended on the head brace. A vertical incision around 4 cm was made across the fourth intercostal space. The subcutaneous tissue was dissected with caution to protect long thoracic nerve and its associated blood vessels. The chest was entered through the 4th intercostal space. A rigid or soft tissue spreader was placed to gain better exposure. A wet sponge was used to protect the right lung while retracting. Right half thymus was resected. A longitudinal pericardial incision was opened about 1.5 cm anterior to right phrenic nerve, and several retraction stitches were placed to help exposing the heart. After

heparinization, the aortic and bicaval cannulations were placed through the incision. Sometime, an additional 1 cm incision was made in the sixth intercostal space, and we pull out the IVC cannulation from this hole, which was used to place a chest tube at the end of operation (Fig. 1). A cardioplegia needle was placed at the aortic root. After aortic cross clamp was placed, Del Nido cardioplegia was given and the heart was arrested. Right atrium was open, and the intracardiac defects were repaired thereafter. The repair technique is almost the same as that from sternotomy. In some cases, especially in VSD patients, the distance from the incision to the defect was too deep to expose the defect well. A wet ice-cold sponge was placed behind the heart in the pericardial cavity, so that the heart was elevated and closer to the surgeon.

RALT group

This technique was mainly applied in elder children, adolescents and adults. Patient was placed in supine position, then the right side was elevated about 30 degrees. Patient was intubated with double-lumen tube. A right anterolateral small incision was made at the fourth intercostal space. In female patients, this incision was lower at the margin of breast tissue. The chest cavity was entered through the fourth intercostal space. In our early experience, a rigid spreader was inserted to expose the heart. The pericardium was opened at 2 cm anterior to the right phrenic nerve. A vertical right groin incision was made, then the femoral artery and femoral vein were mobilized for peripheral cannulation to establish cardiopulmonary bypass. In our earlier series, the SVC canula and cardioplegia needle were placed through the incision, and the aorta was cross clamped, then the intracardiac defects were repaired. In recent years, modifications were made to further minimize the injury. The incision was made less than 5 centimeters. A soft tissue retractor was used, and rigid retractor was abandoned. Thoracoscopy was used for better exposure despite the smaller incision (Fig. 2). The SVC cannula was placed through the internal jugular vein by Seldling technique. A Chitwood aortic cross clamp was placed through the fourth or third intercostal space. Therefore, the incision was spared for defect repair only.

LALT group

This approach was indicated in repair of sub-pulmonary VSD. Patient was put in supine position with single lumen intubation. A horizontal incision parallel to the second intercostal space was made. The left internal mammary artery was kept intact as much as possible. Peripheral cardiopulmonary bypass was established by femoral cannulations of both artery and vein. The venous cannulation was advanced into right atrium to obtain better drainage. The aorta was mobilized through the incision, then a cardioplegia needle was placed at the aortic root. The aorta was cross clamped, and the pulmonary artery was opened around 1 cm superior to the pulmonary annulus (Fig. 3). The VSD was exposed and repaired with the same technique from sternotomy. Usually, SVC cannula was not required because of adequate drainage; however, additional SVC cannula from the incision is also feasible if needed.

Data collection and statistical analysis

Perioperative and follow-up data were collected, and statistical analysis were performed by STATA 14.0. Categorical variables were expressed as frequencies and percentages, and were compared between the two groups using χ^2 test or Fisher exact test. Continuous variables were presented as means \pm standard deviations. Comparisons between each two groups used Student t-test or Mann-Whitney U test as appropriate. STATA 14.0 software (STATA Corporation, College Station, TX) was used for statistical analyses. A two-tailed P-value < 0.05 was considered statistically significant.

Results

The preoperative data were summarized in Table 1. This study included 472 patients, and 52.1% were male. In term of the primary diagnosis, RSAVI group had 335 patients, which contained 192 cases of ASD, 135 cases of VSD, and 8 cases of AVSD. There were 132 patients in RALT group, and this group contained 77 ASDs, 51 VSDs, and 4 AVSDs. There were 5 patients in LALT group, and all of them were sub-pulmonary VSDs. The mean age in RSAVI group was 2.4 ± 0.9 years, and the mean weight was 12.4 ± 2.5 kg. Both of these two characteristics were significantly lower than those in RALT group (Age: 17.5 ± 4.8 years, weight 54.5 ± 14.9 kg) and LALT group (Age 15.1 ± 3.8 years, weight 42.1 ± 12.5 kg).

Table 1
Preoperative data

Characteristics	RSAVI group(N = 335)	RALT group(N = 132)	LALT group(N = 5)
Age (years)	2.4 ± 0.9	$17.5 \pm 4.8^*$	$15.1 \pm 3.8^*$
Weight (kg)	12.4 ± 2.5	$54.8 \pm 14.9^*$	$42.1 \pm 12.5^*$
Male	172 (51.3%)	71 (53.8%)	3 (60%)
Primary diagnosis			
ASD	192 (57.3%)	77 (58.3%)	0
VSD	135 (40.3%)	51 (38.6%)	5(100%)
AVSD	8 (2.4%)	4 (3.0%)	0
RSAVI, right sub-axillary vertical incision; RALT, right anterolateral thoracotomy; LALT, left anterolateral thoracotomy; ASD,atrial septal defect;VSD□ventricular septal defect□AVSD□atrioventricular septal defect□NS□non-significant. *: P < 0.05 when compared to RSAVI group.			

All the patients underwent the minimally invasively surgeries uneventfully. There was one transition to median sternotomy. This was a 6-year-old child who had ASD repair via right sub-axillary vertical incision; however, after the chest was closed, this patient had increased central venous pressure and the hemodynamics was unstable. The decision was to reopen from median sternotomy and fenestrate the ASD patch. This patient recovered well. The intraoperative data and postoperative recovery were summarized in Table 2. Concomitant procedures other than intracardiac defect repair included relief of right ventricular outflow tract obstruction in 9 cases, mitral valve repair in 9 cases, and tricuspid valve

repair in 37 patients. There were 3 patients required second round of cardiopulmonary bypass to repair residual lesions according to intraoperative trans esophageal echocardiography findings (2 residual VSDs, and 1 residual mitral regurgitation). The average cardiopulmonary bypass time was 67.3 ± 11.3 minutes, and the cross clamp time was 38.1 ± 8.9 minutes. RSAVI group had slightly shorter bypass time and clamp time when compared to RALT group. There was no early and late death. Perioperative complications included postoperative chest exploration for bleeding in one patient within RALT group, one redo operation due to patch dehiscence 6 days after initial ASD repair in RSAVI group. One patient experienced temporary neural system dysfunction, and 3 patients had phrenic nerve paralysis; however, all of them recovered later. In addition, 13 patients had pulmonary atelectasis, and they recovered before discharge. The majority patients were extubated on the operative day (462 patients, 97.9%). The median stay in ICU was 2 days, and the median stay in the hospital was 6 days. The echocardiography before discharge indicates 5 trivial residual intracardiac shunts which disappeared during the follow up, 12 less than mild left or right atrioventricular valve regurgitation. No third-degree atrioventricular block was found, and no patient required re-intervention during the follow-up. No new onset of apparent deformity of chest wall or scoliosis was found. All the patients had NYHA I heart function.

Table 2
operative data and postoperative recovery

Characteristics	RSAVI group(N = 335)	RALT group(N = 132)	LALT group(N = 5)
ACC time(min)	35.8 ± 7.5	40.1 ± 10.2*	38.9 ± 8.6
CPB time(min)	64.9 ± 10.2	71.2 ± 12.3*	63.1 ± 10.2
Operations			
Isolated ASD repair	187 (55.8%)	60 (45.5%)	0
ASD + MVP	1 (0.3%)	2 (1.5%)	0
ASD + TVP	2 (0.6%)	15 (11.4%)	0
ASD + RVOTO repair	2 (0.6%)	0	0
Isolated VSD closure by interrupted stitches	60 (17.9%)	23 (17.4%)	3 (60.0%)
Isolated VSD patch closure	55 (16.4%)	15 (11.4%)	2 (40.0%)
VSD repair + MVP	2 (0.6%)	4 (3.0%)	0
VSD repair + TVP	13 (3.9%)	7 (5.3%)	0
VSD repair + RVOTO repair	5 (1.5%)	2 (1.5%)	0
AVSD	8 (2.4%)	4 (3.0%)	0
Postoperative intubation hours	5.9 ± 2.9	8.6 ± 4.3*	3.6 ± 1.9#
Postoperative ICU days	2.0 ± 1.1	1.9 ± 1.0	2.0 ± 0.8
Postoperative chest drainage(ml/kg)	7.4 ± 2.1	6.7 ± 2.1*	6.3 ± 1.8
Postoperative hospitalization days	6.0 ± 1.4	6.5 ± 1.2*	5.9 ± 1.1
RSAVI, right sub-axillary vertical incision; RALT, right anterolateral thoracotomy; LALT, left anterolateral thoracotomy; ASD,atrial septal defect;MVP, mitral valve repair; TVP, tricuspid valve repair; RVOTO, right ventricular outflow tract obstruction; VSD□ventricular septal defect□AVSD□atrioventricular septal defect□NS□non-significant. *: P < 0.05 when compared to RSAVI group. #: P < 0.05 when compared to RALT group.			

Discussion

Conventional full sternotomy in cardiac surgery had the disadvantages of long incision, bleeding and potential mediastinitis. Despite partial sternotomy shortens the incision, the sternal stability is damaged and it requires several months to recover back to normal life after the surgery. In the recent two decades, various minimally invasive techniques were applied in congenital cardiac surgery.(14) Liu et al from

Fuwai Hospital(3) reported their experience of oblique lateral thoracotomy in 683 children with congenital heart disease. The ages ranged from 4 months to 7 years, and the main diseases in this series are ASD and VSD. A few TOF patients were also operated by this incision. However, the length of this incision was relatively long, and the incision was close to mammary tissue. Bleiziffer et al. followed 72 female patients who underwent heart surgery from right anterolateral thoracotomy in their puberties, and the authors found that 61% patients developed asymmetric breasts in adult ages, therefore, the authors recommended not to use such incision in adolescent females. However, these surgeries were performed in 1980s, and the minimally invasive techniques were immature at that time, the length of incision was up to 19.2 centimeter(15). To avoid such complications, this group modified their techniques, and reported their results at 2005. The incision was at mid-axillary level and the length was around 4.5-6 cm. Thirty-six children with isolated ASDs were included in this study, and the outcomes were excellent. The youngest patient in this study was 4 years old (5) Pretre et al from Switzerland reported their experience of using right posterolateral thoracotomy in 80 patients with simple congenital heart disease (4). In the majority of this group, femoral arterial and venous cannulation were used (87.5%). The mid-term follow-up results were good(16). In recent years, several heart centers from China reported various modified minimally invasive methods to operate on simple congenital heart diseases. The most commonly used incision was right sub axillary incision. The incision was modified from oblique shape to vertical direction, and the length of the incision was also shortened. The indications of such minimally invasive surgeries were expanded, and there was a trend of using soft tissue retractor instead of rigid spreader.(13, 17, 18) (9). The safety and efficacy of such strategies were validated, and the outcomes of minimally invasive cardiac surgery in children was not inferior to conventional heart surgery.

The indication of minimally invasive surgery and the choice of incision in children was not yet consistent. The indication in early era was simple ASDs, because the defect was close to the incision, and the exposure usually was very good, so it was easy to repair the defect. However, in patients with VSDs, the surgical exposure was not as good as that in ASD patients, because the VSD was deep and blocked by tricuspid tissues sometime. With the advancement of instruments and techniques in minimally invasive surgery, the indication was expanded in recent years. Anzhen Hospital recently reported a group of infants less than 5 kilograms operated via right sub axillary incision, and the outcomes were the same as those operated from median sternotomy(19). In addition, CAVSD infants were also reported repaired from lateral mini-thoracotomy (9).

An uneventful establishment of cardiopulmonary bypass is the foundation to perform minimally invasive cardiac surgery. The diameters of femoral vessels in infants are too small, and femoral cannulation may lead to high incidence of vascular complications, thus central cannulation is preferred in such patients. The right sub axillary incision can expose ascending aorta, superior vena cava and inferior vena cava very well in most patients. The arterial cannulation site is usually very deep, and aortic cannulation is the most difficult step in most patients. From literature, some authors used forceps to grab the tip of the curve arterial cannula and this facilitate the cannulation; however, it is not easy to master this technique, especially when surgical exposure is not well. We used a straight arterial cannula with a rigid inner cylinder, and put it inside through the arterial incision. The keys of this step are to open the adventitia

within the aortic purse string as much as possible, and to rotate the cannula back and forth slightly if we feel resistance. In some elder patients with deep thoracic cavity and small incision, the aorta is punctured by a needle, and a guiding wire is inserted, therefore, arterial cannula is placed by Seldinger technique. The SVC and IVC canulae can be either curved or straight, and we prefer the canula with thin-walled-wire-reinforcement, which is flexible to be positioned.

The key point to ensure precise repair is well surgical exposure, especially when the infra-axillary incision is tiny. To obtain better surgical exposure, recently, Heinisch et al. reported percutaneous cannulation of IVC in 38 pediatric patients, but 13.5% cases had thrombosis at cannulation site.(20) In our infants operated from right sub axillary incision, the IVC cannula can be placed through the sixth intercostal space, and this puncture site can be used to place chest tube at the end of surgery. After cardioplegia is given, the cardioplegia needle and tube are removed, since most simple cardiac defect can be repaired within the protection time of a single dose of cardioplegia. In some patients with VSD, an ice cold saline rinsed gauze is placed behind the heart in the pericardial cavity, and this helps to push the heart close to the incision; with appropriate retraction, the VSD can be exposed well. In case of unrestrictive VSD, patch closure with interrupted stitches is preferred.

However, we found that the infra-axillary incision is convenient in infants and young children, but it is limited in adolescents and adults, since the incision is too far away from the heart. Therefore, we used right anterolateral thoracotomy in such groups of patients. In this study, the mean age and body weight of RALT group is significantly higher than those of RSAVI group. The RALT incision from the fourth intercostal space is close to the heart, and the surgical view is similar to the view from sternotomy. Peripheral cardiopulmonary bypass established by femoral cannulations helps to obtain better exposure from the mini-thoracotomy. In recent years, the SVC cannula was placed through the right jugular vein, and Chitwood aortic cross clamp was used. In addition, thoracoscopy assistance and soft tissue retractor also help us to reduce the incision to as short as 4 cm in length. To be noticed, the skin incision should be at the lower margin of the breast tissue in adult females, and the incision should be far away from the mammary tissue in prepubescent female children.

The above-mentioned two incisions expose ASD and perimembranous VSD well enough to repair; however, it is difficult to expose sub pulmonary VSD. A few heart centers reported their experience of repair doubly committed sub arterial VSD using sub axillary incision. The VSD was repaired either through tricuspid valve or through main pulmonary artery, but the number of such patients are very limited, and the surgeons are very experienced in this field, so the reproducibility is not easy(13, 18). In this study, one infant with sub pulmonary artery VSD underwent repair from right sub axially incision, and the exposure was not good enough for a precise repair. Intraoperative transesophageal echocardiography demonstrated residual VSD, and a second cross clamp was applied to repair the residual defect. After this case, we preferred median sternotomy in infants with sub pulmonary artery VSD. While in adolescents and adults with sub pulmonary artery VSD, a left anterolateral mini-thoracotomy from the second intercostal space was used. In the present study, we reported our preliminary experience in 5 cases. Femoral arterial and venous cannulations were used, and achieved adequate drainage. SVC cannulation

is not necessary in most patients, but SVC cannulation is possible through the incision if needed after patient is on bypass. In 2017, authors from China reported this approach to repair sub-pulmonary artery VSD, but it was only used in adults, not in children(21). In 2019, authors from Guangzhou reported an alternative method using minimal mid-partial sternotomy in 13 patients (22). Minimally invasive periventricular closure of doubly committed subarterial VSD was also reported, but this technique lacks of long term follow-up results(2). In our opinion, surgical closure from LALT is preferred in such patient groups. Recently, this LALT incision was also applied to replace pulmonary valve in 7 patients following Tetralogy of Fallot repair by Nellis et al.(23)

The lower weight limit of femoral cannulation is inconsistent. Most surgeons prefer using peripheral cannulation in patients over 30 kg; however, surgeons from Switzerland dissected iliac artery in infants with body weight as low as 10 kg.(16) The reported lowest body surface area using a femoral venous cannulation was around 0.3 square meters, however, the patency of the femoral vein was compromised in 13.5% patients.(20) The cutoff body weight is 20 kg in our institution, and preoperative femoral vessels were evaluated by ultrasound to determine the possibility of femoral cannulation.

This study is limited by its retrospective nature in a single institution, and no comparison was done between minimally invasive approach and sternotomy. Score of pain was not evaluated in these patients, and the follow-up time was relative short. The minimally invasive approaches reported here is not suitable for all congenital heart disease, especially in complicated disease. In infants less than 6 months old, we still prefer median sternotomy due to fragile heart and lung tissues in young infants, while a few centers summarized their experience in such patients.(19, 20) In low body weight patients with doubly committed sub arterial VSD, we also prefer median sternotomy, and finally, if the patient has prior thoracic surgery or has significant adherence in thoracic cavity, sternotomy is preferred too.

Conclusions

In conclusion, minimally invasive cardiac surgery is safe and effective in congenital septal defects. Sub axially incision is suitable in infants and young children, while right anterolateral incision is suitable in adolescents and adults. Left anterolateral incision is feasible to repair sub pulmonary artery VSD in patients over 20 kg. Femoral cannulation is the basis of minimally invasive surgery in adolescents and adults. Jugular venous cannulation and thoracoscopy assistance can improve surgical exposure and minimize the length of incision. Application of soft tissue retractor can reduce tissue injury, thus facilitate post-operative recovery. Appropriate preoperative evaluation and surgical strategy obtain both cosmetic and therapeutic effects.

Abbreviations

RSAVI, right sub-axillary vertical incision; RALT, right anterolateral thoracotomy; LALT, left anterolateral thoracotomy; ASD,atrial septal defect;VSD□ventricular septal defect□AVSD□atrioventricular septal defect.

Declarations

Ethics approval and consent to participate

This study was approved by our institutional ethic committee, and the consents from the patients were waived.

Consent for publication

Not applicable.

Availability of data and materials

The dataset generated and/or analyzed during the current study are available from the corresponding author upon reasonable request.

Competing interests

None.

Funding

This study is supported by National Natural Science Foundation of China (81600219).

Authors' contributions

JZ collected the data, analyzed the data and wrote the manuscript. YZ and CB revised the manuscript. CB, FD, and JM performed the surgeries and supervised the study. All authors read and approved the final manuscript.

Acknowledgement

We thank Dr. Zhongdong Hua from Fuwai Hospital for his expertise helping us minimize the incision.

References

1. Mylonas KS, Ziogas IA, Evangeliou A, Hemmati P, Schizas D, Sfyridis PG, et al. Minimally Invasive Surgery vs Device Closure for Atrial Septal Defects: A Systematic Review and Meta-analysis. *Pediatr Cardiol.* 2020;41(5):853–61.

2. Liu H, Lu FX, Zhou J, Yan F, Qian SC, Li XY, et al. Minimally invasive periventricular versus open surgical ventricular septal defect closure in infants and children: a randomised clinical trial. *Heart*. 2018;104(24):2035–43.
3. Liu YL, Zhang HJ, Sun HS, Li SJ, Yan J, Su JW, et al. Repair of cardiac defects through a shorter right lateral thoracotomy in children. *Ann Thorac Surg*. 2000;70(3):738–41.
4. Pretre R, Kadner A, Dave H, Dodge-Khatami A, Bettex D, Berger F. Right axillary incision: a cosmetically superior approach to repair a wide range of congenital cardiac defects. *J Thorac Cardiovasc Surg*. 2005;130(2):277–81.
5. Schreiber C, Bleiziffer S, Kostolny M, Horer J, Eicken A, Holper K, et al. Minimally invasive midaxillary muscle sparing thoracotomy for atrial septal defect closure in prepubescent patients. *Ann Thorac Surg*. 2005;80(2):673–6.
6. Hu C-X, Tan J, Chen S, Ding H, Xu Z-W. Comparison of clinical outcomes and postoperative recovery between two open heart surgeries: minimally invasive right subaxillary vertical thoracotomy and traditional median sternotomy. *Asian Pac J Trop Med*. 2014;7(8):625–9.
7. Zhang X, Xing Q, Wu Q. Treatment of Perimembranous Ventricular Septal Defect in Children Weighing Less than 15 kg: Minimally Invasive Periventricular Device Occlusion versus Right Subaxillary Small Incision Surgical Repair. *Thorac Cardiovasc Surg*. 2015;63(5):409–18.
8. An G, Zhang H, Zheng S, Wang W, Ma L. Mid-term Outcomes of Common Congenital Heart Defects Corrected Through a Right Subaxillary Thoracotomy. *Heart Lung Circ*. 2017;26(4):376–82.
9. Heinisch PP, Wildbolz M, Beck MJ, Bartkevics M, Gahl B, Eberle B, et al. Vertical Right Axillary Mini-Thoracotomy for Correction of Ventricular Septal Defects and Complete Atrioventricular Septal Defects. *Ann Thorac Surg*. 2018;106(4):1220–7.
10. Lee T, Weiss AJ, Williams EE, Kiblawi F, Dong J, Nguyen KH. The Right Axillary Incision: A Potential New Standard of Care for Selected Congenital Heart Surgery. *Semin Thorac Cardiovasc Surg*. 2018;30(3):310–6.
11. Kale SB, Ramalingam S. Minimally Invasive Cardiac Surgery Without Peripheral Cannulation: A Single Centre Experience. *Heart Lung Circ*. 2019;28(11):1728–34.
12. Luo C, Zhu J, Bao C, Ding F, Mei J. Minimally invasive and conventional surgical treatment of primary benign cardiac tumors. *J Cardiothorac Surg*. 2019;14(1):76.
13. An G, Zhang H, Zheng S, Wang W, Wu Q, Xing Q. Minimally invasive surgical closure for doubly committed subarterial ventricular septal defects through a right subaxillary thoracotomy. *Interact Cardiovasc Thorac Surg*. 2016;23(6):924–8.
14. Del Nido PJ. Minimally Invasive Cardiac Surgical Procedures in Children. *Innovations (Phila)*. 2020;15(2):95–8.
15. Bleiziffer S, Schreiber C, Burgkart R, Regenfelder F, Kostolny M, Libera P, et al. The influence of right anterolateral thoracotomy in prepubescent female patients on late breast development and on the incidence of scoliosis. *J Thorac Cardiovasc Surg*. 2004;127(5):1474–80.

16. Dave HH, Comber M, Solinger T, Bettex D, Dodge-Khatami A, Pretre R. Mid-term results of right axillary incision for the repair of a wide range of congenital cardiac defects. *Eur J Cardiothorac Surg*. 2009;35(5):864–9.
17. Hong Z-N, Chen Q, Lin Z-W, Zhang G-C, Chen L-W, Zhang Q-L, et al. Surgical repair via submammary thoracotomy, right axillary thoracotomy and median sternotomy for ventricular septal defects. *J Cardiothorac Surg*. 2018;13(1):47.
18. Liu R, Rui L, Zhang B, Lin Y, Li S, Hua Z. Through Tricuspid Closure for Doubly Committed Subarterial Ventricular Septal Defect with Right Vertical Subaxillary Mini-incision: A Matched-Pair Analysis. *Pediatr Cardiol*. 2019;40(6):1247–52.
19. Li G, Su J, Fan X, Li Z, Zhang J, Zhu Y, et al. Safety and Efficacy of Ventricular Septal Defect Repair Using a Cosmetic Shorter Right Lateral Thoracotomy on Infants Weighing Less than 5 kg. *Heart Lung Circ*. 2015;24(9):898–904.
20. Heinisch PP, Bartkevics M, Beck MJ, Erdoes G, Glockler M, Humpl T, et al. Right axillary thoracotomy in congenital cardiac surgery: analysis of percutaneous cannulation. *Ann Thorac Surg*. 2020. doi:10.1016/j.athoracsur.2020.10.011.
21. Liao Y, Long X, Zhu S, Tu J, Wen H, Xu J, et al. Minimally access via left anterior mini-thoracotomy for repair of adult subarterial ventricular septal defects. *J Cardiothorac Surg*. 2017;12(1):48.
22. Huang C, Yu T, Zhang X. Doubly Committed Subarterial Ventricular Septal Defects Closure Using Minimal Mid-Partial Sternotomy. *Ann Thorac Cardiovasc Surg*. 2019;25(3):172–5.
23. Nellis JR, Vekstein AM, Meza JM, Andersen ND, Haney JC, Turek JW. Left Anterior Mini-Incision for Pulmonary Valve Replacement Following Tetralogy of Fallot Repair. *Innovations (Phila)*. 2020;15(2):106–10.

Figures

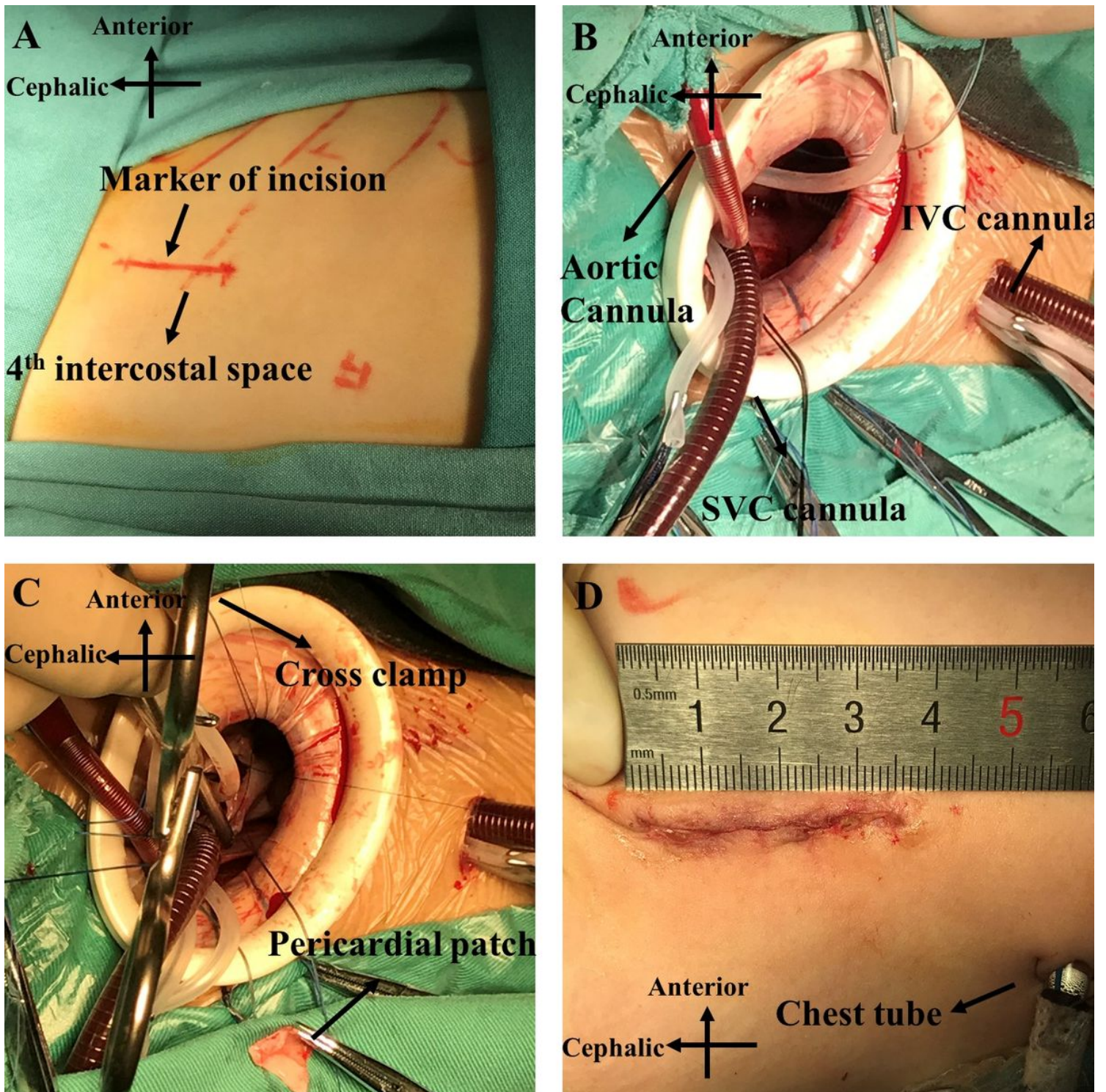


Figure 1

Surgeon's view of minimally invasive cardiac surgery from right sub axillary vertical incision. A, markers of incision and fourth intercostal space; B, setup of the arterial cannula and vena cava cannulas; C, repair of the cardiac defect with a piece of pericardium; D, skin incision and chest tube at the end of operation.

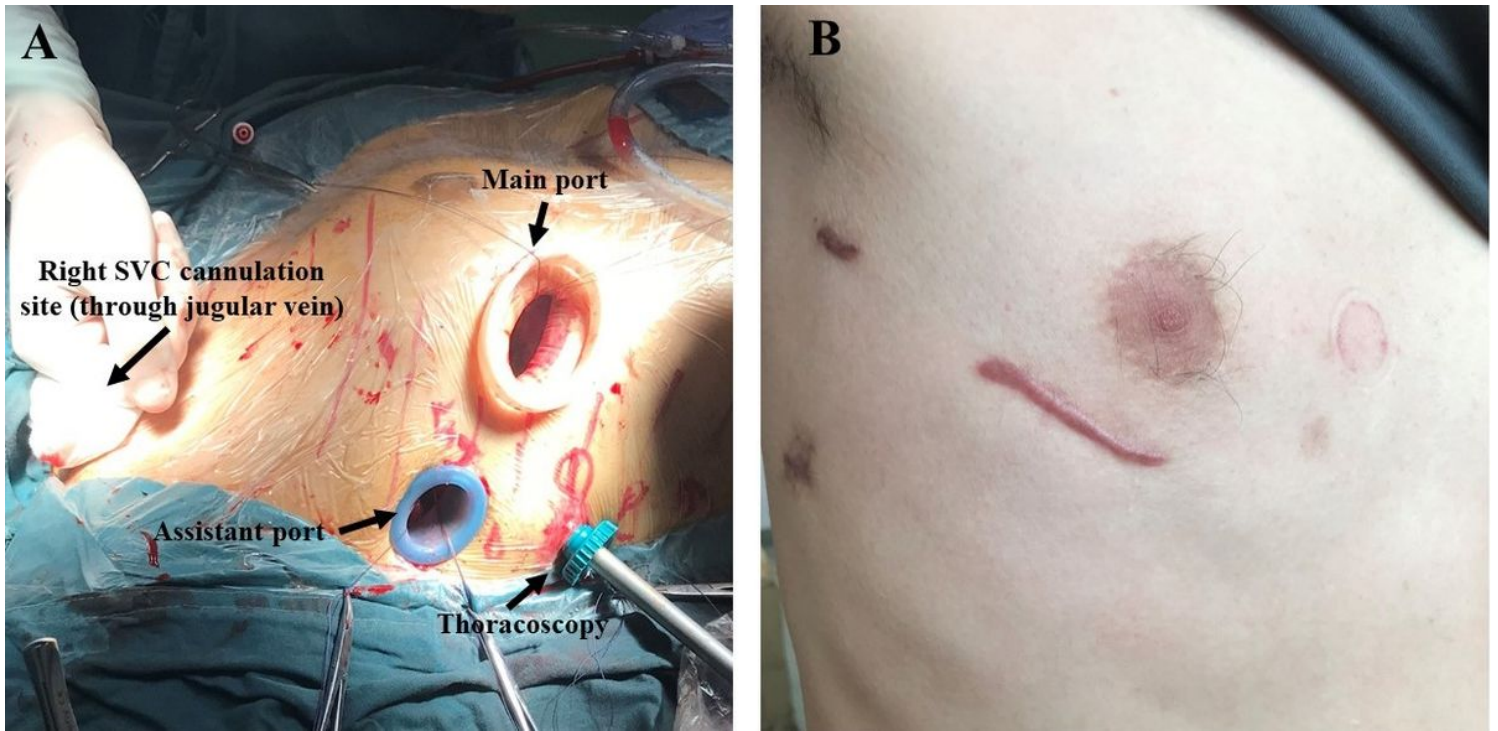


Figure 2

Diagram of right anterolateral incision with thoracoscopy assistance. A, setup of the three ports. The main and assistant ports were in the fourth intercostal space, while the thoracoscopy port was in the sixth intercostal space. Left ventricular vent and Chitwood cross clamp are placed through the assistant port. SVC cannula is placed through right jugular vein. B, skin incision 3 months post operation.

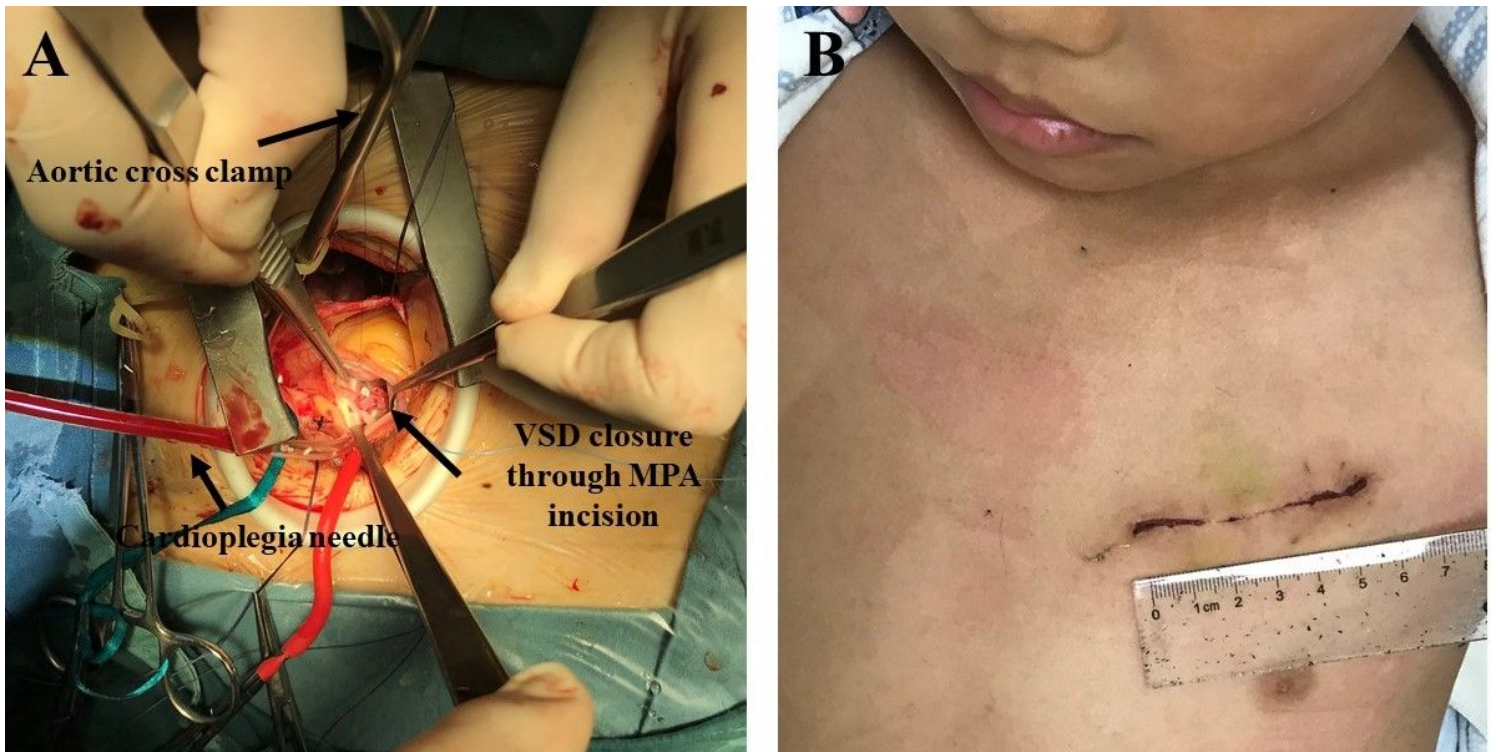


Figure 3

Diagram of left anterolateral incision to repair sub-pulmonary ventricular septal defect. A, surgeon's view of the left 2nd intercostal incision, and the defect was repaired through the main pulmonary artery (MPA) incision; B, incision before discharge.