Redo of ventricular tachycardia ablation in a patient with ischemic cardiomyopathy using the newly omnipolar technology

Sergio Conti (sergioconti.md@gmail.com)
ARNAS Civico – Di Cristina – Benfratelli

Francesco Sabatino
University of Palermo

Giuseppe Sgarito
ARNAS Civico – Di Cristina – Benfratelli

Case Report

Keywords: ventricular tachycardia ablation, multipolar mapping, grid catheter, omnipolar technology, substrate map.

Posted Date: March 17th, 2022

DOI: https://doi.org/10.21203/rs.3.rs-1455898/v1

Abstract

Background

High-definition multielectrode mapping is becoming the cornerstone of complex ablation procedures. Differently from traditional bipolar electrograms that have susceptibility to directionality, Omnipolar Technology (OT) provides voltage, timing, and activation direction assessments independent of catheter orientation by incorporating simultaneously acquired EGM signals from multiple directions.

Case presentation

A 62 years-old male with ischemic cardiomyopathy underwent VT ablation guided by the EnSite X 3D mapping system. The first procedure was performed without the OT, while for the redo, OT was available. The substrate map performed by using the OT was much more defined, and the LPs map showed residual activity. Of great interest, an area noted as a dense scar during the first procedure appeared to be outside the dense scar region at the redo. Complete elimination of LPs in this region made the VT not inducible.

Conclusions

High-definition multipolar mapping using the HD Grid can be rapidly and accurately performed during complex substrate mapping and ablation, such as post-ischemic VT. In particular, omnipolar mapping provide rapid, high-density, orientation-independent assessment of the underlying atrial substrate. This case report has a unique nature considering that the same patient underwent the index procedure without OT and redo with OT.

Background

High-definition mapping is the cornerstone of complex ablation procedures, and multielectrode mapping catheters are widely used to create high-definition substrate and activation maps. However, substrate mapping of a complex substrate, such as ischemic cardiomyopathy, with traditional bipolar voltages may be challenging even with multipolar mapping catheters. The presence of different wavefronts, wave collisions, and EGMs fractionation may result in "pseudo"-low bipolar substrate, worsened by the orientation-dependence of bipolar EGMs. Omnipolar technology (OT) provides voltage, timing, and activation direction assessments independent of catheter orientation by incorporating simultaneously acquired EGM signals from multiple directions. To the best of our knowledge, this is the first report showing, in the same patient, how the OT and the HD Gird mapping catheter improve substrate map during a VT ablation.

Case Report

A 62 years-old male with ICM underwent a redo VT ablation in the setting of ischemic cardiomyopathy. The first procedure was performed using the EnSite X without OT and a substrate-guided approach to abolishing late potentials (LPs) and non-inducibility. After one month, the patient presented with the same VT morphology with a longer CL. The redo was performed using the newly released OT. The substrate map was much more defined, and the LPs map showed residual activity inside a previously ablated area. LPs were successfully ablated, and VT was non-inducible. In this case, OT and HD Grid provided more details of the underlying substrate compared to the bipolar substrate map (Figure 1, Figure 2). Traditional bipolar electrograms have disadvantages such as susceptibility to directionality that OT tries to workaround [1–3]. Overcoming these factors is critical when ablating VTs using a substrate-guided approach to abolish LPs and local abnormal ventricular activities. OT, together with HD Grid SE catheter, aims to provide more details of the underlying substrate and rapidly provide high-density maps.

Conclusions

High-definition multipolar mapping using the HD Grid can be rapidly and accurately performed during complex substrate mapping and ablation, such as post-ischemic VT. In particular, omnipolar mapping provide rapid, high-density, orientation-independent assessment of the underlying atrial substrate. This case report has a unique nature considering that the same patient underwent the index procedure without OT and redo with OT. Further studies - i.e., online and offline comparison between OT on and OT off - are needed to evaluate the potential benefit of this new technology and its impact on acute procedural and long-term success.

Declarations

Conflict of interest: None of the authors have a conflict of interest related to this paper

Funding: None

Acknowledgments: The authors would like to thank Marco Riina, BEng, for the support.

Ethics approval and consent to participate: Not applicable.

Consent for publication: The patient signed informed consent for the procedure data collection and publication.

Availability of data and materials: Procedural data are available in the hospital database.

Competing interest: There are no conflicts of interest of any of the authors.

Funding: This case was not funded by any organization.

Authors' contribution:

Sergio Conti, MD, Ph.D. performed the procedure and wrote the case

Francesco Sabatino, MD, collected the procedural data

Giuseppe Sgarito, MD, Ph.D., critically reviewed the case

Acknowledgments: Acknowledgments to Marco Riina, BEng, for the support.

References

1. Porta-Sanchez A, Magtibay K, Nayyar S, et al. Omnipolarity applied to equi-spaced array for ventricular tachycardia substrate mapping. Europace 2019; 21(5):813–21.
2. Porta-Sanchez A, Magtibay K, Masse´ S, et al. Equi-spaced electrode array for orientation independent bipolar substrate mapping. Europace 2018; 20(suppl 1):196.
3. Magtibay K, Masse´ S, Asta J, et al. Physiological assessment of ventricular myocardial voltage using omnipolar electrograms. J Am Heart Assoc 2017;6: e006447.

Figures

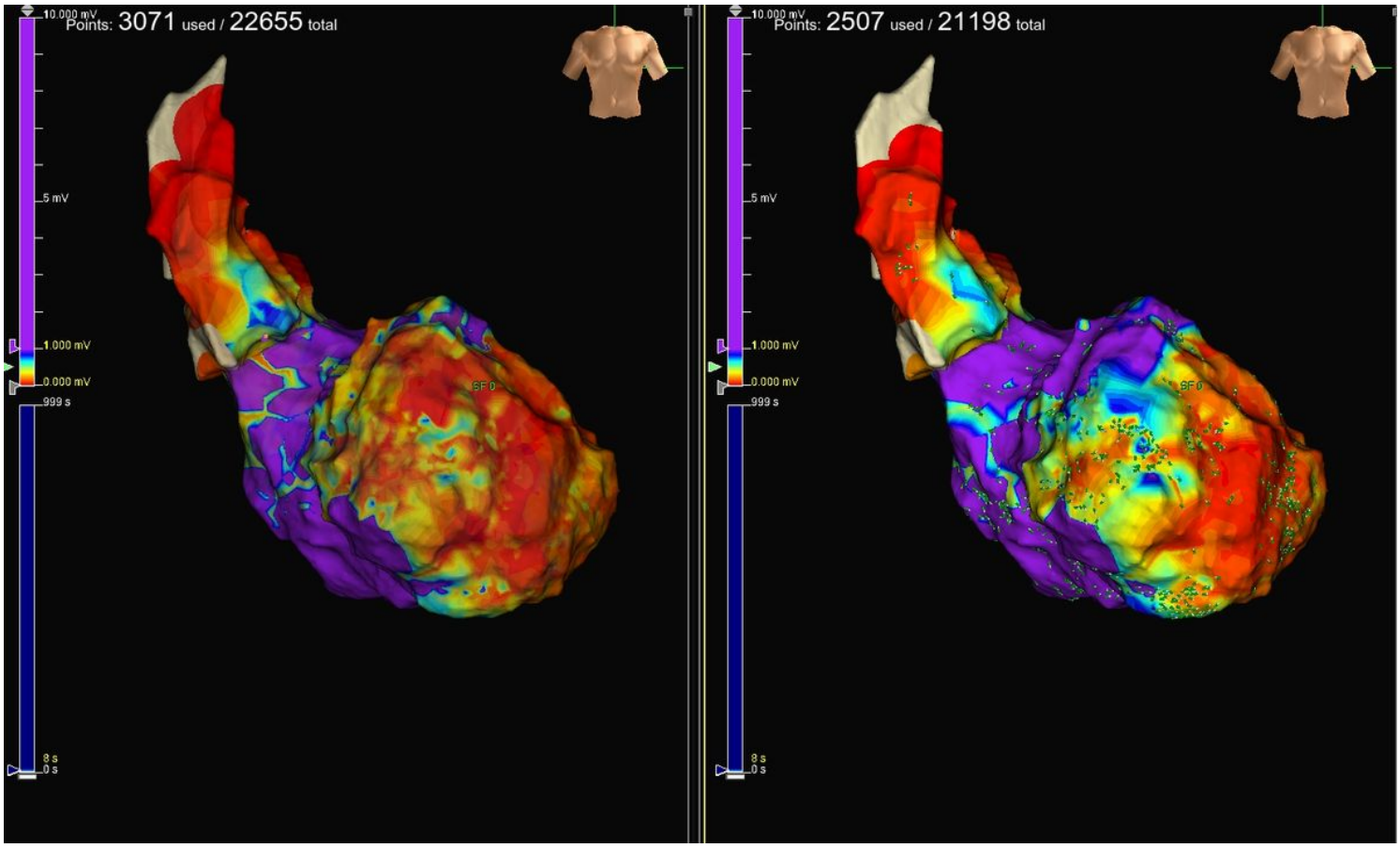

Figure 1

Anteroposterior view of the left ventricle.

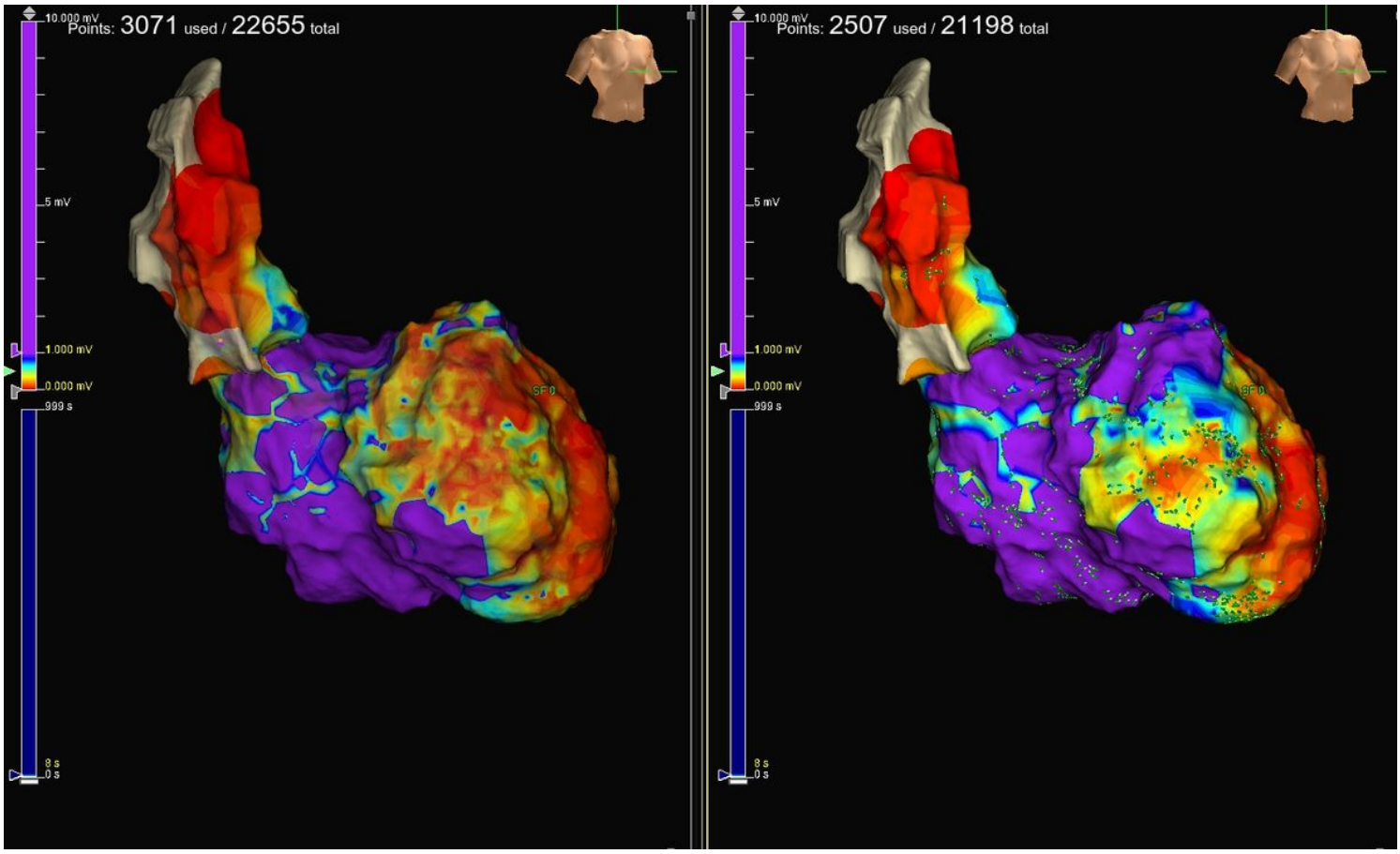

Figure 2

Right anterior oblique view of the left ventricle.

Left panel: standard bipolar map. Right panel: Omnipolar map. Even though we collected fewer points (2507 vs. 3071) in the omnipolar map, we observed a better definition of the substrate and the propagation of the LV activation during right ventricular pacing.