Comparison of Intraocular Tamponade in Patients with Peripheral Tear-Induced Retinal Detachment Coexist Macular Hole without High Myopia

Yucel Ozturk
Haydarpasa Numune Egitim ve Arastirma Hastanesi: Istanbul Haydarpasa Numune Egitim ve Arastirma Hastanesi

Abdullah Ağın (abdullahagin@gmail.com)
Haseki Training and Research Hospital: Istanbul Haseki Egitim Ve Arastirma Hastanesi
https://orcid.org/0000-0001-7173-8617

Aysun Yucel Gencoglu
Haydarpasa Numune Egitim ve Arastirma Hastanesi: Istanbul Haydarpasa Numune Egitim ve Arastirma Hastanesi

Mustafa Talan
kartal city hospital

Muhammed Nurullah Bulut
kartal city hospital

Research Article

Keywords: Internal limiting membrane, macular hole, rhegmatogenous retinal detachment, vitrectomy

Posted Date: March 28th, 2022

DOI: https://doi.org/10.21203/rs.3.rs-1462771/v1

Abstract

Purpose

To introduce the surgical results and examine the effect of intraocular tamponades on surgical outcomes in patients with coexisting macular hole (MH) and rhegmatogenous retinal detachment (RRD) without high myopia.

Methods

This retrospective, cross-sectional, the two-center study was carried out with 29 eyes of 29 patients. The patients were divided into two groups according to the intraocular tamponade used in surgery: silicone oil (group 1) and C3F8 gas (group 2). In all patients, the internal limiting membrane was peeled during surgery. Exclusion criteria were determined as RRD with MH due to high myopia without peripheral retinal tears and traumatic MH.

Results

In group 1, preoperative best-corrected visual acuity (BCVA) was three logMAR, while postoperative BCVA was 1 logMAR ($p < 0.001$). In group 2, preoperative BCVA was 3 logMAR, while postoperative BCVA was 0.76 logMAR ($p = 0.008$). The retinal attachment success rate was 15/17 (89.3%) in group 1, 11/12 (91.7%) in group 2 ($p = 0.64$). MH closure rate was 12/17 (71.6%) in group 1, 10/12 (78.1%) in group 2 ($p = 0.52$). Besides, there was not any difference in terms of preoperative and postoperative BCVA, preoperative and postoperative intraocular pressure, BCVA improvement in both groups. ($p = 0.77$, $p = 0.16$, $p = 0.63$, $p = 0.54$, $p = 0.21$, respectively).

Conclusions

Our results showed no significant difference between using silicone oil or C3F8 gas as an intraocular tamponade after internal limiting membrane peeling in patients with RRD due to peripheral tear coexist MH.

Introduction

The macular hole (MH) is an anatomical opening in the central fovea. It is a treatable cause of central vision loss, more common in older adults, and secondary causes such as myopia, trauma[1–4].

MH accompanying rhegmatogenous retinal detachment (MHRD) is a knotty condition with the prevalence varies from 2–8%.[5, 6] Even though the pathogenesis of MH in MHRD is different from the other common causes of MH such as pathological myopia and trauma, the formation mechanism of MH has

not been fully elucidated in these cases. MHRD may result from posterior vitreous detachment leading to peripheral tears. Further, another proposed hypothesis is related to tangential retraction of the macula, which occurs in conditions such as vitreoretinal interface abnormalities or proliferative vitreoretinopathy. [7, 6, 5].

Pars plana vitrectomy (PPV) is one of the standard treatments for MHRD. Tamponade is necessary to reduce the rate of fluid flow from open retinal tears that will cause recurrent RRD. The main buffering agents available today are various gases and silicone oils. Gases currently available include air, sulfur hexafluoride (SF6), hexafluoroethane (C2F6), and perfluoropropane (C3F8). The most significant advantage of gas tamponade is that the gas usually dissipates spontaneously within a few weeks. Especially in eyes with proliferative vitreoretinopathy, the permanent tamponade effect of silicone provides the use[8]. On the other hand, in addition to the complexity of the formation mechanism of MHRD, surgical management requires a challenging process. Trials and debates are still ongoing regarding whether to perform internal limiting membrane (ILM) peeling, combining scleral buckling with PPV, and using an exogenous extraocular tissue such as the amniotic membrane lens capsular flap to close the hole. [9, 10]

Although there are lots of different studies on this subject in the literature, the effect of tamponade has not been evaluated so far. Our study reported the surgical outcomes and tried to observe how intraocular tamponade affects these complex cases' anatomical and functional results.

Materials And Methods

This is a retrospective, cross-sectional, two-center case study. Twenty-nine eyes of 29 patients who had an MHRD and underwent 23-gauge PPV in the eye clinics of two tertiary university hospitals between 2016–2021 were included in the study. This study carried out with patients with an MH noted preoperatively or discovered during PPV to repair RRD. Some patients had prolapsed RRD or media issues that obstructed the preoperative view of the macula. Patients with at least one tear in the peripheral retina in addition to the MH were included. Exclusion criteria include myopic MHs with associated retinal detachment without peripheral retinal breakage, diabetic retinopathy, trauma, underlying hereditary, and systemic diseases. Sample case is shown in Fig. 1.

We performed detailed examinations of patients diagnosed with RRD. If a preoperative MH was detected, it was noted. Relevant clinical and surgical history information was collected. Best-corrected visual acuity (BCVA), measured on the Snellen eye chart, was recorded before surgery and at the last visit and converted to logarithms of minimum angle resolution (logMAR) acuities. All patients included in the study underwent a comprehensive ophthalmologic examination, including slit-lamp biomicroscopy, dilated fundus examination, and spectral-domain optical coherence tomography (OCT) (Heidelberg Spectralis, Heidelberg Engineering, Dossenheim, Germany). The full-thickness MH was defined using the OCT criteria used in the International Vitreomacular Traction Study[11].

After surgery, patients were divided into two according to the type of tamponade. Patients using silicone oil were classified as group 1, and patients using C3F8 gas were classified as group 2. Retinal attachment was defined as complete absorption of the subretinal fluid and complete attachment of the neurosensory retina to the retinal pigment epithelium. Successful MH closure was defined as the absence of neurosensory defects over the fovea on OCT images (Type 1 closure).

Data collected included preoperative BCVA, MH closure, intraocular tamponade, and postoperative BCVA. The anatomical condition of both the peripheral retina and the macula was documented postoperatively.

Surgery was performed using a standard 3-port, 23-gauge PPV. Combined phaco-PPV was performed in the presence of a cataract. The primary intent in all patients was to repair the RRD, but an attempt was also made to repair the MH. Twenty-three-gauge trocar cannulas were placed 3.5 mm behind the limbus. All patients underwent PPV and ILM peeling surgery. Intraoperatively, it was completely separated from the posterior hyaloid retina after core vitrectomy. Liquid perfluorocarbon was injected to facilitate subretinal fluid drainage and peel ILM safer. Brilliant blue injection was applied to visualize the inner limiting membrane in the macular region, and the inner limiting membrane was peeled off. PVR membranes (if any) peeled. Vitreous base clean-up was carefully completed. Fluid-air exchange was performed, and after retinal reattachment, and endolaser was performed around the peripheral tears. The air in the vitreous cavity was replaced with 16% C3F8 or 1000 centistokes silicone oil. Patients were advised to stay prone for one week after the surgery.

The data were analyzed with the SPSS 22.0 (SPSS Inc., Chicago, IL, USA) program. Data distribution was analyzed with the Shapiro-Wilk test. Demographic variables were expressed as counts and percentages, whereas continuous variables were expressed as a median. The values are presented as the medians. The Mann–Whitney U test was used to compare median values. Changes in values from baseline to final follow-up were analyzed using the Wilcoxon signed-rank test. Differences between groups were compared with Fisher's exact test. A p-value of < 0.05 was considered statistically significant.

Results

Twenty-nine eyes of twenty-nine patients were conducted, the median age was 61.6 years (range 33–80), and the male/female ratio was 18:11 in this study. The average follow-up was nine months, with a range of 3 to 17 months. In all patients evaluated, silicone oil was used as a tamponade in 17 (58.6%), while C3F8 was used in 12 (41.4%). (Table 1) RRD surgery was successful in 26 (89.7%) eyes and unsuccessful in 3 (10.3%) eyes. (Table 2) MH was closed in 22 (75.9%) eyes and not closed in 7 (24.1%) eyes. In group-based assessment, retinal attachment showed a success rate was 15/17 (89.3%) in group 1, 11/12 (91.7%) in group 2 ($p = 0.64$). MH closure rate was 12/17 (71.6%) in group 1, 10/12 (78.1%) in group 2. Postoperative median BCVA increased from 3 to 1 logMAR in group 1 and from 3 to 0.76 logMAR in group 2 $p < 0.001$, $p = 0.08$, respectively). Intraocular pressure (IOP) before and after surgery were similar in two groups ($p = 0.41$, $p = 0.82$, respectively) (Table 3).

Table 1
Patient Demographics and Characteristics

Variable	Data
Gender (M/F)	18(62.1%)/11(37.9%)
Age (median)	61.6
Hole closure (yes/no)	22(75.9%)/7(24.1%)
Retinal attachment (yes/no)	26(89.7%)/3(10.3%)
Tamponade (silicone oil/ C3F8)	17(58.6%)/12(41.4%)

Table 2
Surgical success in patient groups

	Group 1	Group 2	p*
Retinal attachment Yes	15(89.3%)	11(91.7%)	0.64
No	2(11.7%)	1(8.3%)	
Macular hole closure Yes	12(71.6%)	10(78.1%)	0.52
No	5(29.4%)	2(16.6%)	
Fisher's exact test, p*<0.05			

Table 3
Comparison of median BCVA and IOP values before and after surgery within the groups

Variable	Preoperative BCVA (logMAR) [median (min-max)]	Postoperative BCVA (logMAR) [median (min-max)]	p-value
Group 1	3 (0.7-3)	1 (0.2-3)	<0.01*
Group 2	3 (2–3)	0.76 (0.3-3)	0.008*
	Preoperative IOP (mmHg) [median (min-max)]	Postoperative IOP (mmHg) [median (min-max)]	
Group 1	13 (10–19)	15 (12–16)	0.41
Group 2	15 (10–17)	14 (9–18)	0.82
Wilcoxon signed rank test, *p < 0.05, BCVA = Best corrected visual acuity, IOP = Intraocular pressure.			

As shown in Table 4, there is no difference in preoperative and postoperative BCVA, preoperative and postoperative IOP and BCVA improvement. (p = 0.77, p = 0.16, p = 0.63, p = 0.54, p = 0.21, respectively).

Table 4
The median values of the groups were analyzed using the Mann-Whitney U test.

Variable	Group 1 (n = 17) (logMAR) [median (min-max)]	Group 2 (n = 12) (logMAR) [median (min-max)]	p-value
Preoperative BCVA	3 (0.7-3)	3 (2–3)	0.77
Postoperative BCVA	1 (0.2-3)	0.76 (0.3-3)	0.16
BCVA increment	1.14(0.18–2.48)	2 (0.4–2.7)	0.21
Preoperative IOP (mmHg)	13 (10–19)	15(12–16)	0.63
Postoperative IOP (mmHg)	15 (10–17)	14 (9–18)	0.54
Mann-Whitney U test, *p < 0.05, BCVA = Best corrected visual acuity, IOP = Intraocular pressure.			

Discussion

The complex process in the formation of MHRD and the basis of two criteria (retinal attachment and MH closure) that determine the success create various difficulties in applying optimal intervention and acquiring the intended anatomic and functional outcome by struggling with the problem of MH in this patient group. Our study represented the surgical outcomes and investigated the effects of two crucial post-surgical internal tamponades, silicone oil, and C3F8 gas, on visual and anatomical results. Surgery in patients with MHRD has two purposes. The first goal is to restore the retinal attachment, while the second goal is to close the MH. If an only retinal attachment is achieved from the intended targets, postoperative vision will not improve at the desired level. Therefore, we must ensure successful MH closure to improve the resulting visual acuity. Our series provided retinal attachment in 89% of group 1 and 91% of group 2. Further, we achieved MH closure in 71% of group 1 and 78% of group 2.

ILM peeling is a cornerstone for MH closure via altogether removing all contractile cells from the edge of MH. Although the ILM does not have natural contractile properties, it serves as a scaffold for the contractile tissue to exert tangential traction on the umbo. The completeness of elimination of the overlying contractile tissue when the ILM is peeled provides a higher surgical success and contrast sensitivity than in eyes without membrane peeling.[12, 13]. On the other hand, one study conducted by Shukla et al found that ILM peeling did not result in higher closure rates for the MH than those of eyes without ILM peeling, which has better BCVA.[14] In their series, different from our study, Shukla et al. used silicon oil in 26 cases and C3F8 gas in 5 cases. Additionally, they reported a 100% retinal attachment rate,

and all patients underwent encircling scleral buckle different from our series. This minor difference in terms of the two series may be related to the possible effect of the scleral buckle. Besides, the authors touted type 2 closure as a successful closure in this study. However, eight (57%) of the fourteen closed holes in patients with ILM peeling had type 2 closure, whereas in patients without ILM peeling, three (23.1%) of 13 closed holes had type 2 closure. Our study classified only type 1 closure as an accurate and successful closure and achieved these rates.

Chen et al. [15] achieved 100% success in both retinal attachment and closure of the MH with a free retinal flap assisted by liquid perfluorocarbon in their case series of seven people. This method can be used in failed MH closure, although not in the first surgery. A recent study conducted by Zhu et al.[16] compared the ILM flap and ILM insertion techniques on MH closure in 49 MHRD cases. It showed that the ILM flap was superior to the ILM insertion technique to improve the postoperative BCVA. In this series, MH closure was observed at 95% in the ILM flap group and 73% in the ILM insertion group. However, forty (82%) patients in this series were high myopic. In our series, high myopic patients were determined as exclusion criteria in the evaluation. By performing only ILM peeling, we achieved MH closure in 75.9% of the patients in our series.

Ryan et al. [9] showed that ILM peeling increased the success of MH closure in MHRD cases and reported that MH was closed at a rate of 90.7% in these cases, and MH was closed at a rate of 33.3% in cases where ILM was not peeled (Average 83.7%). The authors did not use perfluorooctane in their cases due to the concern of transmission to the subretinal region due to MH and dye due to possible toxicity. We used both brilliant blue and perfluorocarbon in all of our cases and did not encounter any problems associated with them. They also showed that SF6 was superior to C3F8 in terms of success, but we did not use SF6 as a postoperative tamponade in any patient of our series.

Although modern surgical techniques are very advanced, ILM peeling from the detached retina is challenging. The use of liquid perfluorocarbon and dyes such as brilliant blue facilitates ILM peeling in these cases. Some authors have developed bimanual peeling techniques because of the concern that there may be a transition from the hole to the back of the retina during the use of liquid perfluorocarbon. This technique risks serious complications such as macular trauma and paramacular breaks. Peeling the ILM under perfluorocarbon liquid eliminates the need for bimanual counterpressure and reduces the risk of macular annealing. We used liquid perfluorocarbon and brilliant blue dye when peeling ILM in all our cases[17–21].

Conclusion

To best of our knowledge, although there are much information about MHRD secondary high myopia, there is no study as large as our series evaluating patients with MHRD without high myopia in the literature. We presented our surgical results and investigated the efficacity of these intraocular tamponades on surgical success. On the other hand, the limitation of our study includes retrospective

nature. Additionally, we could not perform preoperative OCT imaging in all patients due to the nature of RRD. We made the diagnosis of an MH mostly during the operation.

There is no significant difference between silicone oil or C3F8 gas as an intraocular tamponade after ILM peeling in patients with MHRD. Silicone oil does not have a significant superiority over C3F8 in cases with MHRD. Considering the potential problems that the use of silicone may cause in the future, C3F8 gas can be used in suitable cases as a postoperative tamponade in MHRD.

Declarations

Compliance with ethical standards

Funding

This study was funded by the authors and did not receive any grant from finance agencies in the public or commercial sectors.

Conflict of interest

The authors declare that they have no conflict of interest.

Ethical approval

The study was approved by the Haydarpasa Training and Research Hospital, Clinical Research Ethics Committee (2021/216-3405), and this study complied with the principles of the Declaration of Helsinki.

Informed consent

Informed consent was waived due to the retrospective nature of this study.

References

1. Parravano M, Giansanti F, Eandi CM, Yap YC, Rizzo S, Virgili G (2015) Vitrectomy for idiopathic macular hole. Cochrane Database Syst Rev (5):CD009080. doi:10.1002/14651858.CD009080.pub2

2. Wang S, Xu L, Jonas JB (2006) Prevalence of full-thickness macular holes in urban and rural adult Chinese: the Beijing Eye Study. Am J Ophthalmol 141 (3):589-591. doi:10.1016/j.ajo.2005.10.021

3. Jackson TL, Donachie PHJ, Sparrow JM, Johnston RL (2013) United Kingdom National Ophthalmology Database study of vitreoretinal surgery: report 2, macular hole. Ophthalmology 120 (3):629-634. doi:10.1016/j.ophtha.2012.09.003

4. Budoff G, Bhagat N, Zarbin MA (2019) Traumatic Macular Hole: Diagnosis, Natural History, and Management. J Ophthalmol 2019:5837832. doi:10.1155/2019/5837832A

5. Cunningham MA, Tarantola RM, Folk JC, Sohn EH, Boldt HC, Graff JA, Elkins K, Russell SR, Mahajan VB (2013) Proliferative vitreoretinopathy may be a risk factor in combined macular hole retinal detachment cases. Retina 33 (3):579-585. doi:10.1097/IAE.0b013e31826b0c41

6. Najafi M, Brown JS, Rosenberg KI (2018) Increased Reoperation Rate in Surgical Treatment of Rhegmatogenous Retinal Detachment with Coexistent Macular Hole. Ophthalmol Retina 2 (3):187-191. doi:10.1016/j.oret.2017.07.005

7. Oie Y, Emi K, Takaoka G, Ikeda T (2007) Effect of indocyanine green staining in peeling of internal limiting membrane for retinal detachment resulting from macular hole in myopic eyes. Ophthalmology 114 (2):303-306. doi:10.1016/j.ophtha.2006.07.052

8. Schwartz SG, Flynn HW, Jr., Wang X, Kuriyan AE, Abariga SA, Lee WH (2020) Tamponade in surgery for retinal detachment associated with proliferative vitreoretinopathy. Cochrane Database Syst Rev 5:CD006126. doi:10.1002/14651858.CD006126.pub4

9. Ryan EH, Jr., Bramante CT, Mittra RA, Dev S, Bennett SR, Williams DF, Cantrill HL (2011) Management of rhegmatogenous retinal detachment with coexistent macular hole in the era of internal limiting membrane peeling. Am J Ophthalmol 152 (5):815-819.e811. doi:10.1016/j.ajo.2011.04.026

10. Abouhussein MA, Elbaha SM, Aboushousha M (2020) Human Amniotic Membrane Plug for Macular Holes Coexisting with Rhegmatogenous Retinal Detachment. Clin Ophthalmol 14:2411-2416. doi:10.2147/OPTH.S272060

11. Duker JS, Kaiser PK, Binder S, de Smet MD, Gaudric A, Reichel E, Sadda SR, Sebag J, Spaide RF, Stalmans P (2013) The International Vitreomacular Traction Study Group classification of vitreomacular adhesion, traction, and macular hole. Ophthalmology 120 (12):2611-2619. doi:10.1016/j.ophtha.2013.07.042

12. Park DW, Lee JH, Min WK (1998) The use of internal limiting membrane maculorrhexis in treatment of idiopathic macular holes. Korean J Ophthalmol 12 (2):92-97. doi:10.3341/kjo.1998.12.2.92

13. Brooks HL, Jr. (2000) Macular hole surgery with and without internal limiting membrane peeling. Ophthalmology 107 (10):1939-1948; discussion 1948-1939. doi:10.1016/s0161-6420(00)00331-6

14. Shukla D, Kalliath J, Srinivasan K, Neelakantan N, Rajendran A, Naresh KB, Behera UC (2013) Management of rhegmatogenous retinal detachment with coexisting macular hole: a comparison of vitrectomy with and without internal limiting membrane peeling. Retina 33 (3):571-578. doi:10.1097/IAE.0b013e31826b6748

15. Chen SN, Yang CM (2019) Perfluorocarbon Liquid-Assisted Neurosensory Retinal Free Flap for Complicated Macular Hole Coexisting with Retinal Detachment. Ophthalmologica 242 (4):222-233. doi:10.1159/000502443

16. Lyu J, Xia F, Zhao P (2022) Intraoperative Perfluorocarbon Liquid Tamponade Technique for Treatment of Extensive Retinal Detachment Secondary to a Myopic Macular Hole. Retina. doi:10.1097/IAE.0000000000003429

17. Ichibe M, Yoshizawa T, Murakami K, Ohta M, Oya Y, Yamamoto S, Funaki S, Funaki H, Ozawa Y, Baba E, Abe H (2003) Surgical management of retinal detachment associated with myopic macular hole: anatomic and functional status of the macula. Am J Ophthalmol 136 (2):277-284. doi:10.1016/s0002-9394(03)00186-7

18. O'Driscoll AM, Goble RR, Kirkby GR (2001) Vitrectomy for retinal detachments with both peripheral retinal breaks and macular holes. An assessment of outcome and the status of the macular hole. Retina 21 (3):221-225. doi:10.1097/00006982-200106000-00004

19. Nishimura A, Kita K, Segawa Y, Shirao Y (2002) Perfluorocarbon liquid assists in stripping the ILM to treat detached retina caused by macular hole. Ophthalmic Surg Lasers 33 (1):77-78

20. Uemoto R, Yamamoto S, Tsukahara I, Takeuchi S (2004) Efficacy of internal limiting membrane removal for retinal detachments resulting from a myopic macular hole. Retina 24 (4):560-566. doi:10.1097/00006982-200408000-00009

21. Chen YP, Chen TL, Yang KR, Lee WH, Kuo YH, Chao AN, Wu WC, Chen KJ, Lai CC (2006) Treatment of retinal detachment resulting from posterior staphyloma-associated macular hole in highly myopic eyes. Retina 26 (1):25-31. doi:10.1097/00006982-200601000-00005

Figures

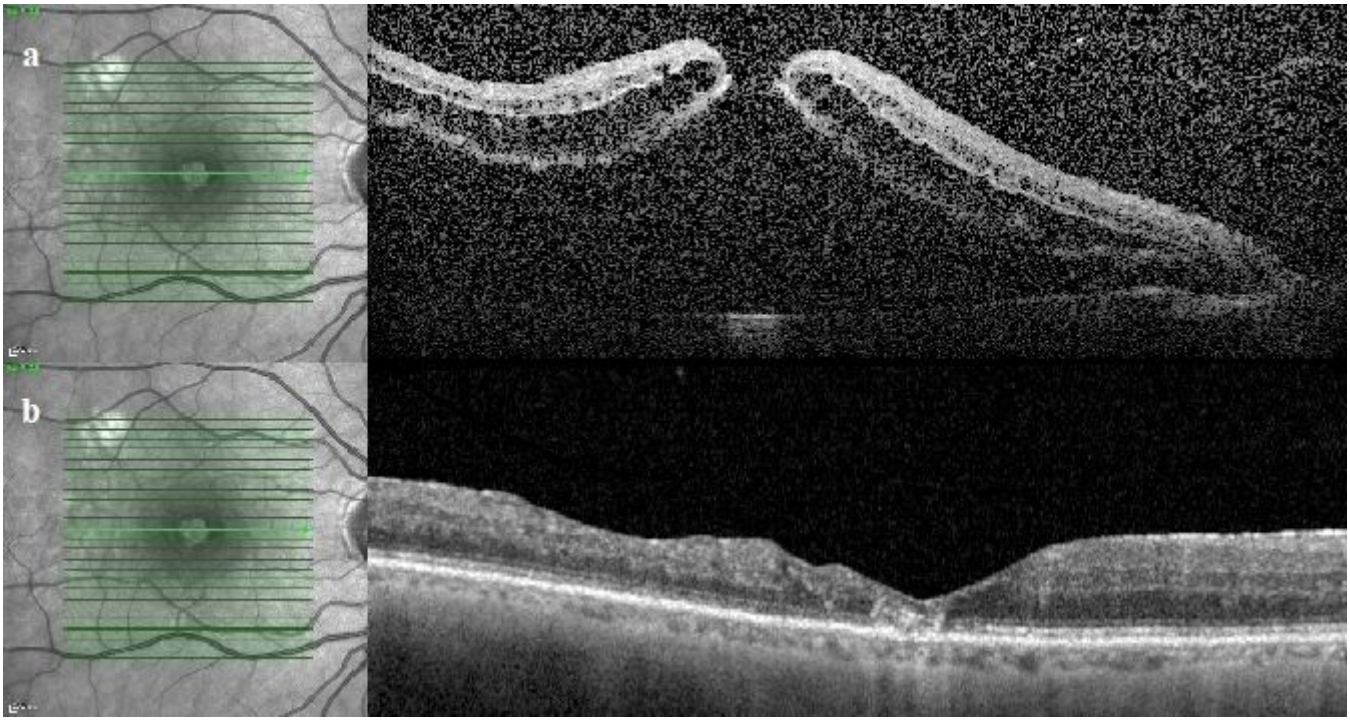

Figure 1

Preoperative OCT image of a patient with retinal detachment and macular hole (A), OCT image of the same patient after silicone oil removal (B).